

The temporal structures in aging - MRI and unbiased stereological studies

Jerzy Dziewiątkowski¹, Barbara Bobek-Billewicz²,
Janusz Moryś¹ and Olgierd Narkiewicz¹

1.- Department of Anatomy and Neurobiology, Medical University of Gdańsk, Poland.

2.- Department of Radiology, Medical University of Gdańsk, Poland.

SUMMARY

The aim of the study was to assess the age-related differences in the volume of the structures of the temporal lobe in the MRI scans using stereological approach. The brains of 29 volunteers aged from 15 to 89 years without any pathological changes in the central nervous system were studied. Special approach was used to minimize the methodological error and to decrease the intersubject variability of measurements. 1- or 1.5-mm thick consecutive scans perpendicular to the long hippocampal axis were used for semiautomatic evaluation of the temporal structures' volume with estimated coefficient of error below 3%. Normalization of raw data was performed according to the covariance principle. The planned comparisons revealed the significant differences in the normalized volumes of the superior temporal gyrus, amygdala and hippocampus between left and right hemispheres in both the younger (with age < 50) and older group (with age > 50). Additionally, the normalized volume of the left hippocampus differed significantly between these two groups. The correlation analysis revealed that the changes of the normalized volume of hippocampus and lateral ventricle were significantly correlated with age both on the right and left side, and that age was not correlated with the normalized volume of any temporal structure in the older group.

Key Words: Temporal lobe - MRI - Aging - Stereology.

INTRODUCTION

The importance of the temporal structures in learning, memory and emotion has been explored in relation to a variety of neuropsychiatric disorders such as schizophrenia, autism, Alzheimer's disease and Down's syndrome. Neuroanatomic and brain imaging studies of healthy individuals show or, according to others, do not show decrease in the amount of the cerebral tissue with advancing age.

According to neuropathological investigations brain weight decreases by about 10% between ages of 8 and 75 (Miller et al., 1980; Tien et al., 1993). Other authors (Double et al., 1996) have found decrease (although not significant - $p=0.11$) of the volume of white matter in 20 healthy cases in the age range 46-92. The decrease of the neuronal population and replacement gliosis (Brady and Mufson, 1990) accompanied by the 20% decrease of the cerebral blood flow can also reflect aging changes in the central nervous system.

Herzog and Kemper (Herzog and Kemper, 1980) found not significant 2% reduction of the volume of the amygdaloid body. However, their groups consisted of four cases only.

Neuropathological investigation of age-related changes on each level of the study usually involves limited number of subjects or structures and additionally can be the source of the possible errors and biases. Only new designs based on contemporary stereological principles, like the study of Hofman et al. (1988) and West (1993), can give reliable results. In these studies the authors have revealed the significant decline of the volume with age in two parts of

Correspondence to:
Janusz Moryś M.D., Ph.D. Department of Anatomy and Neurobiology Medical
University of Gdańsk. 1 Dębinki Street 80-211 Gdańsk, Poland.
Tel.: (+4858) 349-1401. Fax.: (+4858) 349-1421
E-mail: jmorys@amedec.amg.gda.pl

Submitted: May 20, 1999
Accepted: July 31, 1999

the hippocampal formation – hilus and subiculum.

Through the use of brain imaging techniques these problems can be avoided and the opportunity to examine brain morphology in vivo is available. Some of mentioned above neuropathological findings can be reflected during radiological assessment as a diffuse atrophy, ventricles' enlargement and widening of sulci as well as perivascular spaces (Wright and Spink, 1959; Miller et al., 1980; Hubbard and Anderson, 1981).

Because volumetric MRI may be important for the diagnosis of the senile dementia of Alzheimer type, particularly in early stages, the aim of our study was to assess age-related differences in the volume of the structures of the temporal lobe on the MRI scans using stereological approach.

MATERIAL AND METHODS

The brains of 29 volunteers aged from 15 to 89 years without any neurological symptoms of the pathological changes in the central nervous system and without any distinguishable signs on MR scans were used for morphometric evaluation of the temporal structures.

MR imaging

MRI was performed on 0.5T superconducting MRI scanner (Gyrosan T5, Philips) with the use of standard head coil. In the first step, axial SE PD/T2 sequence (TR 2200, TE 20/80, Thk/gap 6/0,6 NSA 1 or 2) on whole brain was obtained to evaluate the brain structures and to rule out gross pathology, as well as, to measure the intracranial volume (ICV) – this parameter was used for the normalization of the results.

In the second step, multi stack scout sequence (FFE M2D, TR/TE/Flip 10/2.9/60 Thk/gap 10.0/10.0) and sagittal scout sequence (SE T1, TR/TE 372/15.0, Thk/gap 6.0/1.0) were performed. The sagittal sequence was used to locate the plane of the hippocampus and then the coronal sequence (perpendicular to the long axis of the hippocampus) on temporal lobe was performed (T1W/ 3D /FFE, TR/TE/Flip 30/13/3, Thk/gap 1 or 1,5mm/0, NSA 1).

Stereology

Morphometric study was performed on coronal MRI scans by using semiautomatic method on image analyzer Q500MC working under software QWin on Pentium 233MHz with 17" SVGA monitor. All MRI scans were saved on disk and then the automatic procedure including sequential reading, contrast enhancing, manual drawing of the structures on the scans, automatic calculation of the cross-sectional area of drawn struc-

tures and saving of partial results for consecutive calculation was used. For the estimation of the volume, the Cavalieri formula was used (the estimated volume is a product of the sum of the cross-sectional areas of the structure (A_i) and the distance between two consecutive scans ($t=1$ or 1.5 mm)

$$\hat{V} = \sum_{i=1}^n V_i = t \times \sum_{i=1}^n A_i \quad [\text{mm}^3]$$

Along with the volume estimation the coefficient of error was calculated in worksheet according to the formulas proposed by Geinisman et al. (Geinisman et al., 1996).

$$CE(\hat{V}) = \frac{\sqrt{Nug + Var_{SRS}}}{\sum_1^n A_i}$$

$$Var_{SRS} = \frac{3(\sum_1^n (A_i \times A_i) - Nug) - 4\sum_1^{n-1} (A_i \times A_{i+1}) + \sum_1^{n-2} (A_i \times A_{i+2})}{12}$$

where *Nug* ("noise-effect") was equal to 0 if the measurements were done by digitizer.

Var_{SRS} reflects the variability of consecutive cross-sectional areas of the structure on MR scans. The sampling was designed to obtain the CE smaller then 3%.

The following structures were studied within the space bordered by the anterior pole of the amygdaloid body and the posterior pole of the hippocampal head (uncus): superior temporal gyrus (STG), basolateral temporal area (BTG – the region including middle temporal gyrus, inferior temporal gyrus and fusiform gyrus), parahippocampal gyrus (PAH), hippocampus (HIP), amygdaloid body (AA) and the lateral ventricle (LV; Fig. 1).

Due to significant differences in the intracranial volume between groups of cases data for individual variables in each subject were normalized according to the formula used by Jack et al. (Jack, Jr. et al., 1989).

$$V_i = \hat{V}_i - B(ICV_i - \overline{ICV})$$

where *ICV* – stands for intracranial volume of the *i*-th case; \overline{ICV} – means intracranial volume, \hat{V}_i – is used for estimated volume of the structure in the *i*-th case; and *B* is the coefficient of regression (slope) based on the dependence between the intracranial volume and volume of the structure.

Statistics

For the statistical analysis of the volumetric changes of medial temporal structures in 29 volunteers the MANOVA (Statistica®, Statsoft, USA) was used. Two groups of patients were distinguished: „younger” (15 patients with age below 50) and „older” (14 patients with age

above 50). The compatibility of fit with normal distribution was checked by means of the Shapiro-Wilk test, the variances’ equality – by means of the Bartlett’s test.

In the case of nonnormality and/or the presence of the unequal variances nonparametric analysis was used (Friedmann test with conse-

	STG	p	BTG	p	AA	p	HIP	p	PAH	p	LV	p
Younger	-12%	0.05	-5%	ns	11%	0.001	-12%	0.001	9%	ns	-34%	0.05
Older	-17%	0.001	-6%	ns	13%	0.001	-20%	0.001	3%	ns	-28%	ns

Table 1. The percentage of difference between the left and right temporal lobe structures calculated according to the formula: %diff = (VL-VR)/VL, where VL and VR are mean normalized volumes of the structure on the left and right side of the brain, respectively.

	STG	p	BTG	p	AA	p	HIP	p	PAH	p	LV	p
Left	10%	ns	5%	ns	6%	ns	15%	0.02	5%	ns	-63%	ns
Right	6%	ns	4%	ns	9%	ns	9%	ns	-1%	ns	-56%	ns

Table 2. The percentage of atrophy of the temporal lobe structures calculated according to the formula: %diff = (VY-VO)/VY, where VY and VO are mean volumes of the structure in the younger and older group, respectively.

Author	Structure	Normalization
Watson et al. (Watson et al., 1992)	amygdala hippocampus	No
Lehericy et al. (Lehericy et al., 1994)	amygdala hippocampal formation	ratio to total ICV
Jack et al. (Jack, Jr. et al., 1997)	amygdala hippocampal formation	ratio to total ICV
Mori et al. (Mori et al., 1997)	amygdala hippocampal formation subiculum parahippocampal cortex	Covariance
Jack et al. (Jack, Jr. et al., 1989)	hippocampal formation	Covariance
Kaye et al. (Kaye et al., 1997)	hippocampal formation parahippocampus	ratio to supratentorial cavity
Laakso et al. (Laakso et al., 1995a)	amygdala	ratio to intracranial area
Shenton et al. (Shenton et al., 1992)	amygdala-hippocampus superior temporal gyrus parahippocampal gyrus	no adjustment
Juottonen et al. (Buchsbaum and Hazlett, 1998)	entorhinal and perirhinal cortices	ratio to intracranial area on the level of anterior commissurae
Cook et al. (Cook et al., 1992)	amygdala hippocampus	no correction
Bilir et al. (Horoupian and Dickson, 1991)	amygdala hippocampus	ratio to total brain volume
Jack et al. (Jack, Jr. et al., 1992)	anterior temporal lobe hippocampus	ratio to total ICV
Bhatia et al. (Bhatia et al., 1993)	hippocampus whole temporal lobe	normalized to total brain volume
Laakso et al. (Laakso et al., 1995b)	amygdala hippocampus	normalized ratio to total brain area
Laakso et al. (Laakso et al., 1998)	hippocampus	normalized to total brain area
De Carli (DeCarli et al., 1994)	temporal lobe volume	normalized ratio to intracranial volume
Coffey et al. (Coffey et al., 1992)	temporal lobe amygdalo-hippocampal complex	intracranial area taken as a covariate
Soininen et al. (Soininen et al., 1994)	amygdala hippocampus	ratio to brain area on the level of the anterior commissure
Free et al. (Free et al., 1995)	hippocampus	3 methods: covariance method, ratio to intracranial volume, ratio to brain volume

Table 3. Reviews of the methods of normalization of raw volumetric data of the temporal lobe structures.

cutive post-hoc Dunn's tests (InStat®, StatGraph, USA). The age was used as the main factor whereas the side of the brain as the repeated measure. The effect of sex was not evaluated due to large differences in the number of volunteers belonging to the groups.

The age and side effects were evaluated by means of planned comparisons. The interhemispheric asymmetry of the relative volumes of the structures (Left vs Right) was studied in two age groups separately and the differences in the relative volumes between two age groups (Younger vs Older) were studied for each hemisphere.

Additionally, the relative volumes of the studied structures were correlated with age (Spearman's correlation coefficient).

RESULTS

COMPARISON BETWEEN THE OLDER AND YOUNGER GROUP

The side of the brain was the only significant effect of the changes in the relative volumes of the studied structures (MANOVA, $p < 0.001$). The effect of age for all structures was not significant (MANOVA, $p = 0.38$) and there was no interaction between main effects (MANOVA, $p = 0.98$).

Univariate analyses have shown the significant differences related to the age only for the normalized volume of the hippocampus – its value in the older group was significantly smaller ($F = 4.98$, $p = 0.035$).

Univariate analyses have revealed the significant differences related to the side in the relative volume of the amygdala, basolateral temporal area, superior temporal gyrus, hippocampus and the lateral ventricle – their values differed significantly between the hemispheres. The relative volume of the amygdala was significantly larger on the left side ($F = 31.0$, $p < 0.001$; Tab. 1), while the relative volumes of the superior temporal gyrus, basolateral temporal area, and hippocampus were significantly larger on the right side ($F = 14.9$, $p < 0.001$; $F = 4.8$, $p < 0.05$; $F = 33.2$, $p < 0.001$; respectively; Tab. 1).

The planned comparisons revealed the significant differences in the relative volume of the superior temporal gyrus ($F = 5.9$, $p < 0.05$), amygdala ($F = 13.3$, $p < 0.001$) and hippocampus ($F = 12.5$, $p < 0.001$) between left and right hemispheres in the younger group as well as the significant differences in the relative volume of the superior temporal gyrus ($F = 9.1$, $p < 0.001$), amygdala ($F = 17.8$, $p < 0.001$) and hippocampus ($F = 21.5$, $p < 0.001$) between left and right hemispheres in the older group (Tab. 2).

The relative volume of the lateral ventricle differed significantly between the left and right hemisphere only in the younger group.

The planned comparisons have shown the significant differences in the relative volume of the hippocampus ($F = 6.4$; $p < 0.02$) in the left hemisphere between the groups under study. In the right hemisphere, there were no differences between the relative volumes of any structures.

CORRELATION OF THE NORMALIZED VOLUME OF THE TEMPORAL STRUCTURES WITH AGE

Taking into account all 29 cases the changes of the relative volume of hippocampus and lateral ventricle were significantly correlated with age both on the right and left side. The Spearman's correlation coefficient was positive for the relative volume of the lateral ventricle (the volume of the lateral ventricle increases with age on the left and right side; $r = 0.41$, $p < 0.01$ and $r = 0.43$, $p < 0.01$, respectively). The relative volume of the hippocampus correlated negatively with age ($r = -0.60$, $p < 0.001$ and $r = -0.43$, $p < 0.01$; on the left and right side, respectively, Fig. 2).

In the younger group we have observed significant correlation of the normalized volume of both left and right hippocampus with age ($r = -0.67$, $p < 0.001$; and $r = -0.56$, $p < 0.001$, respectively). In older group there was no correlation of the normalized volume of any structure with age.

DISCUSSION

STEREOLOGICAL BASIS OF THE ACCURATE MEASUREMENTS

Considering statistical principles to be necessary to distinguish any statistical difference between various groups, the maximum acceptable value of the coefficient of error (CE) of estimated parameter should be lower than 5%. Cook et al. (1992) showed, that in order to reach this prediction level one has to have scans of temporal lobe structures of 3 mm or smaller. In our study we used very thin MR slices (1 or 1.5mm with no gap between), as a consequence we had each of the temporal lobe structure present on 10 to 20 images. We have assumed more rigorous stereological principles for the estimation of the volume of the structures by evaluation of the coefficient of error (CE) of the volume estimation. Also, to minimize methodological error by optimizing the view we used the coronal MR slices perpendicular to the long hippocampal axis (Soininen et al., 1994). Calculation of the CE for

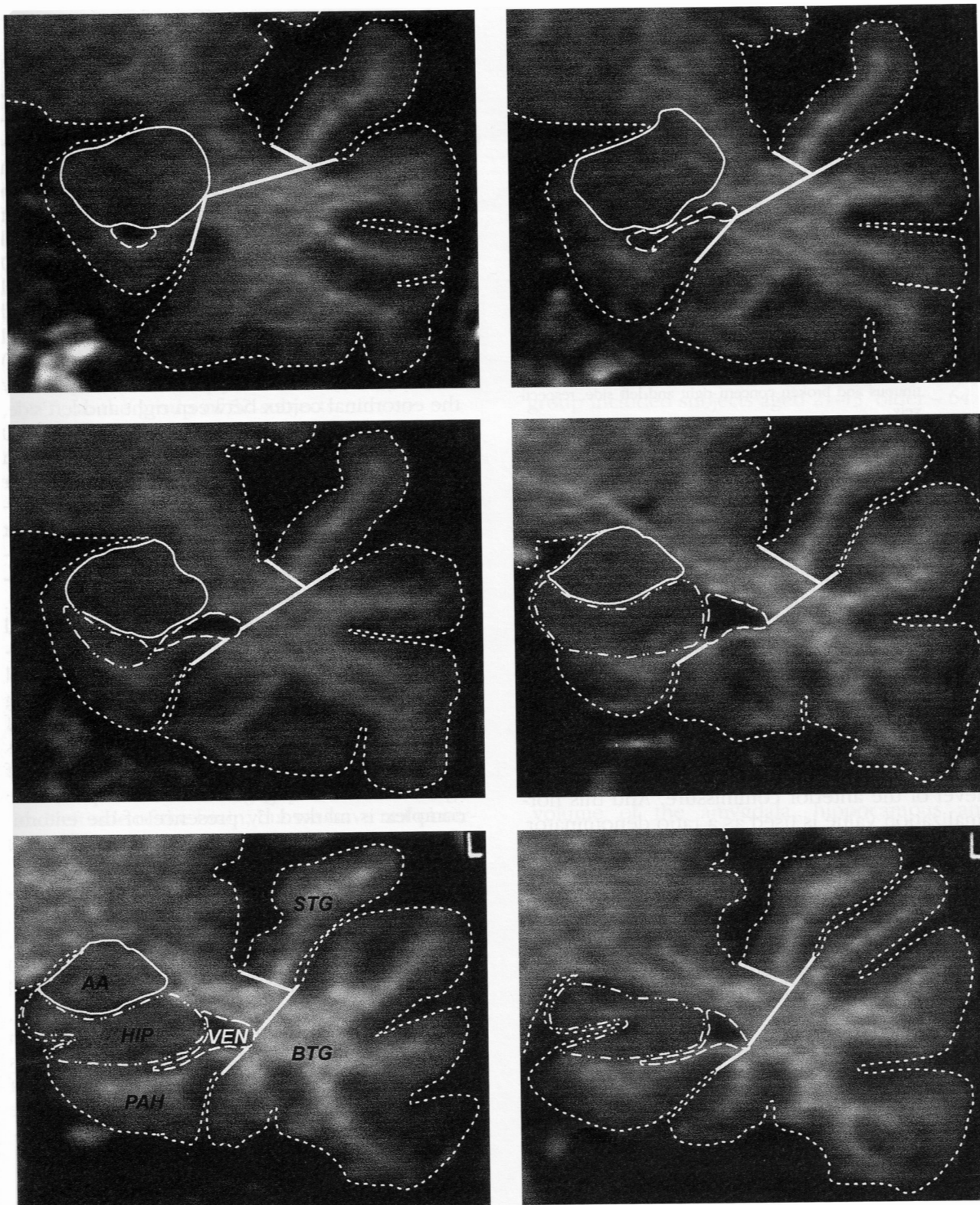


Fig. 1. The neuroanatomic boundaries of structures under study on coronal oblique sections through the anterior part of the temporal lobe. The anatomic outlines of the amygdala (AA), hippocampus (HIP), temporal horn of the lateral ventricle (VEN), parahippocampal gyrus (PAH), superior temporal gyrus (STG) and basolateral temporal gyri (BTG) are indicated on the images.

various structures, in each case revealed that using our design we could reach the CE as small as 1-3%. Manual digitizing of temporal lobe structures (although time-consuming) on consecutive thin (1 or 1.5 mm) MR scans on the screen of high-resolution monitor gave us the value

of Nugget equal 0 and diminished the overall CE. In such a case the CE (or relative variance) of the volume estimation depended only on the number of scans used for calculation and the “shape” of the structure.

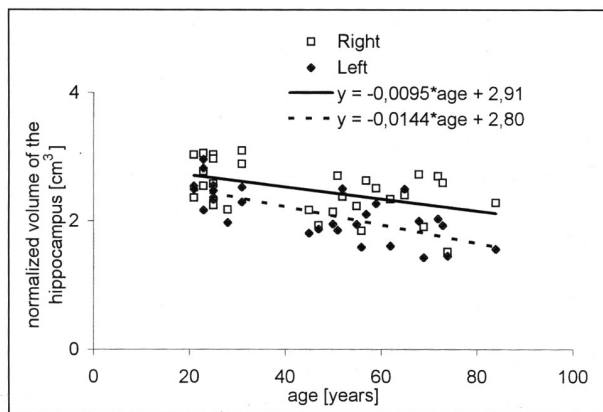


Fig. 2. The normalized volume of the hippocampus on the left and right side in relation to the age. Regression lines: continuous and broken concern right and left side, respectively.

NORMALIZATION OF THE VOLUMES OF THE TEMPORAL STRUCTURES

In the literature three different designs to normalization of the data could be found: (1) raw data (without normalization), (2) data normalized on the basis of area or volume measurement and (3) data with normalization done by ratio or covariate approach (Tab. 3). For the areal normalization – the estimated volume of the structure is divided by the area of the horizontal or coronal plane of the brain on the level of the anterior commissure. And this normalization value is used as a ratio denominator. For the volumetric normalization the total intracranial volume or supratentorial volume or volume of the brain may be used. This normalization value can be exploited in two ways – as a ratio denominator or as a covariant. Additionally statistical methods (ANCOVA) allow us to study the influence of covariable on raw data.

Free et al. (Free et al., 1995) evaluates various methods of normalization on the basis of 2D- or 3D-reference space (“areal” or “volumetric” normalization, respectively) and two methods – on the basis of ratio or covariance method. We used covariance approach with 3D-reference space proposed by him. This approach requires the normal distribution of both variables (volume of the structure and intracranial volume) and a presence of linear correlation between them. Although time-consuming according to Free et al. (Free et al., 1995) this evaluation method is one of the best at reducing in variance in the corrected volumes of given structure.

Additionally, as a consequence, contrary to the results obtained by simple “ratio adjustment”, it gives better distributional properties (Jack, Jr. et al., 1989).

ASSYMETRY OF THE STRUCTURES OF THE TEMPORAL LOBE

In the literature the large discrepancies concerning the asymmetry of the temporal lobe structures exist. For example: according to some authors, there is no effect of the side of the brain on the volume of the hippocampal formation (Cook et al., 1992; Bhatia et al., 1993; Lehericy et al., 1994; Kaye et al., 1997) and amygdaloid body (Lehericy et al., 1994; Kaye et al. (1997) have found no differences in the hippocampal and temporal lobe volumes but they have found significant differences in the parahippocampal volume. Juottonen et al. (Juottonen et al., 1998) have found the difference in the volume of only the entorhinal cortex between right and left side, with the former being larger in their study of 30 control subjects aged 64-79, the differences in the volumes of the perirhinal and temporopolar cortices were not significant. Bhatia et al. (Bhatia et al., 1993) have not found any significant interhemispheric difference in the volume of either the whole temporal lobe or the hippocampal formation in 29 controls aged from 22 to 47. Shenton et al. (Shenton et al., 1992) have found no left-right asymmetry in the volume of amygdalo-hippocampal complex, parahippocampal gyrus, and superior temporal gyrus in the young group of subjects (age matched to group of patients with schizophrenia). However borders of this complex depend on the observation of other structures (e.g. the anterior level of the complex is marked by presence of the entorhinal sulcus, and posterior – by the presence of the mammillary bodies).

Some authors have found that right hippocampal formation has been larger than left (Jack, Jr. et al., 1989; Coffey et al., 1992; Watson et al., 1992; Soininen et al., 1994; Bilir et al., 1998) what agrees with our results. The amygdaloid body is larger either on the right (Watson et al., 1992; Bilir et al., 1998), or on the left (Soininen et al., 1994; Laakso et al., 1995a); the first one is in concordance with our data. The reasons of such discrepancies could be found among the various numbers of studied subjects and different MRI evaluation.

AGING CHANGES

The relative preservation of the neocortical temporal lobe (with little or modest lost of its volume) in normal aging was shown by some authors (Coffey et al., 1992; DeCarli et al., 1994).

The lack of age related changes in temporopolar, perirhinal and entorhinal cortices was reported by Juottonen et al. (Juottonen et al., 1998) in 30 subjects aged from 64 to 79. Two latter structures are included together in parahip-

pocampal gyrus, and the age of people from their control group placed them among our “older” subjects. However, we have found neither difference in the volume nor correlation with age within this “older” group.

Bhatia et al. (Bhatia et al., 1993) have found that in the group of healthy young adults aged 22-47 there was substantial loss of volume of the hippocampal formation (the correlation coefficient was about -0.5), but neither of the temporal lobe nor of the whole brain. Similar data concerning the lack of the effect of age on the volume of the whole temporal lobe were obtained by DeCarli et al. (DeCarli et al., 1994) on the group of 30 healthy volunteers with age ranged from 19 to 92 and by Jack et al. (Jack, Jr. et al., 1989) on the group of 52 subjects.

In our study the effect of age could be expressed as about 9% of atrophy of the hippocampal formation and only in the right hemisphere, but we have studied only the head of the hippocampus – its largest subdivision.

Constant rate of both the hippocampal and parahippocampal volumetric loss with age was almost identical in the group of subjects aged above 84 (Kaye et al., 1997). Jack et al. (Jack, Jr. et al., 1997) divided arbitrarily the hippocampus into three parts – head, body and tail; the most significant decline with age was present in the hippocampal head. We have observed significant correlation of the normalized volume of the hippocampal formation for younger individuals and for pooled control group both on the right and left side of the brain, but we have not observed the significant influence of age on the volume of this structure in older group (age > 50). Interestingly, the material of Jack et al. consisted of elderly population with age range between 51-89 so it was close to the age of cases studied by us (50 – 84). The only difference is that we excluded from our study any cases with other medical conditions even if there had been lack of symptoms of the disturbances in the functioning of the central nervous system, such as heart disease, diabetes, and hypertension. From the literature, we could find that some of these conditions could significantly influence the volume of loss of structures of the temporal lobe.

The same authors (Jack, Jr. et al., 1992; Jack, Jr. et al., 1997) in other control cases found significant correlation of age and hippocampus, parahippocampal gyrus and amygdaloid body. This is consistent with the previous results of other authors (Gur et al., 1991; Coffey et al., 1992). However, the definition of the anterior border of the amygdaloid body as a level first appearing in the hippocampal head does not meet both our criteria and neuroradiological criteria used by others.

Coffey et al. (Coffey et al., 1992) has found the significant effect of age on the cerebral

atrophy for the amygdala-hippocampal complex and for the temporal lobe. However they have used only four 5-mm-thick consecutive MRI scans through this complex, what probably, has given them the large variation of the volume of this complex. The only explanation for this approach seemed to be a large amount of studied cases (76 volunteers aged from 30 to 91) according to the Gundersen's sentence “Do more, less well” (Gundersen and Osterby, 1981).

No significant changes related to age were observed for the hippocampal formation by Jack et al. (Jack, Jr. et al., 1989) in right or left hemispheres (52 healthy volunteers) as well as by Laakso et al. (Laakso et al., 1998). They found no differences between age groups (younger group included subjects aged 21-43, older – 64 – 79) in the normalized volume of the hippocampal formation. Additionally, there was no correlation of age and the volume of the hippocampal formation. Cook et al. (Cook et al., 1992) observed no hippocampal volume difference in the group of ten normal volunteers, but they used for their study 10 healthy volunteers aged 21 – 36. As a consequence we can treat them only as a subgroup of our younger group with no volumetric changes of the hippocampal formation.

In our older group, taken separately, there was no effect of age on the volume of hippocampus both on the left and right hemispheres. Similarly to our results Laakso et al. (Laakso et al., 1995b) have found no correlation of the volume of the amygdala, hippocampus and frontal lobe with age in his study of 16 control cases aged 70 ± 5 . Additionally, the raw and normalized amygdaloid volumes strongly correlated negatively with age in his younger group of patients (<50). However, this correlation seemed to be highly significant probably due to low volumes of amygdala for three control cases with age ranged from 38 to 50. They did not report any correlation between the volume of amygdala and age for control group matched with AD group of patients. However, they reported significant correlation for pooled older and AAMI (age associated memory impairment) groups.

Soininen et al. (Soininen et al., 1994) reported the lack of correlation of the volume of either amygdala or hippocampal formation with age in the subjects with mean age 70 ± 4 . It is consistent with our observations concerning group of our volunteers with age above 50.

No significant influence of age on the volume of the amygdala was found by Cuenod et al. (Cuenod et al., 1993) in the control group ($r=0,07$), but they had only six subjects with average age 69 ± 9 . Herzog and Kemper (Herzog and Kemper, 1980) obtained similar results, they also studied not large groups of cases.

Not all authors used the volumetric approach for the study of age- and/or disease-related changes of the temporal lobe structures. Such type of evaluation was done by Jobst et al. (Jobst et al., 1992). They measured the thickness of the temporal lobe in the specific plane showing that logarithm of this parameter correlated negatively with age (atrophy). Another approach was used by Laakso et al. (Laakso et al., 1995). They assumed that reliable method for the evaluation of the volume of the hippocampus was the interuncal distance measured on single MR scan, finding that younger subjects reached significantly smaller values of this parameter. However, interestingly, the cut off point for AD subjects, proposed as 30 mm interuncal distance, exceeded this value in 5% of younger controls (with average age 29 ± 8) and in 22% of older ones (with mean age 71 ± 4).

MRI volumetry – the indirect assessment method of the status of the brain structures – being correlated with neuropathological changes (presence of neurofibrillary pathology) and neuronal density, and done unbiasedly with the suitable level of precision can be a strong diagnostic tool for distinguishing the aging and dementia changes in the central nervous system.

ACKNOWLEDGEMENTS

The authors wish to thank Ms Sylwia Scisłowska, MA for preparation of illustrations and Mrs. Aleksandra Arceusz, MA from the Institute of Foreign Languages in Elbląg, for checking the manuscript. The research was supported by funds from State Committee of Scientific Research Grant No. 4.P05A.070.10

REFERENCES

- BHATIA S, BOOKHEIMER SY, GAILLARD WD and THEODORE WH (1993). Measurement of whole temporal lobe and hippocampus for MR volumetry: Normative data. *Neurology*, 43: 2006-2010.
- BILIR E, CRAVEN W, HUGG J, GILLIAM F, MARTIN R, FAUGHT E and KUZNIECKY R (1998). Volumetric MRI of the limbic system: anatomic determinations. *Neuroradiology*, 40: 138-144.
- BRADY DR and MUFSON EJ (1990). Amygdaloid pathology in Alzheimer's disease: Qualitative and quantitative analysis. *Dementia*, 1: 5-17.
- BUCHSBAUM MS and HAZLETT EA (1998). Positron emission tomography studies of abnormal glucose metabolism in schizophrenia. *Schizophr Bull*, 24: 343-364.
- COFFEY CE, WILKINSON WE, PARASHOS IA, SOADY SAR, SULLIVAN RJ, PATTERSON LJ, FIGIEL GS, WEBB MC, SPRITZER CE and DJANG WT (1992). Quantitative cerebral anatomy of the aging human brain: A cross-sectional study using magnetic resonance imaging. *Neurology*, 42: 527-536.
- COOK MJ, FISH DR, SHORVON SD, STRAUGHAN K and STEVENS JM (1992). Hippocampal volumetric and morphometric studies in frontal and temporal lobe epilepsy. *Brain*, 115: 1001-1015.
- CUENOD CA, DENYS A, MICHOT JL, JEHENSON P, FORETTE F, KAPLAN D, SYROTA A and BOLLER F (1993). Amygdala atrophy in Alzheimer's disease. An in vivo magnetic resonance imaging study. *Arch Neurol*, 50: 941-945.
- DECARLI C, MURPHY DGM, GILLETTE JA, HAXBY JV, TEICHBERG D, SCHAPIRO MB and HORWITZ B (1994). Lack of age-related differences in temporal lobe volume of very healthy adults. *AJNR Am J Neuroradiol*, 15: 689-696.
- DOUBLE KL, HALLIDAY GM, KRIL JJ, HARASTY JA, CULLEN K, BROOKS WS, CREASEY H and BROE GA (1996). Topography of brain atrophy during normal aging and Alzheimer's disease. *Neurobiol Aging*, 17: 513-521.
- FREE SL, BERGIN PS, FISH DR, COOK MJ, SHORVON SD and STEVENS JM (1995). Methods for normalization of hippocampal volumes measured with MR. *AJNR Am J Neuroradiol*, 16: 637-643.
- GEINISMAN Y, GUNDERSEN HJG, VAN DER ZEE E and WEST MJ (1996). Unbiased stereological estimation of the total number of synapses in a brain region. *J Neurocytol*, 25: 805-819.
- GUNDERSEN HJG and OSTERBY R (1981). Optimising sampling efficiency of stereological studies in biology: Or 'Do more less well!'. *J Microsc*, 121: 65-73.
- GUR RC, MOZLEY PD, RESNICK SM, GOTTLIEB GL, KOHN M, ZIMMERMAN R, HERMAN G, ATLAS S, GROSSMAN R and BERRETTA D (1991). Gender differences in age effect on brain atrophy measured by magnetic resonance imaging. *Proc Natl Acad Sci USA*, 88: 2845-2849.
- HERZOG AG and KEMPER TL (1980). Amygdaloid changes in aging and dementia. *Arch Neurol*, 37: 625-629.
- HOFMAN MA, FLIERS E, GOUDSMIT E and SWAAB DF (1988). Morphometric analysis of the suprachiasmatic and paraventricular nuclei in the human brain: sex differences and age-dependent changes. *J Anat*, 160: 127-143.
- HOROUPIAN DS and DICKSON DW (1991). Striatonigral degeneration, olivopontocerebellar atrophy and atypical: Pick disease. *Acta Neuropathol*, 81: 287-295.
- HUBBARD BM and ANDERSON JM (1981). A quantitative study of cerebral atrophy in old age and senile dementia. *J Neurol Sci*, 50: 135-145.
- JACK CR Jr, PETERSEN RC, OBRIEN PC and TANGALOS EG (1992). MR-based hippocampal volumetry in the diagnosis of Alzheimer's disease. *Neurology*, 42: 183-188.
- JACK CR Jr, PETERSEN RC, XU YC, WARING SC, O'BRIEN PC, TANGALOS EG, SMITH GE, IVNIK RJ and KOKMEN E (1997). Medial temporal atrophy on MRI in normal aging and very mild Alzheimer's disease. *Neurology*, 49: 786-794.
- JACK CR Jr, TWOMEY CK, ZINSMEISTER AR, SHARBROUGH FW, PETERSEN RC and CASCINO GD (1989). Anterior temporal lobes and hippocampal formations: normative volumetric measurements from MR images in young adults. *Radiology*, 172: 549-554.
- JOBST KA, SMITH AD, SZATMARI M, MOLYNEUX A, ESIRI ME, KING E, SMITH A, JASKOWSKI A, McDONALD B and WALD N (1992). Detection in life of confirmed Alzheimer's disease using a simple measurement of medial temporal lobe atrophy by computed tomography. *Lancet*, 340: 1179-1183.
- JUOTTONEN K, LAAKSO MP, INSAUSTI R, LEHTOVIRTA M, PITKANEN A, PARTANEN K and SOININEN H (1998). Volumes of the entorhinal and perirhinal cortices in Alzheimer's disease. *Neurobiol Aging*, 19: 15-22.

- KAYE JA, SWIHART T, HOWIESON D, DAME A, MOORE MM, KARNOS T, CAMICOLI R, BALL MJ, OKEN B and SEXTON G (1997). Volume loss of the hippocampus and temporal lobe in healthy elderly persons destined to develop dementia. *Neurology*, 48: 1297-1304.
- LAAKSO M, SOININEN H, PARTANEN K, HALLIKAINEN M, LEHTOVIRTA M, HÄNNINEN T, VAINIO P and RIEKKINEN PJ Sr (1995). The interuncal distance in Alzheimer disease and age-associated memory impairment. *AJNR Am J Neuroradiol*, 16: 727-734.
- LAAKSO MP, PARTANEN K, LEHTOVIRTA M, HALLIKAINEN M, HÄNNINEN T, VAINIO P, RIEKKINEN P Sr and SOININEN H (1995a). MRI of amygdala fails to diagnose early Alzheimer's disease. *Neuroreport*, 6: 2414-2418.
- LAAKSO MP, SOININEN H, PARTANEN K, HELKALA E-L, HARTIKAINEN P, VAINIO P, HALLIKAINEN M, HÄNNINEN T and RIEKKINEN PJ Sr (1995b). Volumes of hippocampus, amygdala and frontal lobes in the MRI-based diagnosis of early Alzheimer's disease: Correlation with memory functions. *J Neural Transm (P-D Sect)*, 9: 73-86.
- LAAKSO MP, SOININEN H, PARTANEN K, LEHTOVIRTA M, HALLIKAINEN M, HÄNNINEN T, HELKALA E-L, VAINIO P and RIEKKINEN PJ (1998). MRI of the hippocampus in Alzheimer's disease: Sensitivity, specificity, and analysis of the incorrectly classified subjects. *Neurobiol Aging*, 19: 23-31.
- LEHERICY S, BAULAC M, CHIRAS J, PIEROT L, MARTIN N, PILLON B, DEWEER B, DUBOIS B and MARSAULT C (1994). Amygdalohippocampal MR volume measurements in the early stages of Alzheimer disease. *Amer J Neuroradiol*, 15: 929-937.
- MILLER AKH, ALSTON RL and CORSELLIS JAN (1980). Variation with age in the volumes of grey and white matter in the cerebral hemispheres of man: measurements with an image analyser. *Neuropathol Appl Neurobiol*, 6: 119-132.
- MORI E, YONEDA Y, YAMASHITA H, HIRONO N, IKEDA M and YAMADORI A (1997). Medial temporal structures relate to memory impairment in Alzheimer's disease: an MRI volumetric study. *J Neurol Neurosurg Psychiatry*, 63: 214-221.
- SHENTON ME, KIKINIS R, JOLESZ FA, POLLAK SD, LEMAY M, WIBLE CG, HOKAMA H, MARTIN J, METCALF D, COLEMAN M and MCCARLEY RW (1992). Abnormalities of the left temporal lobe and thought disorder in schizophrenia. A quantitative magnetic resonance imaging study. *N Engl J Med*, 327: 604-612.
- SOININEN HS, PARTANEN K, PITKÄNEN A, VAINIO P, HÄNNINEN T, HALLIKAINEN M, KOIVISTO K and RIEKKINEN PJ Sr (1994). Volumetric MRI analysis of the amygdala and the hippocampus in subjects with age-associated memory impairment: Correlation to visual and verbal memory. *Neurology*, 44: 1660-1668.
- TIEN RD, FELSBERG GJ, FERRIS NJ and OSUMI AK (1993). The dementias: correlation of clinical features, pathophysiology, and neuroradiology. *AJR*, 161: 245-255.
- WATSON C, ANDERMANN F, GLOOR P, JONESGOTMAN M, PETERS T, EVANS A, OLIVIER A, MELANSON D and LEROUX G (1992). Anatomic basis of amygdaloid and hippocampal volume measurement by magnetic resonance imaging. *Neurology*, 42: 1743-1750.
- WEST MJ (1993). Regionally specific loss of neurons in the aging human hippocampus. *Neurobiol Aging*, 14: 287-293.
- WRIGHT EA and SPINK JM (1959). A study of the loss of nerve cells in the central nervous system in relation to age. *Gerontologia*, 3: 277-287.