

# New proposed classification of retromandibular vein root variants based on cadaver dissections and review of literature – Clinical implications

Sanjoy Sanyal, Sommy M. Joeaneke

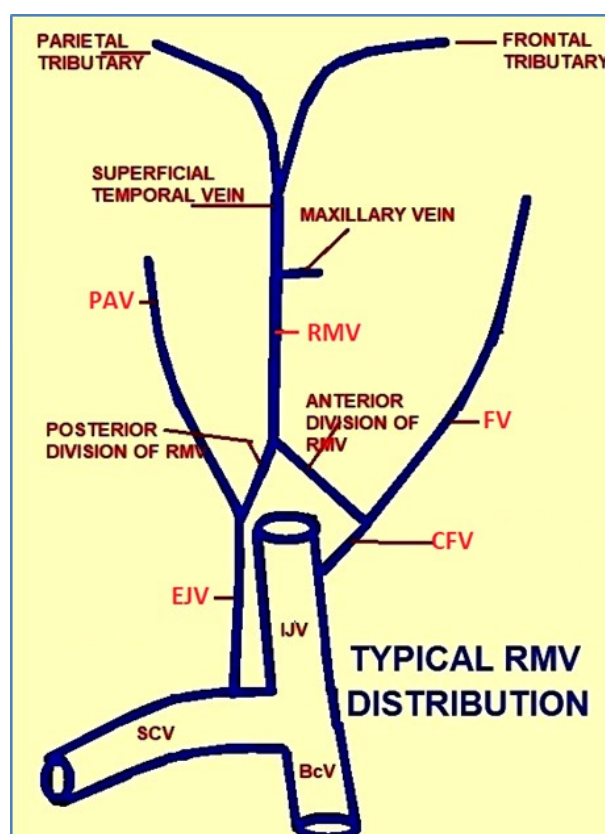
Department of Anatomical Sciences, All Saints University College of Medicine, Belair, St. Vincent and the Grenadines, West Indies

## SUMMARY

Typically the retro-mandibular vein contributes to formation of common facial and external jugular veins, via its anterior and posterior divisions respectively. However, cervico-facial venous variants are rather common. In two successive cadaver dissections the left side of head and neck were unviewable, but the right cervico-facial veins were visible. In both cadavers the right retro-mandibular vein was undivided. The first specimen had right external jugular vein draining into the right subclavian vein but did not have a right common facial vein. The second specimen did not have a right external jugular vein, but had a right common facial vein draining into the right internal jugular vein.

The first variant was characterized as Posterior Dominant Retromandibular Vein with no Common Facial Vein. The second variant was characterized as Anterior Dominant Retromandibular Vein with no External Jugular Vein. Each was sub-classified as Typical or Atypical based on its final drainage pattern. Cervico-facial venous variants often vary from case to case and side to side. Since external jugular and common facial veins are used for clinical and surgical interventions, accurate and structured preoperative classification of variations may preclude intra-operative surprises and consequent

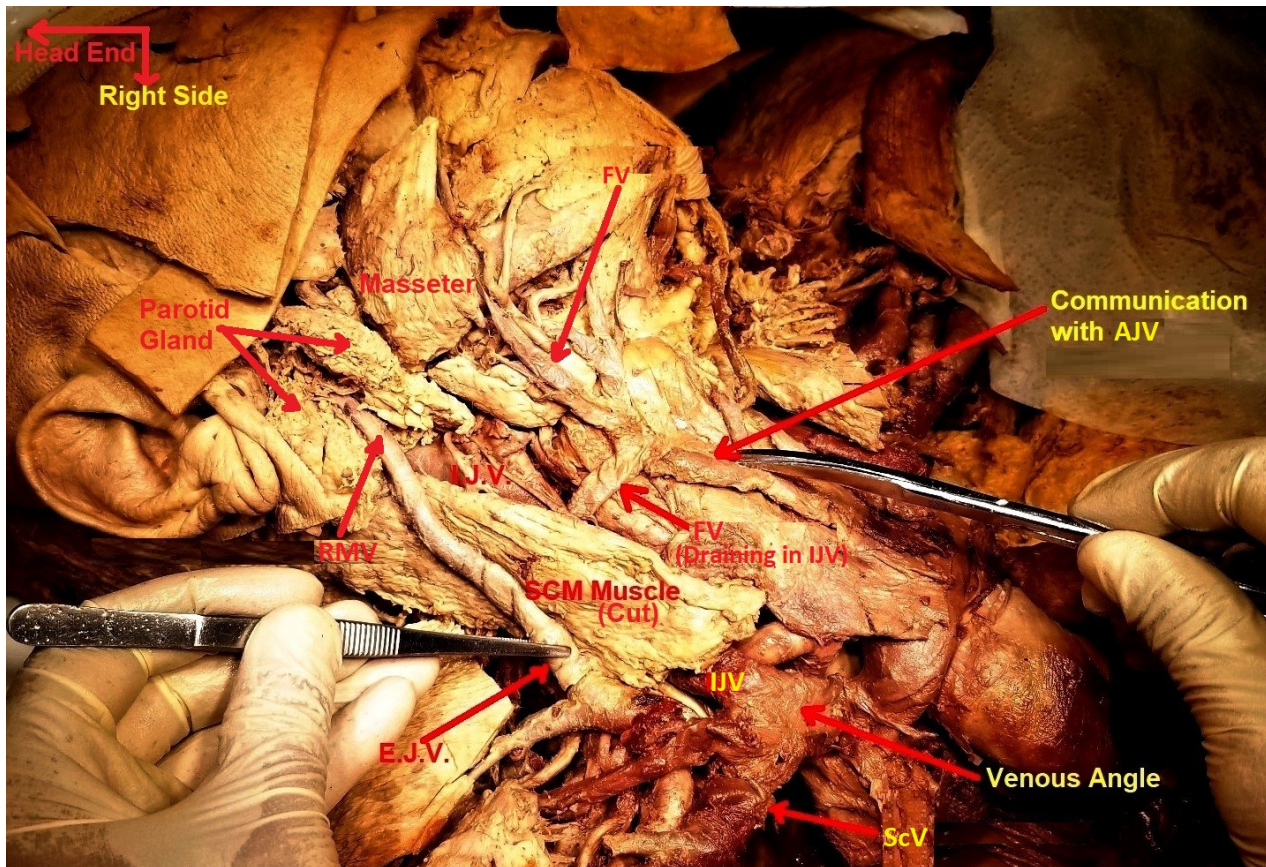
complications.



**Graphic 1.** Schematic representation of typical RMV formation, division, distribution and drainage. Site of union of ScV and IJV is called venous angle. BcV: Brachiocephalic Vein.

**Corresponding author:** Dr. Sanjoy Sanyal. Apartment 1 Ground Floor, Belair Middle Road, Opposite ASU Campus, St. George Parish, Belair, VC0282, St. Vincent and the Grenadines, West Indies. Phone: +1 784 593 4388 .  
E-mail: sanjoy.sanyal@bath.edu

Submitted: 7 July, 2019. Accepted: 10 December, 2019.



**Fig 1.** Dissection specimen of Caucasian female cadaver demonstrating undivided variant of RMV (Posterior Dominant) continuing over SCM muscle as EJV, held up in forceps by principle author, and draining into ScV near venous angle (Typical Drainage). FV did not receive any communication from RMV but it was receiving a communication from AJV (pointed by scissors) and was draining independently into IJV.

**Key words:** Retromandibular vein – External jugular vein – Common facial vein – Venous variants – Variant classification

## INTRODUCTION

Typically the retromandibular vein (RMV), after its formation inside the parotid gland, divides into anterior and posterior divisions. The anterior division unites with the facial vein (FV) to form the common facial vein (CFV), which drains into the internal jugular vein (IJV). The posterior division unites with the posterior auricular vein (PAV) to form the external jugular vein (EJV), which drains into the subclavian vein (ScV) near the venous angle (Graphic 1).

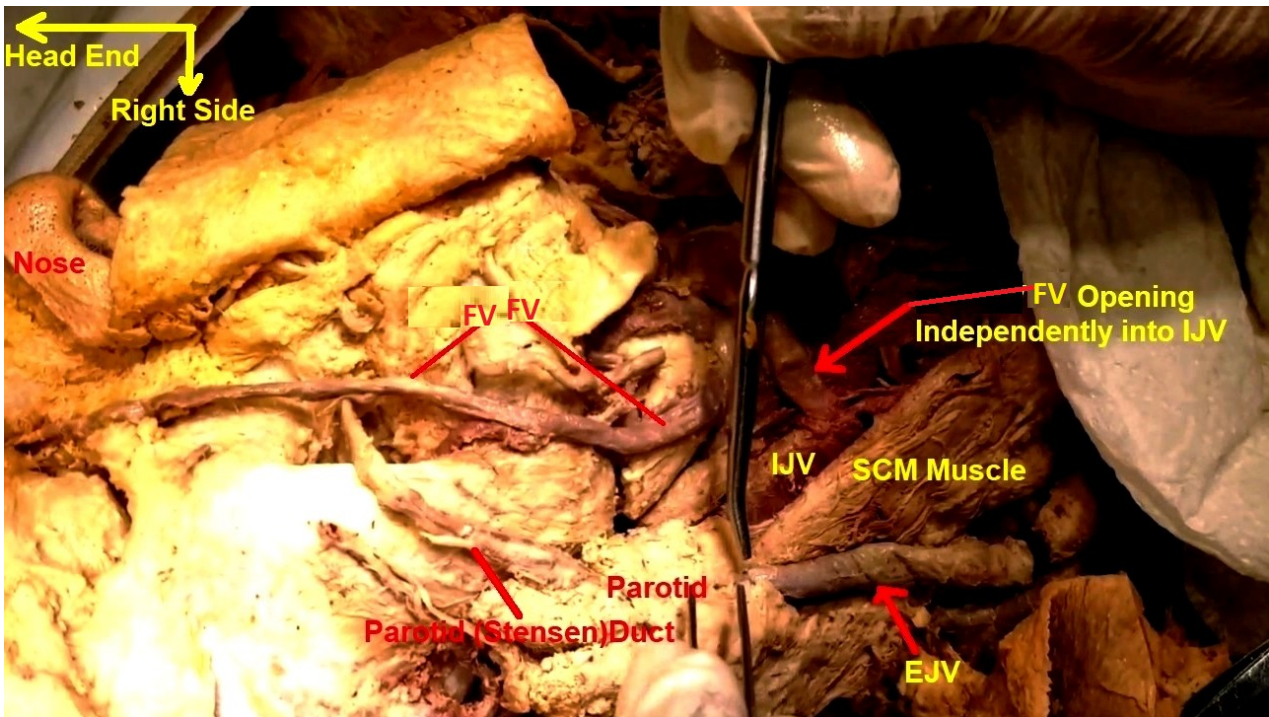
In successive cadaver dissections two instances of non-dividing, mutually opposing variants of RMV were described and anatomically characterized. Based on this classification, the clinical significance of such variants was discussed in the living human population.

## MATERIALS AND METHODS

Two successive cadavers were dissected by the

principle author assisted by an MD clinical research student in 2018, as part of surgical anatomy teaching in a Caribbean medical university. The first was an elderly female Caucasian cadaver. The second was an elderly male cadaver of Oriental extraction. In both cadavers, after reflecting the skin and platysma, the cervico-facial venous drainage patterns were meticulously studied on the right side of the neck. Variations from typical cervico-facial venous drainage patterns, if any, were specifically noted. Because of chemical preservation (embalming) through the right neck arteries, the necks of both cadavers were turned ninety degrees to the left and rigidly fixed in that position when they were received in the dissection lab. This precluded any exploration or conclusive observation of structures on the left side of necks of both cadavers.

Based on the venous drainage patterns observed, a focused literature search was conducted using search queries 'undivided RMV', 'absent EJV', and 'absent CFV'. From relevant results returned by the search engine, a review of literature during the last decade was performed. Finally, based on the findings of the current dissections and certain recurring commonality of variants elu-



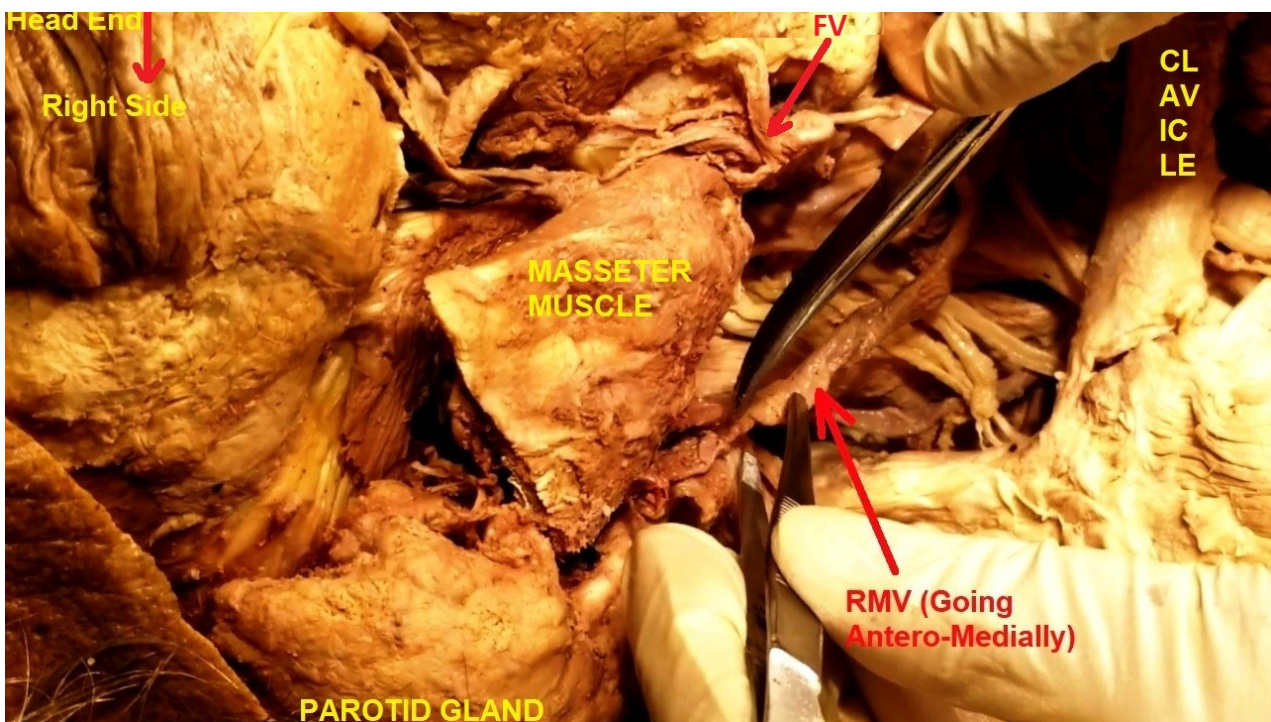
**Fig 2.** Enlarged view of dissection specimen demonstrating undivided variant of RMV (Posterior Dominant), pointed with scissors by principle author, which continued over SCM muscle as EJV. FV had no communication with RMV and was draining independently into IJV.

culated from the literature review, a clinical classification of RMV root variants was proposed.

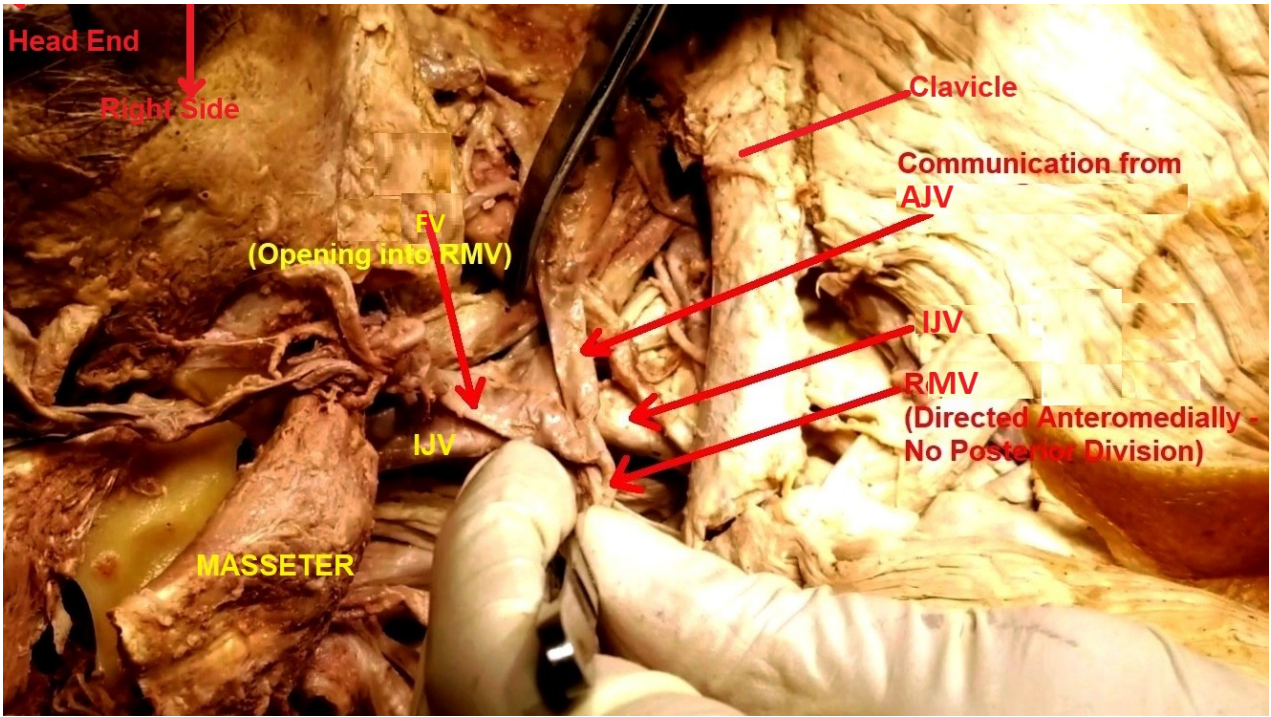
### RESULTS

The right RMV in the Caucasian female cadaver

was dilated and prominent. After its usual formation inside the parotid gland by the union of right maxillary and superficial temporal veins, it continued outside the gland but did not divide into anterior and posterior divisions. After receiving the right PAV from inside parotid gland, the whole right



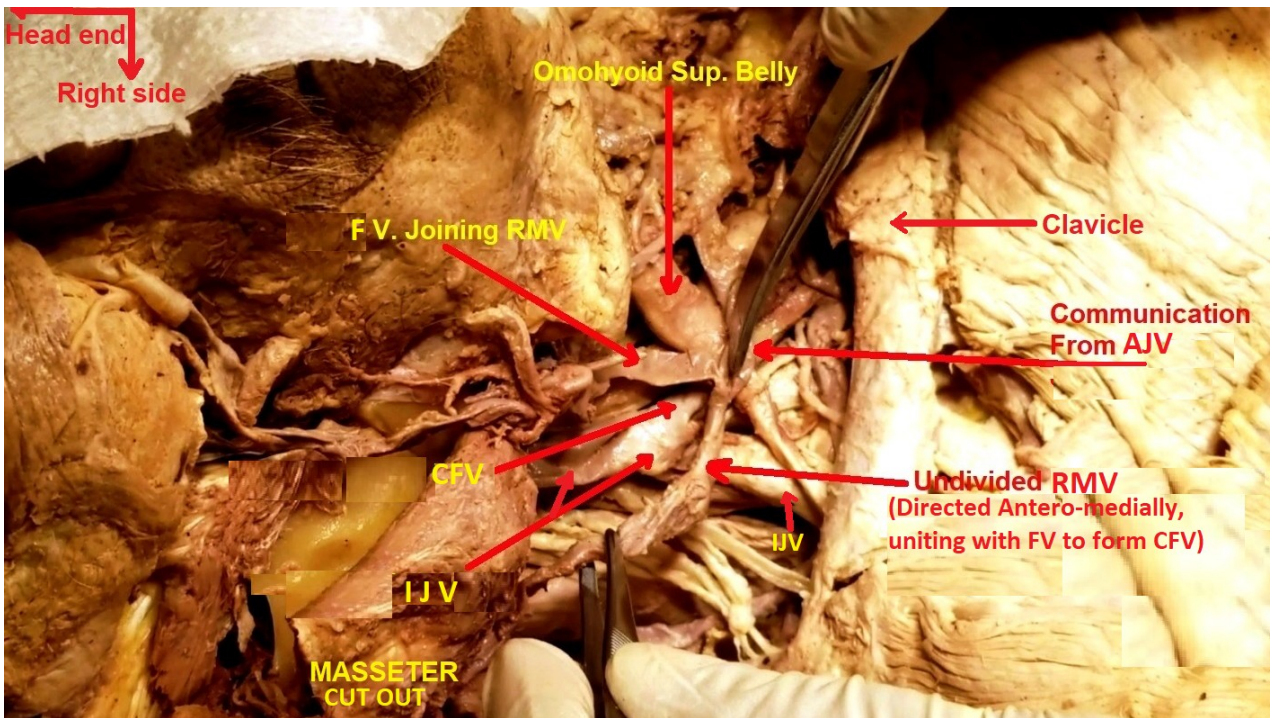
**Fig 3.** Dissection specimen of Oriental male cadaver demonstrating undivided variant of RMV, pointed with instrument held by principle author. It continued antero-medially (Anterior Dominant), after exiting from parotid gland. There was no EJV.



**Fig 4.** Dissection specimen, which is a continuation of that shown in Fig. 3, demonstrating undivided variant of RMV continuing antero-medially (Anterior Dominant), after exiting from parotid gland. It united with FV, which also received a communication from AJV. The IJV is in the center of the picture.

RMV continued laterally superficial to the sternocleidomastoid (SCM) muscle as the EJV. The latter pierced the investing layer of deep cervical fascia in the lateral cervical region and opened into the right ScV at right angles like any typical EJV

(Fig. 1). The fully formed right FV was also dilated and prominent in this specimen. After receiving its usual complement of tributaries in the face, it continued below the lower border of the body of the mandible and drained directly into the right IJV



**Fig 5.** Dissection specimen, which is a continuation of that shown in Fig. 4, demonstrating undivided variant of RMV continuing antero-medially (Anterior Dominant), after exiting from parotid gland. It united with FV to form CFV, which drained into IJV (Typical Drainage). CFV also received a communication from AJV.

deep to the anterior border of SCM without receiving any communication from the RMV. Thus, a true CFV was not formed. The usual right FV did receive a communication from the right anterior jugular vein (AJV) in the anterior cervical region (Fig. 2).

The right RMV in the Oriental male cadaver was not dilated. After its usual formation inside the parotid gland by the union of right maxillary and superficial temporal veins, it also did not divide into anterior and posterior divisions outside the parotid gland. After receiving the right PAV from inside the parotid gland the whole right RMV continued antero-medially into the anterior cervical region and united with the right FV to form the right CFV. The latter drained into the right IJV deep to the anterior border of SCM muscle. The CFV did receive a communication from right AJV in the anterior cervical region (Figs. 3-5). There was no right EJV superficial to the SCM. In the absence of the EJV, its three usual tributaries, namely transverse cervical, suprascapular and AJV drained independently into the right ScV near the venous angle. No observations were possible on left side of necks of both cadavers (Figs. 1-5).

## DISCUSSION

The literature is rife with reports of anomalous venous drainage of face and neck, especially the RMV, EJV and CFV (Hollinshed, 1968; Chauhan

et al., 2011). Veins of the head and neck begin to develop after the formation of the fetal skull. The adult pattern of venous drainage eventually results from regression of some and persistence of other venous channels (Shankar et al., 2012; Bertha and Rabi; 2011). Therefore, aberrant embryological evolution of these fetal venous channels is likely to result in variant cervico-facial venous architecture (Bertha and Rabi; 2011).

## REVIEW OF LITERATURE

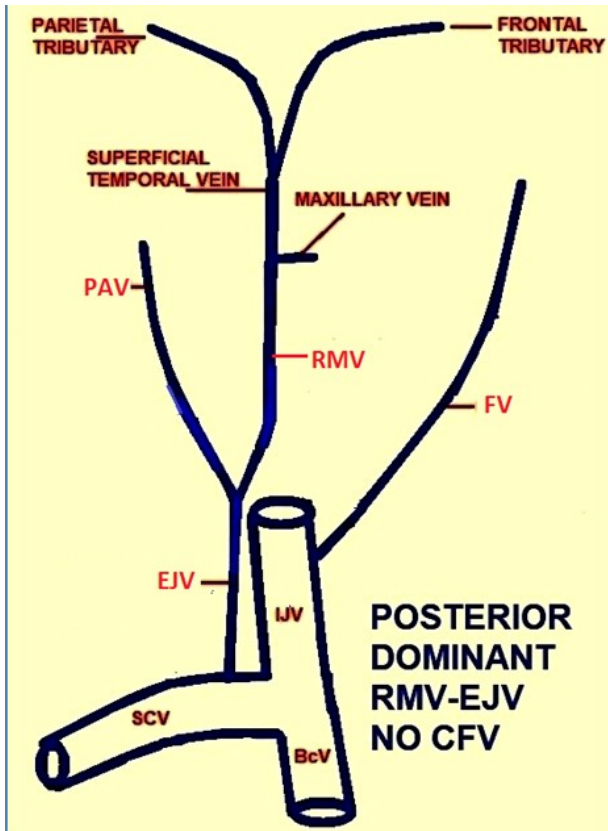
Review of literature in the last decade on undivided RMV, involving 12 sides in 10 cases revealed a pattern, which was substantiated by findings in the current dissections. When the EJV was present, the CFV was absent and vice versa (Table 1). For the purpose of this discussion, CFV was defined as that formed by the union of anterior division of RMV with FV.

### *Undivided retromandibular vein*

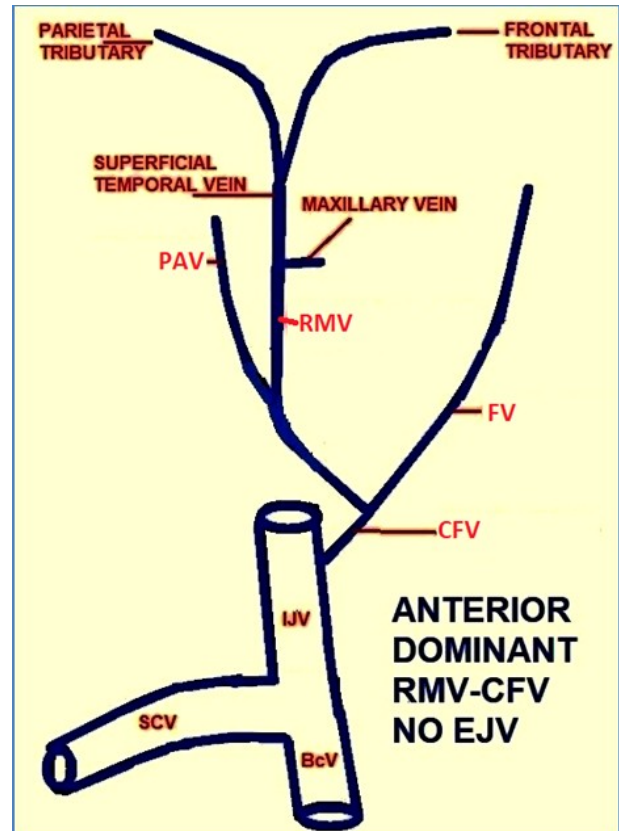
Undivided RMV is not too uncommon among all cervico-facial venous variants, the incidence being 17% in one study (Bertha and Rabi; 2011). The undivided RMV may either travel postero-laterally over the SCM muscle to the lateral cervical region or antero-medially to the anterior cervical region. Often the PAV drains into the undivided RMV, but not invariably so (Sharma and Yadav, 2018). The subsequent drainage of the undivided RMV is typi-

**Tab 1.** Review of literature

Table 1: Review of literature						
Authors	RMV	EJV	CFV	FV	PAV	Comments
<b>Gupta N</b>	Undivided	Present Drained into SCV	Absent	Joined RMV; Continued as EJV; Did not drain into IJV	Joined RMV	1 case; Clinicals plenty
<b>Sharma V</b>	Undivided	Absent	Present (Not mentioned but described, after joining RMV); Drained into IJV	Joined with lingual vein to form Linguo-Facial trunk; Joined RMV	Absent	1 case; Clinicals some
	6 / 35 abnormal; Clinicals plenty					
	Undivided both sides	Absent both sides	Present both sides Drained into ScV both sides	FV joined RMV both sides	Not mentioned	1 case both sides
<b>Bertha A</b>	Undivided	Present	Present (but not with RMV); Opened in IJV	Received submental vein to form CFV	Not mentioned	1 case right side
			6 drained into EJV; 1 drained into IJV			6 cases 7 sides
<b>Chaudhury S</b>	Undivided both sides	Present both sides	Absent both sides	Drained into EJV both sides	Drained into EJV both sides	1 case both sides
<b>Abhinitha P</b>	Divided	Absent; Post. Div. joined IJV without forming EJV	Present (FV + Ant. Div. of RMV); Drained into AJV	FV joined Anterior Division of RMV to form CFV	Not mentioned	1 case left side; Clinicals plenty



**Graphic 2.** Schematic representation of variant undivided Posterior Dominant RMV uniting with PAV to form EJV, which drains into ScV as a Typical Drainage. The FV drains independently into IJV. There is no true CFV in this variant.



**Graphic 3.** Schematic representation of variant undivided Anterior Dominant RMV uniting with FV to form CFV, which drains into IJV as a Typical Drainage. There is no EJV in this variant.

cally to the ScV. However, there can be several variations of the final drainage (Bertha and Rabi; 2011; Gupta et al., 2013; Abhinitha et al., 2013; Sharma and Yadav, 2018), which does not have any bearing on the original course of the undivided root RMV.

In the Caucasian female cadaver and in the last-decade literature the posterior course of the undivided RMV took it superficial to SCM muscle into the lateral cervical region where it pierced the investing deep cervical fascia and drained into the ScV. It usually received the PAV. It did not have any communication with the FV; so a classical CFV was not formed (Graphic 2). The posterior course of the undivided RMV, in effect, matched the course of the posterior division of a typical RMV and that of a typical EJV, as shown in Graphic 1.

In the Oriental male cadaver and in the literature the anterior course of the undivided RMV took it into the anterior cervical region. Here it united with the FV to form the CFV, which then drained into the IJV deep to the anterior border of SCM muscle. Such cases did not have any EJV (Graphic 3). The anterior course of the undivided RMV, in effect, matched the course of the anterior division of a typical RMV and that of a typical CFV, as shown in Graphic 1.

#### **Absent external jugular vein**

Presence or absence of the EJV is closely linked to the course of the undivided root RMV. Generally, if the course of the undivided RMV is antero-medial toward the anterior cervical region, the EJV is likely to be absent. If the course of the undivided root RMV is postero-lateral toward the lateral cervical region, it becomes the EJV. Its final drainage is typically to the ScV. However, there can be several variations of the final drainage (Nayak and Soumya, 2008; Bertha and Rabi; 2011; Choudhary et al., 2010; Gupta et al., 2013; Abhinitha et al., 2013; Sharma and Yadav, 2018).

#### **Absent common facial vein**

Presence or absence of the CFV is also closely linked to the course of the undivided root RMV. Generally, if the course of the undivided RMV is antero-medial toward the anterior cervical region, the CFV is likely to be present. Its final drainage is typically to the IJV. However, there can be several variations of the final drainage. If the course of the undivided root RMV is postero-lateral toward the lateral cervical region, the CFV is likely to be absent (Nayak and Soumya, 2008; Bertha and Rabi; 2011; Choudhary et al., 2010; Gupta et al., 2013; Abhinitha et al., 2013; Sharma and Yadav, 2018).

## CLASSIFICATION OF ROOT RMV VARIANTS

Based on a review of literature on RMV, EJV and CFV variants, substantiated by findings in the current dissections, a classification of cervico-facial venous variants was proposed that characterized the course of an undivided root RMV. This classification is meant to serve as a basis for pre-operatively delineating cervico-facial venous variants, which will guide the surgeon and clinician during their interventional and surgical procedures.

In the Caucasian female cadaver the whole right RMV formed the right EJV. The right CFV was not formed. This was therefore characterized as Posterior Dominant RMV with no CFV. In the Oriental male cadaver the whole right RMV formed the right CFV. Though the literature alluded to the CFV being formed by union of submental or AJV with FV (Bertha and Rabi, 2011), only the union of anterior division of RMV with FV forming the CFV was considered in the present discussion. The right EJV was not formed in this cadaver. This was therefore characterized as Anterior Dominant RMV with no EJV. Drainage of EJV and CFV into the ScV and IJV respectively was characterized as Typical. Any other drainage pattern was characterized as Atypical (Graphic 4 / Table 2).

## CLINICAL APPLICATIONS OF CERVICO-FACIAL VEINS

Following neck cancer excision, reconstructive surgeons use myocutaneous SCM and platysma flaps that depend on cervico-facial venous microvascular anastomosis. En-bloc resection of metastatic cervical lymph nodes entails selective sacrifice of cervico-facial veins. They are also used in biocompatibility studies of synthetic prostheses

prior to their in-vivo application. Prominent neck veins in cardiac failure and thoracic inlet syndromes are of paramount diagnostic importance (Baumgartner and Bollinger, 1991; Sabharwal and Mukerjee, 1998; Nayak and Soumya, 2008; Choudhary et al., 2010; Gupta et al., 2013; Abhinitha et al., 2013).

### Retromandibular vein

The location of RMV in facio-venous plane of Patey medial to facial nerve inside the parotid gland serves as a useful landmark to safeguard the facial nerve during superficial parotidectomy. The RMV and its principle tributary, the superficial temporal vein, also serve as landmarks to expose the facial nerve in the parotid gland during open reductions of mandibular condyle fractures (Kawakami et al., 1994; Kopuz et al., 1995; Shankar et al., 2012; Gupta et al., 2013).

### External jugular and common facial veins

Absence of EJV superficial to SCM muscle may potentially protect a person from air embolism following a laceration in the lateral cervical region. However, absence of EJV also eliminates a possible superficial venipuncture site in a patient with thrombosed peripheral veins requiring intravenous infusion (Moore et al., 2017). The EJV and CFV are cannulated for diagnostic and therapeutic purposes, which includes but are not limited to, measurement of central venous and right atrial pressures, intravenous fluid and drugs administration and hyper-alimentation (Zumbro et al., 1973; Chauhan et al., 2011; Bertha and Rabi, 2011; Gupta et al., 2013; Abhinitha et al., 2013). Other specialized uses of EJV and CFV include permanent cannulation for hemodialysis access (Gupta et al., 2013), recipient for vascularized pedicle flaps in

Table 2. New proposed classification of root RMV variants\*

TABLE 2: New proposed classification of root RMV variants*			
RMV characterization	Divisions of RMV	EJV	CFV
Typical root RMV	Divisions <u>present</u> <b>Anterior Division:</b> Unites with FV to form CFV <b>Posterior Division:</b> Unites with PAV to form EJV	EJV present Drains into ScV***	CFV present Drains into IJV***
	<u>NO</u> Division PAV drains into RMV, but may drain elsewhere		
Variant root RMV	<b>**Posterior dominant:</b> Whole RMV goes toward posterior triangle of neck superficial to SCM muscle as EJV	<b>Typical:</b> EJV present Drains into ScV <b>Atypical:</b> Drains elsewhere	<b>Typical:</b> CFV <u>ABSENT</u> Original FV drains into IJV <b>Atypical:</b> Drains elsewhere
	<b>**Anterior dominant:</b> Whole RMV goes toward anterior triangle of neck and forms CFV	<b>Typical</b> EJV <u>ABSENT</u> <b>Atypical:</b> Other variation(s)	<b>Typical</b> CFV present Drains into IJV <b>Atypical:</b> Drains elsewhere

\*This characterization of variant root RMV is proposed for adoption in clinical practice

\*\*Anterior / Posterior dominance of undivided root RMV is the linchpin of the classification because of its clinical significance

\*\*\*This is Typical drainage

reconstructive surgery (Sabharwal and Mukerjee, 1998; Nayak and Soumya, 2008; Gupta et al., 2013), ventriculo-jugular shunting in hydrocephalus (Gogolev, 1993; Bertha and Rabi, 2011; Gupta et al., 2013), route for trans-jugular liver biopsy (Siegel et al., 1992), and trans-jugular intrahepatic porta-systemic shunt in portal hypertension (Siegel et al., 1992; Bertha and Rabi, 2011; Gupta et al., 2013). Both EJV and CFV are used as autogenous patch or conduit for carotid angioplasty following carotid endarterectomy in stenosis (Sabharwal and Mukerjee, 1998; Nayak and Soumya, 2008; Bertha and Rabi, 2011; Gupta et al., 2013). CFV drains into IJV just above bifurcation of common carotid artery. This serves as an important landmark for carotid exploration. Since it is visible at the carotid exposure site it can be easily harvested through the same incision and at the same time as the carotid angioplasty (Abeysekera et al., 2008).

**CLINICAL IMPLICATION OF PROPOSED NEW CLASSIFICATION**

Any malformation, absence or altered disposition of the superficial cervico-facial veins and their tributaries must be considered before planning any invasive procedure. Clinical appraisal of cervico-facial veins and Doppler probes are inaccurate. Accurate preoperative evaluation entails color Doppler ultrasonography (Nagase et al., 1997; Gupta et al., 2013). Ultrasound-guided venipuncture is a viable option in cases of variations in the patterns of superficial cervical veins (Gupta et al., 2013). Acquaintance of such variations also avoids misidentification and misinterpretation of the cervico-facial veins during contrast angiography

(Chauan et al., 2011; Gupta et al., 2013; Abhinitha et al., 2013).

If preoperative color Doppler ultrasonography indicates Posterior Dominant RMV with Typical EJV drainage, then interventions involving EJV will be favored. Conversely, if the preoperative evaluation determines Anterior Dominant RMV with Typical CFV drainage, then approaches involving CFV are favored (Table 2 / Graphic 4).

**CONCLUSION**

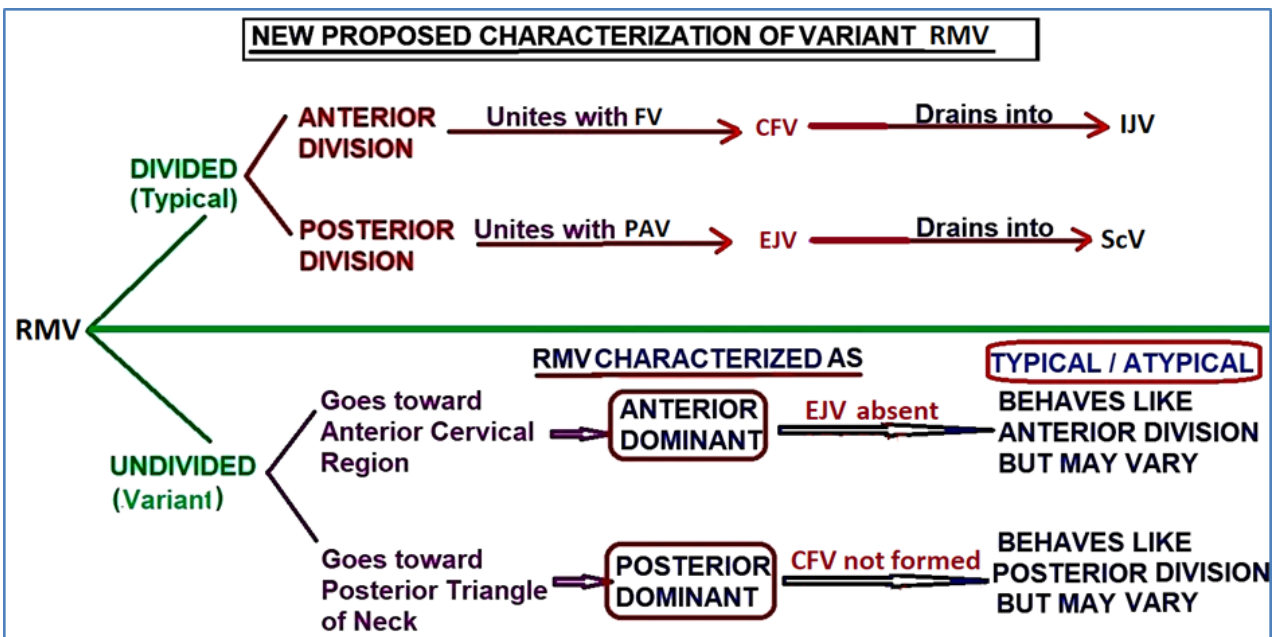
An undivided root RMV may follow a Posterior Dominant pattern, culminating in an EJV and absent CFV, with either Typical or Atypical drainage. Or, an undivided root RMV may follow an Anterior Dominant pattern, culminating in a CFV and absent EJV, with either Typical or Atypical drainage. Prior color Doppler ultrasonography must be employed to characterize the cervico-facial venous pattern. This will forewarn the vascular interventionist or surgeon as to the appropriate vessel to select for the procedure, without unpleasant intra-operative surprises and possible complications to the patient.

**ACKNOWLEDGEMENTS**

Permission to use the cadaver lab of All Saints University College of Medicine, St. Vincent and the Grenadines is gratefully acknowledged.

**REFERENCES**

ABEYSEKARA AM, SIRIWARDANA HP, PRABAHARAN B, TIWARI A, MADIPOLAGEDARA N, JACOB



**Graphic 4.** In the new proposed classification, an undivided root RMV variant may be characterized as Anterior or Posterior Dominant, depending on its direction of flow and whether EJV / CFV is present or not. Each is sub-characterized as Typical or Atypical, depending on whether its final drainage corresponds to a typical RMV.



- S (2008) Common facial vein: an alternative patch material in carotid angioplasty. *ANZ J Surg*, 78(3): 185-188.
- ABHINITHA P, RAO MKG, KUMAR N, NAYAK SB, RAVINDRA SS, AITHAL PA (2013) Absence of the external jugular vein and an abnormal drainage pattern in the veins of the neck. *OA Anat*, 1(2): 15.
- BAUMGARTNER I, BOLLINGER A (1991) Diagnostic importance of the jugular veins. *VASA. Zeitschrift fur Gefasskrankheiten*, 20(1): 3-9.
- BERTHA A, RABI S (2011) The anatomical variations in the termination of the common facial vein. *J Clin Diag Res*, 5(1): 24-27.
- CHAUHAN NK, RANI A, CHOPRA J, RANI A, SRIVASTAVA AK, VIJAY K (2011) Anomalous formation of external jugular vein and its clinical implication. *Natl J Maxillofac Surg*, 2(1): 51-53.
- CHOUDHARY S, SHARMA AK, SINGH H (2010) The undivided retromandibular vein continuing as the external jugular vein with the facial vein draining into it: An anatomical variation. *J K Sci*, 12(4): 203-204.
- GOGOLEV MP (1993) The treatment of hydrocephalus by ventriculojugular shunting. *Zh Vopr Neurokhir Im N N Burdenko*, (3) 24-26.
- GUPTA N, JAIN P, ANSHU A (2013) An undivided retromandibular vein receiving facial and posterior auricular vein: Case report and clinical repercussion. *Ind J Basic Appl Med Res*, 2(7): 710-715.
- HOLLINSHED WH (1968) *Anatomy for surgeons – The Head and Neck*. Harper and Row, New York.
- KAWAKAMI S, TSUKADA S, TANIGUCHI W (1994) The superficial temporal and the retromandibular veins as guides for exposing the facial nerve branches. *Ann Plast Surg*, 32(2): 295-299.
- KOPUZ C, LLGI S, YAVUZ S, ONDEROGLU S (1995a) Morphology of the retromandibular vein in relation to the facial nerve in the parotid gland. *Acta Anatomica (Basel)*, 152(1): 66-68.
- MOORE KL, DALLEY AF, AGUR AMR, (eds) (2017) *Clinically Oriented Anatomy*. Lippincott Williams Wilkins, Philadelphia.
- NAGASE T, KOBOYASHI S, SEKIYA S, OHMORI K (1997) Anatomical evaluation of the facial artery and vein using color Doppler ultrasonography. *Ann Plast Surg*, 39(1): 64-67.
- NAYAK SB, SOUMYA KV (2008) Abnormal formation and communication of external jugular vein. *Int J Anat Var*, 1: 15-16.
- SABHARWAL P, MUKERJEE D (1998) The autogenous common facial vein or an external jugular vein patch for carotid endarterectomy. *Cardiovasc Surg*, 6(6): 594-597.
- SHANKAR VD, CHANDRASHEKAR D, CHOWDAPURKAR S (2012) Bilateral anatomical variations in the formation, communication and the termination of the retromandibular vein. *J Clin Diag Res*, 6(7): 1286-1288.
- SHARMA V, YADAV S (2018) Undivided retromandibular vein and absent external jugular vein - a case report. *Ind J Res*, 7(1).
- SIEGEL EA, CARESIO J, ECKARD DA (1992) Use of the external jugular vein approach for transvenous liver biopsy. *J Vasc Interventional Radiol*, 3: 371-374.
- ZUMBRO GL JR, MULLIN MJ, NELSON TG (1973) Central venous catheter placement utilizing common facial vein. A technic useful in hyperalimentation and venous pressure monitoring. *Am J Surg*, 125(5): 654-656.