

Analysis of the therapeutic role of platelet-rich plasma against cisplatin-induced hepatotoxicity in rats: controversy between oxidative and apoptotic markers

Soheir H. El-Sharouny¹, Ayman A. El Enein Rizk^{1,2}, Laila A. Rashed¹, Walaa M. Sayed¹, Mohammed D.-A. Abd Elmoneam¹

¹Anatomy Department, Faculty of Medicine, Cairo University, Egypt, ²Anatomy Department, Faculty of Medicine (Rabigh), King Abdul-Aziz University (KAU), Saudi Arabia

SUMMARY

Cisplatin is a potent chemotherapeutic agent used to treat a variety of cancers such as ovarian, uterine, and bladder. The major limiting side effect of cisplatin is its hepatotoxicity. The possible mechanism of cisplatin hepatotoxicity was due to the affection of oxidant-antioxidant system. Platelet-rich plasma (PRP) has a powerful therapeutic option for its ability to deliver a great variety of biologically active GFs to the site of injury. PRP has grown as an attractive biologic instrument in regenerative medicine for its powerful healing properties. It is considered as a source of growth factors that may induce tissue repairing and improve fibrosis. This product has proven its efficacy in multiple studies, but its effect on cisplatin-induced hepatotoxicity has not yet been elucidated. The present study was designed to analyze the therapeutic role of PRP in cisplatin-induced hepatotoxicity. 30 adult male albino rats were used in the present study divided into 3 groups (control group, cisplatin-treated group and PRP-treated group). By the end of the experimental period, blood samples were collected for measurement of serum AST, ALT and ALP enzymes; then the rats were sacrificed by cervical dislocation.

Fresh liver parts were used to measure the oxidative markers in liver homogenates, while other parts were processed and subjected for histopathological and histomorphometric and immunohistochemical analyses for VEGF, Caspase 3 expression of the different experimental groups. The statistical study was done for the resultant data. Group II (Cisplatin-treated group) showed marked pathological hepatic changes; loss of architecture, congested dilated sinusoids lined by darkly stained pyknotic Kupffer cells; and hepatocytes nuclei were pyknotic and karyolytic. Dilated congested portal vein, interstitial acidophilic exudate, marked polymorphic cellular infiltration. There were increased collagen fibers deposition, a weak positive PAS reaction, strong positive caspase 3 reactions and strong positive VEGF reaction. Also, there were a marked increase in hepatic enzymes, MDA levels and a marked decrease in GSH level. Treatment with PRP in Group III revealed improvement of the hepatic parenchymal architecture with strong PAS reaction and minimal collagen fibers deposition. Weak positive caspase immunoreaction and strong positive VEGF reaction were noticed. Also, there was a marked improvement in the parameter of hepatic enzymes, MDA and GSH level comparable with the control group. It is concluded that PRP could ameliorate the liver against cisplatin-induced hepatotoxicity.

Corresponding author: Dr. Ayman Abo El Enein Rizk. Anatomy Department, Faculty of Medicine (in Rabigh), King Abdul-Aziz University (KAU), Saudi Arabia. - Faculty of Medicine, Cairo University, Egypt. Mob: +20 01005157798. E-mail: ayman.aboelenien@kasralainy.edu.eg

Key words: Cisplatin – Liver – PRP – Oxidative markers – Caspase 3 – VEGF

Submitted: 3 March, 2019. *Accepted:* 26 March, 2019.

INTRODUCTION

The Liver is the key organ in the metabolism, detoxification, and secretory functions in the body. Its disorders are numerous with no effective remedies; however, the search for new medicines is still ongoing. It is a hemopoietic organ in the fetal period, and mature hepatocytes produce thrombopoietin, which can stimulate platelet production in bone marrow (Hoshi et al., 2007).

Cisplatin is a chemotherapeutic drug (Elwell et al., 2006). Despite its excellent anticancer activity, the clinical use of cisplatin is often limited by its undesirable severe toxic side effects that interfere with its therapeutic efficacy (Ajani, 2008). Extensive investigations had been conducted in cisplatin hepatotoxicity, as it interferes with the tissue antioxidant defense system and generates highly reactive oxygen species (ROS), which can cause oxidative damage to the liver (Ko et al., 2014).

Lipid peroxidation (LPO) was crucial in the pathogenesis of cisplatin-induced organ injury (Mora et al., 2003). Nitric oxide, with high spontaneous chemical reactivities, could react with superoxide to generate peroxynitrite, which had been suggested as the main source of hydroxyl radical in many pathological conditions (Akyol et al., 2002; Obata, 2003). Cisplatin caused the generation of oxygen free radicals, such as hydrogen peroxide (H₂O₂), (O₂⁻) and hydroxyl radical, which abstracted a hydrogen atom from polyunsaturated fatty acids in membrane lipids to initiate LPO (Kadikoylu et al., 2004; Lu and Arthur, 2006).

Oxidative stress was one of the most important mechanisms involved in cisplatin-induced hepatotoxicity, which was secondary to the formation of both nitrogen and reactive oxygen species (ROS) by the mitochondria. Subsequently, there were loss of mitochondrial protein-SH, inhibition of calcium uptake, a reduction in the mitochondrial membrane potential, a decrease in reduced glutathione (GSH), adenosine triphosphate (ATP), nicotinamide adenine dinucleotide phosphate (NADPH) levels, an increase in lipid peroxidation and oxidative damage of cardiolipin and protein sulfhydryl groups (Saad et al., 2004; Martins et al., 2008).

The key problem of regeneration of an organ or tissue is forming an adequate blood supply through the formation of new vasculature. There is an active process of neo-angiogenesis that provides opportunities to recreate the morph functional state of the organ not at the expense of the connective tissue, as happened most frequently, but by reconstructing its parenchyma (Vogrin et al., 2010).

The effect of platelets on liver regeneration was not addressed until the beginning of the 21st century. There are some reported studies in which platelets were shown to promote liver regeneration (Murata et al., 2007). PRP is approved by FDA and extensively used in different medical fields (Kurita et al., 2011; Sanchez-Gonzalez et al., 2012). PRP has many advantages, such as its availability, affordability and being a process of a

minimally invasive technique. The platelet-rich plasma (PRP) used in tissue regeneration serves as a developing era for clinicians and researchers. It is well known that platelets have a thrombotic effect, as they contain not only proteins needed for hemostasis but also many growth factors such as transforming growth factor (TGF), platelet-derived growth factor (PDGF), vascular endothelial growth factor (VEGF), epidermal growth factor (EGF) and insulin-like growth factor (IGF) (Sanchez et al., 2009). Platelets accumulate in the liver under some kinds of pathological conditions, like ischemia/reperfusion injury, liver cirrhosis, cholestatic liver, and viral hepatitis (Pak et al., 2010; Zaldivar et al., 2010). Few studies have investigated the relationship between platelets and liver regeneration (Matsuo et al., 2008).

PRP has potential therapeutic value due to its great advantages, which encourage the research and application of this autologous technology in different medical fields (Anitua et al., 2012) such as corneal persistent epithelial defects and ocular burns (López-Plandolit et al., 2010), treatment of carpal tunnel syndrome by single injection (Malahias et al., 2015), cosmetic and plastic surgery (Plöderl et al., 2011; Rodríguez-Flores et al., 2011) and cardiovascular therapy (Patel et al., 2016).

The platelet-rich plasma (PRP) used in tissue regeneration serves as a developing area for clinicians and researchers. It is well known that platelets have a thrombotic effect. Platelets contain not only proteins needed for hemostasis but also many growth factors such as transforming growth factor (TGF), platelet-derived growth factor (PDGF), vascular endothelial growth factor (VEGF), epidermal growth factor (EGF), and insulin-like growth factor (IGF) (Hiyama et al., 1981).

Some studies have reported that platelets accumulate in the liver under some kinds of pathologic conditions, like ischemia/reperfusion injury (Pak et al., 2010), liver cirrhosis (Zaldivar et al., 2010), cholestatic liver and viral hepatitis (Lang et al., 2008). Thus the present study was designed to analyze the therapeutic role of Platelet-rich Plasma against cisplatin-induced liver injury in the adult albino rat.

MATERIALS AND METHODS

Animals

The present study was carried out on 30 adult male albino rats weighing 180-220 g. The rats were acclimatized in the laboratory for a period of two weeks before carrying out the drug administration. The rats were housed in a separate cage (5 rats each). The experiment was performed at the Animal and Experimental House, Faculty of Medicine, Cairo University. The animals were handled according to the criteria approved by the Institutional Animal Care and Use Committee of Cairo University (IACUC) protocol number CU III S 76 17. The animals were allowed to standardized laboratory diet and water *ad libitum* throughout the experi-

ment.

Chemicals

1. Cisplatin (CDDP): supplied as vials; each contains 10 mg/10ml (a product of Merck company-Germany). It was given as a single intraperitoneal (IP) dose of 7.5 mg/kg body weight. Single dose had been reported to induce hepatotoxicity in rats without lethality (Yadav, 2015).
2. Platelet-rich Plasma (PRP): Under complete aseptic technique, 10 ml of venous blood was drawn from rat's tail veins by a syringe containing 2 ml of sodium citrate. Two centrifugations were performed: the first to separate erythrocytes, and the second to concentrate the platelets (Filardo et al., 2012).

Preparing Platelet-Rich Plasma

The research protocol complied with the guidelines for animal care of our institution. The rats were anesthetized with ether, followed by blood collection from the rats. The blood was then mixed with sodium citrate (3.8%) (9 parts of blood to 1 part of sodium citrate) anticoagulant solution. Then, the blood was centrifuged at 1000 rpm for 15 min at 20°C for separation of platelet rich plasma. Also, the plasma was centrifuged at 3000 rpm for 10 min at 20°C to obtain platelet pellet. The platelet concentrate dissolved in phosphate buffer saline (PBS), pooled and incubated at room temperature for 30 min on a rotating platform to eliminate platelet agglomerates. Platelets were counted using Sysmex KX-21 (Japan), resulting in a platelet number of $679 \times 10^3/\mu\text{l}$ (Xie et al., 2013). At this step, 330 μl of calcium gluconate (100mg/ml) was added to 10mL of plasma and 1mL of thrombin preparation to 4mL of platelet concentrate, and incubated for 1 h at room temperature to facilitate growth factors release. The platelet secretion was centrifuged at 4000 rpm for 5min to reduce the presence of platelet membrane fragments. The supernatant was filtered with a 0.22 μm pore filter, divided into aliquots, and frozen at -80°C for subsequent use (Kazemnejad et al., 2008). This procedure was done in the laboratory of Biochemistry Department, Faculty of Medicine, Cairo University. The PRP must be freshly prepared each time, and used within one hour after preparation (Kwon et al., 2012).

Experimental design

The rats were randomly divided into 3 groups (10 rats each), as follows:

- 1- Group I (sham control): 10 rats, which were injected once on the first day of the experiment received 2 ml of 0.9% saline (the vehicle of cisplatin); then the rats were sacrificed after 4 weeks.
- 2- Group II (cisplatin-treated): each rat was injected intraperitoneally with a single dose of cisplatin (7.5 mg/kg body weight) on the first day of the experiment, and was then sacrificed on the 7th day of the experiment.
- 3- Group III (cisplatin and PRP-treated): each rat was injected intraperitoneally with a single dose of cisplatin (7.5 mg/kg body weight) on the first day of

the experiment. Then on the 7th day each rat was injected subcutaneously with 0.5ml/kg PRP twice weekly for 3 weeks (Hesami et al., 2014); finally, the rats were sacrificed.

At the end of the experiment, the rats of each group were anesthetized using an overdose of anesthesia by intraperitoneal injection of phenobarbital sodium (40 mg/kg). Blood samples were collected from the retro-orbital plexus of veins to measure different liver enzymes. Then the rats were sacrificed by cervical dislocation and the liver was excised and dissected. Fresh liver specimens were taken for histochemical study to measure the oxidative markers in the liver homogenates; the other part was fixed in 10% buffered formol saline, prepared for paraffin blocks. Semi-serial sections of 5 μm thickness were cut. Sections for immunohistochemical study were mounted on charged slides to avoid falling down of tissue during immunostaining. The sections were subjected to:

Light microscopy

Liver sections of each rat were fixed in 10% formal saline solution for 72 h, then were dehydrated through ascending alcohols, cleared with xylene, embedded in paraffin, and sections were cut at 5 μm . Sections were deparaffinized and rehydrated through descending alcohols, and stained with hematoxylin and eosin (H&E) for general oversight, and Masson's trichrome for detection of collagen fibers and Periodic acid Schiff reaction (PAS) to study the density of glycogen in hepatocytes (Bancroft and Gamble, 2008) to demonstrate collagen fibers.

Immunohistochemistry

Ultra Vision large volume detection system anti-polyvalent, HRP (ready to use) (thermoscientific, catalogue number TP-060-HL). It is a broad spectrum detection system that reacts with mouse and rabbit primary antibodies. Sections were cleared in xylene, then mounted and covered by a coverslip. Sections were cut at 5-6 μm thickness and collected on poly-L-lysine coated slides, then deparaffinized in two changes of xylene, 10 minutes each, and hydrated through graded washes of ethanol in water, and finally rinsed in pure water.

For Caspase 3 antibody staining, primary antiserum diluted in antibody diluents (TA-125-UD, Lab vision, Goteborg, Sweden). The peroxidase activity was demonstrated by AEC (3-amino-9-ethyl carbazole) substrate kit (TA-004HAC, Lab vision, Goteborg, Sweden). A positive reaction in the form of brown discoloration of the cytoplasm was shown in the apoptotic cells, while the negative control showed a negative reaction with the absence of the brown discoloration.

Vascular endothelial growth factor (VEGF) staining was performed by the immunoperoxidase technique following predigestion and trypsinization. Antibodies used were a rabbit polyclonal antibody (Santa Cruz Biotechnology, Santa Cruz, CA) at a 1:200 dilution for VEGF. For positive controls, normal liver tissue was stained for VEGF. Negative

controls used all reagents except the primary antibody.

Liver function assay

Retro-orbital blood samples were aspirated from each rat for estimation of liver enzymes. Alkaline Phosphatase (ALP), Aspartate Amino Transferase (AST) and Alanine Amino Transferase (ALT) enzymes levels were estimated using specific kits provided by Bio-diagnostic Company (bio-diagnostic.eka@lycos.com and info@bio-diagnostic.com). These measurements were done in the Biochemistry Department, Faculty of Medicine, Cairo University.

Assays of oxidative/antioxidative markers

We measured MDA using a commercial kit (Biodiagnostic, Cairo, Egypt), according to the manufacturer’s instructions. Briefly, approximately 10-20 mg liver tissue was homogenized in 1 ml PBS, pH 7.0, using a micropestle in a microtube. Then 20% (w/v) trichloroacetic acid was added to the homogenate to precipitate the protein, and centrifuged at 12,000 x g for 15 min. Then 0.8% thiobarbituric acid solution was added to the liver homogenate to precipitate the protein. After boiling for 10 min in a water bath, the absorbance was measured at 405 nm using a spectrophotometer. The concentration of MDA was calculated per milligram protein using a standard curve. The standard curve was prepared as follows. We dissolved 25 µl 1,1,3,3 tetraethoxypropane (TEP) in 100 ml water

to obtain a 1 mM stock solution. We prepared a working standard by hydrolysis of 1 ml TEP stock solution in 50 ml 1% sulfuric acid and incubation for 2 h at room temperature. The resulting MDA 20 nmol/ml standard was diluted with 1% sulfuric acid to produce the final concentrations of 10.5, 2.5, 1.25 and 0.625 nmol/ml to prepare a standard curve for estimating total MDA. Then, 0.250 ml standard were mixed with 25 µl DNPH solution and incubated for 10 min. A 20 µl volume of the reaction mixture was injected directly onto HPLC system (Pilz et al., 2000).

GSH the antioxidant stress marker was measured using a commercial kit to detect glutathione (Biodiagnostic, Cairo, Egypt), according to the manufacturer’s instructions. The measurement was based on reduction of 5, 5 dithiobis-(2 nitrobenzoic acid), with reduced glutathione to produce yellow compound. The reduced chromogen was directly proportional to GSH concentration, and the final reaction product was assayed spectrophotometrically by measuring its absorbance at 405 nm.

Image analysis and histomorphometry

Quantitative study was obtained by the aid of Leica Qwin 500 LTD (Leica Microsystem Corporation, Cambridge, England) using the software Quin 500 (England). All measurements were made by a blinded, independent observer. Measurements were made on ten non- overlapping microscopic fields selected randomly from each slide and examined within the standard measuring frame at X

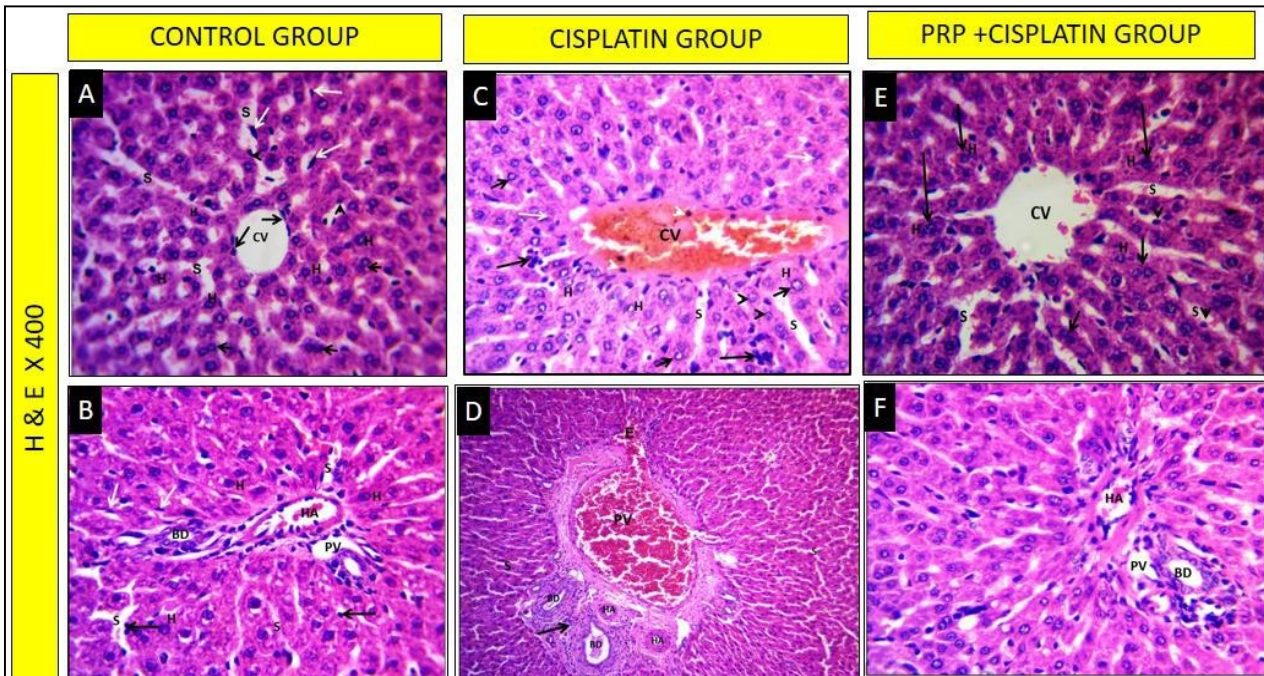


Fig 1. H&E stained liver sections of the experimental groups showing normal classic liver architecture of the control group (A, B). Cisplatin-treated group showing marked dilatation and congestion of the central vein and variable degenerative changes in the hepatocytes. The portal area shows dilatation and congestion of the portal vein and inflammatory cellular infiltration, thickening of the wall of the hepatic artery and acidophilic exudate (C, D). PRP-treated group shows obvious improvement of the liver structure and normalization of the hepatocytes, sinusoids and portal area (E, F). (H&E, x 400).

H: hepatocyte CV: central vein S: liver sinusoid PV: portal vein
 HA: hepatic artery BD: bile duct E: exudate

400. The area percent was determined within the measuring frame. The following measurements were taken: mean optical density of PAS reaction, mean area percentage of collagen fibers, mean area percentage of caspase III and vascular endothelial growth factor (VEGF) immunoexpression.

Statistical analysis

The mean values \pm standard deviations (SD) of the data obtained by the image analyzer for each group were calculated. Comparison of significance between the control and various groups was made by the computer using Statistical Package for the Social Sciences (SPSS) software version 16. The statistical significance of the difference between the obtained mean values was assessed using one way analysis of variance (ANOVA) test. P values \geq 0.05 was considered statistically significant (Armitage and Berry, 1994).

RESULTS

No animal death was observed in the control and CDDP-treated and PRP treated groups.

Light microscopy

Liver sections of the control group showed uniform hepatic parenchymal architecture, cords of hepatocytes radiating from the central vein with narrow hepatic sinusoids in-between. The hepatocytes appeared polyhedral in shape, with central rounded basophilic nuclei and acidophilic cytoplasm. The narrow hepatic sinusoids were lined with flattened endothelial and Von-Kupffer cells. Binucleated hepatocytes were also seen. The por-

tal area was seen at the periphery of the hepatic lobule containing the portal vein, the bile duct and hepatic artery (Fig. 1 A-B).

Liver sections of cisplatin-treated group showed marked dilatation and congestion of the central vein. The hepatocytes exhibited variable degenerative changes. Focal inflammatory cellular infiltration was noticed. Dilated and congested hepatic sinusoids lined with pyknotic Von-Kupffer cells. The portal area showed marked dilated and congested portal vein with interstitial extravasation. Bile ductules degenerative changes and polymorphic cellular infiltration were also detected (Fig. 1 C-D).

Liver sections of PRP-treated group demonstrated preservation of the hepatic parenchymal architecture. Apparently, normal hepatocytes were arranged in radiating cords from the mildly dilated central vein; most of the hepatocytes appeared normal. Some hepatocytes appeared binucleated. The cords were separated by mildly dilated hepatic sinusoids, which were lined with Von-Kupffer cells. The portal area showed apparently normal portal vein, bile ducts (Fig. 1 E-F).

Masson's trichrome-stained sections of the control group showed minimal collagen fibers deposition. The cisplatin-treated group demonstrated a marked increase in collagen fibers deposition mainly in the portal area. PRP-treated group showed a mild increase in collagen fibers deposition (Fig. 2).

PAS stained liver sections of the control group demonstrated strongly positive PAS reaction of the cytoplasm of the hepatocytes. Meanwhile, cisplatin-treated group showed a weak positive PAS reaction. On the other hand PRP-treated group showed

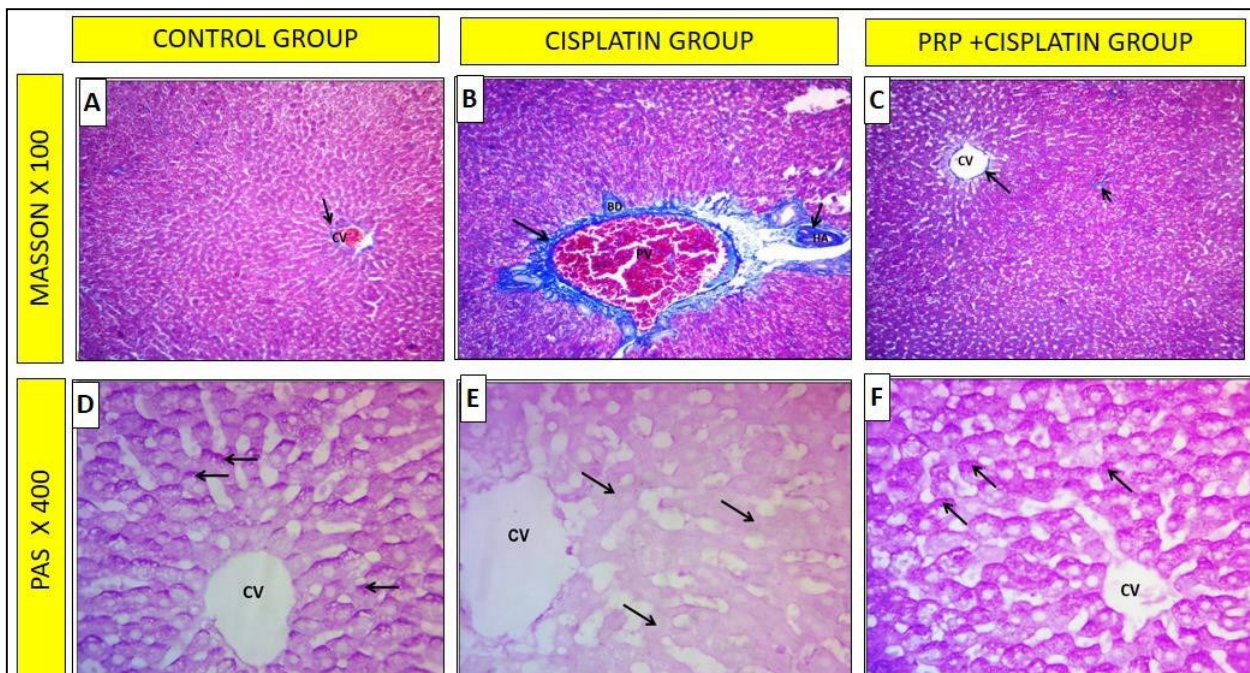


Fig 2. Masson' trichrome stained liver sections showing minimal collagen fibers in the control group (A), marked increase of collagen fibers in cisplatin-treated group (B) and mild collagen deposition in PRP-treated group (C).(x 100). PAS-stained sections showing strong reaction in the hepatocytes of the control group (D), weak reaction in cisplatin-treated group (E) and strong reaction in PRP-treated group (F) (x 400).

a strong positive PAS reaction (Fig. 2).

Immunohistochemistry

Liver stained sections of the control group showed negative caspase-3 immunorexpression. Meanwhile, cisplatin-treated group revealed a strong positive caspase-3 immunorexpression. On the other hand, PRP-treated liver sections revealed a mild positive caspase-3 in the cytoplasm of the hepatocytes (Fig. 3).

Liver stained sections of the control group showed a minimal VEGF reaction in the endothelial lining of the hepatic sinusoids. The cisplatin-treated group showed a strong positive VEGF immunostaining. On the other hand, PRP-treated group showed a strong positive VEGF reaction in the cytoplasm of hepatocytes (Fig. 3).

Biochemical assay

Biochemical assay of the liver enzymes of the cisplatin-treated group revealed a marked increase in AST mean value (152.16 ± 8.2 U/L), which was statistically significant ($P \leq 0.05$) compared with the mean \pm SD values of group I (88.24 ± 4.1) and PRP-treated group. Meanwhile, treatment with PRP in group III showed a reduction in AST mean value (94.12 ± 4.1), which was statistically non-significant ($P > 0.05$) compared with the value the control group.

Group II cisplatin-treated showed a marked increase in ALT mean value (74.14 ± 3.4 U/L), which was statistically significant ($P \leq 0.05$) compared with the mean values of the control group (38.18 ± 2.3) and PRP-treated group. Meanwhile, treatment with PRP in group III showed reduction in ALT mean value (40.18 ± 2.6), which was insignificant in relation with the control group.

The cisplatin-treated group showed a marked increase in ALP mean value (162.32 ± 8.4 U/L), which was statistically significant ($P \leq 0.05$) compared with the mean value of the control (74.22 ± 6.2) and

PRP-treated groups. On the other hand, treatment with PRP in group III showed a reduction in ALP mean value (78.28 ± 9.2), which was statistically significant compared with group II cisplatin-treated and non-significant compared with the value in the control group (Table 1, Fig. 4-A).

Assay of oxidant and antioxidant markers

1- Malondialdehyde (MDA) (nmol/g protein). The liver homogenates of cisplatin-treated group demonstrated a marked increase in MDA mean value (42.18 ± 3.6), which was statistically significant ($P \leq 0.05$) compared with the mean value of the control group (18.62 ± 2.4). Meanwhile, treatment with PRP showed a reduction in MDA mean value (20.16 ± 1.8) compared with the same values in group II, and was statistically non-significant ($P > 0.05$) if compared with the values in the control group (Table 2, Fig. 4-B).

2- Glutathione reductase (GSH) ($\mu\text{mol/g}$ protein). The liver homogenates of cisplatin-treated demonstrated a marked decrease in GSH mean value (0.12 ± 0.02), which was statistically significant ($P \leq 0.05$) compared with the mean value of the control group (0.28 ± 0.02). On the other hand, treatment with PRP demonstrated an increase in the mean value (0.22 ± 0.01), which was statistically non-significant compared with the value of the control group (Table 2, Fig. 4-C).

Image analysis and morphometric analysis

1- Mean optical density of PAS reaction. The histomorphometric analysis showed a marked decrease in mean value of the optical density of PAS reaction in the liver sections of cisplatin-treated group (32.02 ± 2.5), which was statistically significant compared with the mean value of the control group (64.2 ± 12). Meanwhile, treatment with PRP in group III revealed an increase in mean value (60.14 ± 5.1), which was statistically non-significant compared with the value in the control group (Table 4, Fig. 4-D).

Mean area percentage of collagen fibers. Liver sections of cisplatin-treated group revealed a

Table 1. Effect of PRP on selected biochemical parameters in rats treated with cisplatin.

	Group I Control	Group II Cisplatin- treated	Group III PRP + cis- platin-treated
AST	88.24	152.16	94.12
Mean \pm SD (IU/L)	± 4.1	± 8.2	± 4.1
P value	-	$\leq 0.05^*$	NS \neq
ALT	38.18	74.14	40.18
Mean \pm SD (IU/L)	± 2.3	± 3.4	± 2.6
P value	-	$\leq 0.05^*$	NS \neq
ALP	74.22	162.32	78.28
Mean \pm SD (IU/L)	± 6.2	± 8.4	± 9.2
P value	-	$\leq 0.05^*$	NS \neq

SD: Standard deviation

Statistically significant P value $\leq 0.05^*$ compared with control group NS: Non significant \neq compared with the control group

Table 2. Effect of PRP administration on MDA, GSH levels in liver homogenate of rats treated with cisplatin.

	Group I Control	Group II Cisplatin - treated	Group III PRP + cis- platin-treated
MDA (nmol/g protein)	18.62	42.18	20.16
Mean \pm SD	± 2.4	± 3.6	± 1.8
P value	-----	$\leq 0.001^{**}$	NS \neq
GSH ($\mu\text{mol/g}$ protein)	0.28	0.12	0.22
Mean \pm SD	± 0.02	± 0.02	± 0.01
P value	-----	$\leq 0.05^*$	NS \neq

SD: Standard deviation

Statistically significant P value $\leq 0.05^*$ compared with control group NS: Non significant \neq compared with the control group.

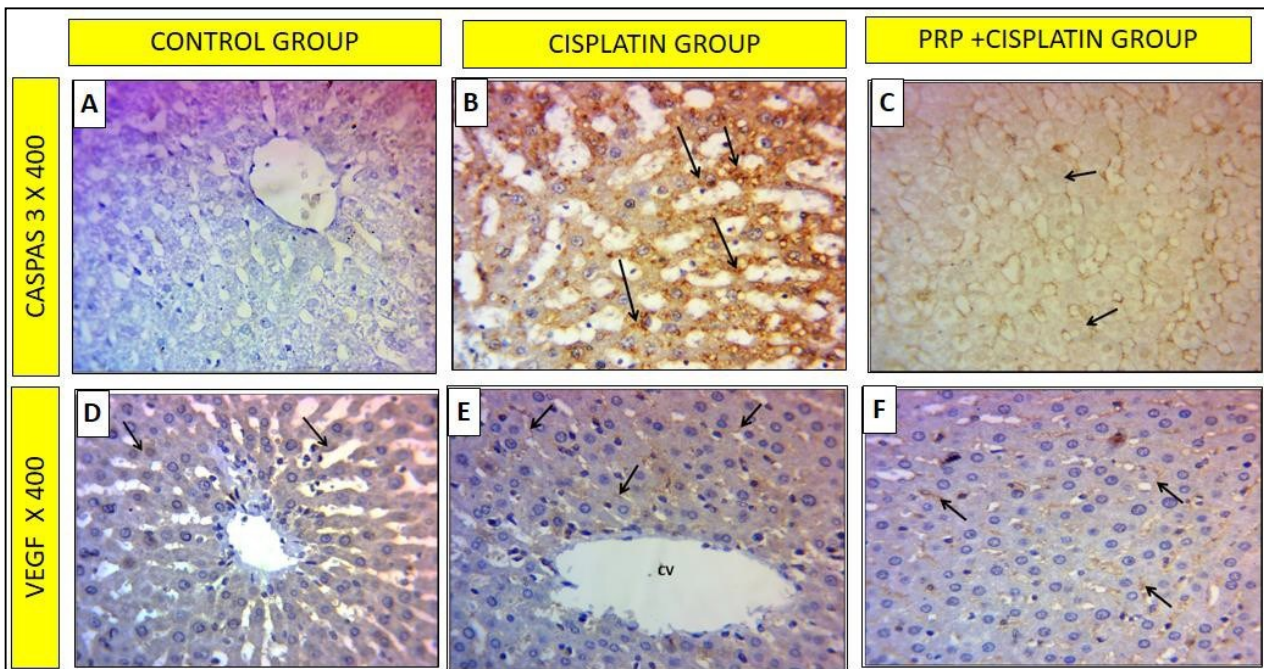


Fig 3. Caspase 3 immunoexpression: Negative reaction in the hepatocytes of the control group (A), strong reaction in cisplatin-treated group (B) and mild reaction in PRP-treated group (C) (x 400). VEGF immunoexpression: minimal VEGF reaction in the endothelial lining of the hepatic sinusoids in the control group (D), strong positive VEGF immunostaining in cisplatin-treated group (E) and strong positive VEGF reaction in PRP-treated group (F) (x 400).

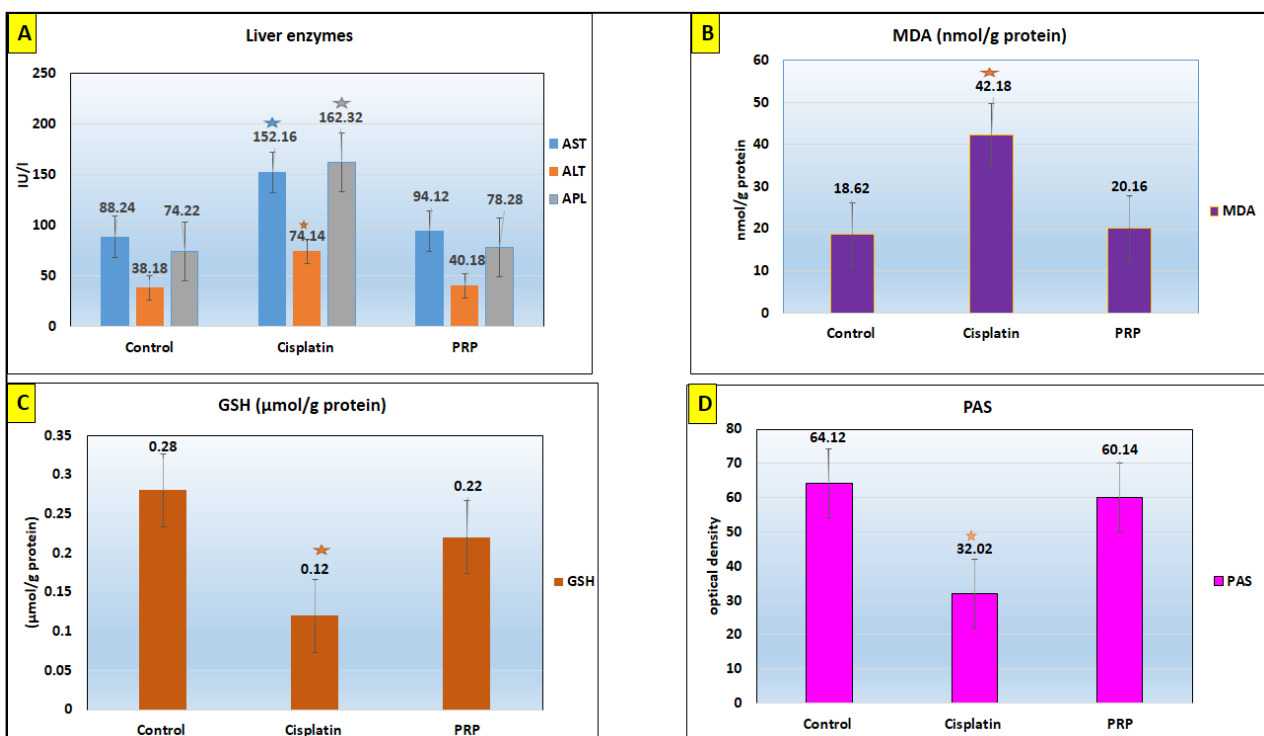


Fig 4. Histograms showing comparison between the different groups:

Liver enzyme assay (A): showing significant elevation* of the liver enzymes (AST, ALT and ALP) of cisplatin-treated group compared with the control group. PRP-treated group showing reduction of such elevated parameters.

MDA level (B): showing significant elevation* of MDA level of cisplatin-treated group compared with the control group. PRP-treated group showing reduction of MDA level.

GSH level (C): showing significant reduction* of GSH level of cisplatin-treated group compared with the control group. PRP-treated group showing obvious increase of GSH level.

Optical density of PAS reaction (D): significant reduction* of optical density of cisplatin-treated group compared with the control group. PRP-treated group showing obvious increase of optical density in relation to other groups.

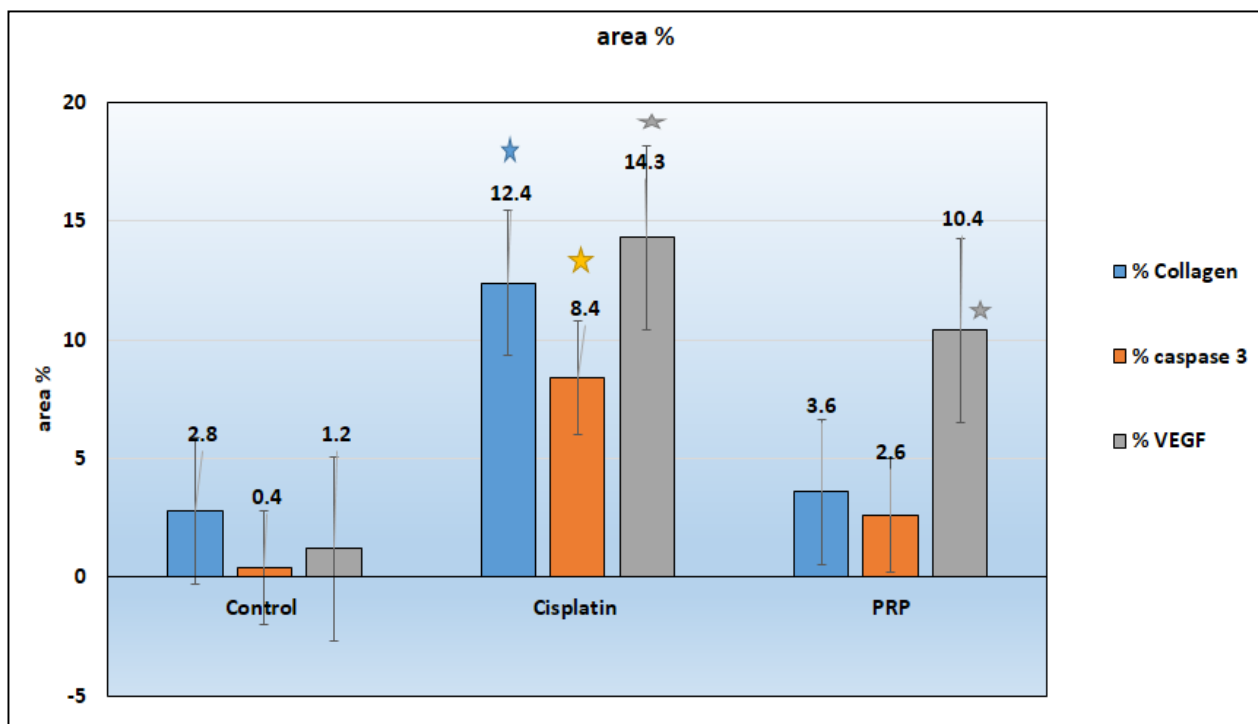


Fig 5. Histogram showing the mean area % of collagen fibers, caspase 3 and VEGF of the different groups showing significant increase* in these parameters in cisplatin-treated group compared with the control group. Meanwhile PRP-treated group showing marked reduction in area % of collagen and caspase 3, but significant rise* of VEGF compared with the control group.

marked increase in mean value of area % of collagen fibers deposition (12.4 ± 1.2 %), which was statistically significant compared with the mean value of the control group (2.8 ± 0.4). Meanwhile, treatment with PRP in group III demonstrated a reduction in mean value (3.6 ± 1.2) in comparison to the same values in groups II, and was statistically insignificant as compared with the values in the control group (Table 3, Fig. 5).

Mean area percentage of caspase-3 immunoexpression. Liver sections of cisplatin-treated group revealed a marked increase in mean value of area % of caspase-3 immunoexpression (8.4 ± 2.1), which was statistically significant compared with the mean value of the control group (0.4 ± 0.02). Meanwhile, treatment with PRP in group III revealed a reduction in mean value (2.6 ± 2.1) which was statistically insignificant compared with the value in the control group (Table 5, Fig. 5).

Table 4. Mean values \pm SD of optical density of PAS reaction in the liver sections of the different experimental groups.

	Group I Control group	Group II Cisplatin- treated	Group III PRP + cispla- tin-treated
Mean optical density Mean \pm SD	64.12 ± 2.8	32.02 ± 2.5	60.14 ± 5.1
P value	-----	$\leq 0.05^*$	NS \neq

SD: Standard deviation

Statistically significant P value $\leq 0.05^*$ compared with control group NS: Non significant \neq compared with the control group

Mean area percentage of vascular endothelial growth factor (VEGF) immunoexpression. Liver sections of cisplatin-treated group revealed a marked increase in the mean value of area % of VEGF immunoexpression of VEGF (14.3 ± 2.3) which was statistically significant compared with the mean value of the control group (1.2 ± 1.6). However, treatment with PRP in group III showed an increase in the mean value (10.4 ± 3.8) which was statistically significant compared with the mean values in the control group (Table 6, Fig. 5).

DISCUSSION

This study was designed to investigate the effects of PRP on cisplatin-induced liver damages. Animals that received CDDP showed severe biochemical and histological changes in serum and tissues. On the other hand, treatment with PRP

Table 3. Mean value \pm SD of area % of collagen fibers of all groups.

	Group I Control group	Group II Cisplatin - treated	Group III PRP + cisplatin- treated
Mean area % Mean \pm SD	2.8 ± 0.4	12.4 ± 1.2	3.6 ± 1.2
P value	-----	$\leq 0.05^*$	NS \neq

SD: Standard deviation

Statistically significant P value $\leq 0.05^*$ compared with control group NS: Non significant \neq compared with the control group

caused a significant improvement in tested parameters, which were significantly altered by cisplatin administration.

The livers of the control group showed normal histological structures. In the cisplatin-treated group, significant histological alterations consisting of congestion, dilatation, epithelial vacuolization, and infiltration of mononuclear cells in the liver tissues took place. There were marked changes in the biochemical parameters and immunoeexpression of caspase 3 and VEGF in the liver tissue. On the other hand, these changes were decreased in the CCDP + PRP treated animals.

Cisplatin-treated group showed marked affection of the liver structures and functions, with significant elevations of serum hepatic enzymes AST, ALT and ALP levels in comparison to the control group. These findings were in agreement with Karadeniz et al. (2011) and Attyah and Ismail (2012).

Histopathological examination of the cisplatin-treated group (group II) revealed hepatocellular degenerative changes, induction of apoptosis and initiation of inflammatory reaction, as well as hemodynamic derangement of hepatic vasculatures. Degenerative and apoptotic cascades induced by cisplatin could be attributed to increased oxidative stress in hepatic tissue which reported by Sinha et al. (2013), who discussed the role of oxidative stress in the induction of apoptosis via mitochondrial and non-mitochondrial pathways. Also, these findings matched with those obtained by Mir et al. (2015), Yadav (2015) and Salem et al. (2017), who reported that cisplatin administration highly elevated ALT, AST and ALP enzymes.

There were congestion and dilatation in the central vein and the hepatic sinusoids with separation of the endothelial lining of the central vein. These findings were in agreement with Koc et al. (2005), Avci et al. (2008), Mir et al. (2015) and Salem et al. (2017), who found congestion of the central vein and the hepatic sinusoids in rats treated with cisplatin. These findings were attributed to portal hypertension or to the direct effect of cisplatin on the vascular endothelial cells leading to release of endothelium relaxation factor-nitric oxide (Hu et al., 2013).

Liver sections showed marked mononuclear cellular infiltration in cisplatin-treated group. This inflammatory reaction could be related to the oxida-

tive stress that resulted in generation of mediators such as IL-8 and cytokine-induced neutrophil chemoattractant, which attract the inflammatory cells into microcirculation, and then to the liver interstitium due to destruction of the endothelial cells by the free radicals, as mentioned by Rahman and Mcnee (2000) and Aydin et al. (2003).

Cytoplasmic vacuolations were noticed in liver sections. Similar findings were reported by Ozyurt et al. (2004), Koc et al. (2005) and Salem et al. (2017), who related this finding to the oxidative damage of cisplatin to the membrane lipids and other cellular component of the liver cells. Mora et al. (2003) reported that the lipid peroxidation (LPO) was crucial in the pathogenesis of cisplatin-induced hepatic injury. Moreover, Hassan et al. (2009) offered another explanation that these vacuolations might be caused by dissolution of hepatic cords by the effect of cisplatin. Halliwell and Gutteridge (1999), Antunes and Darin (2000) and Silva et al. (2001) attributed these findings to reactive oxygen species (ROS), such as superoxide anion and hydroxyl radicles and heavy oxidative stress. Also, they added that cisplatin administration caused an increase in the level of malondialdehyde (MDA) in the liver.

There was marked collagen tissue deposition in group II. This finding was in agreement with Avci et al. (2008), who found a significant fibrosis around the central vein and the periportal area in cisplatin-treated rats. The fibrosis could be explained by either the direct toxic effect of the cisplatin or as a result of the inflammation process as reported by Kumar et al. (2005).

Moreover, there was weak PAS reaction, which was in agreement with the finding of Mansour et al. (2006) and Lee et al. (2007), who revealed the weak reaction in cisplatin-treated groups due to a remarkable reduction in the glycogen stores within the cytoplasm of most hepatocytes. Abdelmeguid et al. (2010) explained that due to hepatic damage induced by cisplatin, the hepatocytes are no more capable of storing glucose in the form of glycogen.

The increase in AST and ALT and ALP activities in the cisplatin-treated group was found to be related to damage in the liver and change in hepatic functions. The rise in the levels of serum parameters has been attributed to the damaged structural integrity of the liver, because these are normally

Table 5. Mean values \pm SD of area % of caspase-3 immunoeexpression in the liver sections of the different experimental groups

	Group I Control group	Group II Cisplatin- treated	Group III PRP + cis- platin-treated
Mean area %	0.4	8.4	2.6
Mean \pm SD	± 0.02	± 2.1	± 2.1
P value		$\leq 0.05^*$	NS \neq

SD: Standard deviation

Statistically significant P value $\leq 0.05^*$ compared with control group NS: Non significant \neq compared with the control group

Table 6. Mean values \pm SD of area % of VEGF immunoeexpression in the liver sections of the different experimental groups.

	Group I Control group	Group II Cisplatin- treated	Group III PRP + cisplatin- treated
Mean area %	1.2	14.3	10.4
Mean \pm SD	± 1.6	± 2.3	± 3.8
P value	-----	$\leq 0.05^*$	$\leq 0.05^*$

SD: Standard deviation

Statistically significant P value $\leq 0.05^*$ compared with control group.

located in the cytoplasm and are released into the circulation after hepatic damage (Sallie et al., 1991).

These findings were explained by Yachi et al. (2010), who mentioned that during cisplatin administration to rats, the actions of aspartate aminotransferase (AST) and alanine aminotransferase (ALT) in rat plasma rise remarkably with necrosis and lipid accumulation of hepatocyte. Both enzymes are indicators of liver injury. Moreover, Wolf (1999) mentioned that ALT is more sensitive to acute liver injury test, whereas AST is more sensitive to chronic injury.

On the other hand, cisplatin-and-PRP-treated group revealed significantly improved liver functions and normalization of the levels of ALT, AST, and ALP, which are indicators of hepatic improvement. These findings were in accordance with Hesami et al. (2014), Kholodkova and Romak (2016) and Mafi et al. (2016), who mentioned that PRP treatment significantly improved the liver functions and the levels of ALT and AST after CCL4 administration.

The present work revealed obvious increase in lipid peroxidation end product, MDA in parallel to the reduction in GSH in the hepatic tissue of cisplatin-treated rats, compared to the control group. These results fit the criteria provided by Shimeda et al. (2005), Lee et al. (2007), Karadeniz et al. (2011) and Yadav (2015). Also, Cayir et al. (2009) mentioned that cisplatin treatment causes an increase in lipid peroxide levels and a decrease in the activities of antioxidant enzymes that protect against lipid peroxidation in the tissues such as liver and kidney. The rise of MDA levels in the liver is indicative of an enhanced peroxidation that causes tissue damage and breakdown of the antioxidant defense mechanisms, and thus inhibits the formation of superabundant free radicals (Lee et al., 2008). These findings could be explained by Schinella et al. (2002), who attributed these changes to the release of the free radicals such as superoxide radicals, hydroxy radicals, peroxy radicals, and singlet oxygen, which at the same time damage liver cells caused by cisplatin administration. Free radicals are known to attack the highly unsaturated fatty acids of the cell membrane to induce lipid peroxidation, which is considered a key process in many pathological events and is one of the reactions induced by oxidative stress.

Moreover, Mansour et al. (2006), Palipoch et al. (2014) and Ko et al. (2014) attributed these findings to the fact that cisplatin may interfere with the tissue antioxidant defense system and generation of highly reactive oxygen species (ROS), thus causing oxidative damage to the liver and reduction of lipid peroxidation protecting enzymes.

Saleh et al. (2014) mentioned that higher MDA and lower GSH in the serum of group III and IV revealed the elevated lipid peroxidation and exhausted antioxidant activities in cisplatin-treated rats. Hanigan and Devarajan (2003) reported that the oxidative stress mainly results from formation of cisplatin-GSH conjugation, which contributes to

GSH depletion and alteration of redox state in kidney, and consequently leads to an increase in generation of superoxide and other oxygen radicals (Santos et al., 2007).

PRP administration in group III caused a significant decrease in MDA and increase in GSH levels, compared to cisplatin-treated rats. These results were in agreement with Hesami et al. (2014), who attributed the hepatoprotective effects of PRP to inhibition of lipid peroxidation and effective recovery of the antioxidant defense system and had a remarkable effect on signal transduction.

In the present study, apoptosis was a characteristic finding seen in group II. A similar finding was reported by Karadeniz et al. (2011) and Salem et al. (2017), who explained that apoptosis is a gene-regulated event related to special morphological changes, such as shrinkage of cell, chromatin condensation, and DNA damage. Many factors participate in apoptotic mechanism, which are believed to act through 2 main families of proteins, including cysteine protease called caspase enzyme (especially caspase-3, 8, 9) and Bcl-2 family. There was strong positive caspase III reaction in group II, which was in agreement with the findings of Omar et al. (2016) who denotes apoptotic changes of the hepatocytes and increase in apoptotic cells. This finding also was matched with that obtained by Dart et al. (2006) and Rios et al. (2009), who suggested that ROS induced by cisplatin caused inhibition of mitochondrial function and antioxidant enzyme activity resulting in DNA damage.

There were a strong positive VEGF immunoeexpression in group II (cisplatin-treated). This finding was in agreement with Saleh et al. (2014). VEGF mediates angiogenesis in both physiologic and pathologic states, and has many effects on endothelial cells related to vasodilation and permeability (Melly et al., 2012). Kimura and Esumi (2003) reported that NO has been described to induce the expression of VEGF. Yilmaz et al. (2005) added that cisplatin caused high nitric oxide (NO) level in liver tissue due to activation of inducible nitric oxide synthase (iNOS). iNOS regulates expression of another proinflammatory and proangiogenic enzymes, COX-2.

The improvement of the morphofunctional state of the liver by PRP might be attributed to the influence of intercellular interactions between numerous growth factors and cytokine cocktail, including HGF, TNF- α , IL-6, TGF- α , and EGF, which have vital roles in activation of downstream cascades, related to the advance of quiescent hepatocytes into the cell cycle and progression beyond the restriction point in G1 phase of the cycle (Malik et al., 2002). Ohkohchi et al. (2012) proved that immediate contact between platelets and hepatocytes could evoke the release of soluble factors from platelets, for example IGF-1, VEGF and HGF, which are considered crucial mediators for liver recovery. The powerful influence of high concentrations of biologically active substances involved in the neoangiogenesis led to growth of new blood

vessels that created a unique framework for the diseased tissue, and the progenitor cells came with the vessels. Textor (2014) and Kholodkova and Romak (2016) declared that the progenitor cells in the PRP differentiate in the hepatic tissue into hepatocytes and stellate cells. Thus, preventing formation of connective tissue components.

Stiles et al. (2009) and Hisakura et al. (2010) suggested that an increase in the platelet count prevents hepatocyte apoptosis by activating the Akt pathway and up regulating Bcl-xL, which suppresses caspase-3 activation, and liver regeneration and strong positive VEGF reaction. Park et al. (2011) and Anitua et al. (2013) attributed this to the PRP has a large content of growth factors responsible for regeneration. Murata et al. (2007) and Matsuo et al. (2008) observed that platelets accumulated in the liver and translocated into the space of Disse to directly contact the hepatocytes, which triggers the secretion of HGF, IGF-1, and VEGF from the platelets. These growth factors initiate mitosis in hepatocytes and promote liver regeneration, a favorable impact on liver sinusoidal endothelial cells.

Our findings match the criteria reported by Salem et al. (2018) who found that PRP administration improved the periductular fibrosis, cholestasis in the bile duct, hyalinized blood vessels with endotheliosis, necrosis and apoptosis in hepatic cells, apart from mild dilated congested hepatic sinusoids.

Kawasaki et al. (2010) demonstrated that the direct contact of platelets with liver sinusoidal endothelial cells induces sphingosine1-phosphate (S1P) release from the platelets, which promotes IL-6 secretion from the liver sinusoidal endothelial cells. IL-6 subsequently accelerates hepatocyte mitosis via the IL-6/STAT3 pathway, and a collaborative impact on Kupffer cells, the hepatic expression of TNF- α and IL-6, which are predominantly produced by Kupffer cells (Decker, 1998; Michalopoulos and Defrances, 2005).

In conclusion, cisplatin treatment induces liver injury, as indicated by the elevation of serum biochemical parameters, the decline of the antioxidant activity, and the increases of caspase-3 immune staining cells number. The excessive production of free radicals is one of the main reasons for the changes above. However, treatment with PRP was found to reduce cisplatin-induced liver changes. This protection may be due to anti-apoptotic, antioxidant, and free radical scavenging activity of PRP and its components. Therefore, PRP may be of help to prevent liver toxicity manifested by cisplatin chemotherapy.

REFERENCES

- ABDELMEGUID NE, CHMAISSE HN, ABOU ZEINAB NS (2010) Silymarin ameliorates cisplatin-induced hepatotoxicity in rats: Histopathological and Ultrastructure Studies. *Pak J Biol Sci*, 13(10): 463-479.
- AJANI JA (2008) Optimizing docetaxel chemotherapy in patients with cancer of the gastric and gastroesophageal junction: Evolution of the docetaxel, cisplatin and 5-fluorouracil regimen. *Cancer*, 113: 945-955.
- AKYOL O, HERKEN H, UZ E (2002) The indices of endogenous oxidative and antioxidative processes in plasma from schizophrenic patients. The possible role of oxidant/antioxidant imbalance. *Neuropsychopharmacol Bio Psychiatry*, 26: 995-1005.
- ANITUA E, ALKHRAISAT MH, ORIVE G (2012) Perspectives and challenges in regenerative medicine using plasma rich in growth factors. *J Control Release*, 10; 157(1): 29-38.
- ANITUA E, ANDIA I, ARDANZA B (2004) Autologous platelets as a source of proteins for healing and tissue regeneration. *Thromb Haemost*, 91: 4-15.
- ANITUA E, ZALDUENDO MM, ALKHRAISAT MH (2013) Release kinetics of platelet-derived and plasma-derived growth factors from autologous plasma rich in growth factors. *Ann Anat*, 195: 461-466.
- ANTUNES LMG, DARIN JDC (2000) Effect of antioxidants curcumin or selenium on cisplatin-induced nephrotoxicity and lipid peroxidation in rats. *Pharmacol Res*, 41: 405-411.
- ARMITAGE P, BERRY C (1994) Statistical methods in medical research, 3rd edition. Blackwell Scientific Publications, London, pp 40-48.
- ATTYAH AM, ISMAIL SH (2012) Protective effect of ginger extract against cisplatin-induced hepatotoxicity and cardiotoxicity in rats. *Iraqi J Pharmaceutical Sci*, 21(1): 27-33.
- AVCI A, ÇETIN R, ERGÜDER IB (2008) Cisplatin causes oxidation in rat liver tissues: Possible protective effects of antioxidant food supplementation. *Tur J Med Sci*, 38(2): 117-120.
- AYDIN G, EKREM I, MEHMET A (2003) Histopathological and biochemical changes in lung tissues of rats following administration of fluoride over several generations. *J Appl Toxicol*, 23: 437-446.
- CAYIR K, KARADENİZ A, YILDIRIM A (2009) "Protective effect of L-carnitine against cisplatin-induced liver and kidney oxidant injury in rats. *Central Eur J Med*, 4: (2): 184-191.
- DART RC, ERDMAN AR, OLSON KR (2006) American Association of poison control: acetaminophen poisoning an evidence-based consumers guideline for out-of-hospital management. *Clin Toxicol*, 44(1): 1-18.
- DECKER K (1998) The response of liver macrophages to inflammatory stimulation. *Keio J Med*, 47: 1-9.
- ELWELL KE, HALL C, THARKAR S (2006) A fluorine-containing bipyridine cisplatin analog is more effective than cisplatin at inducing apoptosis in cancer cell lines. *Bioorg Med Chem*, 14: 8692-8700.
- FILARDO G, KON E, RUIZ MT (2012) Platelet-rich plasma intraarticular injections for cartilage degeneration and osteoarthritis: Single versus double spinning approach. *Knee Surg Sports Traumatol Arthrosc*, 20 (10): 2082-2091.
- HALLIWELL B, GUTTERIDGE JMC (1999) Antioxidants. In: *Nutrition, Health and Disease*, 3rd ed. Oxford University Press, Oxford, New York, Tokyo, pp 59-72.
- HANIGAN MH, DEVARAJAN P (2003) Cisplatin nephrotoxicity: molecular mechanisms. *Cancer Ther*, 1: 47-61.
- HASSAN IE, MOHAMED FI, SHALABY FM (2009): His-

- topathological effects of cisplatin, doxorubicin and 5-fluorouracil (5-FU) on the liver of male albino rats. *Intern J Biol Sci*, 5(5): 466-473.
- HESAMI Z, JAMSHIDZADEH A, AYATOLLAHI M (2014) Effect of platelet-rich plasma on CCL4-induced chronic liver injury in male rats. *Inter J Hepatol*, 932930. doi: 10.1155/2014/932930.
- HISAKURA K, MURATA S, TAKAHASHI K (2011) Platelets prevent acute hepatitis induced by anti-fas antibody. *J Gastroenterol Hepatol*, 26: 348-355.
- HIYAMA Y, MAHMUD I, KARIMI-TARI F (1981) Platelet-derived growth factor and thromboxane are necessary for liver regeneration. *Cell Mol Biol*, 27 (6): 593-599.
- HOSHI R, MURATA S, MATSUO R (2007) Freeze-dried platelets promote hepatocyte proliferation in mice. *Cryobiology*, 55(3): 255-260.
- HU LS, GEORGE J, WANG JH (2013) Current concepts on the role of nitric oxide in portal hypertension. *World J Gastroenterol*, 19: 1707-1717.
- KADIKOYLU G, BOLANAM Z, DEMIR S (2004) The effect of desferrioxamine on cisplatin-induced lipid peroxidation and the activities of antioxidant enzymes in rat kidneys. *Hum Exp Toxicol*, 23: 29-34.
- KARADENIZ A, SIMSEK N, KARAKUS E, YILDIRIM S, KARA A, CAN I, KISA F, EMRE H, TURKELI M (2011) Royal jelly modulates oxidative stress and apoptosis in liver and kidneys of rats treated with cisplatin. *Oxid Med Cell Longev*, 981793. doi:10.1155/2011/981793.
- KAWASAKI T, MURATA S, TAKAHASHI K (2010) Activation of human liver sinusoidal endothelial cell by human platelets induces hepatocyte proliferation. *J Hepatol*, 53: 648-654.
- KAZEMNEJAD S, ALLAMEH A, GHAREHBAGHIAN A, SOLEIMANI M, AMIRIZADEH N, JAZAYERI M (2008) Efficient replacing of fetal bovine serum with human platelet release during propagation and differentiation of human bone marrow-derived mesenchymal stem cells to functional hepatocytes-like cells. *Vox Sanguinis*, 95(2): 149-158.
- KHOLODKOVA OL, ROMAK OI (2016) Experimental grounds of using platelet-rich plasma to stimulate liver regeneration in case of chronic hepatitis. *Deutscher Wissenschaftsherold, German Science Herald*, N 2/2016 56-59 (UDC 616.36-092.9-085.382).
- KIMURA H, ESUMI H (2003) Reciprocal regulation between nitric oxide and vascular endothelial growth factor in angiogenesis. *Acta Biochim Pol*, 50: 49-59.
- KO DW, LEE IC, PARK SH (2014) Protective effect of pine bark extract against cisplatin-induced hepatotoxicity and oxidative stress in rats. *Lab Anim Res*, 30(4): 174-180.
- KOC A, MEHMET D, HARUN C (2005) Protective agent, erdosteine, against cisplatin-induced hepatic oxidant injury in rats. *Mol Cell Biochem*, 278: 79-84.
- KRUGER NJ (2009) The Bradford method for protein quantitation. In: *The Protein Protocols Handbook*. Springer, pp 17-24.
- KUMAR KM, ABBA AK, FAUSTO N (2005) Robbins and Cotran pathological basis of disease. 7th ed. Library of Congress, Philadelphia, Pennsylvania, pp 880-886.
- KURITA J, MIYAMOTO M, ISHII Y (2011) Enhanced vascularization by controlled release of platelet-rich plasma impregnated in biodegradable gelatin hydrogel. *Ann Thorac Surg*, 92(3): 837-844.
- KWON DR, PARK GY, LEE SU (2012) The effects of intraarticular platelet rich plasma injection according to the severity of collagenase induced knee osteoarthritis in a rabbit model. *Ann Rehab Med*, 36(44): 458-465.
- LANG PA, CONTALDO C, GEORGIEV P (2008) Aggravation of viral hepatitis by platelet-derived serotonin. *Nat Med*, 14(7): 756-761.
- LEE CK, PARK KK, LIM SS (2007) Effects of licorice extract against tumor growth and cisplatin-induced toxicity in a mouse xenograft model of colon cancer. *Biol Pharm Bull*, 30: 2191-2195.
- LEE KJ, CHOI J H, KHANAL T, HWANG YP, CHUNG YC, JEONG HG (2008) Protective effect of caffeic acid phenethyl ester against carbon tetrachloride-induced hepatotoxicity in mice. *Toxicol*, 248(1): 18-24.
- LÓPEZ-PLANDOLIT S, MORALES MC, FREIRE V (2010) Plasma rich in growth factors as a therapeutic agent for persistent corneal epithelial defects. *Cornea*, 29(8): 843-848.
- LU Y, ARTHUR IC (2006) Cisplatin-induced hepatotoxicity is enhanced by elevated expression of cytochrome P 450 2E1. *Toxicol Sci*, 89(2): 515-523.
- MACPHEE PJ, SCHMIDT EE, GROOM AC (1992) Evidence for Kupffer's cell migration along liver sinusoids, from high resolution in vivo microscopy. *Am J Physiol*, 263: 17-23.
- MAFI A, DEGHANI F, MOGHADAM A (2016) Effect of platelet-rich plasma on liver regeneration in CCL4-induced hepatotoxicity model. *J Platelets*, 27: 771-776.
- MALAHIAS MA, JOHNSON EO, BABIS GC (2015) Single injection of platelet rich plasma as a novel treatment of carpal tunnel syndrome. *Neural Regen Res*, 10(11): 1856-1859.
- MALIK R, SELDEN C, HODGSON H (2002) The role of non-parenchymal cells in liver growth. *Semin Cell Dev Biol*, 13: 425-431.
- MANSOUR HH, HAFEZ HF, FAHMY NM (2006) Silymarin modulates cisplatin-induced oxidative stress and hepatotoxicity in rats. *J Biochem Mol Biol*, 39: 656-661.
- MARTINS NM, SANTOS NA, CURTI C (2008) Cisplatin induces mitochondrial oxidative stress with resultant energetic metabolism impairment, membrane rigidification and apoptosis in rat liver. *J Appl Toxicol*, 28: 337-344.
- MATSUO R, OHKOHCHI N, MURATA S (2008) Platelets strongly induce hepatocyte proliferation with IGF-1 and HGF in vitro. *J Surg Res*, 145: 279-286.
- MELLY L, MARSANO A, FROBERT A (2012) Controlled angiogenesis in the heart by cell-based expression of specific vascular endothelial growth factor levels. *Human Gene Ther*, 23(5): 346-356.
- MICHALOPOULOS GK, DE FRANCES M (2005) Liver regeneration. *Adv Biochem Engineer Biotechnol*, 93: 101-134.
- MICHALOPOULOS GK, DEFRANCES MC (1997) Liver regeneration. *Science*, 276: 60-66.
- MIR M, ARAB MR, SHAHRAKI MR (2015) Toxic effects of cisplatin on hepatocytes and liver enzymes of rats. *As J*, 12(4): 171-176.
- MORA LO, ANTUNES LM, FRANCESKOCATO HD

- (2003) The effect of oral glutamine on cisplatin-induced nephrotoxicity in rats. *Pharmacol Res*, 47: 511-522.
- MURATA S, OHKOHCHI N, MATSUO R (2007) Platelets promote liver regeneration in early period after hepatectomy in mice. *World J Surg*, 31: 808-816.
- OBATA T (2003) Nitric oxide and depolarization induce hydroxyl radical generation. *J Pharmacol*, 88: 1-5.
- OHKOHCHI N, MURATA S, TAKAHASHI K (2012) Platelet and liver regeneration, tissue regeneration – from basic biology to clinical application. *Int J Hepatol*, doi: 10.1155/2012/542479.
- OMAR HA, MOHAMED WR, ARAB HH (2016) Tangere-tin alleviates cisplatin-induced acute hepatic injury in rats: Targeting MAPKs and apoptosis. *PLoS ONE*, 11. doi: 10.1371/journal.pone.0151649.
- OZYURT H, YILDIRIM Z, KOTUK M (2004) Cisplatin-induced acute renal failure is ameliorated by erdos-teine in a dose-dependent manner. *J App Toxicol*, 24: 269-275.
- PAK S, KONDO T, NAKANOETAL Y (2010) Platelet adhesion in the sinusoid caused hepatic injury by neutrophils after hepatic ischemia reperfusion. *Platelets*, 21(4): 282-288.
- PALIPOCH S, PUNSAWAD C, KOOMHIN P (2014) Hepatoprotective effect of curcumin and alpha-tocopherol against cisplatin-induced oxidative stress. *BMC Comp Alt Med*, 14: 111. doi: 10.1186/1472-6882-14-111.
- PATEL AN, SELZMAN CH, KUMPATI GS (2016) Evaluation of autologous platelet-rich plasma for cardiac surgery: outcome analysis of 2000 patients. *J Cardiot-horac Surg*, 11-62. doi: 10.1186/s13019-016-0452-9.
- PILZ J, MEINEKE I, GLEITER CH (2000) Measurement of free and bound malondialdehyde in plasma by high-performance liquid chromatography as the 2, 4-dinitrophenylhydrazine derivative. *J Chromatogr B, Biomed Sci Appl*, 742: 315-325.
- PLODERL K, STRASSER C, HENNERBICHLER S (2011) Development and validation of a production process of platelet lysate for autologous use. *Platelets*, 22(3): 204-209.
- RAHMAN I, MCNEE W (2000) Oxidative stress and regulation of glutathione in lung inflammation. *Eur Resp J*, 16(3): 534-554.
- RIOS AD, ANTUNES LM, BIANCHI M (2009) Bixin and lycopene modulation of free radical generation induced by cisplatin-DNA interaction. *Food Chem*, 113: 1113-1118.
- RODRÍGUEZ-FLORES J, PALOMAR-GALLEGO MA, ENGUITA-VALLS AB (2011) Influence of platelet-rich plasma on the histologic characteristics of the autologous fat graft to the upper lip of rabbits. *Aesthet Plast Surg*, 35(4): 480-486.
- SAAD SY, NAJJAR TA, ALASHARI M (2004) Role of nonselective adenosine receptor blockade and phosphodiesterase inhibition in cisplatin-induced nephrogonadal toxicity in rats. *Clin Exp Pharmacol Physiol*, 31: 862-867.
- SALEH RM, WALAA F, AWADIN WF (2014) Renal and cardiovascular damage induced by cisplatin in rats. *Life Sci J*, 11(5): 275-287.
- SALEM SI, ABD EL-BAKY AA, MOHAMMED FF (2017) Cytoprotective effect of silymarin on cisplatin induced hepatotoxicity and bone marrow toxicity in rats. *Asian J Anim Sci*, 11(3): 140-152.
- SALLIE R, TREDGER JM, WILLIAMS R (1991) Drugs and the liver. *Biopharm Drug Dispos*, 12(4): 251-259.
- SANCHEZ M, ANITUA E, CUGAT R (2009) Nonunion treated with autologous preparation rich in growth factors. *J Orthopedic Trauma*, 23(1): 52-59.
- SÁNCHEZ-GONZÁLEZ DJ, MÉNDEZ-BOLAINA E, TREJO-BAHENA NI (2012) Platelet-rich plasma peptides: key for regeneration. *Int J Pept*, 532519.
- SANTOS NA, CATÃO CS, MARTINS NM (2007) Cisplatin-induced nephrotoxicity is associated with oxidative stress, redox state unbalance, impairment of energetic metabolism and apoptosis in rat kidney mitochondria. *Arch Toxicol*, 81:495-504.
- SCHINELLA GR, TOURNIER HA, PRIETO JM, MOR-DUJOVICH DE, BUSCHIAZZO P, RÍOS JL (2002) Antioxidant activity of anti-inflammatory plant extracts. *Life Sci*, 70(9): 1023-1033.
- SHIMEDA Y, HIROTANI Y, AKIMOTO Y (2005) Protective effect of capsaicin against cisplatin-induced nephrotoxicity in rats. *Biol Pharm Bull*, 28: 1635-1638.
- SILVA CR, ANTUNES LMG, BIANCHI M (2001) Antioxidant action of bixin against cisplatin-induced chromosome aberrations and lipid peroxidation in rats. *Pharmacol Res*, 43: 561-566.
- SINHA K, DAS J, PAL PB (2013) Oxidative stress: The mitochondria-dependent and mitochondria independent pathways of apoptosis. *Arch Toxicol*, 87: 1157-1180.
- STILES BL (2009) PI-3-K and AKT: Onto the mitochondria. *Adv Drug Deliv Rev*, 61: 1276-1282.
- TEXTOR J (2014) Platelet rich plasma as a therapeutic agent: Platelet biology, growth factors and a review of the literature. *Lecture notes in bioengineering*, pp 61-94.
- VOGRIN M, RUPREHT M, DINEVSKI D (2010) Effects of platelet gel on early graft revascularization after anterior cruciate ligament reconstruction: A prospective randomized double-blind clinical trial. *Eur Surg Res*, 45(2): 77-85.
- WOLF PL (1991) Biochemical diagnosis of liver disease. *Ind J Clin Biochem*, 14(1): 59-90.
- XIE X, ZHAO S, WU H (2013) Platelet-rich plasma enhances autograft revascularization and reinnervation in a dog model of anterior cruciate ligament reconstruction. *J Surg Res*, 183(1): 214-222.
- YACH ROI, GARASHI I, KIYOSE C (2010) Protective effects of vitamin E analogs against carbon tetrachloride-induced fatty liver in rats. *J Clin Biochem Nutr*, 47(2): 148-154.
- YADAV YC (2015) Hepatoprotective effect of *Ficus religiosa* latex on cisplatin induced liver injury in Wistar rats. *Rev Bras Farmaco*, 25: 278-283.
- YILMAZ, HR, SOGUT S, OZYURT B (2005) The activities of liver adenosine deaminase, xanthine oxidase, catalase, superoxide dismutase enzymes and the levels of malondialdehyde and nitric oxide after cisplatin toxicity. *Toxicol Indust Health*, 21: 67-73.
- ZALDIVAR MM, PAUELS K, VON HUNDELSHAUSE-NETAL P (2010) CXC chemokine ligand 4 (CXCL4) is a platelet-derived mediator of experimental liver fibrosis. *Hepatol*, 51(4): 1345-1353.