

# Massive hiatus hernia associated with scoliosis in a female cadaver

Deepa Somanath, Sudha Ramalingam

Department of Anatomy, Sri Manakula Vinayagar Medical College and Hospital, Puducherry 605 107, India

## SUMMARY

Kyphoscoliosis is often associated with enlarged oesophageal hiatus. It is suggested that this spinal deformity leads to prolonged stretching of the diaphragm causing herniation of abdominal organs, particularly the stomach into the thorax. Such a hiatal hernia can compress thoracic viscera, produce symptoms like shortness of breath and intermittent pain after ingestion of food. This cadaveric report discusses a case of a giant, sliding-type of hiatal hernia accompanied by scoliosis with right-sided deviation of the thoracic aorta and small-sized left lung. All patients presenting gastrointestinal symptoms with coexistence of vertebral column anomalies should be evaluated for the occurrence of intra-thoracic stomach.

**Key words:** Scoliosis – Hiatal hernia – Diaphragm – Intra-thoracic stomach

## INTRODUCTION

Development of diaphragm is completed by the 8th week of foetal life by the fusion of the septum transversum, pleuroperitoneal membranes, dorsal mesentery of the oesophagus and the musculature of the body wall (Kotecha et al., 2012). One of the major openings of the diaphragm is the oesophageal hiatus located at the level of T10 vertebra, formed by the splitting of the right crus of the diaphragm transmitting oesophagus, both vagi and oesophageal branches of left gastric vessels. Herniation of the stomach into the thorax can be due to normal or abnormal oesophageal opening

(Putney, 1948).

The types of congenital hiatus hernia (HH) are shown in Table 1 (Mitiiek and Andrade, 2010).

One of the causes for congenital HH is enlarged oesophageal aperture of the diaphragm (Xia et al., 2017). Herniation of 30% or greater than 50% of the stomach is called intra-thoracic stomach, which is a life-endangering condition causing symptoms like intermittent pain, obstruction, haemorrhage, volvulus, gangrene and dyspnoea due to left atrial compression (Mitiiek and Andrade, 2010; Xia et al., 2017; Reifel et al., 2011; Toydemir et al., 2013; Sahin et al., 2015). Acquired HH can be due to shortness of oesophagus, gastro-oesophageal reflux disease (GERD), kyphoscoliosis (KS), obesity and weakness of diaphragmatic musculature (Reifel et al., 2011; Mitiiek and Andrade, 2010; Talarico and Vlahu, 2015). Previous studies have emphasized the relation between KS and HH. Few authors assumed that axial deviation of the vertebral column at the level of the oesophageal opening can distort the hiatus leading to HH. But some authors opine that decreased intra abdominal volume (IAV) and increased intra abdominal pressure (IAP) can be the predisposing factors for the development of such an anomaly in patients with KS (Talarico and Vlahu, 2015, 2016). These studies report the occurrence of massive HH's in female cadavers associated with kyphoscoliosis.

## CASE REPORT

While a 70-year-old female cadaver was dissected in the Department of Anatomy to study the thoracic region for undergraduate medical students, it was noted that the two-third of the stomach was herniating into the posterior mediastinum. On opening the chest wall, it was found that the heart was displaced anteriorly in close contact with the left rib cage. The left lung was found to be small in

---

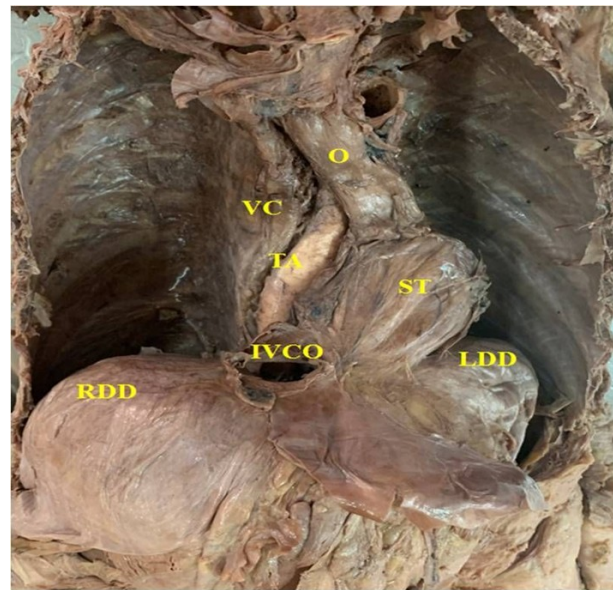
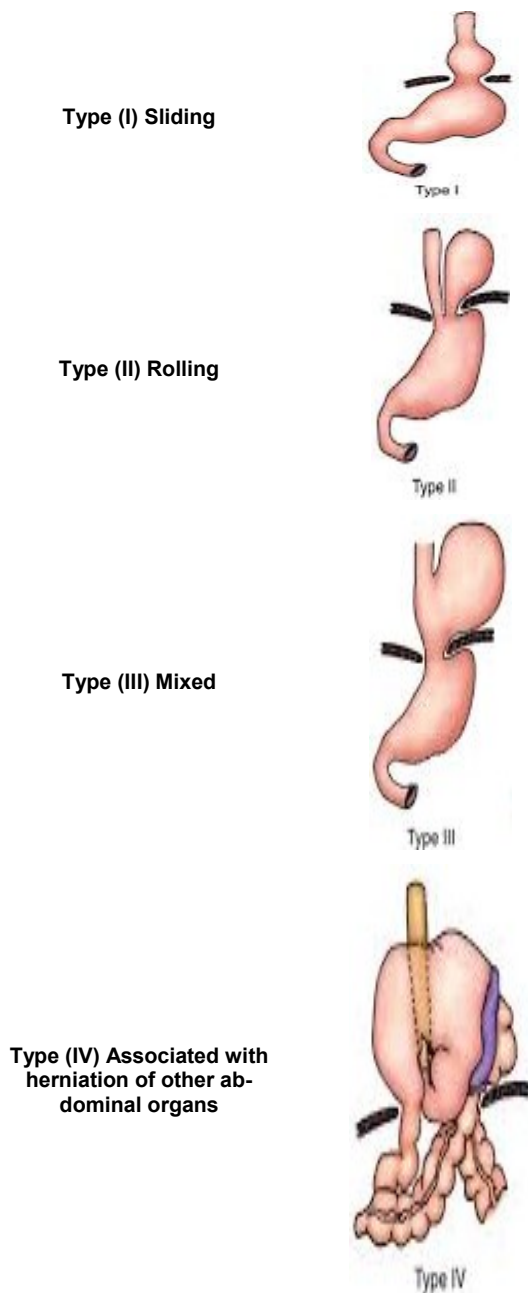
**Corresponding author:** Sudha Ramalingam. Department of Anatomy, Sri Manakula Vinayagar Medical College and Hospital, Puducherry – 605107, India. Phone: 0413-2642016; Fax: 0413-2641549.

E-mail: sudhaanatomy@gmail.com

---

Submitted: 28 February, 2019. Accepted: 15 July, 2019.

**Table 1.** Types of HH with illustration; Type (I) Sliding, Type (II) Rolling, Type (III) Mixed and Type (IV) Associated with herniation of other abdominal organs.



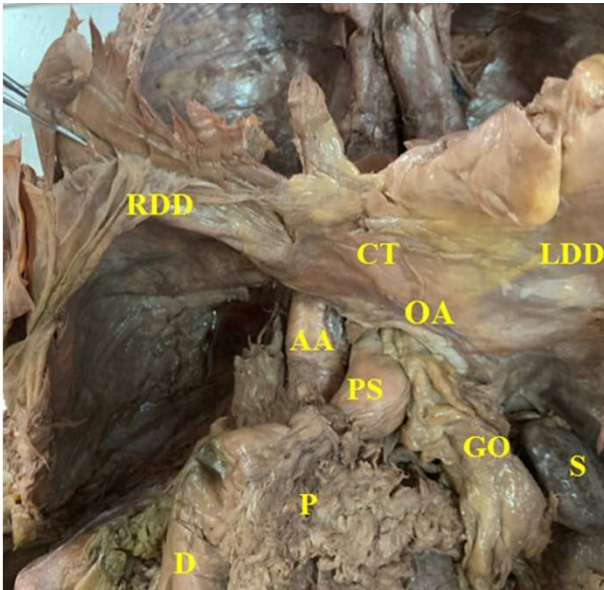
**Fig 1.** Gross anatomy of thorax after reflecting the chest wall. Anterior view of thorax with contents of middle and posterior mediastinum showing intra-thoracic stomach (ST), right lateral deviation of thoracic aorta (TA) and vertebral column (VC). Both the right dome (RDD) and left dome (LDD) of diaphragm are observed. A slightly deviated short oesophagus (O) is seen on the left side of the vertebral column (VC). IVCO: inferior vena caval opening.

the descending thoracic aorta at the level of T5 vertebra. On observing the vertebral column, it showed deviation towards the right side from T7 to T12 vertebra. Hence, the thoracic aorta also followed the course of the spinal column. On subsequent opening of the anterior abdominal wall, a narrow pyloric part of the stomach with a length of 3.2 cm was seen just below the oesophageal hiatus (Fig. 2). The hiatus was abnormally dilated with a width of 5 cm occupying the central tendon of the diaphragm, very close to the inferior vena caval opening. The greater omentum was identified on the left side of pyloric part of the stomach emerging through the oesophageal opening. The aortic opening of the diaphragm slightly shifted to the left of the midline, and thereafter the abdominal aorta was situated in front of the vertebral column. The gastro-duodenal junction was observed on the left side of midline of the body, with the initial part of duodenum placed in normal position. Regarding the vasculature of the stomach, the celiac trunk emerged from the front of the aorta at the usual site and supplied the stomach through its gastric branches, which entered the thorax within the corresponding omenta through the oesophageal hiatus. There was no attachment between stomach and spleen, and hence short the gastric vessels were not visualised.

## DISCUSSION

This case report explains an incidence of giant intra-thoracic stomach associated with scoliosis.

size compared to the normal right lung. After the removal of the pericardium and heart, most of the stomach was located behind the left atrium with upward displacement of gastro-oesophageal junction. The herniated stomach measured 11 cm transversely and 7.5 cm vertically (Fig. 1). The lesser omentum was very short and thin, attached to the lesser curvature of the stomach and did not gain attachment to the liver; but the greater omentum was not seen in the thoracic part of stomach. The displaced gastro-oesophageal junction was found at the level of T7 vertebra. The length of the oesophagus was measured 14 cm from the first rib to the gastro-oesophageal junction and it crossed



**Fig 2.** Gross anatomy of abdomen after reflection of anterior abdominal wall showing the presence of pyloric part of stomach (PS) just below the oesophageal aperture (OA). The oesophageal aperture found extending to the central tendon of diaphragm (CT). The duodenum (D), pancreas (P) and spleen (S) are seen in their normal position. The passage of greater omentum (GO) from thorax into the abdomen through the oesophageal aperture (OA) is visualized. RDD: right dome of diaphragm; LDD: left dome of diaphragm; AA: abdominal aorta.

The aetiology behind intra-thoracic stomach can be due to (i) Presence of gastric mucosa in the lower part of the oesophagus; (ii) Insufficient lengthening of the oesophagus; and (iii) Abnormally large oesophageal hiatus (Xia et al., 2017). It may be also associated with spinal column malformations (Talarico and Vlahu, 2015). Congenital intra-thoracic stomach can be differentiated from HH, based on two factors, namely: presence or absence of peritoneal sac and source of vasculature of the stomach. In case of congenital intra-thoracic stomach, there is absence of peritoneal sac in the thorax, with segmental supply from aorta and normal left gastric artery. In HH, there is peritoneal sac with supply from long, left gastric artery passing through the oesophageal hiatus. In this study, the oesophagus was short with nearly half of the original length, which might be due to longstanding HH, which has pushed the oesophagus leading to apparently short oesophagus and, additionally, it also leads to the compression of the left lung. The peritoneal sac was in the posterior mediastinum with omenta containing normal vasculature. There is a positive correlation between spinal column anomalies and HH. Kyphoscoliosis can be the reason for the shift of aortic opening to the right of the midline, which could have stretched the diaphragm, causing enlarged oesophageal hiatus (Talarico and Vlahu, 2015).

Talarico and Vlahu documented two cases of

giant HH. In the first case, they reported the herniation of the entire stomach into the posterior mediastinum, combined with rotation of the vertebral column to the left of the midline at the level of T1 to L5 vertebrae, with degree of rotation ranging from 4° at T1 to 29° at L5 towards the left side. The degree of curvature of the spine was assessed using Cobb method. The dextro-thoracic scoliosis was measured to be 45°, levo-lumbar scoliosis was 34° and thoracic kyphosis was 78°. The IAV was calculated to be 2360 cm<sup>3</sup> or 29.8 % less than that of normal cadavers (Talarico and Vlahu, 2015).

In the second case, he described Type IV HH with herniation of most of the duodenum and pancreatic head into the thorax associated with KS which showed rotation of thoracic and lumbar vertebrae to the left and right of the midline respectively. The thoracic dextro-scoliosis, levo-lumbar scoliosis and thoracic kyphosis were found to have Cobb Angles of 61°, 39° and 37° respectively and the rotation of spinal column was seen from T1 to L5. The IAV was recorded 63% less than that of normal cadavers (Talarico and Vlahu, 2015, 2016). In the present case, a three-fourth of the stomach was seen herniated into the posterior mediastinum, except the pyloric part accompanied by deviation of spinal column from T7 to T12. Moreover, the oesophageal aperture was predominantly fibrous. Hence, an insufficient sphincter mechanism would have failed to keep the gastro-oesophageal junction at its normal anatomical location. Patients with KS are found to have decreased IAV and increased IAP. It is considered that KS may be the cause for the development of decreased IAV, thereby leading to slackness of the musculature of the diaphragm around the oesophageal hiatus, which accounts for the para-oesophageal hernia. Variation in the fibre components of the peri-oesophageal ligaments is one of the factors for the occurrence of HH. It is stated that reduced collagen Type I- to-Type III ratio and low amount of elastic fibers in the ligaments supporting the gastro-oesophageal junction are associated with HH (Talarico and Vlahu, 2015, 2016). Ehlers-Danlos syndrome Type 6 is an autosomal recessive disorder characterised by defective collagen biosynthesis due to the deficiency of the enzyme lysyl hydroxylase, which results in infirmness of connective tissues like skin, ligaments and cartilage which leads to a group of symptoms and marked KS as well (Talarico and Vlahu, 2016). Therefore, it can be postulated that the present case might have suffered from connective tissue disorder which could have contributed for the manifestation of KS and HH.

**Conclusion.** Previous studies have documented the association between scoliosis and HH. Patients with chronic KS have to be investigated for such anomalies if the patient presents with gastrointestinal complaints. Clinical evaluations should

consist of past history, barium swallow and oesophagoscopy. Routine investigation like X-ray chest would confirm the presence of HH by the presence of retro-cardiac air bubble. The possibility of torsion, position, size and vascularity of HH should be determined by CT Scan, MRI and Doppler study to assess the progress of the disease.

#### ACKNOWLEDGEMENTS

The authors would like to thank the management for the consent to use the facilities of the department.

#### Abbreviations:

KS - Kyphoscoliosis  
HH - Hiatal hernia  
IAV - Intra abdominal volume  
IAP - Intra abdominal pressure  
O - oesophagus  
VC - vertebral column  
TA - thoracic aorta  
ST - stomach  
RDD - right dome of diaphragm  
LDD - left dome of diaphragm  
IVCO - inferior vena caval opening  
CT - central tendon  
AA - abdominal aorta  
PS - pylorus of stomach  
GO - greater omentum  
P - pancreas  
S - spleen  
D - duodenum  
OA - tendinous margin of oesophageal aperture

#### Author's contribution:

Deepa Somanath and Sudha Ramalingam contributed to the conceptualisation, the design of the study, the collection of data, interpretation, analysis of the results and writing of the manuscript.

#### REFERENCES

KOTECHA S, BARBATO A, BUSH A, CLAUS F, DAVENPORT M, DELACOURTE C, DEPREST J, EBER E, FRENCKNER B, GREENOUGH A, NICHOLSON AG, ANTÓN-PACHECO JL, MIDULLA F (2012) Congenital diaphragmatic hernia. *Eur Respir J*, 39: 820-829.

MITIEK MO, ANDRADE RS (2010) Giant hiatal hernia. *Ann Thorac Surg*, 89: S2168-2173.

PUTNEY FJ (1948) Thoracic stomach produced by oesophageal hiatus hernia and congenital short oesophagus. *Ann Intern Med*, 28(6): 1094-1105.

REIFEL CW, LYONS GW, BOYD S, SITU D, TEMKIN R, PANG S C (2011) Thoracic stomach in a centenarian female cadaver. *J Anat*, 198: 505-507.

SAHIN C, AKIN F, CULLU N, ÖZSEKER B, KIRLI E, ALTUN E (2015) A large intra-abdominal hiatal hernia as a rare cause of dyspnea. *Case Rep Cardiol*, 2015:546395.

TALARICO EF JR, VLAHU AC (2015) Characterization of kyphoscoliosis and associated giant hiatal hernia in a 97-year-old female cadaver. *Eur J Anat*, 19(3): 257-268.

TALARICO EF JR, VLAHU AC (2016) Kyphoscoliosis and hiatal hernia: Anatomical analysis stimulates new clinical interest. *Eur J Anat*, 20(1): 93-97.

TOYDEMIR T, ÇIPE G, KARATEPE O, YERDEL MA (2013) Laparoscopic management of totally intra-thoracic stomach with chronic volvulus. *World J Gastroenterol*, 9(35): 5848-5854.

XIA B, HONG C, TANG J, LIU C, YU G (2017) Congenital diaphragmatic hernia in association with congenital short oesophagus. *Medicine*, 96: 51.