

Effect of methanol seed extract of *Buchholzia coriacea* on the left ventricle myocardium of zidovudine-induced cardiotoxic Wistar rats

Josiah T. Mosaku¹, Aderibigbe O. Komolafe¹, Rotimi A. Owolabi², Ayodeji S. Odukoya¹, Stephen O. Saka¹, Atinuke O. Anjorin¹

¹ Department of Anatomy and Cell Biology, ² Department of Medical Pharmacology and Therapeutics, Faculty of Basic Medical Sciences, Obafemi Awolowo University (OAU), Ile Ife, Osun-State, Nigeria

SUMMARY

The degenerative and inflammatory changes were reported in cardiac tissues of rats exposed to zidovudine (ZDV). This study was designed to examine the histochemical changes in the myocardium of adult Wistar rats exposed to ZDV and administered with methanolic extract of *Buchholzia coriacea* (MEBC) seed. Forty-eight healthy Wistar rats weighing 150-155 g. were randomly assigned into eight groups of six rats each. Group A served as control and received distilled water; group B received 100 mg/kg of ZDV; group C received 600 mg/kg of MEBC; group D received 100 mg/kg of vitamin C; group E received 100 mg/kg of vitamin C and ZDV; group F received 150 mg/kg of MEBC and 100 mg/kg of ZDV; group G received 300 mg/kg of MEBC and 100 mg/kg of ZDV, and group H received 600 mg/kg of MEBC and 100 mg/kg of ZDV. Treatment lasted for a period of 56 days. Blood was collected separately into clean capped plain tubes for biochemical parameters. Hearts

were excised, fixed in 10% formal saline and processed for histology. ZDV induced a significant increase in the serum concentration of Nitric Oxide (NO) and Cardiac Troponin I (cTnI) in the ZDV-alone group when compared to control ($p < 0.05$). Also, there was reduction in activity of the Glutathione reductase (GR) enzyme in the ZDV-alone group relative to control ($P = 0.0006$, $F = 7.0$). Distortion of the cross banding pattern of cardiac muscle fibres in ZDV-alone group was manifested. These effects were reversed by administration of MEBC compared to vitamin C group.

Key words: *Buchholzia coriacea* – Zidovudine – Heart – Cardiotoxic

INTRODUCTION

Human immunodeficiency virus and acquired immune deficiency syndrome (HIV/AIDS) are a spectrum of conditions caused by infection with the human immunodeficiency virus (William, 2008;

Corresponding author: Mosaku, Josiah Tolulope, M.Sc. Department of Anatomy and Cell Biology, Faculty of Basic Medical Sciences, Obafemi Awolowo University (OAU), Ile Ife, Osun-State, Nigeria. Phone: +2347036481164
E-mail: mosakutolulope30@gmail.com

Submitted: 27 October, 2019. Accepted: 19 February, 2020.

Alexander et al., 2010). In 2015, about 36.7 million people were living with HIV, with 2.1 million new infections and 1.1 million AIDS-related deaths. Between its discovery and 2015, HIV has infected over 78 million persons and has caused an estimated 35 million deaths (Global Aids, 2015). In Nigeria, an estimated 3.5 million people live with HIV/AIDS, with the number of deaths recorded in 2015 due to HIV/AIDS reaching some 180,000 (Global Aids, 2015). HIV/AIDS is a fatal disease with new antiretroviral (ARV) drugs helping relieve symptoms, or prolong the survival period (William, 2008).

Among all the ARV agents, zidovudine (ZDV) was the first to be approved by the Food and Drug Administration in 1987, and it remains an important component of Highly Active Antiretroviral Therapy (HAART) (Cimons, 1987), and has also been used in the treatment of breast cancer (Carston et al., 1997). ZDV is used along with other medications by health workers after accidental contact with HIV-contaminated blood, tissues, or other body fluids (David et al., 2013). Early long-term higher-dose therapy with ZDV was associated with tissue toxicities that included anaemia (haemoglobin less than 8 g/dL; up to 1.1%), neutropenia, hepatotoxicity, cardiotoxicity, myopathy and lactic acidosis that were serious enough to discontinue therapy in about 25 to 30% of patients (Thaczuk et al., 2014). These conditions were found to be reversible upon reduction of ZDV dosage. Degenerative and inflammatory changes were reported in cardiac tissues of rats exposed to ZDV for two weeks (Vija et al., 2006). These CVS changes were attributed to the drug-induced oxidative stress leading to mitochondrial dysfunction (Vija et al., 2006).

Available remedies for Zidovudine-induced Cardiotoxicity (ZIC) include reducing ZDV dose from 1,200 mg per day to 600 mg per day (Banhart, 1990), administering ZDV with a second Nucleotide Reverse Transcriptase Inhibitor (NRTI) and a viral Persistently Infected (PI) the concomitant use of ZDV and vitamin C, a known antioxidant drug (Italia et al., 2006). As a result, ZIC has become a rare event in Highly Active Antiretroviral Therapy and main toxicities have been limited to lipodystrophy and cytopenias (Deveaud et al., 2005; Moh et al., 2005). Still, ZDV monotherapy is currently used to prevent the transmission of HIV from mothers to their babies prior to delivery and during the baby's first postnatal month (Sia et al., 2004). ZDV is also a mainstay of HIV treatment in many developing nations (Stringer et al., 2006).

Buchholzia coriacea (BC) seed has been reported to have phytochemicals such as alkaloids, tannins, anthraquinones, terpenoid, saponins, glycosides, steroids, and reducing sugars (Anie et al., 2015). As a result, it is used for various ailments that include hypertension, premature ageing, conjunctivitis, rheumatism, scabies, haemorrhoids,

snake bites, fever, diabetes, cough and many others (Lemmens et al., 2013). The methanolic seed extract of BC has been reported to have abundant antioxidant properties (Nweze, 2011). This study investigated the biochemical activities and the effects of methanol seed extracts of *buchholzia coriacea* (buchholz) on the histology of zidovudine-induced cardiotoxic of the left ventricle in adult Wistar rats.

MATERIALS AND METHODS

Plant material and preparation of extract

BC seeds were procured from a local farmer at Lawoka Government Reserve Area, Ife South, Ile-Ife, Osun State. It was identified by a taxonomist at the Department of Botany, Obafemi Awolowo University, Ile-Ife, Osun State, Nigeria with Herbarium Voucher No 17536.

Seeds were washed, chopped into pieces, air-dried and grounded into powder. The powdered seed was soaked in 60% methanol and shaken on a vibrator for 4 days at ambient temperature. The mixture was filtered and evaporated at 50°C while the yield was stored in a desiccator until use (Alani et al., 2005).

Animal treatment

Forty-eight healthy Wistar rats (150-155 g) from the Animal Holding of College of Health Sciences, Obafemi Awolowo University Ile-Ife were used for this study. The rats were randomly assigned into 8 groups of 6 rats each (Groups A, B, C, D, E, F, G, and H). They were maintained on standard laboratory rat pellet before the commencement of the experiment and water was provided ad libitum.

Rats in group A served as control and received only distilled water. Rats in group B received 100 mg/kg body weight of ZDV. Rats in group C received 600 mg/kg body weight of MEBC. Rats in group D received 100 mg/kg body weight of vitamin C. Rats in group E received 100 mg/kg of vitamin C and 100 mg/kg of ZDV. Rats in group F received 150 mg/kg of MEBC and 100 mg/kg of ZDV. Rats in group G received 300 mg/kg of MEBC and 100 mg/kg of ZDV. Finally, rats in group H received 600 mg/kg of MEBC and 100 mg/kg of ZDV. The extract solution was administered through an oral cannula and the duration of the experiment was 56 days. ZDV (manufactured under the trade name Retrovir by GlaxoSmithKline) was obtained from the Department of Pharmacy, Public Health Unit of Wesley Guild, Obafemi Awolowo University Teaching Hospital, Ilesa, Nigeria. Ethical approval was obtained from the Health Research Ethic Committee (HREC), Institute of Public Health, Obafemi Awolowo University, Ile-Ife, Nigeria with HREC number IPHO-AU/12/666.

Animal groupings

Groups	Test Drugs
A	Distilled water
B	ZDV 300
C	MEBC 600
D	Vitamin C 100
E	Vitamin C (100 mg/kg) +
F	MEBC (150 mg/kg) +
G	MEBC (300 mg/kg) +
H	MEBC (600 mg/kg) +

Sacrifice of Animals

Twenty-four hours following the final administration, rats were sacrificed under ketamine (30 mg/kg) anesthesia. Blood samples were collected from each animal through cardiac puncture into sample bottles with the aid of non-heparized capillary tubes. The blood samples were centrifuged at 2000 rpm at 4°C for 20 min. Serum was frozen until the biochemical determination was performed. A midline incision was made through the thorax, the heart was excised and tissue from the left ventricle was separated by a transverse section through the midpoint between the apex and the base of the heart.

Histological techniques

The excised heart tissue was fixed 10% formal saline for 48 hours, and processed using paraffin wax embedding method. Sections of 5 µm thickness were cut from the paraffin-embedded tissues and stained with haematoxylin and eosin stain to demonstrate the general histoarchitecture of the left ventricle, Verhoeff-Van Gieson stain was used to demonstrate elastic fibers in the left ventricle, Sudan Black-B was used to demonstrate lipochrome pigments and Toluidine blue was used to demonstrate mast cells.

Verhoeff - Van Gieson Stain

Slides were brought into distilled water, stained in Verhoeff's solution for an hour, thereby rendering black tissue coloration, then rinsed in tap water with 2-3 changes and differentiated in 2% ferric chloride solution for 1-2 minutes. Therefore, slides were washed in tap water, treated for a minute in 5% sodium thiosulphate solution, after which the solution was discarded and washed for 5 minutes in running tap water. Then they were counterstained in Van Gieson's solution for 3-5 minutes and dehydrated quickly through 95% alcohol for 2 changes of absolute alcohol which later cleared in 2 changes of xylene for 3 minutes each, and finally coverslipped with resinous mounting medium.

Sudan Black B

Sections were washed in three exchanges of tap water and dehydrated in 100% propylene glycol for

5 minutes, which was treated in propylene glycol and decanted while Sudan Black B was added and stained overnight. It was washed in three exchanges of tap water, differentiated in 85% propylene glycol for 3 minutes, rinsed several times with tap water and coverslipped with the aqueous mounting medium onto a labelled glass slide.

Toluidine Blue

This was used to demonstrate mast cells, which are found widely distributed in the connective tissue. Their cytoplasm contains granules composed of heparin and histamine, which are metachromatic. Sections were deparaffinised, hydrated in distilled water and stained in working Toluidine blue stain for 2 minutes. It was rinsed in 3 changes of distilled water, dehydrated rapidly in 95% and absolute alcohols. It was cleared in xylene and Coverslipped using an aqueous mountant.

Periodic acid Schiff

PAS staining was also carried out on all the experimental groups to demonstrate the presence of glycogen on the myocardium of the left ventricle. Sections were deparaffinized and hydrated to water. The sections were then oxidized in 0.5% periodic acid solution for 5 min after, which were rinsed in distilled water. After the sections were placed in Schiff reagent for 15 min (sections became lightpink color during this step), they were washed in lukewarm tap water for 5 min (immediately sections turned dark pink color). They were counterstained in Mayer's hematoxylin for 1 min, washed in tap water for 5 min and then dehydrated and coverslipped using asynthetic mounting medium.

Determination of nitric oxide levels in serum

At the end of the experiment, the serum was separated from the blood by centrifugation at 3,000g for 10 min. The serum NO levels were determined using Nitric oxide assay kit for the colorimetric determination of total nitrite (Bioassays Systems, USA).

Glutathione Reductase activity (GR)

GR activity was assayed by the method of Sharma et al. (2001). The assay mixture consisted of 1.6 ml of sodium phosphate buffer (0.1M, pH 7.4), 0.1 ml EDTA (1mM), 0.1 ml of 1mM oxidized glutathione, 0.1ml of NADPH (0.02mM), 0.01 ml of 1mM H₂O₂ and 0.1 ml PMS in a total volume of 2 ml. The enzyme activity measured at 340 nm was calculated as nmoles of NADPH oxidized/min/mg of protein using ϵ of $6.22 \times 10^3 \text{ M}^{-1} \text{ cm}^{-1}$.

Cardiac Troponin I Assay (cTnI)

The desired number of coated wells was secured in the holder. 100 ml of cTnI horseradish peroxidase (HRP) Conjugate was dispensed into each well. 100 ml of standards and samples was dispensed

into the appropriate wells. This was thoroughly mixed for 10-15 seconds. This was incubated on an orbital shaker (150 rpm) at room temperature (18-25°C) for 60 minutes. The incubation mixture was removed by flicking the plate contents into a bio-waste container. The microtiter wells was washed and emptied 5 times with 1 wash solution. This was performed using plate washer (400 ml/well). The entire wash procedure was carried out.

Photomicrography

Stained sections were viewed under a Leica DM750 microscope (Leica Microsystems, Heerbrugg, Switzerland) with digital camera attached (Leica ICC50), and digital photomicrographs were taken at various magnifications. Photomicrographs of stained sections were imported onto the ImageJ version 1.48 (NIH, Bethesda, MD, USA) software for elastic cell quantification.

Quantification of staining intensity

Image analysis and processing for Java (ImageJ), was used to analyze and quantify Verhoeff-Van Gieson staining intensity. Imported RGB images were converted to grayscale images on ImageJ. The software quantifies staining intensity by measuring the pixel value of each pixel in grayscale images following threshold of areas of staining activity and converting the pixel value to brightness value or gray value, in a scale of 0 to 255 from less brighter (that is more intensity) to more brighter (that is less intensity).

Statistical analysis

One-way ANOVA was used to analyze data, followed by Tukey test for multiple comparisons.

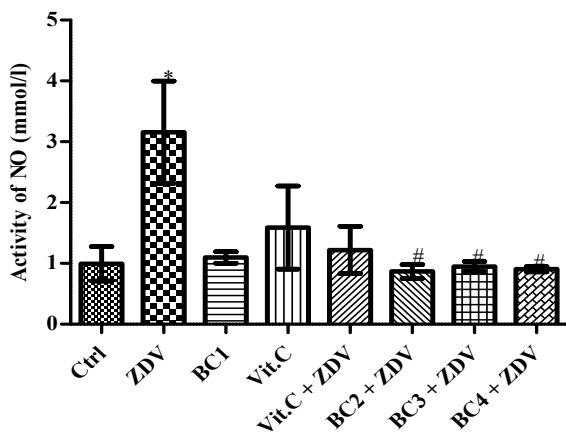


Fig 1. Activity of NO in the control and treated groups. Group A (Control), group B (ZDV) (100 mg/kg Zidovudine), group C (BC1) (600 mg/kg MEBC), group D (Vit. C) (100 mg/kg Vitamin C), group E (Vit. C + 100 mg/kg ZDV), group F (BC2) (150 mg/kg MEBC + ZDV), group G (BC3) (300 mg/kg MEBC + ZDV), group H (BC4) (600 mg/kg MEBC + ZDV). □ ZDV induced a significant increase in the concentration of NO in the ZDV-alone group relative to control. # MEBC induced a significant reduction in the concentration of NO in the MEBC-intervention groups relative to ZDV-alone group and comparable to control. $p = 0.02$, $F = 3.30$.

GraphPad Prism 5 (Version 5.03; Graphpad Software Inc., San Diego, CA) was the statistical package used for data analysis. Statistically significant difference was set at $p < 0.05$.

RESULTS

ZDV induced a significant increase in the serum concentration of NO in the ZDV-alone group relative to control ($p < 0.05$). However, MEBC induced a significant statistical reduction ($p < 0.05$) in the concentration of NO in the MEBC intervention groups relative to the ZDV-alone group to a level that is comparable to the control ($P = 0.02$, $F = 3.30$) (Fig. 1). ZDV induced a significant statistical reduction ($p < 0.05$) in the activity of the GR enzyme in the ZDV alone group relative to control. MEBC induced a significant statistical ($p < 0.05$) increase in the activity of the GR enzyme in the MEBC alone group relative to the ZDV-alone group ($P = 0.0006$, $F = 7.0$) (Fig. 2). ZDV induced a significant statistical ($p < 0.05$) increase in the concentration of cTnI in the ZDV-alone group relative to the control ($P = 0.05$, $F = 2.60$). This effect was reversed in the MEBC intervention groups (Fig. 3).

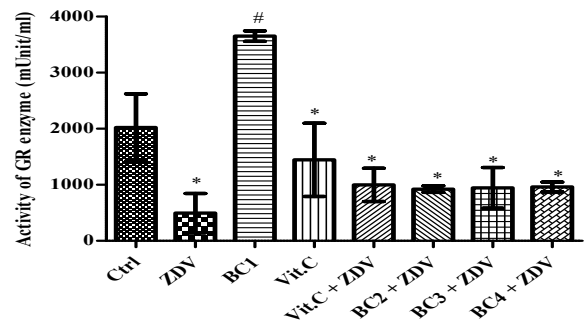


Fig 2. Activity of Glutathione reductase enzyme in control and treated groups. * ZDV induced a significant reduction in the activity of the GR enzyme in the ZDV-alone group relative to control. Also, there was a significant statistical reduction in the activity of GR enzyme in the Vit. C group as well as the various MEBC-intervention groups relative to control. # MEBC induced a significant statistical increase in the activity of GR enzyme in the MEBC alone group relative to ZDV-alone group. $P = 0.0006$, $F = 7.0$.

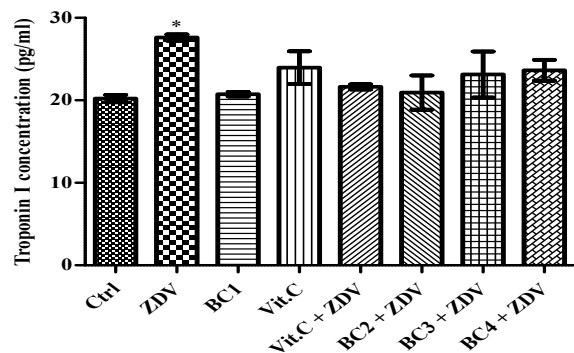


Fig 3. Concentration of cTnI in control and treated groups. * ZDV induced a significant increase in concentration of cTnI in the ZDV-alone group relative to control. $P = 0.05$, $F = 2.60$.

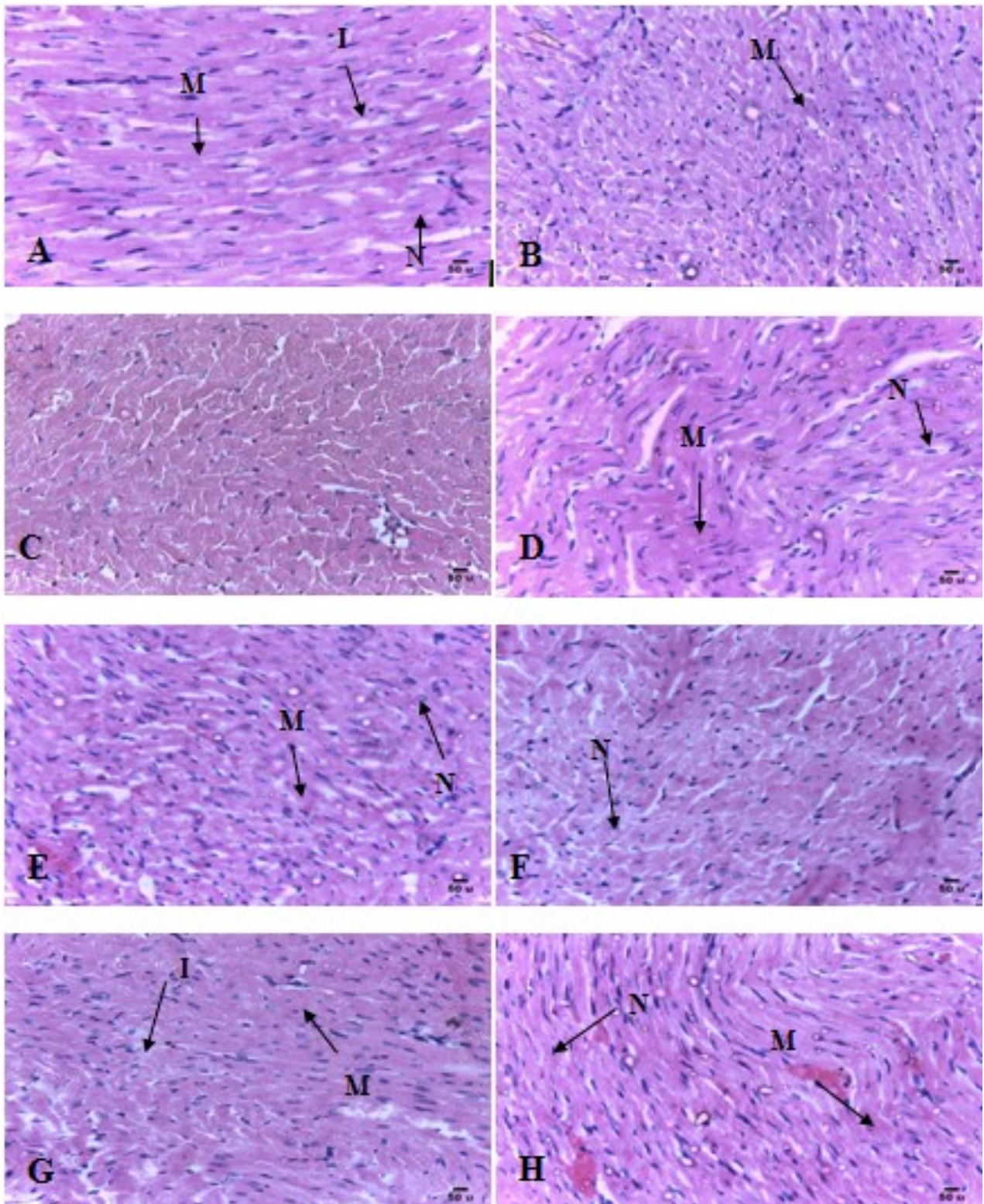


Fig 4. (A-H): Longitudinal sections of the left ventricle of rats showing arrangements of cardiac muscles. **A** (Control), **B** (100 mg of ZDV), **C** (600 mg of BC), **D** (100 mg of Vitamin C), **E** (100 mg of Vitamin C + 100 mg of ZDV), **F** (150 mg of BC + 100 mg of ZDV), **G** (300 mg of BC + 100 mg of ZDV), **H** (600 mg of BC + 100 mg of ZDV). H&E staining, x 400, scale bars = 50 µm. N: Nucleus, M: Muscle fibre, I: Inflammatory cells, Ne: Necrosis, D: Displaced nucleus.

Histological findings

Histological finding shows distortion of the cross banding pattern of cardiac muscle fibres with displacement of cell nuclei and evidence of tissue necrosis in the ZDV-alone group. Results of Ima-

geJ software analysis on the deposition of elastic fibres on Verhoeff-Van Gieson's stain showed significant reduction in elastic fibres composition in the ZDV-alone group relative to control. There was accumulation of lipochrome pigments and mast

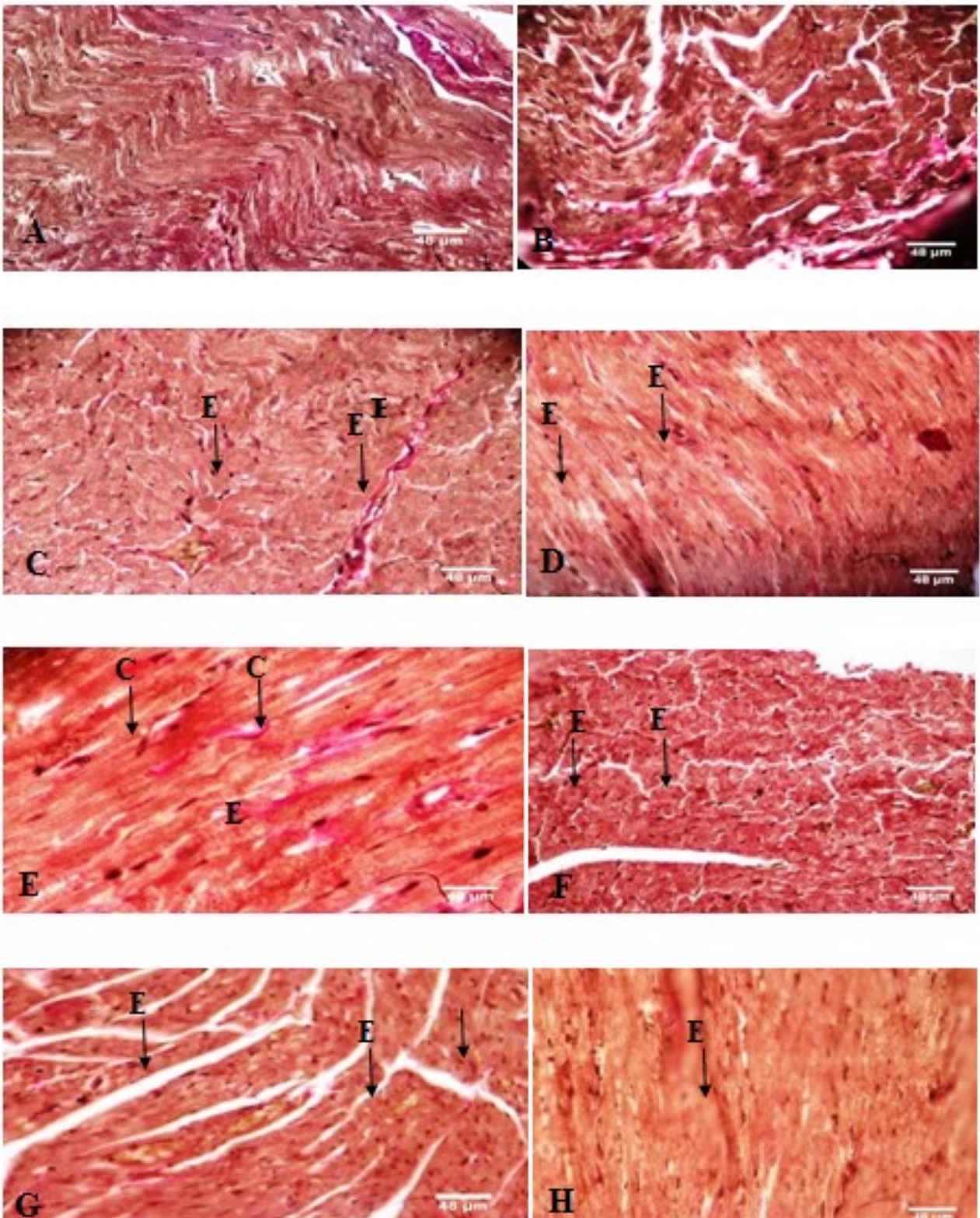


Fig 5. (A-H): Longitudinal sections of the left ventricle of rats showing arrangements of cardiac muscles. **A** (Control), **B** (100 mg of ZDV), **C** (600 mg of BC), **D** (100 mg of Vitamin C), **E** (100 mg of Vitamin C + 100 mg of ZDV), **F** (150 mg of BC + 100 mg of ZDV), **G** (300 mg of BC + 100 mg of ZDV), **H** (600 mg of BC + 100 mg of ZDV). VVG staining, x 400, scale bars = 48 μ m. E: Elastic fibers, C: Collagen fibers.

cells in the ZDV-alone group. MEBC treatment was able to restore the structural cellular integrity of myocardial cells to a state comparable with the known antioxidant drug, vitamin C.

DISCUSSION

This study investigated the effects of the co-administration of methanolic extract of MEBC

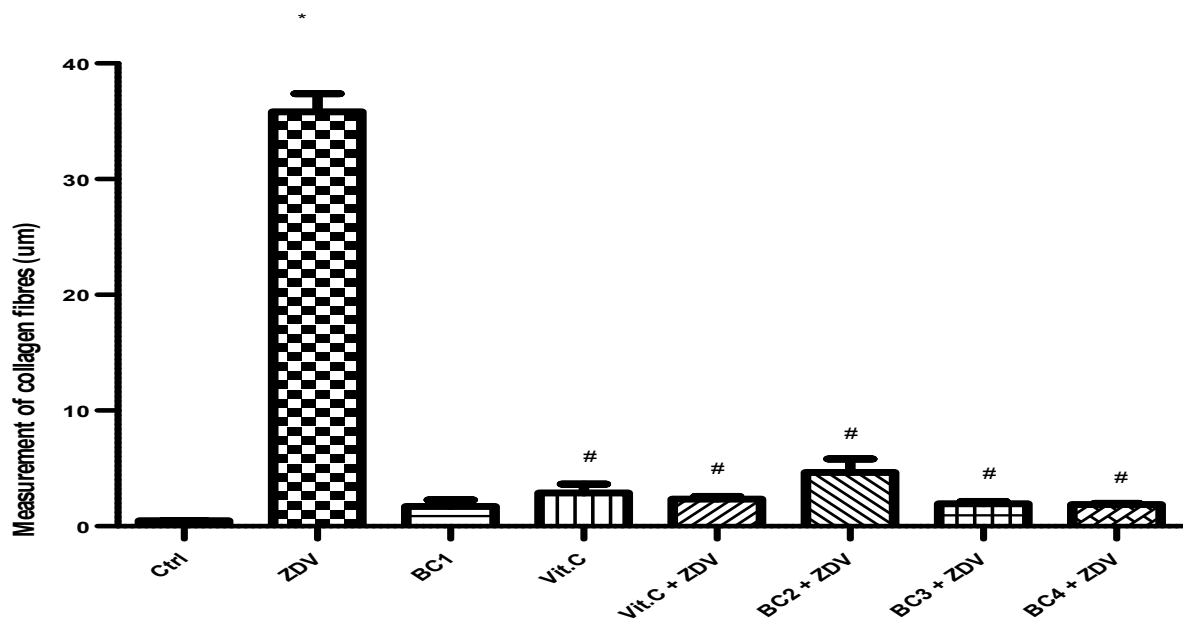


Fig 6. Measurement of the collagen fibres ZDV (Zidovudine), BC (*Buchholzia coriacea*). * ZDV induced a significant increase in the deposition of collagen fibres in the ZDV group relative to control. # BC induced a significant decrease in the deposition of collagen fibres in the BC intervention groups relative to control and comparable with the vitamin C groups. $P < 0.0001$, $F = 242$.

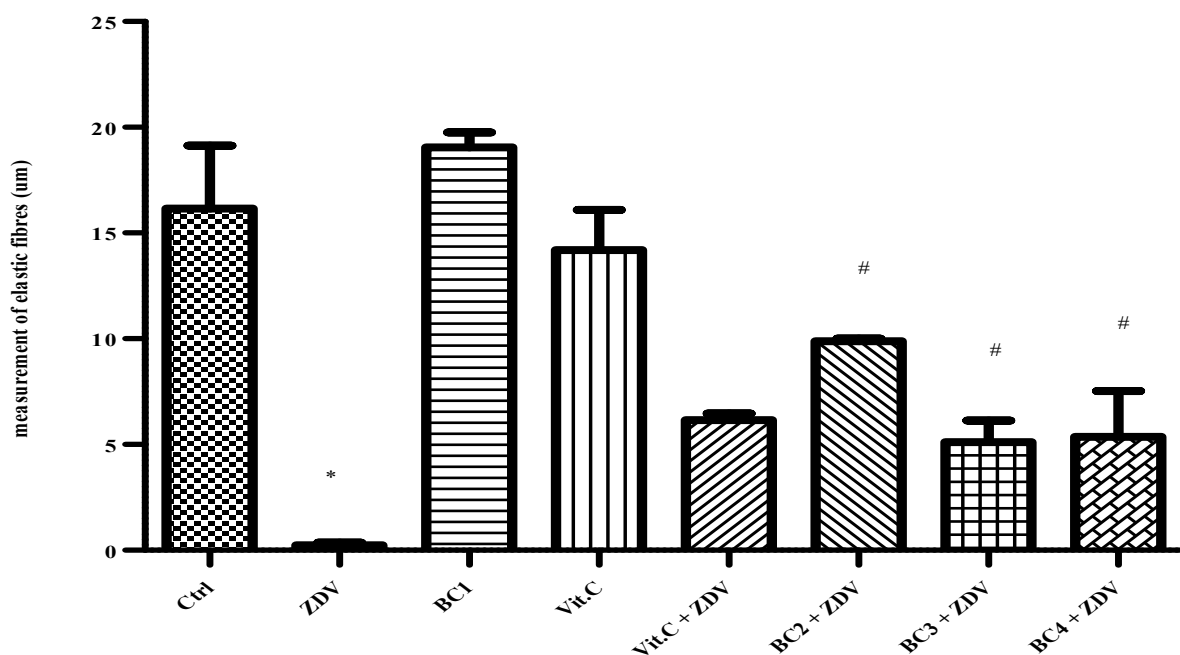


Fig 7. Measurement of elastic fibres. ZDV (Zidovudine), BC (*Buchholzia coriacea*). * ZDV induced a significant decrease in the deposition of elastic fibres in the ZDV group relative to control. # ZDV induced a significant decrease in the intervention groups relative to control. $P = 0.0003$, $F = 18$.

seeds and zidovudine on the left ventricle of adult Wistar rats. The result shows that the administration of ZDV for fifty-six days induced a significantly high ($p < 0.05$) concentration of NO in the ZDV-alone group relative to control (Beltran et al., 2003). It was also reported that ZDV caused degradation of mitochondrial Thymidine Kinase 2

(TK2) which led to a depletion of mitochondrial DNA, dysfunctional mitochondrial energy metabolism and subsequently oxidative stress (Ren et al., 2014). Some findings also supported that ZDV with oxidative stress produced some cardiovascular effects such as atherosclerosis (Jiang et al., 2007; Jiang et al., 2009; Balcarek et al., 2010; Yamagu-

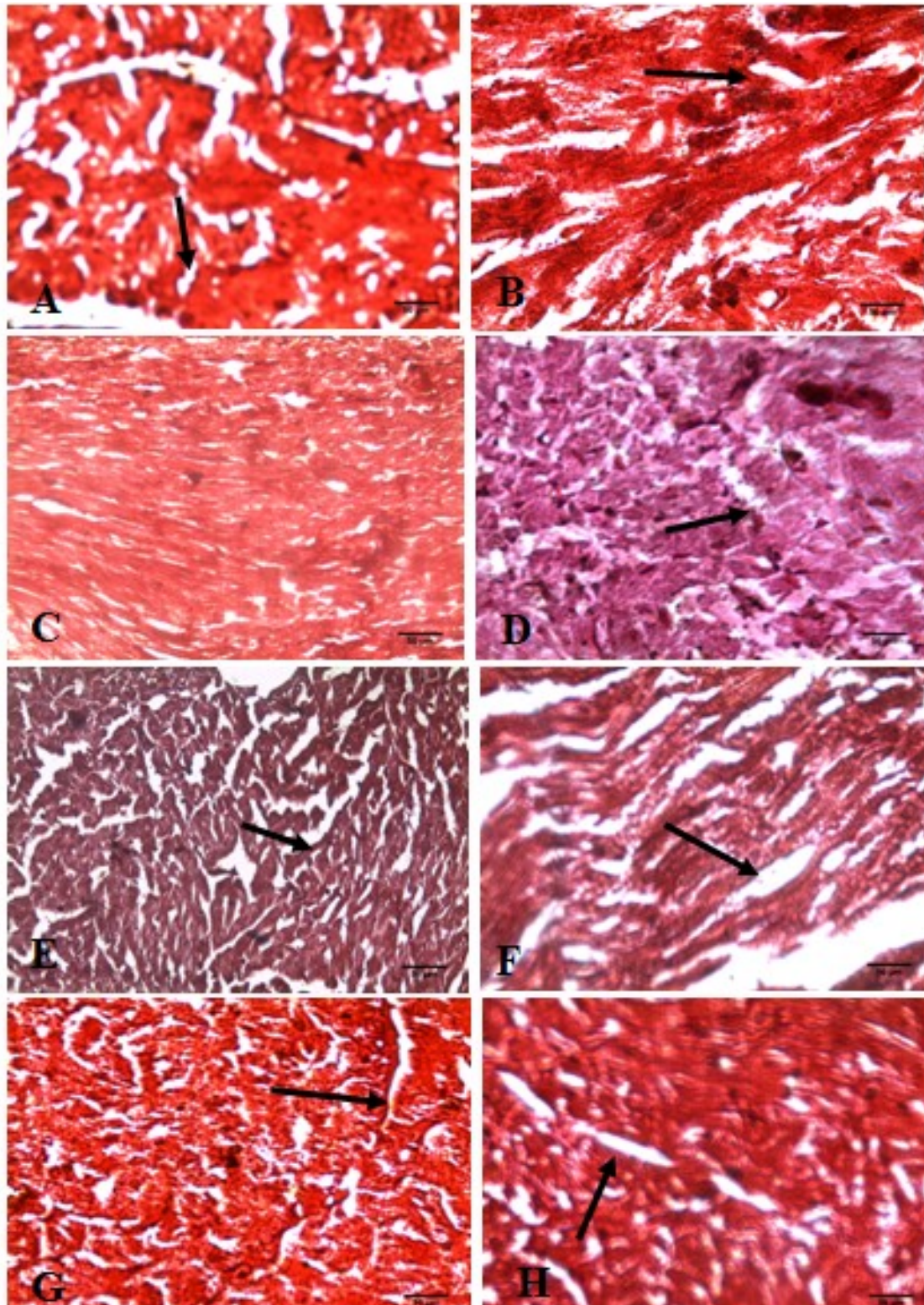


Fig. 8.- (A-H): Longitudinal sections of the left ventricle of rats showing arrangements of cardiac muscles. **A** (Control), **B** (100 mg of ZDV), **C** (600 mg of BC), **D** (100 mg of Vitamin C), **E** (100 mg of Vitamin C + 100 mg of ZDV), **F** (150 mg of BC + 100 mg of ZDV), **G** (300 mg of BC + 100 mg of ZDV), **H** (600 mg of BC + 100 mg of ZDV). SBB staining, x 400, scale bars = 50 μ m. Black arrows: lipochrome pigments.

chi et al., 2002).

Activity of serum glutathione reductase (GR) enzyme, whose function is to prevent and or eliminate the build-up of Reactive Oxygen Species (ROS), which had declined significantly in the ZDV-alone

group, further confirms oxidative stress as the mechanism of ZIC (Wu et al., 2004). Other studies have implicated mtDNA depletion, apoptosis and oxidative stress as possible mechanisms of ZIC (de la Asuncion, 2004; Wheeler et al., 2005; Lewis

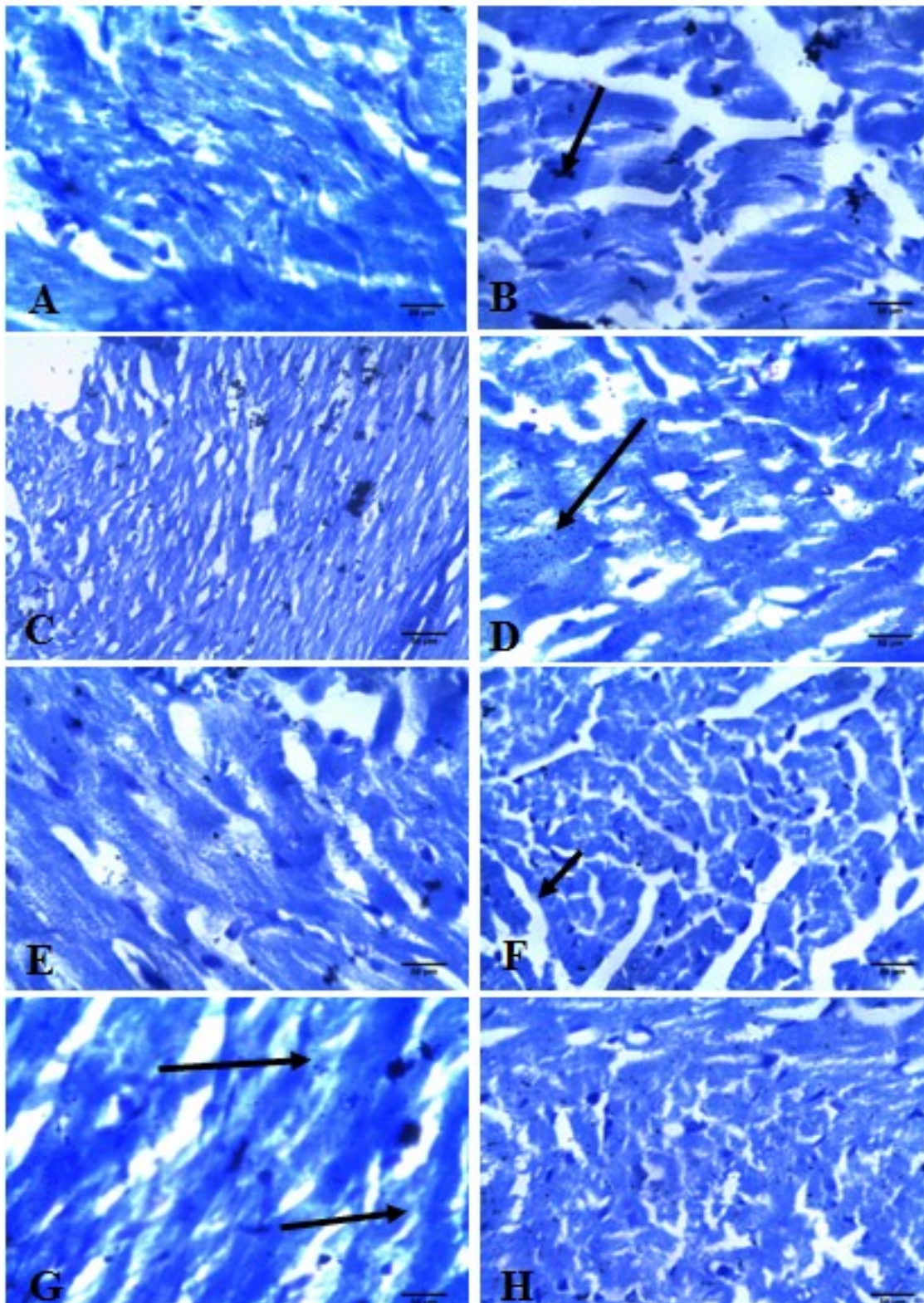


Fig. 9.- (A-H): Longitudinal sections of the left ventricle of rats showing arrangements of cardiac muscles. **A** (Control), **B** (100 mg of ZDV), **C** (600 mg of BC), **D** (100 mg of Vitamin C), **E** (100 mg of Vitamin C + 100 mg of ZDV), **F** (150 mg of BC + 100 mg of ZDV), **G** (300 mg of BC + 100 mg of ZDV), **H** (600 mg of BC + 100 mg of ZDV). TB staining, x 400, scale bars = 50 µm. Black arrows: Mast cells.

et al., 2007).

The result also shows that vitamin C prevented the build-up of ROS and exerted a protective role against cardiovascular complications associated with ZDV therapy (Italia et al., 2006).

To confirm cardiac injury, analysis of cardiac Troponin-I (cTnI), a specific biomarker of cardiac injury, revealed significant elevation in the serum level of cTnI in the ZDV-alone group relative to control

(Andleeb et al., 2014).

The results on the histology of myocardial tissues of the MEBC and Vitamin-C-alone groups was able to restore the normal myocardial histoarchitecture with regular striations. However, in the ZDV-alone group, it induced distortion in the heart tissue that manifested as small focal cardiomyocytes necrosis and infiltration with lymphocytes (Klusa et al., 2006).

Image J analysis of the VVG stained sections showed that ZDV induced a significant reduction in the deposition of elastic fibres in the ZDV-alone group relative to control. The findings showed that re-modelling and degradation of the elastic property of the myocardium may result in a number of cardiovascular diseases (Hiroshi et al., 2011). Whereas, MEBC attenuated the damage caused by ZDV by restoring the elastic fibre deposition as seen in the H & E micrographs of the intervention groups.

Infarct areas of the cardiac tissue are the high collagen regions that have formed to replace the dead cells caused by tissue necrosis. MEBC prevented tissue necrosis in the intervention groups by restoring the antioxidant properties of the cells. This is in concert with the finding, reported well on the antioxidant potential of MEBC seed (Chinaka et al., 2012).

The results obtained from Sudan black B and Toluidine blue stains showed deposits of lipochrome and mast cells respectively in the ZDV alone group. These further confirm degeneration and inflammatory changes in the tissues.

Histological results showed that MEBC reversed the cardiotoxic effects of ZDV to a level comparable with vitamin C, a known standard antioxidant drug. This was brought about by the antioxidant property of the extract.

The protective effect of extract against cardiac injury noted in the study can be attributed to the flavonoid component of the methanolic extract of *buchholzia coriacea* seeds known to provide protection against inflammation.

Conclusion

Prolonged zidovudine therapy was found to induce cardiotoxicity by enhancing reactive oxygen species production and depleting the antioxidant capacity of the cells. This damage was reversed by the simultaneous administration of methanolic extract of *buchholzia coriacea* seed. Further studies should be carried out to fractionate and concentrate the active component of methanolic extract of *buchholzia coriacea* seeds for use in zidovudine-induced cardiotoxicity.

REFERENCES

- ALANI SAD, GLAZADA F, GERRANTES JA, TARRES J, CEBALLAS GM (2005) Antibacterial properties of some plants used in Mexican traditional medicine for the treatment of gastro intestine disorders. *J Ethnopharmacoth*, 100(1-2): 153-157.
- ALEXANDER K, MIRJAM K, KLAUS K (2010) Modern infectious disease epidemiology concepts, methods, mathematical models and public health. Springer, New York, 88.
- ANDLEEB S, IKBAL S, ORUC A, BURAK O, CEMRE K, SIBEL OO, AHMET GA, ZELIHA Y (2014) Cardiac Troponin-I (cTnI) a biomarker of cardiac injuries induced by doxorubicin alone and in combination with ciprofloxacin, following acute and chronic dose protocol in Sprague Dawley rats. *Int J Pharmacol*, 10: 258-266.
- ANIE CO, NWABUOKEI IG, OGHENEJOB O M, ENWA FO (2015) The antibacterial effect of the leaf extract of *Buchholzia coriacea* (Capparidaceae) on Gram-negative nasal isolates. *Scholars Acad J Pharmacy*, 4 (4): 226-231.
- BALCAREK K, NILS V, CATHERINE D, BERTRAND B, JACQUES B, JANBERND K, ANA CV, DIRK L, ULRICH AW (2010) Role of pyrimidine depletion in the mitochondrial cardiotoxicity of nucleoside analogue reverse transcriptase inhibitors. *J Acquired Immune Defic Syndrome*, 55: 550-557.
- BANHART ER (1990) Physicians' desk reference. 799-801. Medical Economics Company Oradell, New Jersey.
- BELTRAN B, MATHUR A, DUCHEN MR, ERUSALIMSKY JD, MONCADA S (2003) The effect of nitric oxide on cell respiration: A key to understanding its role in cell survival or death. *Proc Natl Acad Sci*, 97: 14602-14607.
- CARSTON RW, GEORGE B, ABRAHAM OA, EDWARD JM, RICHARD SL, SHULING C, YUSUF JA (1997) Potent growth inhibitory activity of zidovudine on cultured human breast cancer cells and rat mammary tumours. *Am Assoc Cancer Res J*, 57(12): 2341-2345.
- CHINAKA ON, OKWOCH E JO, FLORENCE CN, NKEIRUKA EU (2012) Effects of methanol extract of *Buchholzia coriacea* fruit in streptozotocin induced diabetic rats. *J Pharmacol Toxicol*, 7(4): 181-191.
- CIMONS M (1987) U.S. approves sales of AZT to AIDS patients. *Los Angeles Times*.1.
- DAVID TK, DAVID KH, KIMBERLY AS, WALID H, VASAVI T, LAURA WC, AHMED G, ADELISA LP (2013) Updated US Public Health Service Guidelines for the management of occupational exposure to HIV and recommendations for post exposure prophylaxis. 117-119.
- DE LA ASUNCION JG (2004) AZT induces oxidative damage to cardiac mitochondria: protective effect of vitamins C and E. *Life Sci*, 19: 76(1): 47-56.
- DEVEAUD C, BEAUVOIT B, HAGRY S, GALINIER A, CARRIEERE A, SALIN B, SCHAEFFER J, CASPARBAUGUIL S, FERNANDEZ Y, GORDIEN JB, BREILH D, PENICAUD L, CASTEILLA L, RIGOLET M (2005) Site specific alterations of adipose tissue mitochondria in 3'-azido-3'-deoxythymidine (AZT)-treated rats: an early site in lipodystrophy? *Biochem Pharmacol*, 71: 90-101.
- GLOBAL AIDS (2015) Response progress reporting, 1-78.

- HIROSHI W (2011) Role of elastic fibers on cardiovascular disease. *J Health Sci*, 57(6): 449-457.
- ITALIA P, GIULIO C, LAURA B, MAURIZIO C, SERGIO B, GABRIELLA C, EZIA R, ORNELLA M, LORENZO F, MARTINA M, LUCIA P, GASTON G, NUSSDORFER AS (2007) Vitamin C prevents zidovudine-induced NAD(P)H oxidase activation and hypertension in the rat. *J Cardiovasc Res*, 75: 432-438.
- JIANG B, HEBERT VY, KHANDELWAL AR, STOKES KY, DUGAS TR, LI J, MATHIS M, ALEXANDER JS (2007) HIV antiretroviral drug combination induces endothelial mitochondrial dysfunction and reactive oxygen species production, but not apoptosis. *Toxicol Appl Pharmacol*, 224: 60-71.
- JIANG B, HEBERT VY, KHANDELWAL AR, STOKES KY, DUGAS TR (2009) HIV-1 antiretrovirals induce oxidant injury and increase intima media thickness in an atherogenic mouse model. *Toxicol Lett*, 187: 164-171.
- KLUSA V, JOLANTA P, SERGEJS I, JURIS R, VALENTINA G, AINA K, IMMANUELS T, SIMONS S, LUDMILA V, IVARS K (2006) Protection of azidothymidine-induced cardio-pathology in mice by mildronate, a mitochondria-targeted drug. *Basic Clin Pharmacol Toxicol*, 99: 323-328.
- LEMMENS RHMJ (2013) *Buchholzia coriacea* Engl. In: Schmelzer GH, Gurib-Fakim A (Eds). *Plant Resources of Tropical Africa / Ressources végétales de l'Afrique tropicale*. Wageningen, Netherlands, p 335.
- LEWIS W, GRUPP IL, GRUPP G (2000) Cardiac dysfunction in the HIV-1 transgenic mouse treated with zidovudine. *Lab Invest*, 80: 187-197.
- MOH R, DANIEL C, SORHO S, SAUVAGEOT D, ANZIUM A, MINJA A, GOMIS OB, KONJA C, INWOLEY A, GALLILARD D, BISSAGNENE E, SALAMON R, ANGLARET X (2005) Haematological changes in adults receiving zidovudine-containing HAART regimen in combination with cotrimoxazole in Cote d'Ivoire. *Antiretroviral Therapy*, 10: 615-624.
- NWEZE NE (2011) Studies on the antioxidant and antimicrobial activities of the seed extract of *Buchholzia coriacea* (Cyperaceae). *Nigerian Vet J*, 32(2): 143-147.
- REN S, STAFFAN E, LIYA W (2014) Zidovudine induces down-regulation of mitochondrial deoxynucleoside kinases: implications for mitochondrial toxicity of antiviral nucleoside analogs. *Am Soc Microbiol*, 58(11): 6758-6766.
- SCRUGGS ERD, NAYLOR AJ (2008) Mechanisms of zidovudine-induced mitochondrial toxicity and myopathy. *Pharmacology*, 82(2): 83-88.
- SIA J, PAUL S, MARTIN RM, CROSS H (2004) HIV infection and Zidovudine use in child-bearing women. *Paediatrics*, 114: 707-712.
- STRINGER JS, ZULU I, LEVY J, STRINGER EM, MWANGO A, CHI BH, MTONGA V, REID S, CANTRELL RA, BULTERYS M, SAAG MS, MARLINK RG, MWINGA A, ELLERBROCK TV, SINKALA M (2006) Rapid scale-up of antiretroviral therapy at primary care sites in Zambia: feasibility and early outcome. *J Am Med Assoc*, 296: 782-793.
- SUN R, ERIKSSON S, WANG L (2010) Identification and characterization of mitochondrial factors modulating thymidine kinase 2 activity. *Nucleosides Nucleotides Nucleic Acids*, 29(4-6): 382-385.
- THACZUK D, MACLEAN D, LANDS L (2014) *A practical guide to HIV drug treatment for people living with HIV* 2nd ed. Toronto: CATIE.
- VIJA K, JOLANTA P, SERGEJS I, JURIS R, VALENTINA G, AINA K, IMMANUELS T, SIMONS S, LUDMILA V, IVARS K (2006) Protection of azidothymidine-induced cardio-pathology in mice by mildronate, a mitochondria-targeted drug. *Basic Clin Pharmacol Toxicol*, 99: 323-328.
- WHEELER S, MAXWELL-BAWDEN A, HERB RA, GALLAGHER GE, COAST JR (2005) Zidovudine-induced diaphragmatic contractile dysfunction: impact of an antioxidant diet. *Respirology*, 10: 171-176.
- WILLIAM K (2008) *Encyclopaedia of Public Health*. Springer, New York, pp 676-677.
- WU G, FANG YZ, YANG S, LUPTON JR, TURNER ND (2004) Glutathione metabolism and its implication for health. *J Nutrition*, 134(3): 489-492.
- YAMAGUCHI T, KATOH I, KURATA S (2002) Azidothymidine causes functional and structural destruction of mitochondria, glutathione deficiency and HIV-1 promoter sensitization. *Eur J Biochem*, 269: 2782-2788.