

Anatomical variation of arterial blood supply of liver segment IV

Haider Abdulrasool¹, Christopher Briggs²

¹Lyell McEwin Hospital, South Australia, Australia, ²Department of Anatomy and Neuroscience, The University of Melbourne, Victoria, Australia

SUMMARY

There has been a dilemma about the arterial supply of segment IV of the liver, and the subsequent risk of ischaemia, necrosis, hepatic artery thrombosis of segment IV after split-liver transplantation or the associating liver partition and portal vein ligation for staged hepatectomy procedure. We report a rare case of anatomical variation of the arterial blood supply of segment IV of the liver. In this case the proper hepatic artery trifurcated into left, middle and right branches that supplied the liver. Moreover, Segment IV received dual blood supply from both, the middle hepatic artery and the right branch of the proper hepatic artery. Identifying such anatomical variation prior to any liver surgery is essential. It is of particular significance in defining the resection line in liver surgeries. In order to avoid ischaemia, necrosis or cholangiopathy in segment IV, the division of liver parenchyma needs to be based on the anatomy of the arterial blood supply and the intrahepatic blood distribution to segment IV.

Key words: Segment IV blood supply – Segment IV ischaemia – Proper hepatic artery – Middle hepatic artery – Right branch of proper hepatic artery – Left branch of proper hepatic artery

INTRODUCTION

The currently used classification of liver segments follows the scheme that was developed by Couinaud in the early 1960s. Since then, surgeons consider these segments in hepatic surgery (Fischer et al., 2002).

The Couinaud classification is based on the main

stems of the portal and hepatic veins. The liver is divided into two functional hemilivers by the scissures known as the main portal scissure and Cantlie's line. Cantlie's line is the line that runs anteriorly from the middle of the gallbladder bed posteriorly to the inferior vena cava. The umbilical fissure and the falciform ligament separate segments II and III from segment IV in the left hemiliver. The tract of the right hepatic vein divides the right hemiliver into anterior segments (segments V and VIII) and posterior segments (segment VI and VII) (Alghamdi et al., 2017).

Embryologically, the liver has 3 lobes in the early stage of its formation, each supplied by an embryonic artery of its own: the lateral sector (segment II) by the embryonic left hepatic artery, the medial and anterior sectors (segments III, IV, V, and VIII) by the embryonic middle hepatic artery, and the posterior sector (segments VI and VII) by the embryonic right hepatic artery. In the adult liver, segment IV is a part of the medial sector, and is supplied by the middle hepatic artery (Jin et al., 2008).

Conventionally, the middle hepatic artery originates from the left branch of the proper hepatic artery and heads toward the right side of the umbilical fissure and supplies segment IV (Onishi et al., 2000; Furuta et al., 2009; Yoshimura et al., 1986; Jason et al., 2012).

There are anatomical variations in the blood supply of the liver and that includes aberrant or accessory hepatic arteries. In previous studies, it was found that a right hepatic artery arose from the superior mesenteric artery. It was considered as an accessory artery when the right branch of proper hepatic artery existed and it was considered as an aberrant artery when it was the only artery supplying the right hemiliver. The same condition applies to a left hepatic artery when it arises from the left gastric artery (Fonseca-Neto et al., 2017; Michels, 1966). Also, it was noticed that the accessory right hepatic artery can arise from coeliac trunk

Corresponding author: Haider Abdulrasool. Lyell McEwin Hospital, Haydown Road, Elizabeth Vale, SA, 5112 Australia. Mobile: +61 0403587021.

E-mail: haiderabdulrasool@yahoo.com

Submitted: 26 December, 2017. Accepted: 23 May, 2018.

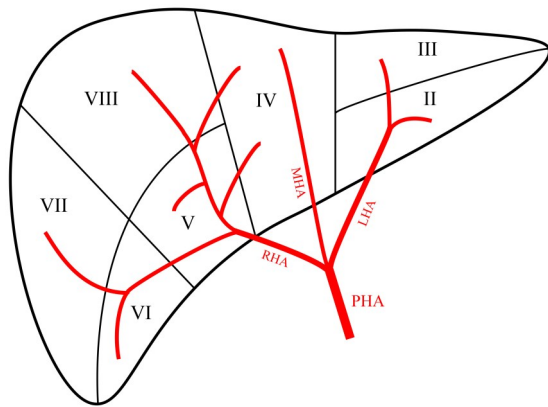


Fig 1. A schematic presentation of the anatomical variation. The liver is subdivided into its functional Couinaud's segments.

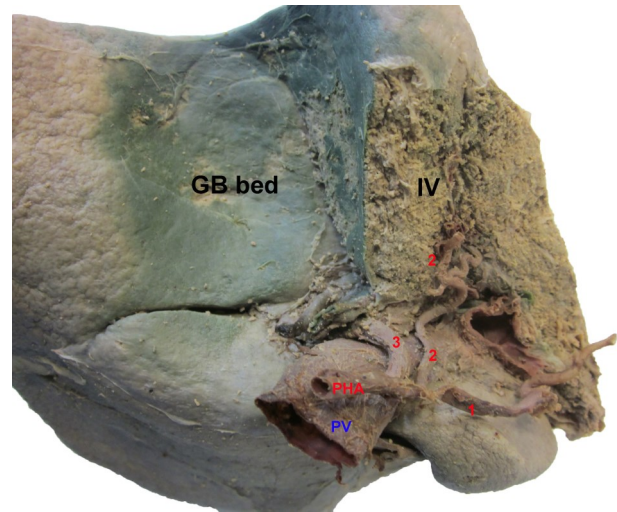


Fig 3. Further dissection of segment IV; segment II and III removed. 1. LHA; 2. MHA; 3. RHA; PV. Portal vein; GB. Gallbladder.

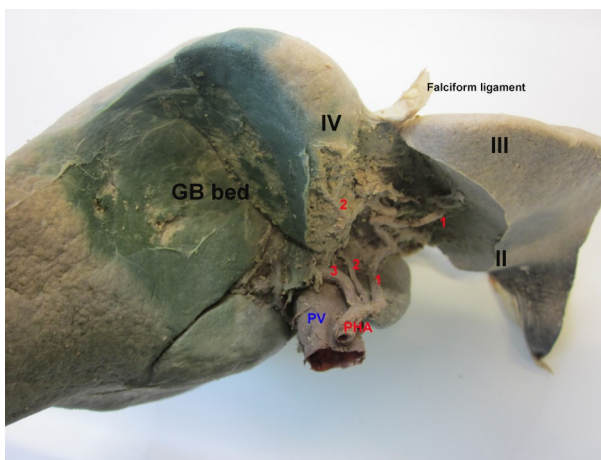


Fig 2. Trifurcation of the PHA with its branches supplying the liver segments. 1. LHA; 2. MHA; 3. RHA; PV. Portal vein; GB. Gallbladder.

or common hepatic artery directly (Polguy et al., 2010; Olewnik et al., 2017).

Couinaud's method of dividing the liver into autonomously functioning liver segments is generally accepted as a good approximation. But there seems to be a significant variability in the shape and position of the segment borders (Fischer et al., 2002).

Segment IV is different from the other segments of the left hemiliver according to the Couinaud classification, as it forms the border with the right hemiliver. There has been a dilemma about the arterial supply of segment IV of the liver, and the subsequent risk of ischaemia, necrosis, hepatic artery thrombosis of segment IV after split-liver transplantation or the associating liver partition and portal vein ligation for staged hepatectomy (ALPPS) procedure (Alghamdi et al., 2017).

CASE REPORT

While performing a routine anatomical dissection of an eighty-four-year-old male cadaver who died of metastatic prostate cancer, an anatomical variation of the hepato-biliary arterial system was recognised.

It was noticed that the proper hepatic artery (PHA) trifurcates at the porta hepatis into three branches. The three branches were (from left to right) the left branch of the proper hepatic artery (LHA), the middle hepatic artery (MHA), and the right branch of the proper hepatic artery (RHA). Further dissection of the liver parenchyma was performed to identify which liver segments the three hepatic arteries supply. LHA supplied segments II & III only while MHA supplied segment IV. However, in addition to supplying the segments of the right hemiliver, RHA also supplied segment IV (Figs. 1-3).

DISCUSSION

In this case report, the MHA originated directly from the PHA and supplied Segment IV. However, MHA was not the sole artery of segment IV as the RHA supplied segment IV as well. A review of the literature on the arterial blood supply of segment IV showed a versatile pattern.

According to Michels (1966), the common hepatic artery provides three branches to the liver: RHA, MHA, and LHA. The MHA courses in the umbilical fossa to supply the medial segment of the liver (segment IV) and is a branch of either RHA or LHA with a nearly equal incidence rate.

Each hepatic artery, whether replaced from other source or accessory to the right and left hepatic arteries, is functionally essential. As such, each hepatic artery has its specific area of blood supply. This was demonstrated in the 100 plastic casts of livers made by Healey and Schroy in the Daniel Baugh Institute (1951 to 1953). Therefore, hepatic arteries are end arteries with no anastomosis inside the liver (Michels, 1966).

In an anatomical study of 171 livers focusing on segment IV by Onishi et al. (2000), the MHA originated from LHA in 61.5%, from RHA in 27.5%, from PHA in 5.5%, and from both LHA and RHA in

5.5%. A similar pattern of categorization of MHA according to its point of origin was established by Jin et al. (2008); however, the incidence of each type was different.

Alghamdi et al. (2017) found that in 23 of 29 livers (79.3%) the arterial perfusion of segment IV was separated by a line drawn from the left side of the inferior vena cava at the top of and lateral to the falciform ligament to the medial point of the gallbladder bed. The area lateral to this line was supplied mainly by RHA with/without MHA, and the area medial to it was supplied mainly by LHA with/without MHA. In one case, water and ink perfusion to segment IV came only from the MHA, and in this case the MHA originated directly from the PHA.

The MHA originated from the RHA in nine livers and from the LHA in other nine livers, giving a frequency of 31% for each occurrence. The MHA originated from the PHA in one liver (3.4%), but was absent in nine livers (31%). The MHA was doubled in one liver: one arm arose from the RHA and the other from the LHA. In 6 of the 29 livers, the results of the water and ink perfusion were not as described above (Alghamdi et al., 2017).

These variations in the arterial blood supply of segment IV of the liver are significant in defining the resection line in split-liver resection and ALPPS procedure. To avoid ischaemia, necrosis or cholangiopathy in segment IV, the division of liver parenchyma needs to be based on the anatomy of the arterial blood supply and the intrahepatic blood distribution to segment IV (Alghamdi et al., 2017).

Abbreviations

ALPPS: associating liver partition and portal vein ligation for staged hepatectomy

PHA: proper hepatic artery

LHA: left branch of proper hepatic artery

MHA: middle hepatic artery

RHA: right branch of proper hepatic artery

ACKNOWLEDGEMENTS

We would like to thank Agron Mataj for his ongoing assistance and advice during the dissection process.

REFERENCES

- ALGHAMDI TC, JUSTINGER C, LORF T (2017) Arterial blood supply of liver segment IV and its possible surgical consequences. *Am J Transpl*, 17(4): 1064-1070.
- FISCHER LCC, THORN M, BENNER AXEL, GREINER L, VETTER M, LEHNERT T, KLAR E, MEINZER HP, LAMADÉ W (2002) Limits of Couinaud's liver segment classification: a quantitative computer-based three-dimensional analysis. *J Comp Assist Tomography*, 26(6): 962-967.
- FONSECA-NETO OCLD, LIMA HCS, RABELO P, MELO PSV, AMORIM AG, LACERDA CM (2017) Anatomic variations of hepatic artery: a study in 479 liver transplantations. *Arq Bras Cir Dig*, 30(1): 35-37.

FURUTA T, MAEDA E, AKAI H, HANAOKA S, YOSHIOKA N, AKAHANE M, WATADANI T, OHTOMO K (2009) Hepatic segments and vasculature: projecting CT anatomy onto angiograms. *Radiographics*, 29(7): 1-22.

JASON K, SICKLICK MDA, YUMAN F (2012) Hepatic artery. In: Courtney M, Townsend RDB, Evers M, Kenneth L, Mattox (eds). *Sabiston Textbook of Surgery*. 19th ed. Elsevier Saunders, Philadelphia, pp 1418-1419.

JIN GY, YU HC, LIM HS, MOON JI, LEE JH, CHUNG JW, CHO BH (2008) Anatomical variations of the origin of the segment 4 hepatic artery and their clinical implications. *Liver Transpl*, 14(8): 1180-1184.

MICHELS NA (1966) Newer anatomy of the liver and its variant blood supply and collateral circulation. *Am J Surg*, 112(3): 337-347.

OLEWNIK Ł, WYSIADECKI G, POLGUJ M, WAŚNIEWSKA A, JANKOWSKI M, TOPOL M (2017) Types of coeliac trunk branching including accessory hepatic arteries: a new point of view based on cadaveric study. *Folia Morphol (Warsz)*, 76(4): 660-667. doi: 10.5603/FM.a2017.0053

ONISHI HKY, DAS BC, NAKANO K, GADZIJEV EM, RAVNIK D, ISAJI S (2000) Surgical anatomy of the medial segment (S4) of the liver with special reference to bile ducts and vessels. *Hepato-gastroenterol*, 47(31): 143-150.

POLGUJ M, GABRYNIAK T, TOPOL M (2010) The right accessory hepatic artery; a case report and review of the literature. *Surg Radiol Anat*, 32(2): 175-179.

YOSHIMURA H, UCHIDA H, OHISHI H, HONDA N, OHUE S, KINOSHITA Y, KATSURAGI M, MATUSO N, HOSOGI Y, HATAKEYAMA M, et al. (1986) Evaluation of "M-point" in hepatic artery to identify left medial segment of liver. Angiographic study. *Eur J Radiol*, 6(3): 195-198.