

A radiographic review of the subacromial architecture: a South African study

Nerissa Naidoo¹, Lelika Lazarus², Alexander Van Tongel³, Shameem A. Osman⁴, Kapil S. Satyapal²

¹College of Medicine, Mohammed Bin Rashid University of Medicine and Health Sciences, Dubai Healthcare City, Dubai, United Arab Emirates, ²Department of Clinical Anatomy, School of Laboratory Medicine and Medical Sciences, University of KwaZulu-Natal, Durban, South Africa, ³Department of Physical Medicine and Orthopaedic Surgery, Ghent University, Ghent, Belgium, ⁴Orthopaedics, Suite 11 Medical Centre East, Life Entabeni Hospital, Durban, South Africa

SUMMARY

The subacromial space, which is occupied by the subacromial bursa, rotator cuff complex and the long head of the biceps brachii tendon, is a well-known area of study due to its association with subacromial disease. Although it is demarcated by the coraco-acromial arch and the supraglenoid tubercle, degenerative changes in these osteological components often lead to mechanical narrowing and subsequent tendon abrasion. In addition to the morphological characteristics, the morphometry of the subacromial architecture is considered to play an important role in maintaining glenohumeral stability. Accordingly, the present study outlined the morphometry of the subacromial architecture and the acromial morphology from a radiological perspective.

A total of 120 true lateral-outlet view radiographs ($n = 120$), representative of 58 males and 62 females of the Black (12), Coloured (10), Indian (27) and White (71) race groups, were analysed. In addition to calculation of the standard and population-specific means, the acromial classification scheme of Bigliani et al. (1986) was adopted.

A trend of ascending values from Type III

(16.7%) to Type II (37.5%) to Type I (45.8%) acromia was noted. Various shapes of the subacromial space were observed, viz. rhomboidal (20.0%), trapezoidal (65.8%) and triangular (14.1%). Since a statistically significant P value of 0.030 was recorded for the comparison of acromial type with the shape of the subacromial space, the shape of the subacromial space appeared to be dependent on the acromial type.

While the parameters were determined with regard to the demographic representation of South Africa, this study also provided standard mean values which were not previously reported. Furthermore, the correlation of the acromio-glenoidal length with side, gender and shape of the subacromial space reflected levels of significance and highlighted this parameter as a diagnostic determinant of subacromial disease due to its tendency to change in accordance with the demographic and morphological factors.

Key words: Subacromial architecture – Acromial type – Patient demographics – Subacromial disease

INTRODUCTION

The subacromial space, which is bound by the coraco-acromial arch and the supraglenoid tubercle, consists of osteological components that have been identified as causative agents in subacromial

Corresponding author: Dr Nerissa Naidoo. College of Medicine, Mohammed Bin Rashid University of Medicine and Health Sciences, P.O Box 505055, Dubai, Building 14, Dubai Healthcare City, United Arab Emirates. Phone: + 27 76 437 2115. E-mail: nerissa.naidoo17@gmail.com

Submitted: 21 June, 2017. Accepted: 22 September, 2017.

disease (Bigliani et al., 1986; Dwivedi and Varshney, 2015; El-Din and Ali, 2015; Naidoo et al., 2015; Standing et al., 2016). It is occupied by the tendons of the rotator cuff, subacromial bursa and the tendon of the long head of biceps brachii (Acar et al., 2014; Gupta et al., 2014; Dwivedi and Varshney, 2015; Naidoo et al., 2015; Standing et al., 2016). As the subacromial space presents as the passage of exit for the supraspinatus tendon, mechanical narrowing of it has been reported to cause friction, compression and subsequent tearing of the tendon (Neer, 1983; Atalar et al., 2001; Alpyoruk and Basaloglu, 2003; Acar et al., 2014; Dwivedi and Varshney, 2015). Furthermore, it may result in an increased risk of pain and limited movement due to the reduced operative area available (Acar et al., 2015; Naidoo et al., 2015).

Moreover, processes such as the acromion play an important role in maintaining the static stability of the shoulder (El-Din and Ali, 2015). Bigliani et al. (1986) further classified the acromial morphology into three types, viz. I: flat inferior surface, II: curved inferior surface, III: hooked inferior surface. Subsequently, there has been a correlation between the incidence of type III acromia and the prevalence of subacromial compression and rotator cuff tendinopathy (Acar et al., 2014; Dwivedi and Varshney, 2015). Although many studies have documented the acromial shape and accompanying morphometry of the subacromial space, radiographic patient demographics specific to the South African population have not been recorded (Dwivedi and Varshney, 2015). Such reference data may contribute to the body of knowledge regarding the spectrum of subacromial syndromes and prove beneficial for differential diagnoses (Acar et al., 2014; Gupta et al., 2014).

This study focused on the morphometry of the subacromial architecture and the acromial morphology from a radiological perspective.

MATERIALS AND METHODS

A total of 120 true lateral-outlet view radiographs were randomly extracted from the radiological database of Life Entabeni Hospital, Durban, South Africa. As this was conducted under the supervision of the orthopedician and in accordance with the protocol of hospital management, ethical clearance was granted by the Biomedical Research Ethics Committee of the University of KwaZulu-Natal (Ethical Clearance Number: BE 279/15). Additional gatekeeper permission was sought from the management of Life Entabeni Hospital.

The study consisted of 58 males and 62 females ($n = 120$) with a mean age of 50.6 ± 14.6 years old belonging to the Black (12), Coloured (10), Indian (27) and White (71) race groups.

Lateral-outlet view radiographs demonstrating the PA technique were included. In all these radio-

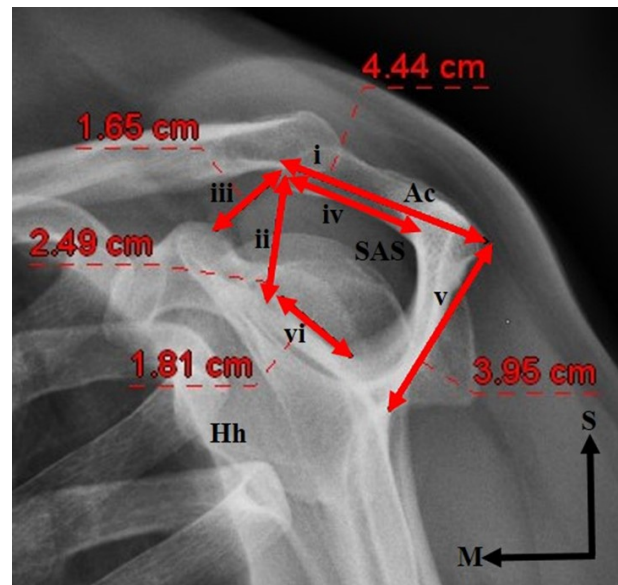


Fig 1. Morphometric parameters of the subacromial architecture. i- Acromial length (distance from anterior acromial tip to the postero-lateral most aspect of the acromion); ii- Acromio-glenoidal length (distance from inferior surface of anterior acromial tip to supraglenoid tubercle); iii- Acromio-coracoid distance (distance from inferior surface of anterior acromial tip to posterior-most surface of coracoid process); iv- Distance between inferior surface of anterior acromial tip and spinous process; v- Distance between supraglenoid tubercle and spinous process; vi- Length of spinous process (distance between its attachment to the acromion and glenoid) (Lateral-outlet view, left shoulder).

Key: Ac Acromion, Hh Humeral head, M Medial, S Superior, SAS Subacromial space

graphs, the patient stood erect facing the upright detector with the anterior aspect of his/her shoulder against the x-ray plate, the arm flexed and the hand rested on the hip joint. The radiographs displayed the characteristic “Y” shape, i.e. the acromion and coracoid process formed the upper arms of the “Y”, the humeral head protruded toward the base of the “Y”, and the posterior aspect of the clavicle and anterior acromion formed a roof over the glenohumeral joint. A portrait orientation was maintained for all patients, with the exposure ranging from 60 to 70kVp.

Through the use of the GE Healthcare Centricity PACS – IW Dynamic Imaging (3.7.3.9) software, the following morphometric parameters relating to the subacromial space were calculated: i- Acromial length (distance from the anterior acromial tip to the postero-lateral most aspect of the acromion); ii- Acromio-glenoidal length (distance from the inferior surface of the anterior acromial tip to the supraglenoid tubercle); iii- Acromio-coracoid distance (distance from the inferior surface of the anterior acromial tip to the posterior-most surface of the coracoid process); iv- Distance between the inferior surface of the anterior acromial tip and the spinous process; v- Distance between the supraglenoid tubercle and the spinous process; vi- Length

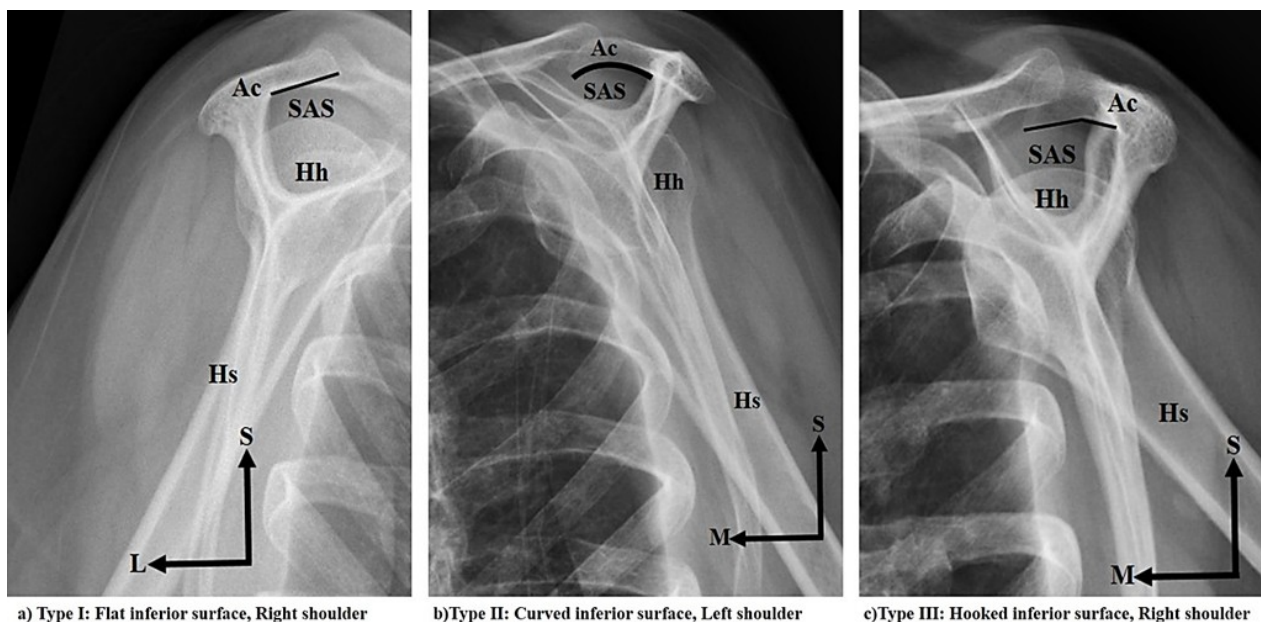


Fig. 2.- Acromial Types as proposed by Bigliani et al. (1986). **a)** Type I: Flat inferior surface, Right shoulder; **b)** Type II: Curved inferior surface, Left shoulder; **c)** Type III: Hooked inferior surface, Left shoulder (Lateral-outlet view).

Key: Ac Acromion, Hh Humeral head, Hs Humeral shaft, L Lateral, M Medial, S Superior, SAS Subacromial space

of the spinous process (distance between its attachment to the acromion and glenoid) (Fig. 1). Each parameter was computed three times and an average determined by the same researcher. In addition, the shape of the acromion was identified and recorded according to the classification scheme devised by Bigliani et al. (1986). The data collected was subjected to statistical analysis (SPSS version 21.0). *P* values of less than 0.05 were considered to reflect statistical significance.

RESULTS

Morphology

In this study, the acromial morphology was classified into type I (45.8%), II (37.5%) and III (16.7%) (Fig. 2, Table 1). Three standard shapes of the subacromial space were identified, viz. rhomboid (20.0%), trapezoid (65.8%) and triangle (14.1%) (Fig. 3, Table 1).

The acromial morphology and shape of the subacromial space were also recorded in accordance with laterality and patient demographics (Table 1).

i) Acromial morphology: Type I (Left: 20.8%, Right: 25.0%), Type II (Left: 13.3%, Right: 24.2%), Type III (Left: 11.7%, Right: 5.0%)

Type I: Gender [Male: 21.1%, Female: 24.2%], Race [Black: 2.5%, Coloured: 3.3%, Indian: 9.2%, White: 30.8%]; Type II Gender [Male: 17.5%, Female: 20.0%], Race [Black: 5.0%, Coloured: 3.3%, Indian: 10.0%, White: 19.2%]; Type III Gender [Male: 9.2%, Female: 7.5%], Race [Black: 2.5%, Coloured: 1.7%, Indian: 3.3%, White: 9.2%]

A statistically significant *P* value of 0.036 was recorded for the comparison of acromial morpho-

gy between right and left sides.

ii) Shape of subacromial space: Rhomboid (Left: 9.2%, Right: 10.8%), Trapezoid (Left: 30.8%, Right: 35.0%), Triangle (Left: 5.8%, Right: 8.3%)

Rhomboid: Gender [Male: 8.3%, Female: 11.7%], Race [Black: 0%, Coloured: 1.7%, Indian: 5.0%, White: 13.3%]; Trapezoid: Gender [Male: 33.3%, Female: 32.5%], Race [Black: 6.7%, Coloured: 5.0%, Indian: 15.0%, White: 39.2%]; Triangle: Gender [Male: 6.7%, Female: 14.2%], Race [Black: 3.3%, Coloured: 1.7%, Indian: 2.5%, White: 6.7%]

The comparison of acromial type with the shape of subacromial space yielded a statistically significant *P* value of 0.030.

Morphometry

The mean subacromial morphometry was recorded as follows (Table 1):

i) Acromial length – 58.1±13.8mm; Left: 70.9±2.4mm, Right: 47.3±8.4mm

Gender [Male: 74.7±9.8mm, Female: 42.6±6.4mm]; Race [Black: 46.3±7.4mm, Coloured: 45.5±6.7mm, Indian: 43.3±6.7mm, White: 46.4±8.4mm]

Acromial Type [I: 72.5±2.4mm, II: 46.5±7.9mm, III: 44.9±7.8mm]; Shape of Subacromial Space [Rhomboid: 44.3±7.3mm, Trapezoid: 46.4±7.6mm, Triangle: 43.8±9.6mm]

ii) Acromio-glenoidal length – 25.7±7.8mm; Left: 23.9±7.7mm, Right: 27.2±7.6mm

Gender [Male: 27.5±8.8mm, Female: 23.9±7.6mm]; Race [Black: 27.5±8.8mm, Coloured: 25.2±6.3mm, Indian: 22.7±7.0mm, White: 26.7±7.9mm]

Table 1. Morphological and morphometric parameters of the subacromial architecture.

Parameter	Morphometry (mm)						
	Dimensions of subacromial space			Distance from:		Length of spinous process	
	Acromial length	Acromio-glenoidal length	Acromio-coracoid distance	Inferior surface of anterior acromial tip to spinous process	Supraglenoid tubercle to spinous process		
Standard	58.1±13.8	25.7±7.8	21.8±7.3	3.4±7.4	14.5±4.7	23.1±0.5	
Side	Left	70.9±2.4	23.9±7.7	21.6±8.2	22.5±6.9	14.7±4.6	23.3±4.9
	Right	47.3±8.4	27.2±7.6	22.1±6.7	24.1±7.8	14.4±4.8	23.0±5.5
P Value	0.352	0.019*	0.733	0.224	0.746	0.777	
Sex	Male	74.7±9.8	27.7±7.6	22.6±7.9	25.3±7.5	14.8±4.7	24.2±4.5
	Female	42.6±6.4	23.9±7.6	21.1±7.5	21.6±6.9	14.3±4.7	22.2±5.6
P Value	0.205	0.008*	0.266	0.005*	0.613	0.035*	
Race	Black	46.3±7.4	27.5±8.8	18.9±6.6	24.3±9.4	14.7±5.3	21.6±4.8
	Coloured	45.5±6.7	25.2±6.3	25.8±7.3	25.9±3.0	19.0±4.5	23.1±4.5
	Indian	43.3±6.7	22.7±7.0	20.8±6.1	21.6±6.5	14.1±3.3	22.1±4.2
	White	46.4±8.4	26.7±7.9	22.2±7.8	23.5±7.7	14.1±4.8	23.8±5.6
P Value	0.419	0.110	0.097	0.163	0.010*	0.308	
Shape of sub-acromial space	Rhomboid	44.3±7.3	23.9±6.8	20.6±8.6	23.0±6.7	14.1±5.8	20.2±4.7
	Trapezoid	46.4±7.6	26.0±7.8	21.0±5.6	24.1±6.4	14.6±4.2	24.2±5.0
	Triangle	43.8±9.6	26.7±9.0	27.7±11.0	20.5±1.1	14.7±5.2	22.5±5.2
P Value	0.323	0.366	0.031*	0.254	0.652	0.003*	
Acromial Type	I	72.5±2.4	25.5±3.8	21.9±7.4	21.6±7.0	14.8±5.1	23.0±5.0
	II	46.5±7.9	26.5±7.6	23.0±7.8	25.0±7.5	14.6±4.7	23.5±4.2
	III	44.9±7.8	24.6±6.8	19.1±5.7	24.7±5.4	13.6±3.2	23.0±6.0
P Value	0.580	0.658	0.144	0.045*	0.591	0.867	
Age							
P Value	0.694	0.127	0.594	0.495	0.557	0.320	

Key: *Significant *P* Value

Acromial Type [I: 25.5±3.8mm, II: 26.5±7.6mm, III: 24.6±6.8mm]; Shape of Subacromial Space [Rhomboid: 23.9±6.8mm, Trapezoid: 26.0±7.8mm, Triangle: 26.7±9.0mm]

The comparison of laterality, gender and shape of the subacromial space with the acromio-glenoid length yielded a statistically significant *P* values of 0.019, 0.008 and 0.031, respectively.

iii) Acromio-coracoid distance – 21.8±7.3mm; Left: 21.6±8.2mm, Right: 22.1±6.7mm

Gender [Male: 22.6±7.9mm, Female: 21.1±7.5mm]; Race [Black: 18.9±6.6mm, Coloured: 25.8±7.3mm, Indian: 20.8±6.1mm, White: 22.2±7.8mm]

Acromial Type [I: 21.9±7.4mm, II: 23.0±7.8mm, III: 19.1±5.7mm]; Shape of Subacromial Space [Rhomboid: 20.6±8.6mm, Trapezoid: 21.0±5.6mm, Triangle: 27.7±11.0mm]

iv) Distance from inferior surface of anterior acromial tip to spinous process – 3.4±7.4mm; Left: 22.5±6.9mm, Right: 24.1±7.8mm

Gender [Male: 25.3±7.5mm, Female:

21.6±6.9mm]; Race [Black: 24.3±9.4mm, Coloured: 25.9±3.0mm, Indian: 21.6±6.5mm, White: 23.5±7.7mm]

Acromial Type [I: 21.7±7.0mm, II: 25.0±7.5mm, III: 24.7±5.4mm]; Shape of Subacromial Space [Rhomboid: 23.0±6.7mm, Trapezoid: 24.1±6.4mm, Triangle: 20.5±1.1mm]

Statistically significant *P* values of 0.005 and 0.045 were recorded for the comparison of the distance from the inferior surface of the anterior acromial tip to the spinous process with gender and acromial type, respectively.

v) Distance from supraglenoid tubercle to spinous process – 14.5±4.7mm; Left: 14.7±4.6mm, Right: 14.4±4.8mm

Gender [Male: 14.8±4.7mm, Female: 14.3±4.7mm]; Race [Black: 14.7±5.3mm, Coloured: 19.0±4.5mm, Indian: 14.1±3.3mm, White: 14.1±4.8mm]

Acromial Type [I: 14.8±5.1mm, II: 14.6±4.7mm, III: 13.6±3.2mm]; Shape of Subacromial Space [Rhomboid: 14.1±5.8mm, Trapezoid: 14.6±4.2mm,

Table 1. Morphological and morphometric parameters of the subacromial architecture.

Parameter		Morphology (%)					
		Acromial Type			Shape of subacromial space		
		I	II	III	Rhomboid	Trapezoid	Triangle
Standard		45.8	37.5	16.7	20.0	65.8	14.1
Side	Left	20.8	13.3	11.7	9.2	30.8	5.8
	Right	25.0	24.2	5.0	10.8	35.0	8.3
P Value		0.036*			0.914		
Sex	Male	21.7	17.5	9.2	8.3	33.3	6.7
	Female	24.2	20.0	7.5	11.7	32.5	14.2
P Value		0.806			0.739		
Race	Black	2.5	5.0	2.5	0	6.7	3.3
	Coloured	3.3	3.3	1.7	1.7	5.0	1.7
	Indian	9.2	10.0	3.3	5.0	15.0	2.5
	White	30.8	19.2	9.2	13.3	39.2	6.7
P Value		0.675			0.349		
Shape of subacromial space	Rhomboid	12.5	25.0	5.8	-	-	-
	Trapezoid	4.2	27.5	5.8			
	Triangle	0.8	13.3	2.5	-	-	-
P Value		0.030*			-		
Acromial Type	I	-	-	-	12.5	4.2	0.8
	II	-	-	-	25.0	27.5	13.3
	III	-	-	-	5.8	5.8	2.5
P Value		-			0.030*		
Age		0.895			0.988		
P Value							

Key: *Significant P Value

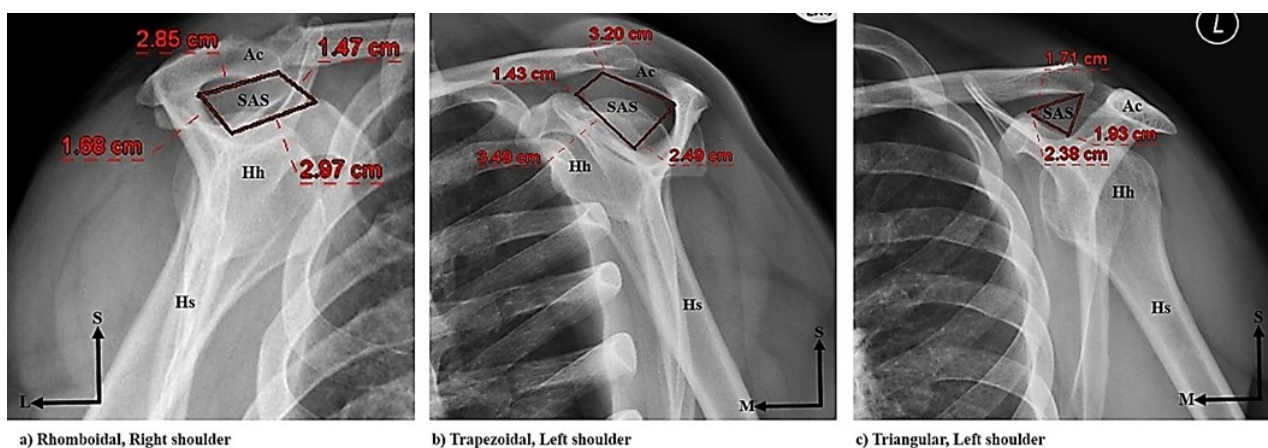


Fig 3. Shape of Subacromial Space: a) Rhomboidal, Right shoulder; b) Trapezoidal, Left shoulder; c) Triangular, Left shoulder (Lateral-outlet view).

Key: Ac Acromion, Hh Humeral head, Hs Humeral shaft, L Lateral, M Medial, S Superior, SAS Subacromial space

Triangle: 14.7±5.2mm]

A statistically significant P value of 0.010 was recorded for the correlation between race and the distance from supraglenoid tubercle to spinous process.

vi) Length of spinous process – 23.1±0.5mm; Left: 23.3±4.9mm, Right: 23.0±5.5mm

Gender [Male: 24.2±4.5mm, Female: 22.2±5.6mm]; Race [Black: 21.6±4.8mm, Coloured: 23.1±4.5mm, Indian: 22.1±4.2mm, White:

23.8±5.6mm]

Acromial Type [I: 23.0±5.0mm, II: 23.5±4.2mm, III: 23.0±6.0mm]; Shape of Subacromial Space [Rhomboid: 20.2±4.7mm, Trapezoid: 24.2±5.0, Triangle: 22.5±5.2mm]

The comparison of gender with the length of the spinous process resulted in a statistically significant *P* value of 0.035.

DISCUSSION

According to the seven trends regarding the frequency of the three acromial types summarized by Naidoo et al. (2015), trend “e = TIII<TII<TI”, which was reflected by ascending values from Type III to Type II to Type I acromia, was observed in this study, viz. Type III (16.7%), Type II (37.5%) and Type I (45.8%) (Table 1). This further corroborated the findings of Schippinger et al. (1997). As the hooked Type III acromia are considered to predispose the subacromial complex to rotator cuff tendinopathy, the low prevalence of Type III acromia was consistent with the theory of Bigliani et al. (1986). In addition to the clinical assessment of the patient, proliferative and degenerative changes in the acromial morphology have been recognized to be indicative of acromioplasty (Dwivedi and Varshney, 2015).

With the exception of the kite-shaped subacromial space reported by Sperner (1995), the rhomboidal, trapezoidal and triangular shapes seen in the present study corroborated our previous osteological investigation (Naidoo et al., 2015). Moreover, the statistically significant *P* value of 0.030 that was recorded for the comparison of acromial type with the shape of the subacromial space, verified hypothesis that the shape of the subacromial space appeared to be dependent on the acromial type (Naidoo et al., 2015).

The increased incidence of Type I and II acromia on the right side was also noted by El-Din and Ali (2015) and Naidoo et al. (2015). Since the comparison of acromial morphology between right and left sides yielded a statistically significant *P* value of 0.036, this increased incidence was understood to represent a standard reference for Types I and II acromia on the right side. Similarly, all three subacromial shapes were more prevalent on the right side. However, this was in contrast to the predominance of left-sidedness documented by Naidoo et al. (2015), thus highlighting the asymmetry in laterality of the South African population.

Since El-din and Ali (2015) stated that population demographics alter the development of osteological protrusions which lead to variation in size and morphology, the present study incorporated the analysis of patient demographics in relation to the scapular parameters.

Although Types I and II acromia, along with the rhomboidal and triangular subacromial spaces were frequently seen in female individuals, Type III

acromia and trapezoidal subacromial spaces were common in male individuals. This was comparable to the findings of Paraskevas et al. (2008), Mohamed and Abo-Sheisha (2014) and Dwivedi and Varshney (2015) as Type I acromia were more prevalent in female individuals, while male individuals presented with a higher incidence of Type II acromia. On the contrary, Naidoo et al. (2015) reported the greater occurrence of all acromial types in male individuals only.

In light of the larger representation of White individuals within the sample, all acromial types and shapes of the subacromial space were most prevalent within this race group. However, our previous osteological South African study displayed a larger sample of Black individuals which may explain the different in predominance race group between these two studies (Naidoo et al., 2015).

As Edelson and Taitz (1992) established a relationship between the acromial length and degenerative changes of the subacromial osteology, the present study also integrated the morphometric parameters of the subacromial space with the resultant morphology and patient demographics. Although, the mean acromial length was greater than that reported in the Egyptian study of El-Din and Ali (2015), the acromio-glenoidal length and acromio-coracoid distance appeared to be markedly lower. Consequently, the standard mean morphometric parameters that were determined may present as a unique set of permissible values most relevant to the South African population as no study as such exists.

The presence of a larger left mean acromial length was confirmed by Gupta et al. (2014) and El-Din and Ali (2015), whereas Collipal et al. (2010), Singh et al. (2013), Acar et al. (2014) and Naidoo et al. (2015) recorded increased right acromial lengths. The greater mean acromio-glenoidal length and acromio-coracoid distance on the right side supported the findings of Gupta et al. (2014) and Naidoo et al. (2015). Conversely, Singh et al. (2013), Acar et al. (2014) and El-Din and Ali (2015) found the acromio-glenoidal length and acromio-coracoid distance to be increased on the left side. While the distance from supraglenoid tubercle to spinous process and the length of the spinous process were increased on the left side; the distance from inferior surface of the anterior acromial tip to the spinous process was greater on the right side.

All mean morphometric parameters were notably larger in male individuals which were similar to the findings of Nicholson et al. (1996), Paraskevas et al. (2008) and Naidoo et al. (2015). Furthermore, statistically significant *P* values recorded for the comparison of gender with the length of the spinous process and the distance from the inferior surface of the anterior acromial tip to the spinous process, may suggest that these parameters are generally higher in South African males.

According to El-Din and Ali (2015), scapular ra-

cial variations bear great relevance to the pathomechanics of subacromial diseases, therefore the differences found in the morphology and morphometry of this study may indicate the apparent ethnic origin within the demographic representation of South Africa.

Despite the previous report of Naidoo et al. (2015) that outlined the predominance of larger morphometric parameters within White individuals only, this study identified a different trend. Although the acromio-glenoidal length was increased in Black individuals, White individuals presented with larger lengths of the acromion and spinous processes. Consistent with the statistically significant *P* value deduced for the correlation between race and the distance from the supraglenoid tubercle to the spinous process, the acromio-coracoid distance and the distance from the inferior surface of the anterior acromial tip to the spinous processes were also larger in Coloured individuals.

With regard the shape of the subacromial space, the acromial length and the distance from inferior surface of the anterior acromial tip to the spinous process appeared to be greater in trapezoidal subacromial spaces. Likewise, the increased length of spinous process exhibited by the trapezoid subacromial space was further substantiated by a statistically significant *P* value of 0.003. In addition, the triangular subacromial space presented with a larger acromio-glenoidal length, acromio-coracoid distance and distance from the supraglenoid tubercle to the spinous process. Since the rotator cuff tendons traverse the narrow space between the coraco-acromial arch and the humerus as they insert onto the humeral head, a decrease in size of this exit site may result in tendon abrasion (Acar et al., 2014; El-Din and Ali, 2015). Therefore, the statistically significant *P* value recorded for the comparison between the shape of subacromial space and acromio-coracoid distance highlights the latter as an etiological factor in rotator cuff tendinopathy.

While Types I and II acromia reflected increased values for the respective morphometric parameters, it was proposed that the distance from inferior surface of the anterior acromial tip to the spinous process is generally greater in cases with Type II acromia (*P* value = 0.045).

Given that the acromio-glenoidal length is considered to be a diagnostic determinant of subacromial pathology, decreased dimensions of the subacromial space have been correlated to rotator cuff tendinopathy (El-Din and Ali, 2015). Consequently, the correlation of this morphometric parameter with side, gender and shape of the subacromial space yielded statistically significant *P* values. This may indicate the predisposition of the acromio-glenoidal length to change in accordance with side, gender and shape of the subacromial space.

Due to the different methodological techniques

described in the literature, it is likely that variation may arise in the classification schemes. It may be suggested that future studies should provide a correlation between different methodologies so as to determine the most accurate and reliable approach. Furthermore, as the data were obtained from a private hospital, access to information detailing patient history and current diagnosis was not permitted and may present a limitation in this study. In addition to the inclusion of patient history, it is recommended that the actual shoulder pathology is correlated with the relevant subacromial architecture in future studies as this may aid in precise diagnosis.

CONCLUSION

This study provided standard dimensions of the subacromial architecture that are specific to the South African population and may allow for the timeous evaluation of subacromial disease, thus preventing progression to rotator cuff tendinopathy. Furthermore, the radiological outline of the relative morphometric and morphological parameters may be required for pre-operative planning and enhanced surgical outcome, especially in cases where the rotator cuff exit site is narrowed.

REFERENCES

- ACAR M, SIMSEK T, ULUSOY M, ZARARSIZ I, ACAR S, EFE D (2014) The morphometrical and morphological analysis of the acromion with Multidetector Computerised Tomography. *Biomed Res*, 25(3): 377-380.
- ALPYORUK TF, BASALOGU H (2003) Morphometric dimensions of the scapula. *Ege tip dergisi*, 42: 73-80.
- ATALAR AC, DEMIRHAN M, KOCABEY Y, AKALIN Y (2001) Arthroscopic subacromial decompression: one-to seven-year results. *Act Orthop Traumatol Turc*, 35: 377-381.
- BIGLIANI L, MORRISON D, APRIL E (1986) The morphology of the acromion and its relationship to rotator cuff tears. *Orthop Trans*, 228.
- COLLIPAL E, SILVA H, ORTEGA L, ESPINOZA E, MARTINEZ C (2010) The acromion and its different forms. *Int J Morphol*, 28(4): 1189-1192.
- DWIVEDI M, VARSHNEY A (2015) Study of correlation between Bigliani's acromion types and shoulder problems. *Indian J Orthopaed Surg*, 2: 111-115.
- EDELSON JG, TAITZ C (1992) Anatomy of the coraco-acromial arch. Relation to degeneration of the acromion. *Bone Joint J*, 74(4): 589-594.
- EL-DIN WA, ALI MH (2015) A morphometric study of the patterns and variations of the acromion and glenoid cavity of the scapulae in Egyptian population. *J Clin Diagnost Res*, 9(8): AC08.
- GUPTA C, PRIYA A, KALTHUR SG, D'SOUZA AS (2014) A morphometric study of acromion process of scapula and it clinical significance. *CHRISMED J Health Res*, 1(3): 164-169.

- MOHAMED RE, ABO-SHEISHA DM (2014) Assessment of acromial morphology in association with rotator cuff tear using magnetic resonance imaging. *Egyptian J Radiol Nuclear Med*, 45(1): 169-180.
- NAIDOO N, LAZARUS L, OSMAN SA, SATYAPAL KS (2015) Acromial morphology and subacromial architecture in a South African population. *Int J Morphol*, 33(3): 817-825.
- NEER CS (1983) Impingement lesions. *Clin Orthopaed rel Res*, 173: 70-77.
- NICHOLSON GP, GOODMAN DA, FLATOW EL, BIGLIANI LU (1996) The acromion: morphologic condition and age-related changes. A study of 420 scapulas. *J Shoulder Elbow Surg*, 5(1): 1-1.
- PARASKEVAS G, TZAVEAS A, PAPAZIOGAS B, KITSOULIS P, NATSIS K, SPANIDOU S (2008) Morphological parameters of the acromion. *Folia Morphol*, 67(4): 255-260.
- SCHIPPINGER G, BAILEY D, MCNALLY EG, KISS J, CARR AJ (1997) Anatomy of the normal acromion investigated using MRI. *Langenbecks Archiv für Chirurgie*, 382(3): 141-144.
- SINGH J, PAHUJA K, AGARWAL R (2013) Morphometric parameters of the acromion process in adult human scapulae. *Indian J Basic Appl Med Res*, 2: 1165-1170.
- SPERNER G (1995) Role of the subacromial space on development of the impingement syndrome. I. *Unfallchirurg*, 98(6): 301-308.
- STANDRING S (2016) *Gray's Anatomy: The Anatomical Basis of Clinical Practice*. Elsevier Ltd, Spain.