

# Imaging of accessory buccal foramina using cone-beam computed tomography: case reports

Sergey L. Kabak<sup>1</sup>, Nina A. Savrasova<sup>2</sup>, Yuliya M. Melnichenko<sup>3</sup>, Natallia V. Zhuravleva<sup>3</sup>

<sup>1</sup>Research Laboratory of Belarusian State Medical University, <sup>2</sup>Radiation Examination and Radiation Therapy Department of Belarusian State Medical University, <sup>3</sup>Department of Human Morphology of Belarusian State Medical University

## SUMMARY

Rare variations of several additional foramina of the mandible and their combinations were visualized in the dry mandible and in vivo using Cone-Beam Computed Tomography images. One accessory mental foramen (AMF) was located at the root apex of the right second premolar upward from the mental foramen (MF), almost in the middle between the base of the mandible and the alveolar ridge. The second AMF was detected between the first and second left premolars downward from the MF. Two separate foramina in the buccal cortical plate of each half of the dry mandible located along a horizontal line were classified as the mental and mandibular incisive canal foramina. In all presented cases other additional foramina were identified. They were located on the buccal and/or lingual surface of the mandibular body.

**Key words:** Accessory mental foramen – Cone-beam computed tomography – Mandible

**Corresponding author:** Melnichenko Yuliya Mikhaylovna.  
Belarusian State Medical University, Department of Human Morphology, Romenskaya str. 5-54, 220028 Minsk, Belarus.  
E-mail: mjm1980@yandex.ru

## INTRODUCTION

Mental foramina (MF) are located on the external surface of the body of the mandible on each side from the midline. Being the external hole of the mandibular canal, it transmits a bundle composed of a nerve, artery and vein of the same name.

It has also been reported that besides of MF additional buccal holes could be detected by macroscopic investigations of dry skulls, as well as two-dimensional radiography (periapical and panoramic radiography), and computed tomography analysis (Garay and Cantin, 2013).

Buccal foramina (BFs) that have no communication with the mandibular canal are known as nutrient foramina. Blood vessels originating from the submental, facial (lower labial) or buccal arteries are located inside them (Fuakami et al., 2011). One or more additional mental foramina (accessory mental foramina, AMFs) are opening into the mandibular canal and usually contain branches of the inferior alveolar nerve (Fuakami et al., 2011; Katakami et al., 2008; Naitoh et al., 2009a).

The prevalence of AMFs varies in differ-

*Submitted:* 14 December, 2016. *Accepted:* 17 March, 2017.

ent ethnic groups. Hanihara and Ishida (2001) reported the highest AMF occurrence rate in the Kazakhs (more than 30% of cases), based on the analysis of anatomical data collected from representatives of 81 populations. AMFs were detected in almost 20% of Russians and less than 5% of the British. The frequency of AMFs detection using the Cone Beam Computed Tomography (CBCT) was found to be 3.2% in Brazil (Leite et al., 2014), 6.3 - 6.5% in Turkey (Kalender et al., 2012; Göregen et al., 2013), 7% in Japan (Naitoh et al., 2009a), 8.1% in Korea (Han et al., 2016) and 13% in Spain (Muñelo-Lorenzo et al., 2015). Nutrient foramina in the buccal cortical plate are much more common than AMF. According to Naitoh et al. (2009b), BFs were found in 44% of cases between the midline and level of mandibular molars, and only in 7% of them joined the mandibular canal i.e. were defined as AMF.

The anterior jaw bones are often considered relatively safe surgical sites. Nonetheless, the increasing rate of surgical interventions in that area, such as oral implant placement and bone grafting, has highlighted the potential risks of complications (Garay and Cantin, 2013; Arquez, 2014; Aykol et al., 2015; Iwanaga et al., 2015; Sisman et al., 2012). A careful documentation of all anatomic variations in anterior jaw bone neurovascularization has thus become necessary (Salinas-Goodier et al., 2016).

The aim of the present report was to describe the presence of accessory foramina in the anterior mandible and to discuss the practical impact of these anatomical variations. We considered AMF as a foramen connecting with mandibular canal and smaller than MF.

All CBCT scans were performed on Galileos GAX5 (Sirona Dental Systems, Bensheim, Germany) using standard settings (85 kV; tube current: 5-7 mA; acquisition period: 14 s; effective radiation time: 2-6 s; voxel size: 0.3 × 0.3 × 0.3 mm). Reformatted sagittal and axial CBCT im-

ages were analyzed using GALILEOS Viewer 1.9 (Sirona, Bensheim, Germany).

## RESULTS

### Case 1

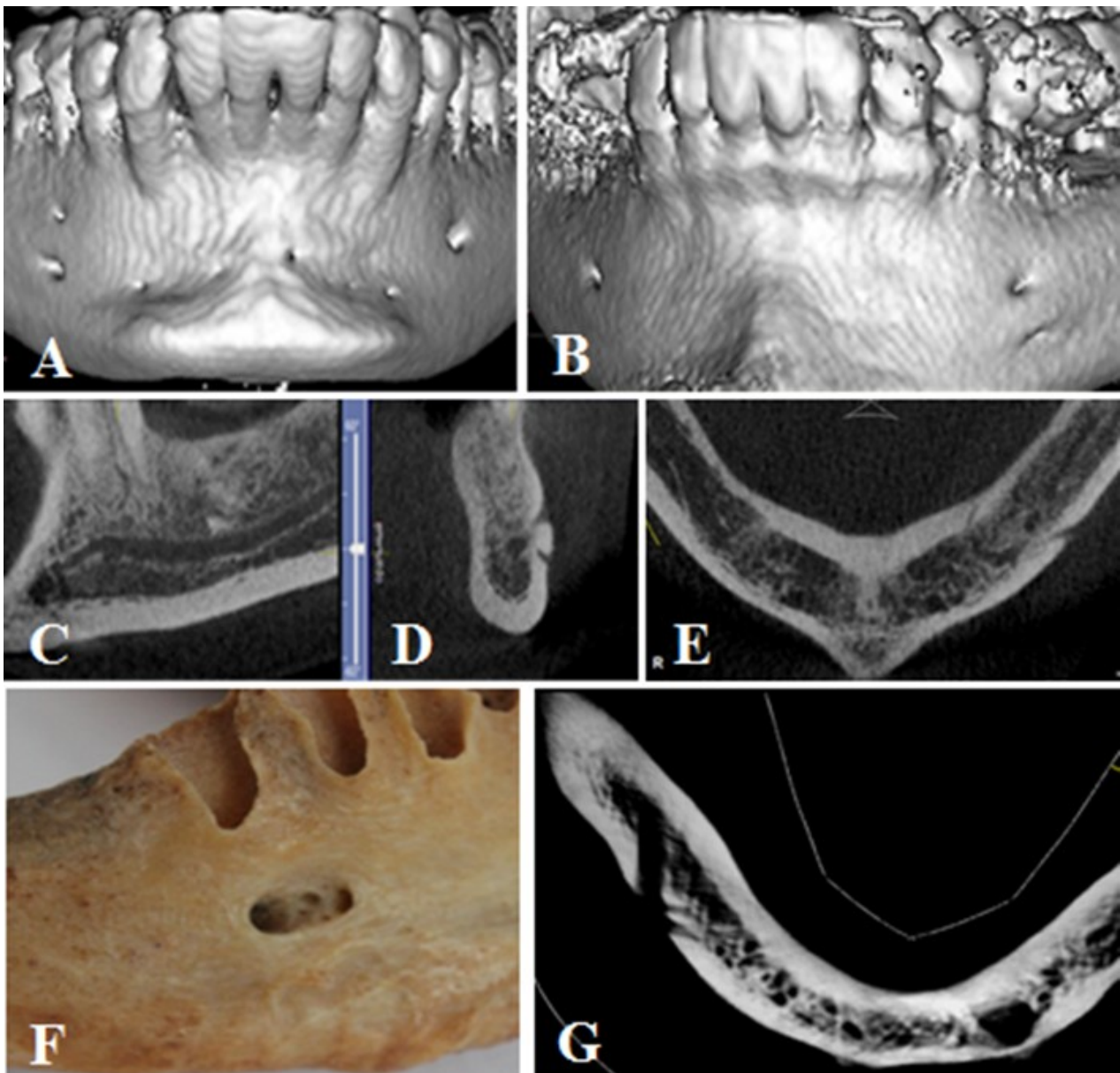
In 2016 March, after obtained signed consent form, a 35-year-old Caucasian woman was referred for CBCT examination by dentist of the outpatient clinic due to a chronic inflammatory process in the area of a partially erupted left lower third molar. The mandibular canal was visualized as a radiolucent strip with well-defined smooth borders formed by thin linear shadows of high intensity (cortical plate).

The right mandibular canal could be traced from the mandibular foramen to the level of the second premolar. At this point two lateral branches were detected departing from the inner contour of the vestibular cortical plate. The main canal's diameter was 3.1 mm at the starting point and 2.7 mm at the point of division into two lateral branches. The largest of the lateral branches, which was 2.8 mm in length and 2.1 mm in diameter, deviated from the main canal at the right angle and it terminated at the MF, which is located on the buccal surface of the mandibular body between premolars (closer to the root of the second premolar). The vertical and horizontal dimensions of that foramen were found to be 2.0 mm and 2.5 mm respectively. It was located 7.3 mm from the root apex of the second premolar, 10.3 mm from the base of the mandible and 14.7 mm from the alveolar ridge. The smaller lateral branch deviated from the main canal at the angle of 58.9 degrees, pierced the buccal cortical plate and terminated at the AMF 2.0 mm mesially to the root apex of the second premolar and 5.1 mm upwards from the MF (Fig. 1A). The vertical and horizontal dimensions of the AMF were 1.3 mm and 1.8 mm respectively. The distance to the base of the mandible was 16.1 mm and to the alveolar ridge – 9.8 mm. On the mesial aspect the mandibular canal extended directly into the

mandibular incisive canal with the diameter of 1.6 mm at the starting point.

The left mandibular canal had one lateral branch in its distal part, which terminated at the MF on the buccal surface of the mandibular body between the roots of the premolars closer to the second premolar (5.7 mm from its root apex). The vertical and horizontal dimensions were 2.6 mm and 3.1 mm respectively.

Beside the AMF, additional buccal and lingual holes of exit were also detected in this patient. Totally 6 BFs have been found, the largest of which was located 8.21 mm from the root of the left central incisor, 7.7 mm from the root of the left canine, and 5.9 mm from the root of the right canine. Those openings led into the buccal perforating canals that penetrated into the vestibular cortical plate by 1.8



**Fig.1.-** Accessory buccal and lingual foramina of anterior mandible.

1 – mental foramen; 2 – accessory mental foramen; 3 – lingual lateral foramen; 4 – mandibular incisive canal; 5 – mandibular canal; buccal foramina (black arrows); 6 – alveolar canal.

CBCT: A, B – three-dimensional reconstruction; C – coronal, D – sagittal; E, G – axial sections. F – dry mandible (right side, macroscopic view). Case 1 (A); case 2 (B, C, D, E); case 3 (F, G).

mm, 2.7 mm and 3.3 mm, respectively (Fig. 1A). Any communication of those canals with the mandibular incisive canal was not found.

In the middle of mandible body on its lingual side a LF of 0.4 mm in diameter was found. It was located down from the genial spines and led to the canal of 6.6 mm in length. Its diameter decreased from the outer cortical plate to the deeper part of the spongy substance.

### Case 2

A 57-year-old Caucasian woman in 2016 September after obtained signed consent form was referred for CBCT examination by dentist of the outpatient clinic because of restorative treatment planning needs.

On the left side the mandibular canal could be traced from the mandibular foramen to the level of the second premolar. At that point two lateral branches departed from the inner contour of the vestibular cortical plate. The diameter of the mandibular canal at the starting point was 3.4 mm narrowing down to 2.5 mm at the point of division into two lateral branches. The larger lateral branch was 1.5 mm in width, left the main canal at an angle of 40 degrees and ran for 4.2 mm to the buccal surface of the mandibular body between the roots of premolars (closer to the root of the first premolar), where it opened with the MF. The size of the MF was 2.1 (vertical) x 2.8 (horizontal) mm. It was located at the distance of 2.3 mm from the first premolar's root apex, 12.1 mm from the base of the mandible and 13.4 mm from the alveolar ridge. The second (smaller) branch of the mandibular canal extended downwards at an angle of 21.4 degrees, pierced the buccal cortical plate and opened with the AMF at the distance of 7.3 mm from the first premolar's root apex and 3.6 mm down from the mental foramen (Fig. 1B). The size of AMF was 0.9 (vertical) x 0.9 (horizontal) mm. It was located at the distance of 8.3 mm from the base of the mandible and 18.0 mm from the alveolar ridge (Fig. 1B).

The mandibular canal continued directly

to the mandibular incisive canal in the anterior part of mandible being 1.9 mm in diameter at the starting point (Figs. 1C, D).

The right mandibular canal had one lateral branch in its distal part, which terminated with the MF on the buccal surface of the mandibular body between the roots of premolars closer to the first premolar (at the distance of 3.8 mm from its root). The size of the foramen was 1.9 (vertical) x 2.5 (horizontal) mm.

Besides the AMF, three additional lingual foramina (LFs) were also found in this patient. The central foramen with the diameter of 1.3 mm on the sagittal section and 1.0 mm on axial section was located above genial spines and led to the canal of 9.8 mm in length. Its diameter decreased from 1.0 mm in the outer cortical plate to 0.6 mm deeper in the spongy substance. The right lateral LF was located at the canine root level in the range of 19.7 mm from the alveolar crest and 8.3 mm from the base of the mandible. It led into the canal of 7.43 mm in length, represented as a thin radiolucent strip in the compact and cancellous bone, which was oriented at an angle of 58.1 degrees to the bone surface and connected to the mandibular incisive canal.

The left lateral LF was located at the level of the first premolar in the range of 18.19 mm from the alveolar crest and 9.7 mm from the base of the mandible. It led into the canal of 8.9 mm in length, which was oriented at an angle of 15.9 degrees to the bone surface and connected to the mandibular incisive canal (Fig. 1E).

### Case 3

Two grooves of 6.7 mm (right) and 6.2 mm (left) in length and 4.3 mm and 3.9 mm in width respectively were detected on both sides on the buccal surface of the dry mandibular body from an adult human cadaver of an unknown sex and age from the collection of anatomical specimens of Belarusian State Medical University. Foramina were present on each side of the grooves.

Mandibular canal with well-defined corticalization of the walls were detected on the CBCT scans. It began from the mandibular foramen on the lingual surface of the mandibular ramus, passed in the mesial direction, gradually approaching the vestibular cortical plate. In the area between the second premolar and the first molar on the right and left sides of the mandible it pierced the inner contour of the cortical plate and went obliquely forward. The angulation of canals in relation to the vestibular surface of the bone was 26.9 and 23.8 degrees; and the length within the cortical plate was 4.1 mm and 3.9 mm on the right and left sides respectively. Each canal terminated with MF at the distal end of the grooves located on the buccal surface of the mandibular body.

Two foramina were found in the mesial end of the groove at the level of the right first premolar. The smaller one (1.3 mm x 0.9 mm) led into the intraosseous alveolar canal, which passed obliquely upwards and forwards in the direction of the dental alveolus of the first premolar (Figs. 1F, G). The second foramen also transformed in the canal within the bone. It passed forward and was defined as the incisive mandibular canal (Figs. 1F, G).

One foramen was found in the mesial end of the left groove at the level of the left first premolar, extending in the mandibular incisive canal.

## DISCUSSION

Identified defects of the buccal cortical plate of the mandibular body were classified as MF, AMF and additional or nutrient foramina.

The main features suggesting a defect of the buccal cortical plate of the mandibular body to be an additional foramen are its location, size and connection with the mandibular canal. Out of all foramina found in this study two were just additional exits from the mandibular canal (AMF). One of them was located at the root apex of the right second premolar upwards from

the MF, almost in the middle of the distance between the base of the mandible and the alveolar ridge with a slight deviation towards the base. The second foramen was detected between the first and second left premolars downwards from the MF in almost 2 times closer to the base of the mandible than to the alveolar ridge. According to Iwanaga et al. the AMF appears to be located most commonly posterior to MF rather than anterior (Iwanaga et al., 2015). The highest percentage of AMF was found under the second premolar (Garay and Cantin, 2013).

Muinelo-Lorenzo et al. (2015) found that the size of MF in the presence of adjacent AMF was considerably smaller than on the opposite side. We observed the same pattern only in one of two cases of unilateral AMF presence.

AMF region is the additional trigger point in the peripheral trigeminal nerve, a neuralgia irritation of which provokes pain attacks. Persistence of neuralgic pain after neurectomy of the mental nerve is usually caused by retaining of an additional branch of the inferior alveolar nerve, passing through the AMF (Jha and Kumar, 2012).

The foramina identified in the present study on the dry mandible are classified as mental, alveolar and incisive canal foramina. As seen on CBCT scans, mental and incisive canal foramina were located along the horizontal line. The greater foramen was located posterior to the smaller one. The mandibular canal configuration showed that the canal shifted in the direction of the mesial vestibular cortical plate and terminated on the bone surface with the MF first. Then the groove passed into the bone as the incisive foramen of the mandible. This variation of the mental foramen region corresponds to the findings of Serman (1989) and Fuakami et al. (2011). Authors observed one of the branches of mental nerve returning into the bone through the additional foramen on the buccal surface of the mandibular body and directing to anterior teeth.

Besides the AMF and incisive canal foramen the present study disclosed other additional foramina, which were located on the buccal and/or lingual surfaces of the mandibular body.

LFs were reported to be at the level of first premolars (lateral LFs), as well at the midline (medial LFs), above and below the genial spine. The LFs revealed in dry mandible and by modern methods of radiological studies with a frequency of 80-100% (Liang et al., 2007; Von Arx et al., 2011; Sheikhi et al., 2012; Bernardi et al., 2014). The LFs are nutrient in nature because they contain vessels and nerves. They open into the canals, perforating the outer cortical plate and passing inside the bone to different depths. Canals located above the genial spine contain branches of the lingual artery and nerve, and there are branches of the submental and/or sublingual artery, as well as a branch of the mylohyoid nerve in canals located below the genial spine (Liang et al., 2007). The size of LFs found in the present study ranged from 0.51 to 1.01 mm. The diameter of LFs greater than 1 mm indicates the presence of a quite large arterial branch damaging which may cause a profuse hemorrhage (Sheikhi et al., 2012).

## CONCLUSION

In the present study we discovered and described rare variations of the location of several additional foramina and their combinations in the mandible. They were well visualized in vivo with the help of CBCT with an accuracy that is comparable to anatomical studies ex vivo. Information about individual variability of the additional foramen topography is of a high demand among practitioners. The detection of these foramina reduces risks of iatrogenic damage during dental procedures, increases the effectiveness of the mandibular anesthesia and helps in differential radiographic diagnosis of different kinds of pathology in the mandible.

## ACKNOWLEDGEMENTS

The authors wish to express their gratitude to the Belarusian State Medical University, institution responsible for research support and/or financial support.

## REFERENCES

- ALSAAD K, LEE TC, MCCARTAN B (2003) An anatomical study of the cutaneous branches of the mental nerve. *Int J Oral Maxillofac Surg*, 32(3): 325-333.
- ARQUEZ HF (2014) Accessory nerve and mental nerve. *Int J Pharm Bio Sci*, 5(4): 739-744.
- AYKOL S, ORDUYILMAZ F, GUMUSOK M, OZMERIC N, ALKURT MT (2015) Imaging of accessory mental foramen before implant therapy. *J Oral Maxillofac Radiol*, 3(3): 105-107.
- BERNARDI S, RASTELLI C, LEUTER C, GATTO R, CONTINENZA MA (2014) Anterior mandibular lingual foramina: an in vivo investigation. *Anat Res Int*, 2014: 906348. doi: 10.1155/2014/906348.
- DI BARI R, CORONELLI R, CICCONE A (2014) Intraosseous vascularization of anterior mandible: a radiographic analysis. *J Craniofac Surg*, 25(3): 872-879.
- FUAKAMI K, SHIOZAKI K, MISHIMA A, SHIMODA S, HAMADA Y, KOBAYASHI K (2011) Detection of buccal perimandibular neurovascularisation associated with accessory foramina using limited cone-beam computed tomography and gross anatomy. *Surg Radiol Anat*, 33(2):141-146.
- GARAY I, CANTÍN M (2013) Accessory mental foramina assessed by cone-beam computed tomography: Report of unilateral and bilateral detection. *Int J Morphol*, 31(3): 1104-1108.
- GÖREGEN M, MILOĞLU Ö, ERSOY I, BAYRAKDAR İŞ, AKGÜL HM (2013) The assessment of accessory mental foramina using cone-beam computed tomography. *Turk J Med Sci*, 43: 479-483.
- HAN SS, HWANG JJ, JEONG HG (2016) Accessory mental foramina associated with neurovascular bundle in Korean population. *Surg Radiol Anat*, [Epub ahead of print].
- HANIHARA T, ISHIDA H (2001) Frequency variations of discrete cranial traits in major human populations. IV. Vessel and nerve related variations. *J Anat*, 199(Pt 3): 273-287.
- HU KS, YUN HS, HUR MS, KWON HJ, ABE S, KIM HJ (2007) Branching patterns and intraosseous course of the mental nerve. *J Oral Maxillofac Surg*, 65(11): 2288-2294.
- IMADA TS, FERNANDES LM, CENTURION BS, DE OLIVEIRA-SANTOS C, HONÓRIO HM, RUBIRABULLEN IR (2014) Accessory mental foramina: prevalence, position and diameter assessed by cone-beam computed tomography and digital panoramic radiographs. *Clin Oral Implants Res*, 25(2): e94-99.
- IWANAGA J, SAGA T, TABIRA Y, NAKAMURA M, KITASHIMA S, WATANABE K, KUSUKAWA J, YAMAKI K (2015) The clinical anatomy of accessory mental

- nerves and foramina. *Clin Anat*, 28(7): 848-856.
- IWANAGA J, WATANABE K, SAGA T, TABIRA Y, KITASHIMA S, KUSUKAWA J, YAMAKI K (2016) Accessory mental foramina and nerves: Application to periodontal, periapical, and implant surgery. *Clin Anat*, 29(4): 493-501.
- JHA AK, KUMAR NG (2012) Accessory mental nerve: case report, review and its role in trigeminal neuralgia. *Surg Radiol Anat*, 34: 469-473.
- KALENDER A, ORHAN K, AKSOY U (2012) Evaluation of the mental foramen and accessory mental foramen in Turkish patients using cone-beam computed tomography images reconstructed from a volumetric rendering program. *Clin Anat*, 25(5): 584-592.
- KATAKAMI K, MISHIMA A, SHIOZAKI K, SHIMODA S, HAMADA Y, KOBAYASHI K (2008) Characteristics of accessory mental foramina observed on limited cone-beam computed tomography images. *J Endod*, 34: 1441-1445.
- LEITE GM, LANA JP, DE CARVALHO MACHADO V, MANZI FR, SOUZA PE, HORTA MC (2014) Anatomic variations and lesions of the mandibular canal detected by cone beam computed tomography. *Surg Radiol Anat*, 36(8): 795-804.
- LIANG X, JACOBS R, LAMBRICHTS I, VANDEWALLE G (2007) Lingual foramina on the mandibular midline revisited: a macroanatomical study. *Clin Anat*, 20(3): 246-251.
- LOYAL PK, BUTT F, OGENG'O JA (2013) Branching pattern of the extraosseous mental nerve in a Kenyan population. *Craniofacial Trauma Reconstr*, 6(4): 251-256.
- MUINELO-LORENZO J, SUÁREZ-QUINTANILLA JA, FERNÁNDEZ-ALONSO A, VARELA-MALLOU J, SUÁREZ-CUNQUEIRO MM (2015) Anatomical characteristics and visibility of mental foramen and accessory mental foramen: Panoramic radiography vs. cone beam CT. *Med Oral Patol Oral Cir Bucal*, 20(6): e707-714.
- NAITOH M, HIRAIWA Y, AIMIYA H, GOTOH K, ARIJI E (2009a) Accessory mental foramen assessment using cone-beam computed tomography. *Oral Surg Oral Med Oral Pathol Oral Radiol Endod*, 107(2): 289-294.
- NAITOH M, NAKAHARA K, HIRAIWA Y, AIMIYA H, GOTOH K, ARIJI E (2009b) Observation of buccal foramen in mandibular body using cone-beam computed tomography. *Okajimas Folia Anat Jpn*, 86(1): 25-29.
- PARASKEVAS G, MAVRODI A, NATSIS K (2015) Accessory mental foramen: an anatomical study on dry mandibles and review of the literature. *Oral Maxillofac Surg*, 19(2): 177-181.
- PATIL S, MATSUDA Y, OKANO T (2013) Accessory mandibular foramina: a CT study of 300 cases. *Surg Radiol Anat*, 35(4): 323-330.
- SALINAS-GOODIER C, MANCHÓN Á, ROJO R, COQUERELLE M, SAMMARTINO G, PRADOS-FRUTOS JC (2016) Prevalence and location of accessory foramina in the human mandible. *Oral Radiol*, 32: 72. doi:10.1007/s11282-015-0212-x.
- SERMAN NJ (1989) The mandibular incisive foramen. *J Anat*, 167: 195-198.
- SHEIKHI M, MOSAVAT F, AHMADI A (2012) Assessing the anatomical variations of lingual foramen and its bony canals with CBCT taken from 102 patients. *Dent Res J (Isfahan)*, 9(Suppl 1): S45-S51.
- SINGH, SRIVASTAV AK (2010) Study of position, shape, size and incidence of mental foramen and accessory mental foramen in Indian adult human skulls. *Int J Morphol*, 28(4): 1141-1146.
- SISMAN Y, SAHMAN H, SEKERCİ A, TOKMAK TT, AKSU Y, MAVILI E (2012) Detection and characterization of the mandibular accessory buccal foramen using CT. *Dentomaxillofac Radiol*, 41(7): 558-563.
- STANDRING S, editor (2016) Gray's Anatomy. The anatomical basis of clinical practice. 41th Ed., Elsevier Churchill Livingstone.
- TOH H, KODAMA J, YANAGISAKO M, OHMORI T (1992) Anatomical study of the accessory mental foramen and the distribution of its nerve. *Okajimas Folia Anat Jpn*, 69(2-3): 85-88.
- TRESCOT AM, editor (2016) Peripheral Nerve Entrapments: Clinical Diagnosis and Management.
- VON ARX T, MATTER D, BUSER D, BORNSTEIN MM (2011) Evaluation of location and dimensions of lingual foramina using limited cone-beam computed tomography. *J Oral Maxillofac Surg*, 69(11): 2777-2785.