

A rare variation of the celiac trunk: a case report

Constanze Nossol, Stephanie Henel, Julius Brosch, Christina Maria Junghans, Olaf Laddey, Sebastian Bartel, Hermann-Josef Rothkötter

Institute of Anatomy, Medical Faculty, Otto-von-Guericke University Magdeburg, Leipziger Strasse 44, 39120 Magdeburg, Germany

SUMMARY

Vascular variations of visceral arteries are common and usually asymptomatic, but they become important in patients suffering from gastrointestinal bleeding and undergoing diagnostic angiography or an invasive vascular catheter intervention or operative procedure. In our institute about 200 anatomical specimens were dissected in the last ten years. However, a gastroduodenal artery as a branch of the celiac trunk and a separated duodenal artery, originated from the left proper hepatic artery, were found for the first time. Furthermore, we observed a second left gastric artery that supplies the fundic area of the stomach. Arterial variations are very important in abdominal operative procedures and they need to be known in order to avoid complications in clinical medicine during radiological and surgical interventions.

Key words: Anatomical variation – Celiac trunk – Gastroduodenal artery – Duodenal artery – Proper hepatic artery

INTRODUCTION

The celiac trunk (CT), with its trifurcation into the left gastric artery (LGA), the common hepatic artery (CHA) and the splenic artery (SA), is the first branch of the abdominal aorta and supplies the upper colic compartment. This anatomic structure

was first described as *tripus halleri* by Haller (1756). The largest branch of the celiac trunk is the splenic artery, which ascends to the left along the upper edge of the pancreas to the spleen. En route to the spleen it gives short gastric branches to the corpus, has pancreatic branches, and is the origin of the left gastroepiploic artery. The left gastric artery is the smallest one and moves upwards to the pars cardiac, and also supplies the oesophagus. The last of the three main branches is the common hepatic artery, which arises from the right side of the CT and gives origin to the right gastric artery and gastroduodenal artery. Vascular variations of the visceral arteries are common, and anatomic variances of the celiac trunk were also reported by many authors. In 1917, Lipshutz was the first that classified 4 types of variations: type I normal trifurcation, type II hepatosplenic trunk, type III hepatogastric trunk and type IV gastrosplenic trunk.

In 1928, Adachi modified the classification due to the inclusion of the superior mesenteric artery into 6 different types of variations with 28 forms (Adachi, 1928). This was followed by Michels (1966) and Uflacker (1997). Both classifications were nearly the same, but vary due to additional variations, e.g., “absence of the celiac trunk” (Uflacker, 1997). The classification of common variants makes sense and is useful, but knowledge of rare variations which were described by single observations is also very important because many vascular variants are usually asymptomatic. Due to the lack of symptoms, it is essential for general and transplantation surgeons, as well as for radiologists, to be aware of even rare variations.

Corresponding author: Dr. rer. nat. Constanze Nossol. Otto-von-Guericke University Magdeburg, Medical Faculty, Institute of Anatomy, Leipziger Strasse 44, 39120 Magdeburg, Germany. Phone: +49 (0) 391 67 21930; Fax: +49 (0) 391 6713630. E-mail: constanze.nossol@med.ovgu.de

Submitted: 10 March, 2016. *Accepted:* 7 July, 2016.

CASE REPORT

In the dissection course, we detected interesting variations of the CT (Fig. 1A). At the level of the 12th thoracic vertebra and the corresponding rib, the CT was observed with a total length of 1 cm and a diameter of 1.2 cm. The CT separated into five different arteries (pentafurcation). After 1.2 cm of the CT, two branching arteries were observed, namely the inferior phrenic artery (RIPA and LIPA; diameter: 0.3 cm) directing to the diaphragm including a branch to the oesophagus. After a length of 5 cm the inferior phrenic artery provided a branch that was the suprarenal artery.

In addition to this variation the CT showed 3 additional vessels: left gastric artery (LGA), gastroduodenal artery (GDA) and splenic artery (SA). The splenic artery (length: 13 cm; diameter: 1.2 cm) followed the normal anatomical course and after 7 cm the left gastroepiploic artery was leaving the splenic artery.

However, no short gastric arteries as branches of the splenic artery were found. In contrast, the left gastric artery divided (after 2.5 cm) into separate branches: a left proper hepatic artery and some short gastric arteries. Furthermore, an additional left gastric artery was found as a separate branch of the left proper hepatic artery. This left gastric artery directed to the fundic area of the stomach (Fig. 1B). The gastroduodenal artery (originating from the CT), divided after 8 cm (diameter: 1 cm) into a superior pancreaticoduodenal and a right gastroepiploic artery.

Two centimetres below the CT, the superior mesenteric artery (SMA) was found having a diameter of 1.2 cm. Its first branch was the right proper hepatic artery, having a total length of 6.5 cm. At a distance of 1.5 cm, one duodenal artery separated from the right proper hepatic artery and it divided into 4 arteries supplying the superior and descending parts of the duodenum (Fig. 2).

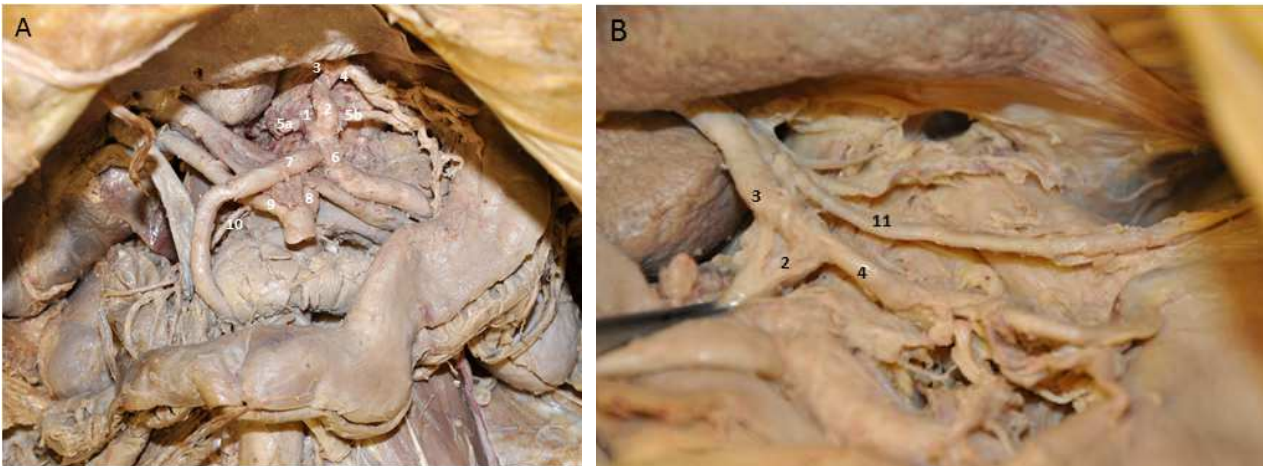


Fig. 1. Gastroduodenal artery as a branch of celiac trunk (A) and additional left gastric artery arising from the left proper hepatic artery (B). 1: celiac trunk; 2: left gastric artery; 3: left proper hepatic artery; 4: left gastric artery; 5a: left superior suprarenal artery; 5b: right superior suprarenal artery; 6: splenic artery; 7: gastroduodenal artery; 8: superior mesenteric artery; 9: right proper hepatic artery; 10: duodenal artery; 11: additional left gastric artery (to fundus).

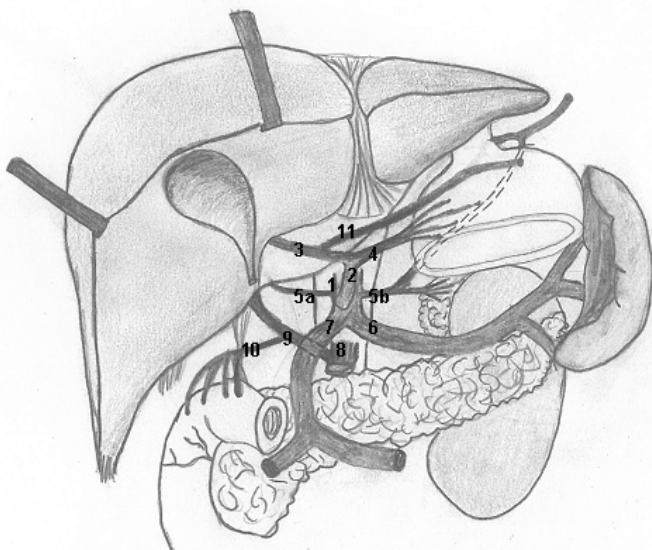


Fig. 2. Hand drawing of the anatomical structures. (Pencilled by Stephanie Henel). 1: celiac trunk; 2: left gastric artery; 3: left proper hepatic artery; 4: left gastric artery; 5a: left superior suprarenal artery; 5b: right superior suprarenal artery; 6: splenic artery; 7: gastroduodenal artery; 8: superior mesenteric artery; 9: right proper hepatic artery; 10: duodenal artery; 11: additional left gastric artery (to fundus).

DISCUSSION

With the focus on Adachi's classification with 6 different types and 28 forms, we could not include our case report to any classification type of Adachi (1928).

Michels' classification resulted in 7 types from type I normal branching to type VII celiacocolic trunk (Michels, 1955) and Vandamme and Bonte (1985) examined 156 cadavers. Their classification resulted in 4 different types but our findings could not be related to any type of them. Hiatt and co-workers took the study of 1000 organs as basis for their new classification (Hiatt et al., 1994).

They compose a sub-division into 6 types. Type I (normal anatomical type) was found in 77.5% of the cases. This goes along with the findings of Lippert and Pabst (1985).

They detected a normal anatomical type in 76% of all cases. Our findings relate to type IV (RHA from LGA and LHA from SMA). Furthermore, Chen and collaborators prepared a new classification due to the absence of rare variants of the hepatic arterial origins (Cheng et al., 2009). They split variations into seven types with the incidence of the hepatic arterial anatomy. With the restricted focus on the hepatic arteries, we could relate our findings partly to type VIb with an observed probability of 0.3% (Cheng et al., 2009). Babu and Khrab (2013) proposed a new classification which vary from type I normal trifurcation to type VI (d) celiaphrenic Trunk (CT + RIPA +LIPA) (Babu and Khrab, 2013). In our report, we found a pentafurcation of the CT: RIPA, LIPA, LGA, SA and GDA. This variation could not be allocated to any trunk classification number of Babu and Khrab (2013). Type VI (d) was classified as pentafurcation showed the branches of: RIPA, LIPA, LGA, SA and SMA (Babu and Khrab, 2013). Marco-Clement and co-workers (2016) classified 4 types: 1. complete CT, 2. incomplete trunk, 3. absence of the trunk and 4. celiacomesenteric trunk. In 86% of the cadavers and 90.8% of the CT-angiographies with a total result of 90.5% of all cases a complete CT was found, but the classification of Marco-Clement and co-worker disregarded the SMA as an origin of hepatic arteries. Mariani et al. (2013) reported about the existence of hepato-gastric and spleno-mesenteric arterial trunks instead of a CT. In contrast, only one report of a gastroduodenal artery was described as a 4th branch of the CT (Chitra, 2009). The most common origin of a "non CT origin" gastroduodenal artery is the superior mesenteric artery (0.8% of all cases) described by Song et al. in 2010. In our case, we detected a gastroduodenal artery as 3rd branch, but also a right proper hepatic artery as a branch of superior mesenteric artery, which gives origin for a duodenal artery. In our institute about 200 anatomical specimens were dissected in the last ten

years. However, a gastroduodenal artery as a 3rd branch of the CT and a separated duodenal artery were found for the first time.

In conclusion, arterial variations are very important in abdominal operative procedures and they need to be known in order to avoid complications in clinical medicine during radiological and surgical interventions.

REFERENCES

- ADACHI B (1928) Anatomie der Japaner I. Das Arteriensystem der Japaner. Band II. Kaiserlich-Japanischen Universität zu Kyoto. Maruzen Publishing Co., Kyoto, pp 20-71.
- CHENG H, YANO R, EMURA S, SHOUMURA S (2009) Anatomic variation of the celiac trunk with the special reference to hepatic artery patterns. *Ann Anat*, 191: 399-407.
- CHITRA R (2009) Clinical relevance of a rare variation in the origin of gastroduodenal artery. *Int J Anat Variation*, 2: 60-70.
- HALLER AV (1756) *Lcones Anatomicae in Quibus Praecipuae Partes Corporis Humani Delineate Pronuntur et Arteriarum Potissimum Historia Continuer*. Vandenhoeck, Gottingen.
- HIATT JR, GABBAY J, BUSUTTIL RW (1994) Surgical anatomy of the hepatic arteries in 1000 cases. *Ann Surg*, 220(1): 50-52.
- LIPPERT H, PABST R (1985) Arterial variations in man. Classification and frequency. Bergmann, München.
- MARCO-CLEMENT I, MARTINEZ-BARCO A, AHUMADA N, SIMON C, VALDERRAMA JM, SANUDO J, ARRAZOLA J (2016) Anatomical variations of the celiac trunk: cadaveric and radiological study. *Surg Radiol Anat*, 38: 501-510.
- MARIANI GM, MARONI L, BIANCHI L, BROCCOLI A, LAZZARINI E, MARCHEGIANI, MAZZOTTI A, MAZZOTTI MC, BILLI AM, PICCARI GG, COCCO L, MANZOLI L (2013) Hepato-gastric and spleno-mesenteric arterial trunks: anatomical variation report and review of literature. *Ital J Anat Embryol*, 118(2): 217-222.
- MICHELS NA (1955) Blood supply and anatomy of the upper abdominal organs with a descriptive atlas. JB Lippincott, Philadelphia, 581: 136-147.
- LIPSHUTZ B (1917) A composite study of the celiac axis artery. *Ann Surg*, 65: 159-169.
- SONG SY, CHUNG JW, YIN YH, JAE HJ, KIM HC, JEON UB, CHO BH, SO YH, PARK JH (2010) Celiac axis and common hepatic artery variations in 5002 patients: systematic analysis with spiral CT and DSA. *Radiol*, 255(1): 278-288.
- UFLACKER R (1997) Atlas of vascular anatomy: an angiographic approach. Williams & Wilkins, Baltimore. Cited in the *Brit J Anat*, 83: 661-667 (2010).
- VANDAMME JP, BONTE J (1985) The branches of a celiac trunk. *Acta Anat*, 122: 110-114.