

# Median nerve motor entry points in the forearm - clinical application

Ehab M. El Zawawy<sup>1</sup>, Nancy M. El Sekily<sup>1</sup>, Wael A. Fouad<sup>2</sup>,  
Mohamed H. Emam<sup>3</sup>, Marwa M. Hassan<sup>3</sup>

<sup>1</sup>Department of Anatomy and Embryology, Faculty of Medicine, Alexandria University, Alexandria, Egypt,

<sup>2</sup>Department of Neurosurgery, Faculty of Medicine, Alexandria University, Alexandria, Egypt,

<sup>3</sup>Department of Physiotherapy, Faculty of Medicine, Alexandria University, Alexandria, Egypt

## SUMMARY

Superficial forearm flexors receive primary and secondary branches from the median nerve (mn). These branches vary in number, size and motor entry points (m) into the muscles. Knowledge of these points is essential for maximal compound muscle action potential (cmap) recording from these muscles. Spasticity of these flexors is treated using botulinum toxin (bt) injection or selective partial neurotomy (spn) of the nerve branches to the spastic muscles. Twenty human cadaveric forearms were dissected. The location of the motor entry points of the median nerve to the superficial forearm flexor muscles was expressed as a distance from the medial (me) and lateral (le) epicondyles of the humerus. Fifty apparently healthy volunteers (25 males and 25 females) underwent cmap recording from the superficial forearm flexors. Thirty patients (15 males and 15 females) with spastic hyperflexion of the wrist and fingers underwent bt injection or spn. Pronator teres (pt) had 2-4 m, flexor carpi radialis (fcr) had 1-3 m and flexor digitorum superficialis (fds) had 3-8 m. Variable shapes of the cmap were recorded from them (monophasic, biphasic or multiphasic). Based on the anatomical results, bt injection was done at 5 points (p1-p5); pt was injected at p1, fcr was injected at p2, and fds is a large muscle and was injected at p3, p4, p5 (proximal, middle, distal), giving

good results in 85% of cases; spn was done in severe cases refractory to bt injection with excellent to good results in 80% of cases. The patterns of branching of mn differ from the classically described patterns. Therefore, revising the innervation patterns of the superficial forearm flexors is mandatory, since the variations observed are more diverse than has been described. Identification of the branches and the motor entry points of mn are essential for cmap recording from the superficial forearm flexors, bt injection, spn and tendon transfer.

**Key words:** Branching patterns – Forearm flexors – Compound muscle action potential recording – Botulinum toxin

## INTRODUCTION

The muscle motor points are the sum of the primary and/or secondary branches of a motor nerve entering the muscle. The primary branches arise from the main nerve trunk, while secondary branches arise from the primary branch. Each muscle of the superficial forearm flexors has multiple motor entry points (Liu et al., 1995; Liu, 1997a, b).

As stated in the literature, the median nerve (mn) classically gives two branches, superior and inferior for the 2 heads of pronator teres (pt); the superficial head (s) and the deep head (d), a common trunk for flexor carpi radialis (fcr) and palmaris lon-

**Corresponding author:** Dr. Nancy Mohamed El Sekily.

Department of Anatomy and Embryology, Faculty of Medicine,  
Alexandria University, Alexandria, Egypt.

E-mail: nancyelsekily@yahoo.com

Submitted: 28 June, 2015. Accepted: 17 November, 2015.

gus (pl) and a single branch for flexor digitorum superficialis (fds) (Gunther et al., 1992). The part of fds to the index finger may be supplied from the anterior interosseous nerve (ai) (Standing et al., 2005). Many anatomists have reported that the median nerve may exhibit a different distribution from this classical pattern (Abd-Elhamid, 2008; Canovas, 1998; Chantelot, 1999; Safwat and Abdel-Meguid, 2007; Sunderland and Ray, 1947). Knowledge of these patterns is important for tendon and nerve transfer in the forearm (Yavari, 2014).

For maximal compound muscle action potential (cmap) recording from the superficial forearm flexor muscles, the exact location of the motor entry points is essential for the precise insertion and the suitable selection of the number of electrodes used for these muscles (Popovic et al., 1991; Wu et al., 2002).

Muscular spasticity of the wrist and fingers is very common in hypertonic cerebral palsy and post-stroke patients. This involves flexor muscle groups of the wrist and fingers and pronators of the forearm (Kong and Chua, 2005). Spasticity is treated through either botulinum toxin (bt) injection into the motor entry points (Won et al., 2010), or selective partial neurotomy (spn) of the nerve branches to the spastic muscles (Msaddi et al., 1997; Page et al., 2003).

The aim of this work was to determine the median nerve branches and their precise motor entry points to the superficial forearm flexor muscles.

## MATERIALS AND METHODS

### **Anatomical study**

Twenty human adult (between the ages of 30 and 60 years) cadaveric forearms were obtained from the Anatomy Department, Faculty of medicine, Alexandria University. Both sides of five male and five female cadavers were dissected. The limbs were extended at the elbow, with the wrist in the neutral position. Midline volar incisions were made from above the elbow to the wrist. The median nerve and its branches were exposed and followed distally to the terminal nerve entry points into the superficial forearm flexor muscles. The number of the primary branches (p) arising from the main nerve trunk and the secondary branches (if found) arising from the primary branches to the individual muscles and their motor entry points (m) into the muscles were recorded. The location of the motor entry points was expressed as a distance from the medial (me) and lateral (le) epicondyles of the humerus. Forearm length was measured from the lateral epicondyle of the humerus to the styloid process of the radius. All measurements were done using a Vernier caliper.

### **Statistical analysis**

The statistical analysis was done using Statistical

Package for Social Sciences (SPSS/ version 15) software. Arithmetic mean, standard deviation and mode were calculated. For numerical data, t-test was used to compare between two groups. The level of significance was at  $p \leq 0.05$ .

### **Clinical study**

The clinical study was done in light of the anatomical results, and included fifty apparently healthy adult (between the ages of 30-60 years) volunteers (25 males and 25 females) from those attending the outpatient clinic of Physical Medicine, Rheumatology and Rehabilitation Department. All the included subjects signed informed consent. They had no neurological diseases that could affect their nerves. Motor conduction studies of the median nerve were done on both sides for the included subjects. Nohon Coden apparatus was used to conduct the tests. Surface recording using round silver 1× 1cm in diameter electrodes were used. The electrodes were applied to the skin through the use of gel after cleansing the skin with alcohol prior to application. Stimulation was done at the cubital fossa and recording from the superficial forearm flexors at the points explained in the anatomical results. The ground electrode was placed between active and stimulating electrodes (Kimura, 2001).

Those who had normal motor conduction study of the median nerve were included in the study. Analysis of the shape of cmap curve was performed, and correlation between it and the anatomical innervations of the forearm flexors was calculated.

Thirty adult (between the ages of 30 and 60 years) patients (15 males and 15 females) with spastic hyperflexion of the wrist and fingers, and attending the outpatient clinic of Department of Neurosurgery, were included in the study. Selection and assessment of patients were performed carefully, and this process included observation of posture, assessment of passive range of motion, orthopedic status (musculoskeletal contractures), and quantification of the degree of spasticity using modified Ashworth scale. All patients preoperatively had spasticity either grade 3 or 4 as measured by modified Ashworth scale.

When a motor block using anaesthetic or a first test using bt had given good functional results, bt injection was proposed first. Botulinum toxin type A (Botox) is dispensed as a freeze dried powder in vials containing 100 units of the toxin. The powder is reconstituted with 0.9% saline prior to use. Dosing of Botox is based on the number of units of toxin. 1 cc tuberculin syringe and a 27 gauge, 1.5 inch needle was used for injection. Correct placement of the needle was confirmed by muscle activation, ultrasound or electromyographic control. The target muscle was stretched and palpated, and the toxin was infiltrated into the area of maximal myoneural concentration, guided by previous

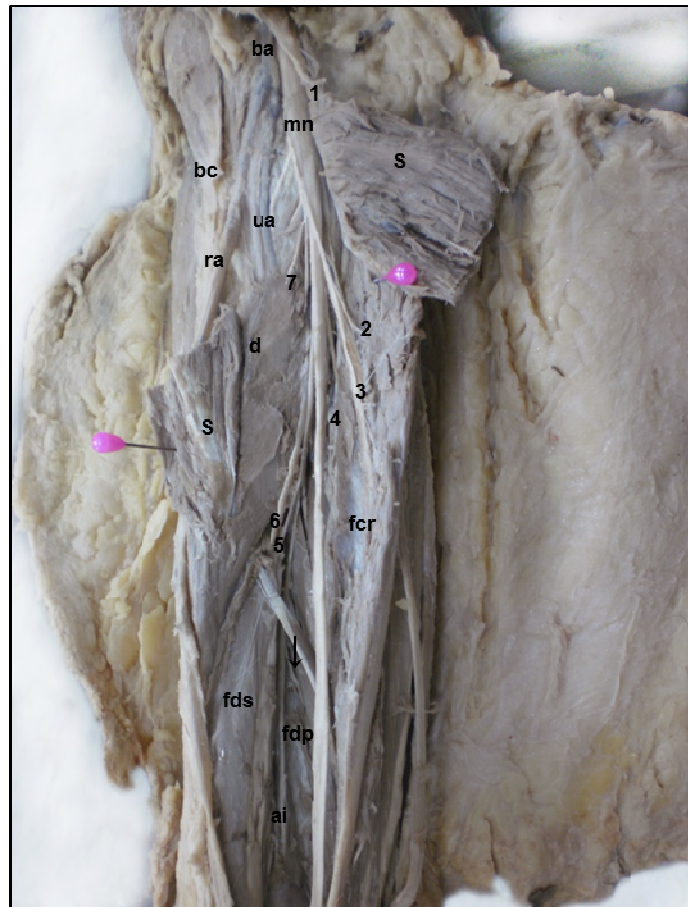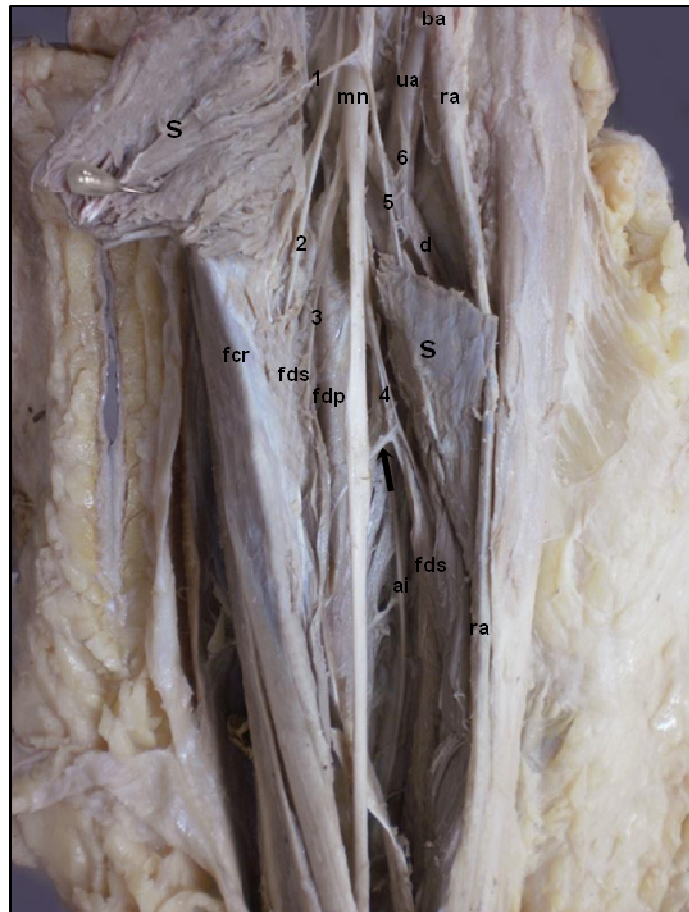
methods of control that were matched with results of the motor entry point and patterns of branching of the median nerve obtained from cadaveric dissection. Twenty cases had multiple injections of bt in the forearm flexors every 6 months at the points explained in the anatomical results. The number of repeated injections ranged from 3 to 6, with a mean follow-up examination period 24 months after the first injection.

Ten cases with severe spasticity involving multiple muscles and/or bt resistance underwent surgery in the form of spn of mn. 50–80% of the isolated motor branchlets were resected under the operating microscope. The amount of nerve fibers to be resected depended on the degree of preoperative spasticity, on maintaining residual force, on the result obtained by an anesthetic motor block, and on the response to intraoperative electrical stimulation after sectioning 50% of the fibers. The mean postoperative follow-up examination period was 21 months.

## RESULTS

### Anatomical results

The median nerve branched in a tree-like fashion as it entered the forearm in most specimens (Figs. 1, 2, 3). It passed in the plane between *fds* and *fdp* in all specimens (figs.1-10). *fds* formed a thin sheet of muscle superficial to *fdp* in 2 of 20 specimens (10%) (Figs. 1, 4B, C). The *mn* passed deep to deep



**Fig. 1 (top).** Left forearm. The median nerve (*mn*) gives branches in a tree-like fashion as it enters the forearm. The superficial head of pronator teres (*s*) is divided at its middle and reflected medially and laterally to show the branches of *mn*. It gives branches (1,5) that arise from a common stem and supply *s*. It gives branch (2) to flexor carpi radialis (*fcr*), branches (3,4) to flexor digitorum superficialis (*fds*) which is a thin sheet split vertically at its middle, branch (4) gives a secondary branch (pointed by arrow) to flexor digitorum profundus (*fdp*) and branch (6) to deep head of pronator teres (*d*). *mn* gives anterior interosseous nerve (*ai*) to the deep flexors. The brachial artery (*ba*) is seen lateral to *mn* and it divides into ulnar artery (*ua*) and radial artery (*ra*).

**Fig. 2 (bottom).** Right forearm of the previous cadaver showing the median nerve (*mn*) entering the forearm with *ba* and its two terminal branches, *ra* and *ua* lateral to it and tendon of biceps (*bc*) more laterally. *s* is divided and reflected to show the branches of *mn* which pass in a tree-like fashion. The branches are: (1) to *s*, branches (2,3,4) to *fcr*, (5,6) to *fds*, (7) to *d* and *ai* which gives a branch (pointed by arrow) to *fdp*.

head of pt instead of the usual pathway between its superficial and deep heads, and was accompanied by ulnar artery (ua) in 1 of 20 specimens (5%) (Fig. 5A). The mn entered the forearm with the brachial artery and its terminal branches (ulnar and radial arteries) lateral to it, except in 1 of 20 specimens (5%) where mn passed lateral to the brachial artery (Fig. 6).

mn gave its first muscular branch to pt, which may arise in the lower part of arm (Figs. 1, 2), followed by the branch to fcr and the branch to fds in all specimens (Figs. 1-10). pl was absent in 12 of 20 specimens (60%), and, if present, it was supplied by a separate branch (Fig. 8). The branch to fds gave a secondary branch to fdp in 2 of 20 specimens (10%) (Figs. 1, 3). The branch to fcr gave secondary branches to fdp in 1 of 20 specimens (5%) (Fig. 5C), or mn itself gave a primary branch to fdp in 1 of 20 specimens (5%) (fig.10). mn gave the anterior interosseous nerve (ai) which supplied mainly the deep flexors in all specimens (Figs. 1, 2, 5C, 7).

There were 5 types of nerve supply to pt; type 1: two branches (superior and inferior), one for each head in 6 of 20 specimens (30%) (Figs. 2, 8, 10), the branch to the superficial head gave 2 secondary branches (Fig. 1); type 2: a common trunk for both heads and fcr in 4 of 20 specimens (20%)

Modified Ashworth scale for grading spasticity.

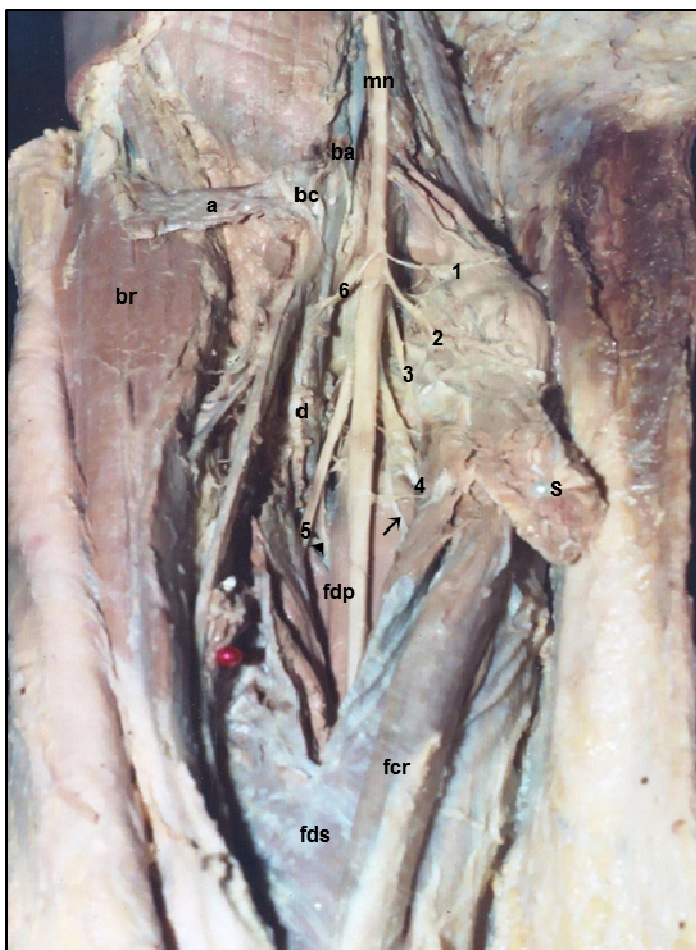
| Grade | Patient's status   |
|-------|--|
| 0     | No increase in muscle tone   |
| 1     | Slight increase in tone with a catch and release or minimal resistance at end of range of motion |
| 1+    | Slight increase in tone but with minimal resistance through range of motion following catch      |
| 2     | More marked increase in tone but limb easily moved   |
| 3     | Considerable increase in tone, passive movement is difficult                                     |
| 4     | Affected part is rigid   |

(Fig. 4A); type 3: a common trunk for pt, fcr and fds in 4 of 20 specimens (20%) (Figs. 6A, 9); type 4: multiple small branches for the superficial head and a single branch for the deep head in 4 of 20 specimens (20%) (Fig. 3), the branch to the deep head supplied the superficial head as well (Fig. 5A), and type 5: a single branch to both heads in 2 of 20 specimens (10%) (Fig. 7).

There were 2 types of nerve supply to fcr; type 1: a single branch in 14 of 20 specimens (70%), either from mn (Figs. 1, 8, 10) - this branch may give

2-3 secondary branches (Fig. 7) - or from a common trunk with pt (Fig. 4B) or fds (Fig. 3) or pt and fds (Figs. 6A, 9) or fdp (Fig. 5C). Type 2: in 6 of 20 specimens (30%); it was supplied by 2-3 branches from mn (Fig. 2).

Types of nerve supply to fds were: type 1: mn gave 2-4 branches to fds, 2 branches in 3 of 20 specimens (15%) (Figs. 1, 10), 3 branches in 2 of 20 specimens (10%) (Figs. 2, 8), 4 branches in 2 of 20 specimens (10%) (Fig. 7); type 2: a single or multiple branches from mn in the upper forearm and additional supply from ai near mid-forearm in 6 of 20 specimens (30%) (Figs. 4C, 5C, D); type 3: a common trunk for pt, fcr and fds and 1 or 2 branches from ai in 4 of 20 specimens (20%) (Fig.



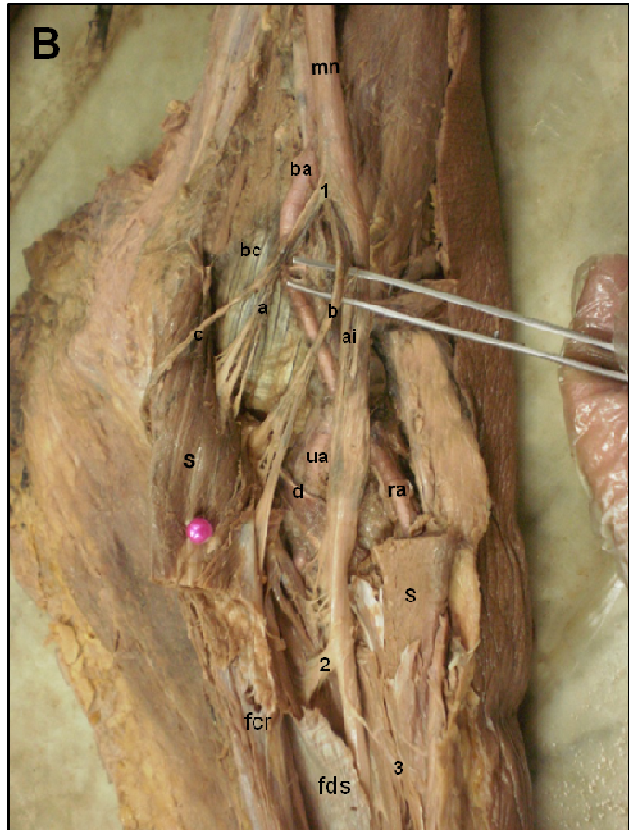
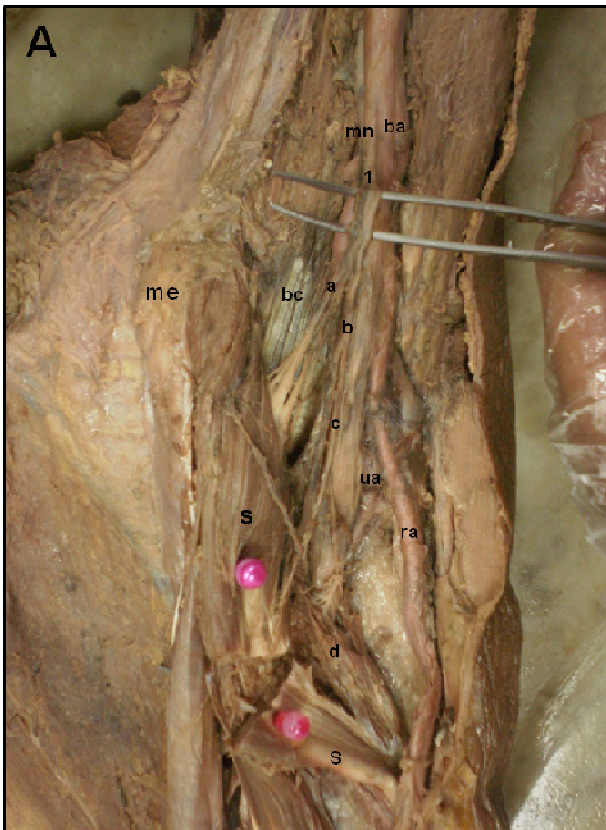
**Fig. 3.** Right forearm showing the median nerve (mn) with ba and the biceps tendon (bc) lateral to it and the bicipital aponeurosis (a) is cut and reflected laterally. s is cut and reflected medially. fds is split vertically in the midline to show mn passing in the plane between it and fdp. mn gives muscular branches in a tree like fashion. s is supplied by branches (1,2,3), branch (4) supplies fcr and fds through branch pointed by arrow, branch (5) supplies fds and gives a secondary branch pointed by arrow head to fdp and branch (6) to d. Brachioradialis muscle (br) can be seen on the lateral side of the forearm.

**Table 1.** The number of the primary branches of the median nerve and the motor points supplying the superficial forearm flexors

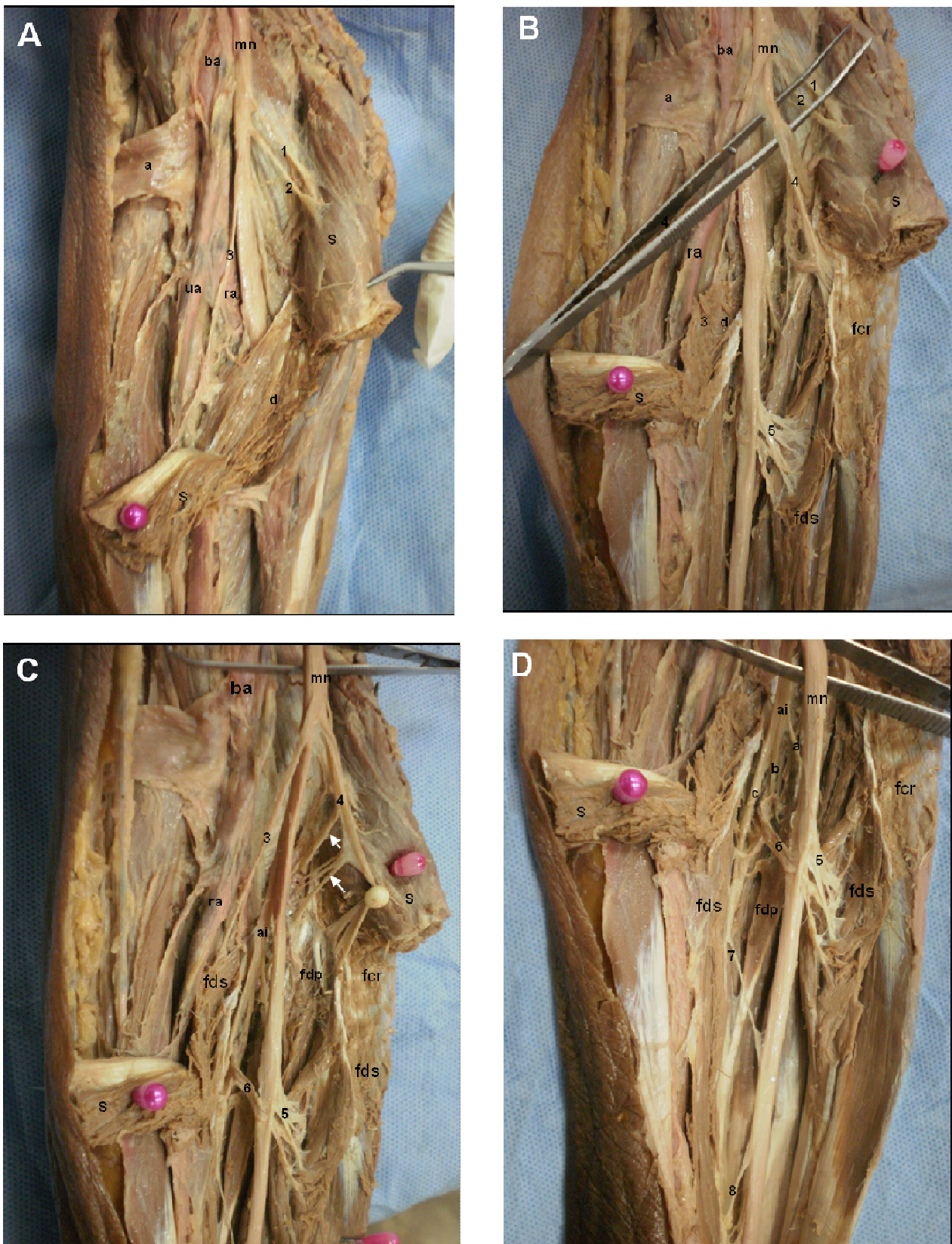
| Flexor muscle |           | p=Primary branches | m=Motor points=1ry+2ry branches |
|---------------|-----------|--------------------|---------------------------------|
| <b>Pt</b>     | Range     | 1-3                | 2-4                             |
|               | Mean±S.D. | 2.0±0.33           | 3.08±0.28                       |
| <b>Fcr</b>    | Range     | 1-3                | 1-3                             |
|               | Mean±S.D. | 1.40±0.79          | 2.06±0.82                       |
| <b>Fds</b>    | Range     | 2-6                | 3-8                             |
|               | Mean±S.D. | 4.0±1.01           | 5.21±0.84                       |
| <b>Pl</b>     | Range     | 1-2                | 1-2                             |
|               | Mean±S.D. | 1.2±0.44           | 1.32±0.52                       |

**Table 2.** Diameter (mm), length (cm) of the branches supplying the forearm flexors and the distances (cm) of their motor entry points from me and le

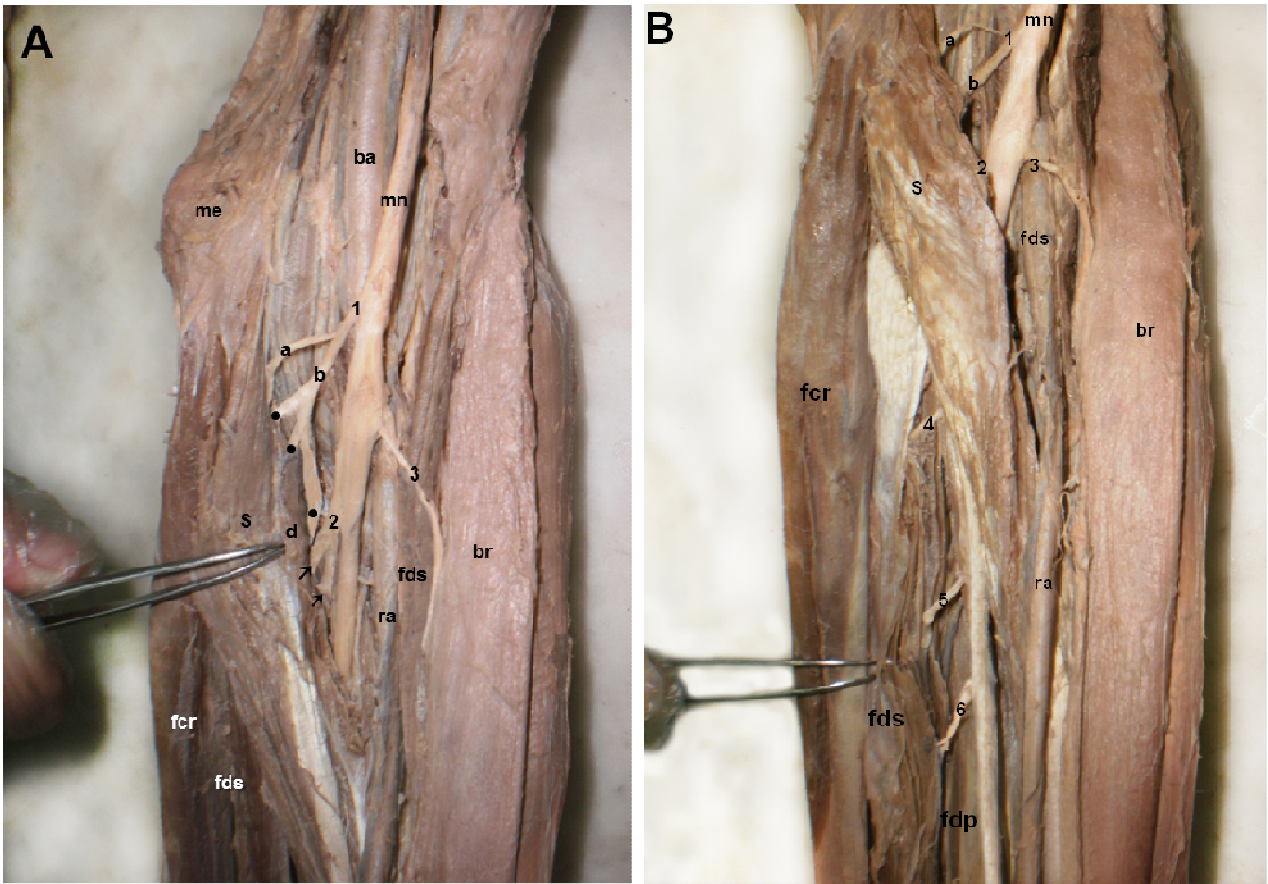
| Flexor muscle           | Mean | Std. Deviation | Std. Error | 95% Confidence Interval for Mean |             | Min.   | Max. | Mode  |               |
|-------------------------|------|----------------|------------|----------------------------------|-------------|--------|------|-------|---------------|
|                         |      |                |            | Lower Bound                      | Upper Bound |        |      |       |               |
| <b>Diam</b>             | pt   | 1.0800         | .42131     | .08426                           | .9061       | 1.2539 | .40  | 2.10  | 1.0           |
|                         | fcr  | 1.2581         | .40561     | .07285                           | 1.1093      | 1.4068 | .40  | 2.00  | 1.1           |
|                         | fds  | 1.3167         | .50188     | .10245                           | 1.1047      | 1.5286 | .50  | 2.10  | 1.4           |
|                         | pl   | .7600          | .16733     | .07483                           | .7522       | 1.1678 | .30  | 1.20  | 0.8           |
| <b>Length</b>           | pt   | 2.1368         | 1.01610    | .23311                           | 1.6471      | 2.6266 | 1.50 | 4.50  | 2.3           |
|                         | fcr  | 2.8935         | 1.50487    | .27028                           | 2.3416      | 3.4455 | 1.50 | 6.00  | 3.0           |
|                         | fds  | 3.3958         | 1.71070    | .34920                           | 2.8735      | 3.9182 | 1.80 | 6.00  | 3.5           |
|                         | pl   | 1.6233         | .5034      | .11003                           | 1.1070      | 1.6800 | 1.00 | 2.00  | 1.5           |
| <b>Distance From me</b> | pt   | 3.9789         | 1.00088    | .22962                           | 3.8965      | 4.1614 | 3.50 | 4.20  | 4             |
|                         | fcr  | 5.4871         | .90985     | .16341                           | 4.9534      | 5.7208 | 4.55 | 5.90  | 5.4           |
|                         | fds  | 7.7792         | 2.00954    | .41020                           | 6.9306      | 7.8277 | 5.30 | 12.30 | 7.8,10.2,11.4 |
|                         | pl   | 4.7600         | .46368     | .20736                           | 4.4243      | 4.8757 | 3.60 | 5.10  | 4.6           |
| <b>Distance from le</b> | pt   | 5.4800         | 1.13284    | .22657                           | 5.2124      | 5.8476 | 4.00 | 7.30  | 5.6           |
|                         | fcr  | 6.8968         | 1.51492    | .27209                           | 5.1411      | 6.2525 | 5.10 | 8.30  | 7.1           |
|                         | fds  | 9.1790         | 2.38783    | .48741                           | 8.0709      | 9.4875 | 7.00 | 12.50 | 8.8,9.0,12.0  |
|                         | pl   | 4.3800         | .22804     | .10198                           | 3.9969      | 4.5631 | 4.00 | 4.94  | 4.5           |



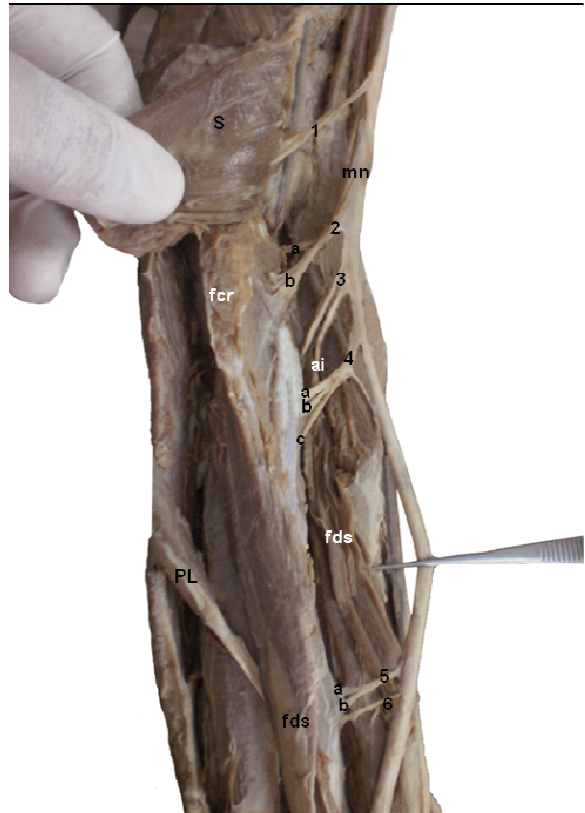**Fig. 4 (A,B,C).** Left forearm showing the median nerve (mn) giving branch (1) which divides into 3 branches: (a), (b) and (c). Branch (a) supplies s. Branch (b) supplies fcr. Branch (c) supplies both heads of pt (s,d). Branches (a) and (b) divide into several secondary branches before entering s and fcr respectively. mn gives ai and branches (2,3,4,5) to fds which forms a thin sheet of muscle. ai gives 4 small twigs (pointed by arrow) to supply fds and continues distally to supply fdp. The brachial (ba), the radial (ra) and ulnar (ua) arteries are seen. The Biceps tendon (bc) and the medial epicondyle (me) are noted.



**Fig. 5 (A,B,C,D).** Right forearm. The median nerve (mn) gives 2 branches (1,2) to s and branch (3) which supplies s and d. mn passes deep to d instead of the usual pathway between s and d and is accompanied by the ulnar artery (ua). The brachial (ba) and radial (ra) arteries are noted. The bicapital aponeurosis (a) is cut and reflected laterally. After cutting the deep head of pronator teres (d), mn gives a large branch (4) (pointed by forceps) to fcr and a large branch (5) which divides into several secondary branches to supply fds which is split vertically along its middle. Branch (4) to fcr (held by white pin) also supplies the proximal part of fdp by several branches (pointed by arrows). mn gives branches (5,6) to fds and ai. ai gives 2 branches (a, b) to supply fds by several branches (pointed by arrows) to the deep flexors. mn gives branches (7, 8) to supply the distal part of fds.

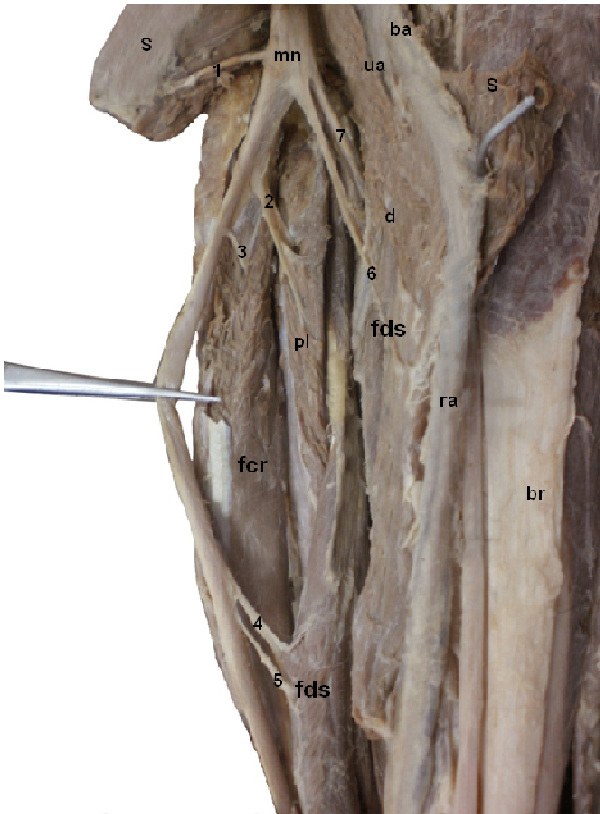


**Fig. 6 (A,B).** Left forearm, the medial humeral epicondyle (me) is noted. The median nerve (mn) crosses lateral to the brachial artery (ba) in the cubital fossa. It gives branch (1) that divides into (a) which supplies s and (b) which gives 3 branchlets (•) to supply d, fcr and fds. Branch (2) divides into 2 branches (pointed by arrows) and supplies the proximal part of fds. Branch (3) supplies fds. Brachioradialis (br) can be seen on the lateral side of forearm. mn gives 3 additional branches (4, 5, 6) to the distal part of fds. The radial artery (ra) is seen on the lateral side of the forearm.

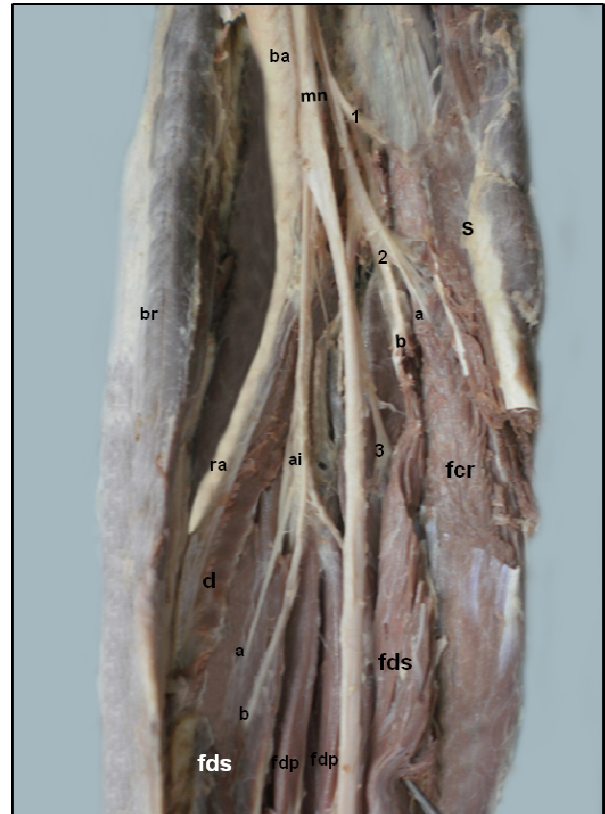


**Fig. 7.** Left forearm. fds is split vertically along its middle. mn gives branch (1) to s which is cut and reflected, branch (2) which divides into (a,b) to the proximal part of fcr, branches (3,4) to fds, branch (4) gives 3 secondary branches (a,b,c) before entering the muscle. Branches (5,6) supply the distal part of fds. Branch (5) divides into (a,b). ai is seen passing to the deep flexors, Palmaris longus (pl) is cut and reflected downward.

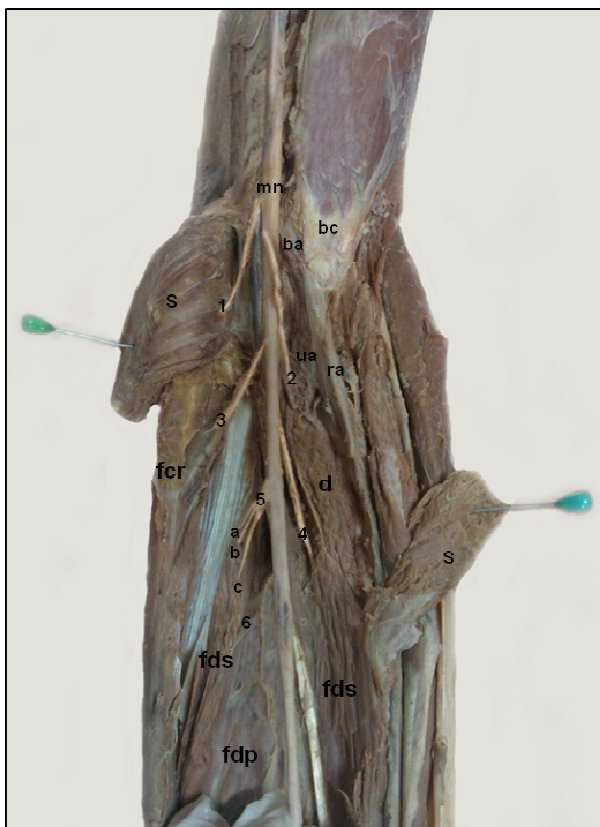




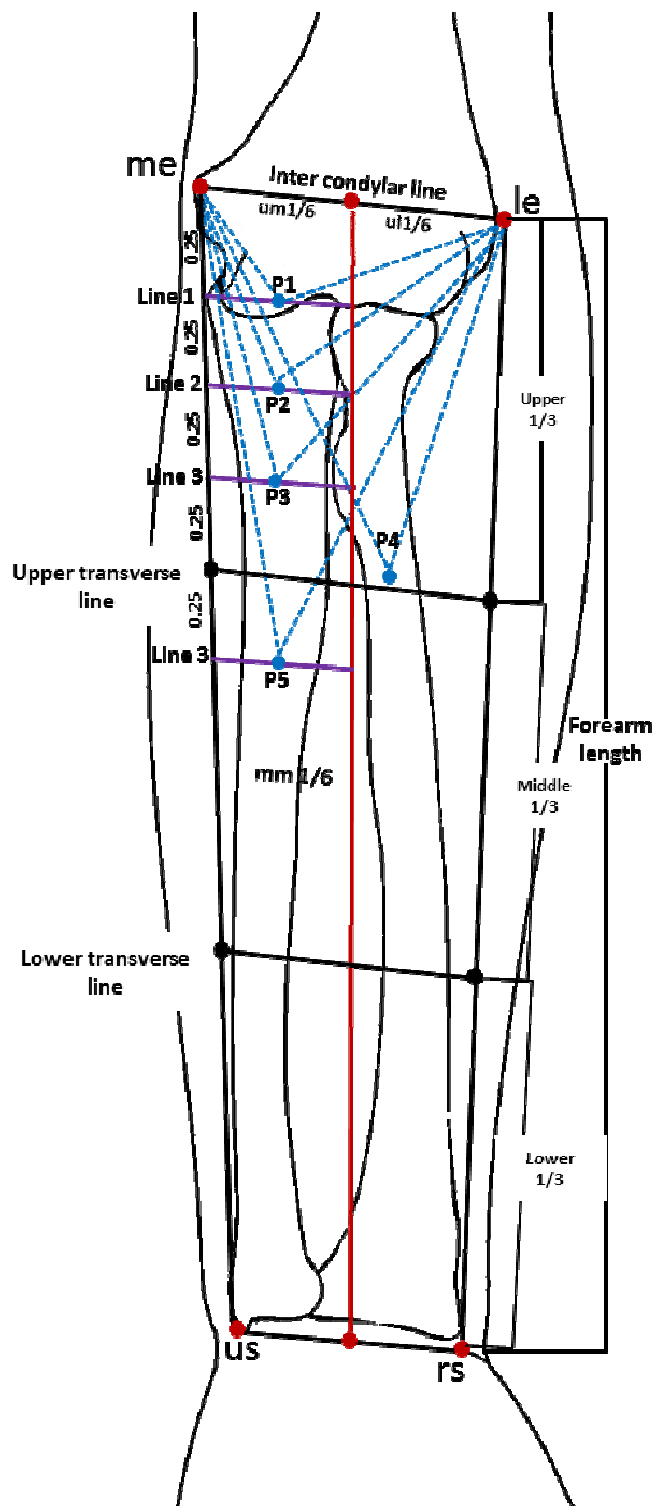
**Fig. 8.** Left forearm. The median nerve (mn) passes medial to the brachial artery (ba) and gives branch (1) to s, branch (2) to palmaris longus (pl), branch (3) to fcr, branches (4,5,6) to fds which is split vertically along its middle and branch (7) to d. Radial artery (ra), ulnar artery (ua) and Brachioradialis (br) are seen on the lateral side of the forearm.



**Fig. 9.** Right forearm. s is cut and reflected medially while d is left in its place. fds is split vertically along its middle. The median nerve (mn) gives branch (1) to s, branch (2) splits into (a,b) to fcr and fds respectively, branch (3) to fds and ai which gives 2 branches (a,b) to the lateral part (radial head) of fds. The brachioradialis (br) and radial artery (ra) are seen on the lateral side of the forearm. The brachial artery (ba) is seen lateral to mn.



**Fig. 10.** Left forearm. The median nerve (mn) gives branch (1) to s, branch (2) to d, branch (3) to fcr, branch (4) to the lateral part (radial head) of fds, branch (5) which splits into 3 smaller branches (a,b,c) before supplying the medial part (humeroulnar head) of fds and a small branch (6) to fdp. The brachial (ba), radial (ra) and ulnar (ua) arteries and biceps tendon (bc) are noted.



**Fig. 11.** Diagrammatic illustration of the motor entry points (m) of the superficial forearm flexors. The forearm is divided into 6 rectangles by 3 vertical lines (represent forearm length) and 4 transverse lines. The vertical lines connect me and us (ulnar styloid process), le and rs (radial styloid process) and the midpoint of the inter-condylar line with the midpoint of the line connecting us and rs (red line). The 4 transverse lines are the intercondylar line, the line connecting us and rs and upper and lower transverse lines that divide forearm into upper, middle and lower thirds. Point 1 (p1) is m of pt: 4.1 cm below and lateral to me and 5.6 cm below and medial to le. Point 2 (p2) is m of fcr: 5.4 cm below and lateral to me and 7.1 cm below and medial to le. fds has 3 points: Point 3 (p3): 7.8 cm below and lateral to me and 8.8 cm below and medial to le. Point 4 (p4): 10.2 cm below and lateral to me and 9 cm below and medial to le. Point 5 (p5): 11.4 cm below and lateral to me and 12 cm below and medial to le. The first 3 points are in the upper medial (um) 1/6 of the forearm which is further subdivided equally by 3 transverse lines. Point 1 is on the middle of line1, point 2 is on the middle of line 2 and point 3 in on the middle of line 3. Point 4 is just above the junction of the medial 2/3 and lateral 1/3 of the upper transverse line in the upper lateral (ul) 1/6 of the forearm. Point 5 is the only point in the medial middle (mm) 1/6 of forearm on the middle of line 4 dividing mm into upper 1/4 and lower 3/4. ( Mean forearm length: 27.4±0.72cm. Mean inter-condylar distance: 7.5±0.83 cm).

9); type 4: a common trunk for fcr and fds and a single branch from mn in 2 of 20 specimens (10%) (Fig. 3); type 5: a common trunk for pt, fcr and fds and multiple branches from mn in 1 of 20 specimens (5%) (Figs. 6A, B).

The number of the primary branches (p) of the median nerve and the motor entry points (m) supplying the superficial forearm flexors are shown in Table 1. The diameter, length of the branches supplying the forearm flexors and the distances of their motor entry points from me and le are shown in Table 2.

### Clinical results

1. Based on the anatomical results, the recording electrodes were best placed at p1, p2 and p3 (the modes for pt, fcr and fds respectively) (Table 2, Fig. 11). The shapes of cmap curve obtained from the superficial forearm flexors were as follows:
  - 20 out of 100 forearms (20%) had a bell- or dome-shaped monophasic cmap (Fig. 12).
  - 36 out of 100 forearms (36%) had biphasic or double peak cmap (Fig. 13).
  - 44 out of 100 forearms (44%) had a multi phasic cmap (Figs. 14, 15).
2. As regard cases that underwent spn: based on the anatomical results, the microsurgical spn of the motor branches of the median nerve were performed by one surgical approach, since all of them enter the muscles in a short interval located between 3.5 and 12.5 cm below the medial and lateral humeral epicondyles. This surgical approach is a vertical, S-shaped incision with a short proximal curve at the bicipital medial groove, and a longer distal curve following the medial edge of the brachioradialis. There is no need for the usual transverse incision in the middle of the cubital fossa described by Msaddi et al. (1997). There was no operative mortality. Transient paresis of flexors of the wrist and fingers because of excessive nerve sectioning occurred in one patient that responded well to physiotherapy. Postoperatively, all the patients had immediate improvement of their spasticity grade. After initial improvement, recurrence of spasticity occurred in one patient 6 months postoperatively, and that might be due to insufficient amount of nerve sectioning. Abnormal hand posture that was present in all cases improved in 9 of 10 patients (90%), while pain that was present in 5 of 10 cases (50%) of cases improved in all cases as measured by visual analogue scale. Assessment of outcome after surgery was done by comparing modified Ashworth scale preoperatively and postoperatively. At the last follow up examination period, excellent results were obtained in 4 of 10 patients (40%), good results in 4 of 10

patients (40%), fair results in 1 of 10 patients (10%), and poor results in 1 of 10 patients (10%).

3. As regard cases that underwent bt injections, based on the anatomical results, 5 motor entry points were chosen for the injection: pt was injected at p1; fcr was injected at p2; fds is the largest and most important muscle in the superficial group having two heads (radial and humeroulnar) and has the largest number of motor entry points, and for this reason and for its superficial easily accessible location, it is the main target of bt injection to relieve forearm spasticity. It was injected at 3 points p3, p4, p5 (figure 11). p3 (the proximal point) is the mode—the most frequently encountered point. p4 (the middle point) and p5 (the distal point) are the 2nd and 3rd most frequently encountered points in the present results. Transient paresis of flexors of the wrist and fingers occurred in 3 of 20 cases (15%), which improved spontaneously two months after injection. All the patients had improvement of their spasticity grade two weeks after injection. Recurrence of spasticity occurred in all patients after a period ranging from 6 to 9 months; they necessitated another set of injection. Abnormal hand posture that was present in all cases improved in 15 of 20 cases (75%), while pain that was present in 8 of 20 cases (40%) improved in all cases as measured by visual analogue scale. Assessment of outcome after injection was done by comparing modified Ashworth scale before and after injection.

The patients were classified into four groups according to their results.

Group 1: Reduction of three or more grades was considered excellent; Group 2: reduction of two grades was considered good; Group 3: reduction of one grade was considered fair; and Group 4: no grade reduction was considered poor. All patients had immediate initial improvement of their spasticity.

At the last follow-up examination period, excellent results were obtained in 8 of 20 (40%) of patients, good results in 8 of 20 (40%) of patients, fair results in 2 of 20 (10%) of patients, and poor results in 2 of 20 (10%) of cases due to development of resistance (antibodies) to bt.

In excellent and good results, the reduction of spasticity was accompanied by complete withdrawal of medication.

### DISCUSSION

Many authors have reported their results concerning variations in the nerve supply of the forearm flexors (Abd-Elhamid, 2008; Safwat and Abdel-Meguid, 2007; Standing et al., 2005; Unver et al.,

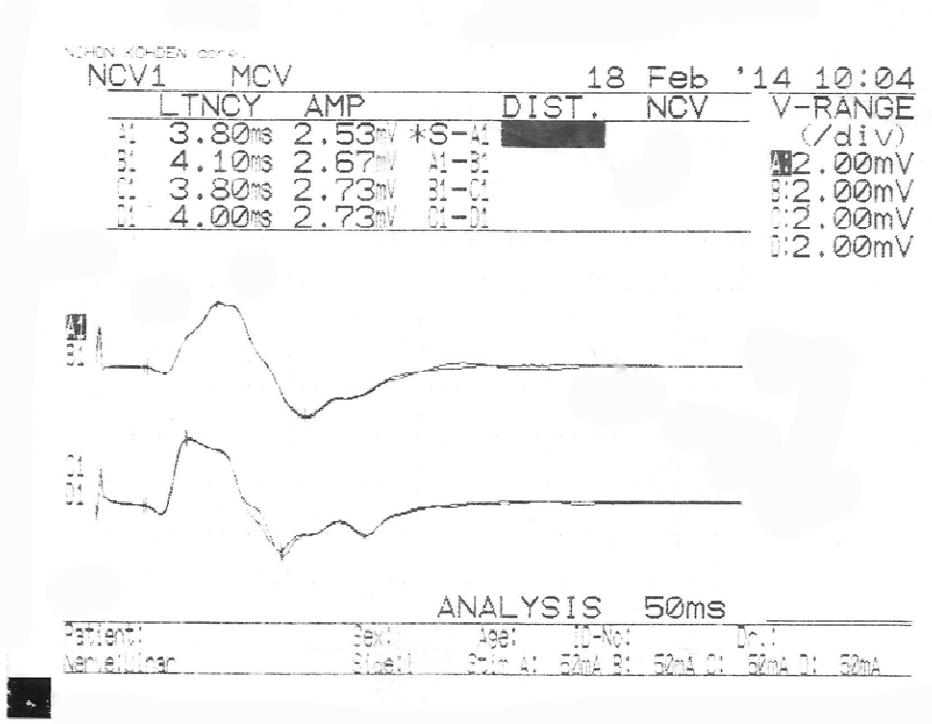


Fig. 12. Monophasic or bell-shaped cmap on both sides.

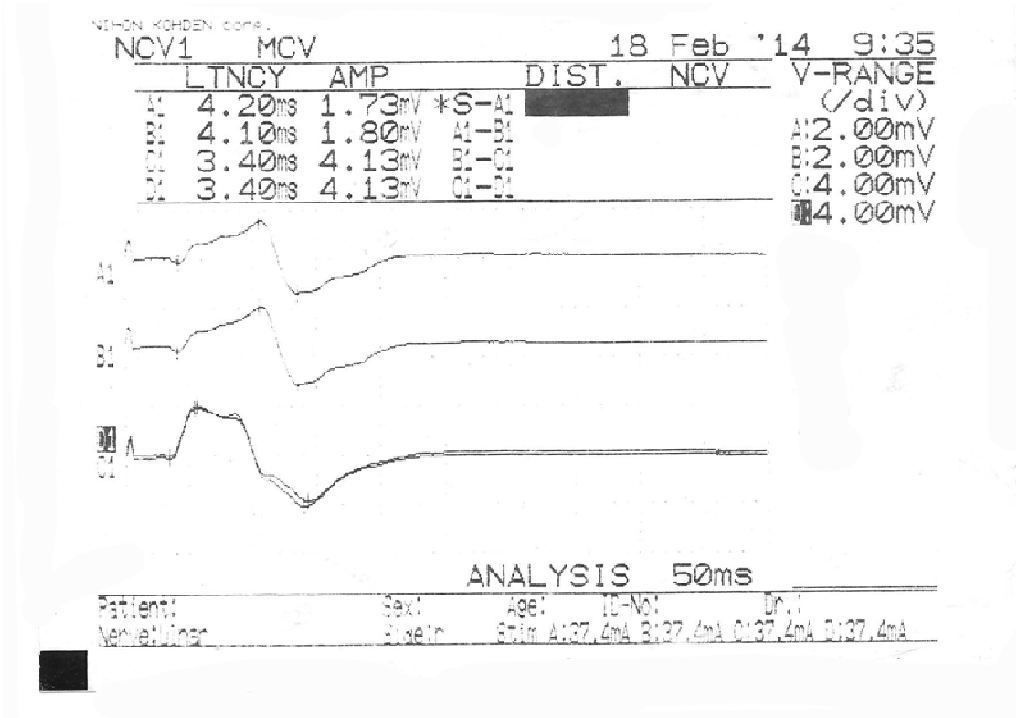


Fig. 13. Biphasic or double peak cmap on both sides.

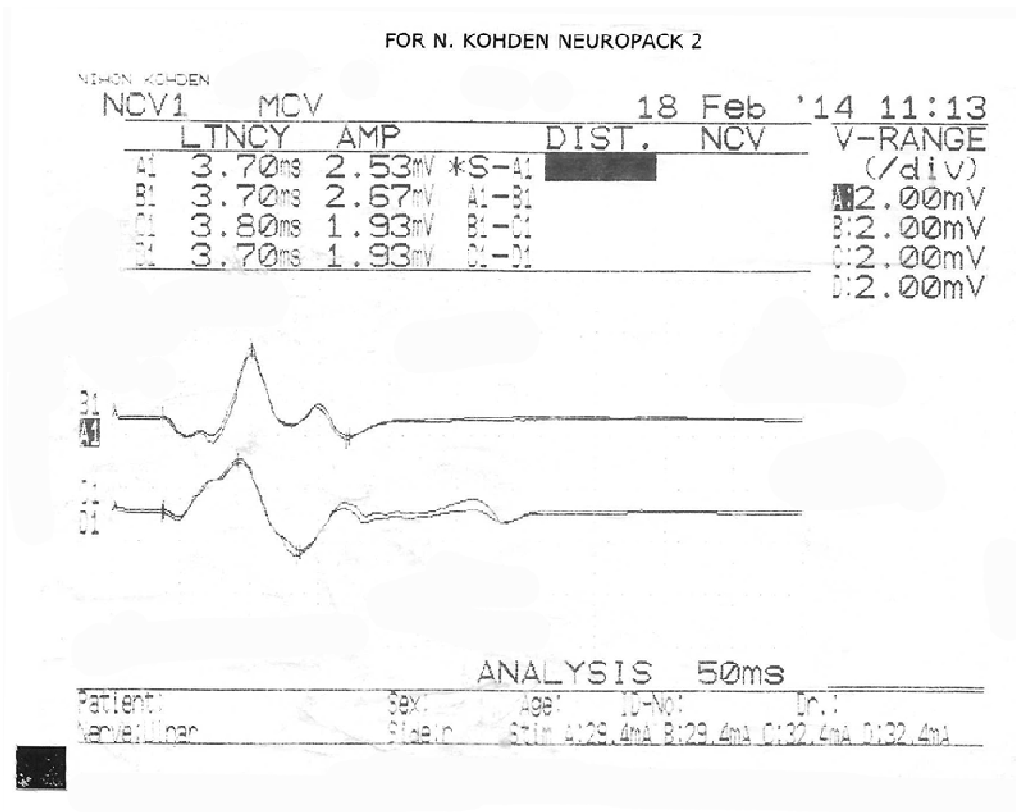


Fig. 14. Multiphasic cmap on both sides.

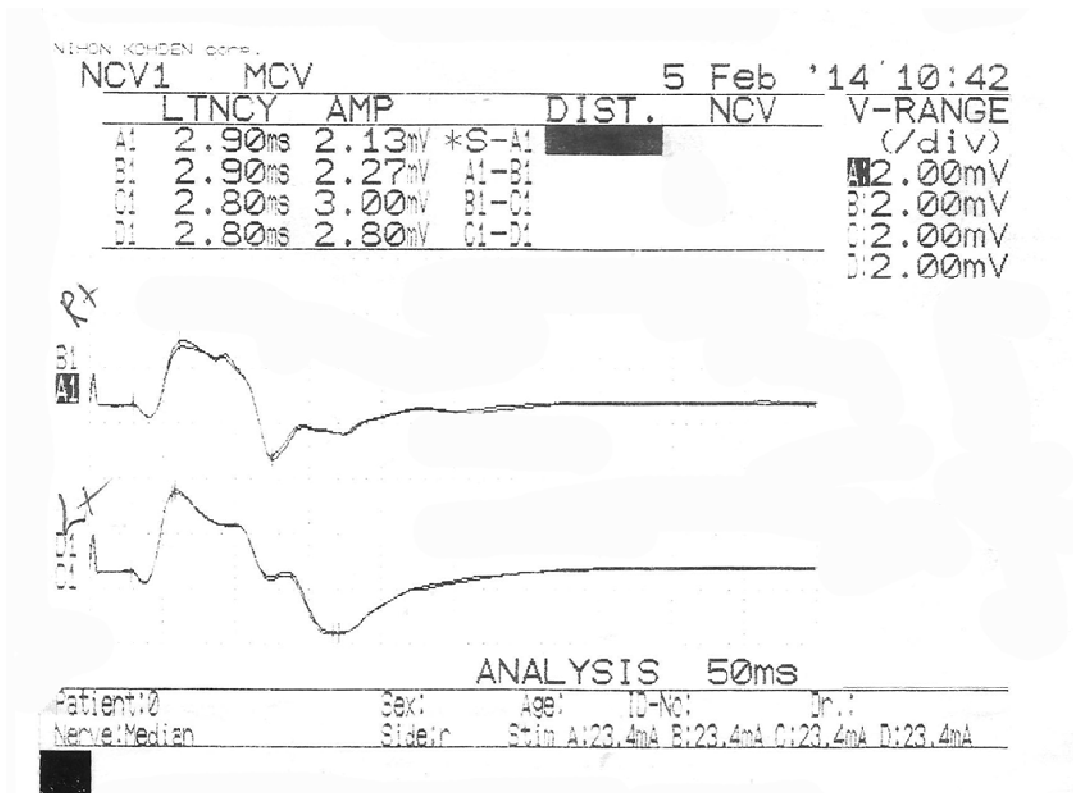


Fig. 15. Right side: Biphasic or double peaked cmap. Left side: Multiphasic cmap.

2010). Canovas et al. (1998) reported that the muscular branches of mn to the superficial forearm flexors are very variable, while ai is less variable, and is therefore more reliable in free transfers to restore finger mobility. Chantelot et al. (1999) observed that classical nerve supply was found in 26% in case of pt, in 40% in case of fcr and in 68% in case of fds.

The distribution of mn to pt, fcr, pl and fds in the present study showed great variability. In fact, classic textbook description was rarely encountered. The variable distribution of median nerve may be linked to muscle anomalies such as accessory, duplicate or absent pl (Kawashima et al., 2002; Raouf et al., 2013). Absent pl was found in 60% of our specimens compared to 53% in the study of Raouf et al. (2013), marking the Egyptians as the highest population with absent pl. When present, pl can be used in tendon transfer along with its nerve as it receives a separate branch from mn (Yavari et al., 2014).

The present work, as well as previous studies (Chantelot et al., 1999, 2000; Gunther, 1992), emphasized that the first motor branch from mn was the pt branch which can arise proximally in the arm. pt received a single branch either alone or in common with other flexors in 50%, while it received multiple branches in the other 50% of our series. Injury of the branch to pt could lead to grave outcome if it arises as a common trunk with other muscular branches. This situation makes the branch to pt unsuitable for nerve transfer. Unver et al., (2010) reported that the first motor branch from mn was the pt branch except in 1 out of 50 cases; it was ai. They determined the main pattern of innervation of the pt as a single branch in the majority of their cases. If pt is supplied by more than one branch, which was observed in 50% of our cases, it can maintain pronation of the forearm in case of injury of one branch.

Segal et al. (2002) mentioned that fcr was supplied by one primary nerve. In the present study, fcr was supplied by one primary nerve in 70% of cases. This nerve could arise as a single branch from mn or in common with other muscular branches. Only 30% of dissected muscles were supplied by more than one branch marking fcr as the least variable of the superficial forearm flexors regarding nerve supply. Nevertheless, Hua et al. (1999) reported that in case of split fcr, each half of the muscle receives separate nerve supply facilitating muscle transfer.

The present results coincide with those of Abd-Elhamid (2008), Safwat and Abdel-Meguid (2007) and Liu et al. (1997a, b) in the number of the primary branches and the number and location of the motor entry points to fds (Tables 3, 4). Fds is supplied at regular intervals by two, three or four branches from mn and occasionally from ai coinciding with previous reports (Abd-Elhamid, 2008; Chantelot et al., 1999; Liu et al., 1997a, b; Safwat

and Abdel-Meguid, 2007; Standing et al., 2005). This pattern of nerve supply as well as the existence of two muscle heads is an advantage and disadvantage at the same time. The disadvantage is the often unpredictable therapeutic results of injections of bt into this muscle. To overcome this problem, bt was injected at the 3 most frequently encountered motor entry points with good results. The advantage of the presence of several branches and the fact that these branches are the longest and thickest among the nerves supplying the superficial flexors make the muscle and/or its nerve supply suitable for transfer in case of forearm injuries. Unver et al. (2010) reported that fds was innervated by a single muscular branch in 88% and by two branches in 12% of their cases. They stated that their study was conducted on aborted pre-term fetuses and this could explain the much less number of branches.

fdp is mainly supplied by the ulnar and ai nerves and rarely by mn itself (Bhadra et al., 1999; Hwang et al., 2007; Marur et al., 2005). In the present study, the muscle took additional nerve supply from the nerve to fcr (5%) or fds (10%) or from mn itself in 5% of cases. Therefore, these additional branches can be used for nerve transfer. Bertelli et al. (2014) reported that mn and/or ai usually supply the whole of fdp, and this explains the persistence of flexion of the distal interphalangeal joint of the little and ring fingers in high ulnar nerve lesions, and they advise nerve transfers to ai to provide flexion of all fingers in these lesions. Chantelot et al. (1999) reported that 4% of the branches innervating the radial part of the fdp arose from mn through a common root supplying the fds as well. As much as 2% of their cases were shown to receive nerve supply from mn as a single branch.

The median nerve and its muscular branches can be isolated above pt. It then enters distally between the superficial and the deep head of this muscle. This usual arrangement was found in 95% of specimens of this study, thus making it easy to dissociate the two muscle heads to expose mn before running deep to fds arcade. In 5% of the present results, mn ran deep to both heads of pt accompanied by the ulnar artery. According to Von Lanz and Wachsmuth (2004), mn perforates the superficial head in 2% of cases or it runs deep to the two heads in 3% of cases. It is important to keep these particular arrangements in mind, as surgical dissection during spn could need to be modified.

The multiphasic appearance of cmap recorded from the superficial forearm flexors was the most common type (44%). The recording electrodes were placed at 3 motor points representing the 3 superficial forearm flexors and this explains the multiphasic cmap where each peak represents contraction of one of the 3 muscles. This concludes that the points chosen were the closest to the motor entry points.

In 36% of forearms, the cmap of the median nerve is biphasic and this can be explained by two waves of muscle contraction: the first one is caused by contraction of pt and fcr supplied from a common trunk, and the second wave is produced by contraction of fds supplied by a separate branch from mn and/or ai. fdp is supplied by mn itself, or in common with the superficial muscles in some cases, and could be responsible for the second wave of contraction if the recording electrode passes into the muscle through a thin or absent radial head of fds.

The less common monophasic (bell- or dome-shaped pattern) occurs in only 20% of cases and can be explained by the fact that mn gives a common trunk for pt, fcr and fds muscles in 20% of cases of the present study, and the signals reach all the superficial flexor muscles simultaneously, causing contraction at the same time.

The anatomical results of this study were used as a guide to select the best sites for electrodes insertion. It is obvious that electrodes insertion at

these points yields excellent cmap recording from the superficial forearm flexors in spite of its variable shapes caused by the different patterns of mn distribution. Electrical stimulation through electrodes placed near or at the motor points of a muscle gives maximal cmap recording from this muscle (Bottle et al., 1999).

In numerous studies, it has been found that the efficiency of bt varies from one patient to another (Basu et al., 2015; Brashear et al., 2002; Hurvitz et al., 2003; Page et al., 2003; Speth et al., 2015). There is no doubt that the results of these injections can be improved if they are made as near as possible to the motor entry points. In fact, there is no present imaging technique that permits the determination of these points, and it is mandatory to revise anatomic cadaveric dissections to determine practical mappings to propose injection sites that can be considered optimal. Also, cmap recording before bt injection or spn can give a good idea about mn distribution pattern.

**Table 3.** Comparison between the present study and Abd-Elhamid et al. as regards the number of branches and points of their entry into fds

|                     | Abd-Elhamid et al. (2008) |      |             | Elzawawy et al. |       |           | P     |
|---------------------|---------------------------|------|-------------|-----------------|-------|-----------|-------|
|                     | Min                       | Max  | Mean + SD   | Min             | Max   | Mean + SD |       |
| Forearm length (cm) | 25                        | 27.4 | 26.9 ± 0.65 | 26.1            | 28.80 | 27.4±0.72 | >0.05 |
| No. of p            | 2                         | 7    | 4.3 ±1.6    | 2               | 6     | 4.0±1.01  | >0.05 |
| No. of m            | 2                         | 9    | 5.7 ± 1.7   | 3               | 8     | 5.21±0.84 | >0.05 |
| d.m (cm)            | 2.4                       | 11.2 | 6.32 ± 2.9  | 3.30            | 10.30 | 6.77±2.0  | >0.05 |

No. of p: number of primary branches of median nerve to fds. No. of m: number of motor entry points into fds. d.m: distance between motor entry points and me.

**Table 4.** Comparison between the present study and previous studies regarding primary branches of median nerve and their motor points to the forearm flexors

| Flexor muscle | Safwat and Abdel- Meguid (2007) |         | Liu et al. (1997) |          | Elzawawy et al. |           |           |
|---------------|---------------------------------|---------|-------------------|----------|-----------------|-----------|-----------|
|               | P                               | M       | P                 | M        | P               | M         |           |
| Pt            | Mean±S.D.                       | 2-2     | 2-4               |          | 1-3             | 2-4       |           |
|               | Range                           | 2.0±0.0 | 3.04±0.7          | 2.0±0.67 | 3.4±0.70        | 2.0±0.33  | 3.08±0.28 |
| Fcr           | Mean±S.D.                       | 1-2     | 2-3               |          | 1-3             | 1-3       |           |
|               | Range                           | 1.1±0.3 | 2.2±0.4           | 1.0      | 3.1±1.10        | 1.40±0.79 | 2.06±0.82 |
| Fds           | Mean±S.D.                       | 2-8     | 3-9               |          | 2-6             | 3-8       |           |
|               | Range                           | 4.2±2.6 | 4.8±2.8           | 4.2±1.23 | 5.6±1.65        | 4.0±1.01  | 5.21±0.84 |
| PI            | Mean±S.D.                       | 1-1     | 2-2               |          | 1-2             | 1-2       |           |
|               | Range                           | 1.0±0.0 | 1.7±0.5           | 1.0      | 1.1±0.33        | 1.2±.44   | 1.32±0.52 |

Based on the anatomical and electrophysiological results, bt injections should be made for pt, fcr and fds at the 5 points described in the results. These points are changeable according to the length and width of forearm (figure 11). Injections of bt at these points are easy to perform, ensure adequate response and avoid complicated mathematical or algorithmic equations as proposed by previous studies of Hwang et al. (2007) and Ye et al. (2011).

Injections of bt and spn are two therapeutic options for treatment of localized spasticity with absence of associated contracture. There are technical constraints concerning these two therapies: determination of the appropriate surgical approaches for spn, and the optimal injection sites and the number of injections for bt treatment. In well-selected patients, spn can yield good effects on refractory spasticity of the hand and its consequences. Msaddi et al. (1997) confirmed that spn is an effective procedure in the treatment of segmental spasticity after failure of a well-conducted conservative treatment associating physiotherapy and antispasmodic medications. It must be performed before the fixed deformities and other orthopedic complications arise. bt injection is a safe, effective procedure in all cases but has many disadvantages that are: it is expensive; the effect is transient and necessitate repeated injection after 6 months and the possibility of development of resistance due to formation of antibodies to bt.

Brashear et al. (2002) and Hurvitz et al. (2003) concluded the same results as the present work. bt reduced spasticity of the wrist and fingers, improved hand grip and increased range of motion. Future research should focus on the value of adjunct therapy, such as task-specific training, in addition to bt treatment to facilitate functional improvement of the spastic upper extremity. Page et al. (2003) suggested the use of modified constraint-induced therapy in combination with bt as an effective management of stroke-induced motor disorder to improve hand function. Recent treatment options have been suggested by Speth et al. (2015) either alone or in combination with bt injection as the bimanual task oriented therapy which gives more improvement of functional grip strength.

#### ACKNOWLEDGEMENTS

The authors would like to thank the donors of the cadavers used in this study.

#### REFERENCES

- ABD-ELHAMID FA (2008) Detailed anatomical study of nerve supply of flexor digitorum superficialis muscle. *Bull Alex Fac Med*, 44(1): 259-266.
- BASU AP, PEARSE J, KELLY S, WISHER V, KISLER J (2015) Early intervention to improve hand function in hemiplegic cerebral palsy. *Front Neuro*, 15: 281.
- BERTELLI JA, GHIZONI MF, TACCA CP (2014) The median nerve consistently drives flexion of the distal phalanx of the ring and little fingers: Interest in finger flexion reconstruction by nerve transfers. *Microsurg*, 35(3): 207-210.
- BHADRA N, KEITH MW, PECKHAM PH (1999) Variations in innervation of the flexor digitorum profundus muscle. *J Hand Surg Am*, 24: 700-703.
- BOTTLE MJ, NAKAI RJ, WATERS RL, MCNEAL DR, RUBAYI S (1999) Motor point delineation of the gluteus muscle for functional electrical stimulation: An in vivo anatomic study. *Arch Phys Med Rehabil*, 72: 112.
- BRASHEAR A, GORDON MF, ELOVIC E, KASSICIEH VD, MARCINIAK C (2002) Intramuscular injection of botulinum toxin for the treatment of wrist and finger spasticity after a stroke. *N Engl J Med*, 347: 395-400.
- CANOVAS F, MOUILLERON P, BONNEL F (1998) Biometry of the muscular branches of the median nerve to the forearm. *Clin Anat*, 11: 239-245.
- CHANTELOT C, FEUGAS C, GUILLEM P, CHAPNIKOFF D, REMY F, FONTAINE C (1999) Innervation of the medial epicondylar muscles: an anatomic study in 50 cases. *Surg Radiol Anat*, 21: 165-168.
- CHANTELOT C, FEUGAS C, MIGAUD H, GUILLEM P, CHAPNIKOFF D, FONTAINE C (2000) Effect of the Steindler procedure on the median nerve branches to the medial epicondylar muscles. *J Hand Surg*, 25B: 276-280.
- GUNTHER SF, DI PASQUALE D, MARTIN R (1992) The internal anatomy of the median nerve in the region of the elbow. *J Hand Surg*, 17A: 648-656.
- HUA J, KUMAR VP, PEREIRA BP, LIM AY, PHO RW, LIU J (1999) Split flexor carpi radialis muscle. *Plast Reconstr Surg*, 103: 930-934.
- HURVITZ EA, CONTI GE, BROWN SH (2003) Changes in movement characteristics of the spastic upper extremity after botulinum toxin injection. *Arch Phys Med Rehabil*, 84: 444-454.
- HWANG KS, JIN SH, HWANG KM, LEE SH (2007) Location of nerve entry points of flexor digitorum profundus. *Surg Radiol Anat*, 29: 617-621.
- KAWASHIMA T, KIKUSHIMA S, YOKOTA E (2002) A case of an accessory palmaris longus and a duplicate palmaris longus with special reference to their nerve supply- morphologic significance of a common innervation trunk. *Okajimas Folia Anat Jpn*, 79: 75-81.
- KIMURA J (2001) Assessment of individual nerves; chapter 6. In: *Electrodiagnosis in disease of nerve and muscle: Principles and practice*. 3<sup>rd</sup> Edition. Oxford University Press, Inc., pp 130-171.
- KONG KH, CHUA KSG (2005) Intramuscular neurolysis with alcohol to treat post-stroke Anger Xerox spasticity. *Clin Rehabil*, 16: 378-381.
- LIU J, LAU HK, MIN WX, PEREIRA BP, KUMAR VP, PHO RW (1995) Contractile characteristics on electrical stimulation of muscle with multiple motor points: an in vivo study in rabbits. *Clin Orthop*, 313: 231-238.
- LIU J, KUMAR VP, LAU HK, PEREIRA BP, SHEN Y,



- PHO RWO (1997a) Neuromuscular compartments in the long head of triceps: a morphological study in rabbits. *Muscle Nerve*, 20: 897-899.
- LIU J, PHO RW, PEREIRA BP, LAU HK, KUMAR VP (1997b) Distribution of primary motor nerve branches and terminal nerve entry points to the forearm muscles. *Anat Rec*, 248(3): 456-463.
- MARUR T, AKKÉN SM, ALP M, DEMIRCI S, YALÇÉN L, ÖGÜTT, AKGÜN I (2005) The muscular branching patterns of the ulnar nerve to the flexor carpi ulnaris and flexor digitorum profundus muscles. *Surg Radiol Anat*, 27: 322-326.
- MSADDI AK, MAZROUE AR, SHAHWAN S, AL AMRI N, DUBAYAN N, LIVINGSTON D, MOUTAERY KR (1997) Microsurgical selective peripheral neurotomy in the treatment of spasticity in cerebral palsy children. *Stereotact Funct Neurosurg*, 69: 251-258.
- PAGE SJ, ELOVIC E, LEVINE P, SISTO SA (2003) Modified constraint-induced therapy and botulinum toxin A: a prom combination. *Am J Phys Med Rehabil*, 82: 76-80.
- POPOVIC D, GORDON T, RAFUSE VF, PROCHAZKA A (1991) Properties of implanted electrodes for functional electrical stimulation. *Ann Bio-med Eng*, 19: 303-316.
- RAOUF HA, KADER GA, JARADAT A, DHARAP A, FADEL R, SALEM AH (2013) Frequency of palmaris longus absence and its association with other anatomical variations in the Egyptian population. *ClinAnat*, 26(5): 572-577.
- SAFWAT MD, ABDEL-MEGUID EM (2007) Distribution of terminal nerve entry points to the flexor and extensor groups of forearm muscles: an anatomical study. *Folia Morphol*, 66(2): 83-93.
- SEGAL RL, CATLIN PA, KRAUSS EW, MERICK KA, ROBILOTTO JB (2002) Anatomical partitioning of three human forearm muscles. *Cells Tissues Organs*, 170: 183-197.
- SPETH L, JANSSEN-POTTEN Y, LEFFERS P, RAMECKERS E, DEFESCHE A, WINKENS B, BECHER J, SMEETS R, VLES JS (2015) Effects of botulinum toxin A and/or bimanual task-oriented therapy on upper extremity impairments in unilateral cerebral palsy: an explorative study. *Eur J Paediatr Neurol*, 19(3): 337-348.
- STANDRING S, JOHNSON D, ELLIS H (2005) Median nerve; Chapter 52. In: Gray's Anatomy, 39<sup>th</sup> ed. Churchill Livingstone, Edinburgh. pp 885-886.
- SUNDERLAND S, RAY LJ (1946) Metrical and non-metrical features of the muscular branches of the median nerve. *J Comp Neurol*, 85: 191-203.
- UNVER DN, UYSAL II, KARABULUT AK, FAZLIOQULLARI Z (2010) The motor branches of median and ulnar nerves that innervate superficial flexor muscles: a study in human fetuses. *Surg Radiol Anat*, 32: 225-233.
- VON LANZ T, WACHSMUTH W (2004) Practical Anatomy (5<sup>th</sup> edition). Vol. 1, part 4. The upper limb. Springer, Auflage, Sonderausgabe, p 140.
- WON SY, HUR MS, RHA DW, PARK HD, HU KS, FONTAINE C, KIM HJ (2010) Extra- and intramuscular nerve distribution patterns of the muscles of the ventral compartment of the forearm. *Am J Phys Med Rehabil*, 89(8): 644-652.
- WU L, GOTO Y, TANIWAKI T, KINUKAWA N, TOBIMATSU S (2002) Different patterns of excitation and inhibition of the small hand and forearm muscles from magnetic brain stimulation in humans. *Clin Neurophysiol*, 113: 1286-1294.
- YAVARI M, ABDOLRAZAGHI HA, RIAHI A (2014) A comparative study on tendon transfer surgery in patients with radial nerve palsy. *World J Plast Surg*, 3 (1): 47- 51.
- YE JF, LEE JH, AN XC, LIN CH, YUE B, HAN SH (2011) Anatomic localization of motor entry points and accurate regions for botulinum toxin injection in the flexor digitorum superficialis. *Surg Radiol Anat*, 33(7): 601-607.