

## REVIEW

# Practical teaching of preclinical anatomy

Beat M. Riederer<sup>1,3</sup>, José L. Bueno-López<sup>2,3</sup>, Raphaël Ayer, Concepción Reblet<sup>2,3</sup>, Hugues Cadas<sup>1</sup> and Julien P. Puyal<sup>1</sup>

<sup>1</sup>Morphology Platform, Faculty of Biology and Medicine, University of Lausanne, Switzerland,

<sup>2</sup>Department of Neurosciences, Faculty of Medicine and Dentistry, University of the Basque Country (UPV/EHU), Bilbao, Spain and <sup>3</sup>Members of the Trans-European Pedagogic Anatomical Research Group (TEPARG)

## SUMMARY

We illustrate here why today practical teaching in preclinical anatomy is important and why the use of human cadavers is still essential for learning human anatomy by taking two examples. We explain why it is important for a student to be able to dissect and learn anatomy by exploratory anatomy. Several alternatives are discussed and modern teaching tools are illustrated with on-line and computer-based resources, anatomical models, reconstructions and radiographic images that could supplement the traditional dissection courses. Newer techniques such as anatomical body painting, projections, ultrasound or living anatomy may help in the understanding of topographical anatomy. We underline the authenticity that comes from using human tissue and consider the strengths and limitations of different teaching tools. Here we discuss also how far one should go in teaching anatomical variations in preclinical teaching. In Europe there is no consensus regarding anatomical teaching, and each institution has its own curriculum. It would be helpful to set up an anatomical data bank with images and PowerPoint slides that could be used in teaching programs. Here the Trans-European Pedagogic Anatomical Research Group (TEPARG) for Europe and the International Federation of Associations of Anato-

mists (IFAA) at an international level could play an essential role.

**Key words:** Anatomy – Dissection – Preclinical – Skills – Practicality – European Community

## INTRODUCTION

“It may be true that doctors do not need to dissect a cadaver or study a prosection in order to practice, but if it can improve their understanding of what they do and why they do it, this surely has to benefit both for the safety of the patient and the satisfaction of the doctor as a professional” (Turney, 2007). The practice of dissection teaches students not only the foundations of anatomical knowledge, but also favors the development of professional competencies (Böckers et al., 2012). Here, we will provide two examples, one from Spain and the other one from Switzerland, on how to organize preclinical anatomy teaching and discuss some teaching tools for practical anatomy.

## SPAIN: FACULTY OF MEDICINE AND DENTISTRY OF THE UNIVERSITY OF THE BASQUE COUNTRY (UPV/EHU)

The methodology for practical teaching of preclinical anatomy discussed below is used in about half of the medical faculties of Spain. However, even among these, the distribution of the *materia anatomica* by semesters and subjects of the medical curriculum varies from one university to other. As well, teachers in charge of teaching anatomy can

---

**Corresponding author:** Beat M. Riederer. University of Lausanne, Morphology Platform and Department of Fundamental Neurosciences, Faculty of Biology and Medicine, Rue du Bugnon 9, CH-1005 Lausanne, Switzerland.  
Phone/Fax: ++41-21-692 5105. E-mail: Beat.Riederer@unil.ch

---

Submitted: 9 March, 2015. Accepted: 7 April, 2015.

belong to departments that either have explicitly the term anatomy (or morphology) in their name, or be integrated with other specialties. Specifically at the University of the Basque Country (UPV/EHU), the Department of Neurosciences is on charge of teaching anatomy (that is, embryology and organogenesis, gross anatomy and neuroanatomy) in addition to psychology, psychiatry and clinical neurology. Twenty-four teachers of this Department of Neurosciences, ranking from assistant to full professors, are enrolled for teaching anatomy in Medicine, Dentistry, Pharmacy, Human Nutrition and Dietetics, Physical Education and Sports, and Physiotherapy Degrees. Twelve of those above-said 24 teachers are assigned to the medical degree; half of these 12 teachers, all of them senior teachers, hold in turn a medical degree.

The total number of students that are currently enrolled in the First Year of UPV/EHU medical degree is admittedly high (some over 300, see below). As in other Spanish faculties of medicine, such a number has increased in recent years because of the need of teaching medical doctors to attend the enlarged population currently living in Spain. It must be also taken into account that due to the existing economical crisis, a number of medical doctors and specialists taught in the Spanish faculties and hospitals has leaved Spain to work in other European Countries in recent years. In the Spanish universities there is no 'numerus clausus'. Students finishing Baccalaureate (usually on their 17 years of age) and wishing to register at any university must pass the 'Selectividad' exam, which is organized by each Autonomous Region Educative Authority every year. Then students apply to be possibly enrolled at the studies and universities of their choice. In turn, the universities choose the applicants in accordance to their 'Selectivity' marks. Eventually, students choose among the universities (and studies) that positively answer their applications. As said above, new students of First-Year at the UPV/EHU medical degree are being just over 300 in each of the recent years. These students have passed the 'Selectividad' exam with marks that have been in the top 15% peak. Of these fresh students, about two-thirds usually enroll themselves in the 'Spanish-Language line', less than one-third in the 'Basque-Language line', and 25 in the 'English-Language line'. Whereas to enroll in either the Spanish-Language or Basque-Language lines is entirely up to the student's wish, the number of students in the English-Language line is limited on the basis of 'first asking, first served'. (In the anatomy subjects of the medical degree at the UPV/EHU, the English-Language line in is a pilot line assisted only by one teacher.) Every effort is done to ensure that teaching contents and methodology are similar in all these Language lines, in particular by applying comparable exams to all students. The anatomical

terminology used in these lines is the official one, published in Latin and English Languages by the Federative Committee on Anatomical Terminology of the International Federation of Associations of Anatomists (FCAT-IFAA, 1998) and translated in addition into Spanish by the 'Comité Federal sobre Terminología Anatómica de la Sociedad Anatómica Española' (CFTA-SAE, 2001). Though still not been published, the official anatomical terminology is that which is also in use in the Basque-Language line of the UPV/EHU medical degree, as translated into Basque Language by the teachers of the line.

In the following we will concentrate on the practical teaching of preclinical anatomy at the UPV/EHU Degree of Medicine. Human Anatomy (HA) is taught during 1<sup>st</sup> and 2<sup>nd</sup> academic years to 18-year-old and 19-year-old students, respectively. Each year is divided in two terms. Consequently, HA is divided in four subjects, i.e. HA I-IV, which are taught sequentially. Each of HA I-III subjects has 6 ECTS. HA IV has 8 ECTS. HA I is for teaching descriptive embryology and organogenesis. HA IV is reserved for central nervous system. Gross anatomy is taught regionally/topographically in HA II-III. The back of the body, trunk walls (except perineum) and limbs are taught in HA II, namely in the second term of first year. Head, neck, trunk cavities and their contents, together with perineum and external parts of genitourinary systems are taught in HA III, that is, in first term of second year.

In each of the above-referred four anatomical subjects, practical teaching predominates over lecture teaching at a scale of 1.2:1. Adding seminar sessions (which may consist of oral expositions prepared by the students, see below at the end of this Section) to lectures, practical teaching is 50% of all hours scheduled for anatomy teaching. Any student enrolled in the UPV/EHU Degree of Medicine should spend a total of 64 hours at the laboratory (with teacher guidance) and 36 hours of personal study aimed to practical learning of gross anatomy. Certainly, half of this time is to be consumed at HA II and the other half at HA III. For personal learning, students take advantage of free access to laboratory at times agreed with teachers and laboratory technicians. As a rule, the calendar and contents of practical teaching correlates with those of teaching at lecture and seminar rooms. For practical teaching, students are grouped in groups of eight; each of these groups is assigned to one teacher (the teacher can be assigned of more than one group of students, but then each group has different hours in the timetable); a cadaver is allotted to each group of eight students.

Practical teaching of gross anatomy is done by means of dissections and prosections as well as the handling of bi-dimensional and tri-dimensional models of the human body or its regions, plastinated specimens of dissected parts of the human body, imaging anatomy and exploratory anatomy.

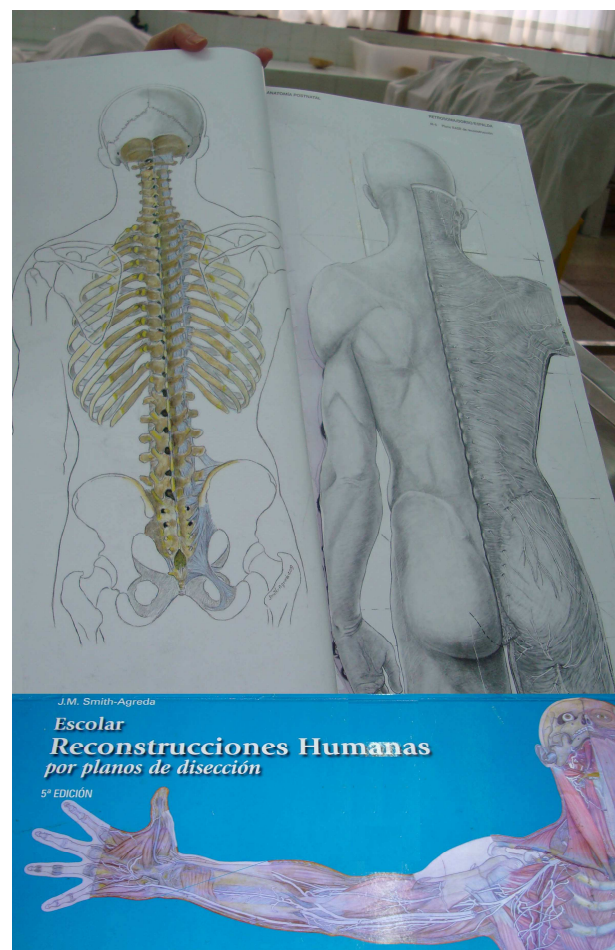Corpses come from volunteer donors (McHanwell et al., 2008; Riederer et al., 2012), see also Table 1.

At the UPV/EHU, we think dissection of human cadavers is fundamental for the practical teaching of preclinical anatomy because of many reasons. Firstly, dissection builds cognitive together with interwoven procedural memories in the minds of the students involved. Every dissection is the practical deciphering of anatomical intricacies that become apparent in the dissector's mind just during dissection. The students not only actively acquire knowledge with the practice of dissection but also skills that will be advantageous later on. Dissection familiarizes the students with tools and procedures that will be widely used posteriorly during their clinical courses and medical practice. Furthermore, the use of dissection immediately teaches the students the essentials of the scientific method, that is, to observe (*autopsía*) and interpret on the basis of the observed (*hermenía*) by contrasting with the observations of others. Last but not least, dissection does challenge the students with severe and clear visions of death perhaps for the first time in their lives. Today's world is to avoid childhood and adolescence confrontation with the actual presence of death, beyond abstract and detached idealizations in comics, video games, films and TV broadcasts. Medical students at the end of their adolescence can learn during dissection, with aid of their teachers, that death is unavoidable, but also that it is an inseparable part of life cycle in which, fortunately, there are altruistic people that donate their body for the benefit of students and medical/surgical practitioners. In the end, this sense of caring for others is in the very nature of medicine, and it is good to be learnt since the beginning of the medical degree. We see the practice of dissection as an opportunity to instill the willingness to donate among future health professionals, so that they can actively participate in the dissemination of this need. In the UPV/EHU there is a monument erected to honor body donors for medicine. There, students, teachers and families of donors meet regularly in simple intimate ceremonies to commemorate donors. This memorial, called "Vitae Silva" (Life Forest), is located in a quiet spot in the "arboretum" that is next to the UPV/EHU Faculty of Medicine at the Leioa Campus, which is near to Bilbao (Arráez-Aybar et al., 2014; Riederer and Bueno-López, 2014; Biasutto et al., 2014).

In our practice, we the teachers dissect halves of the allotted cadavers in presence of and with the help of students. Following this guide, our students then dissect selected regions of the other side of the cadavers; to this purpose, each group of eight students is subdivided in smaller working-teams, which constitute also teams for other practical activities and seminars (see below). Though dissections are serially done along three terms (those corresponding to HA II-IV), cadavers never be-

come divided into detached pieces. Cadavers are dissected regionally by planes, in which the nervous, vascular and other connective pedicles are preserved in order to keep as much as possible the corporal unity. To this, muscles can be partially deinserted at one of their ends but not cut across. Planes are put orderly back in place and then the skin covers again the body after dissection. Moreover, after dissecting the bodies as a whole, students do a review of variations and anomalies, looking as well to signs of pathologies. The latter is done in order to discuss possible causes of illnesses and death, which are then checked against those reported in the medical records that come along with cadavers.

Indeed, two-dimensional models to be constructed by the students can be helpful for learning anatomy. At UPV/EHU Degree of Medicine, we use the model of Professor JM Smith-Agreda of Malaga University, Spain (Smith-Agreda, 2010), which comes with a CD-ROM that incorporates the Terminologia Anatomica (CFTA-SAE, 2001) in Latin and Spanish Languages (Fig. 1). The model in itself has no lettering. It consists of sheets of flexible cardboard in which anatomical planes—which are similar to those dissected in cadavers—are



**Fig. 1.** This figure shows the topographical anatomy of the Atlas of Prof. J.M. Smith-Agreda.

naturalistically portrayed in detail (scale, 1:33). The sheets are to be cut, glued on top of each other and then coloured by every student working-group in a process parallel to dissection. In this two-fold way, i.e. cadaver's dissection plus model construction, students can repeatedly compose and decompose the human body in order to interiorize structures and relationships while combining vision, handling and perceptive thinking. Old models can be also used as a guide for dissections. Collections of plastinated specimens serve as a guide for dissection too, but also as a valuable tool for teaching anatomy of body regions that cannot be dissected by the students due to both, combined difficult accesses and time restrictions.

In addition, the use of three-dimensional models is helpful for understanding the volumes of corporal regions. They are valuable as well for better interpreting X-ray, ultrasound and sectional imaging. Given the importance of the latter in present medical and surgical practices, teaching imaging anatomy in the medical curriculum is entirely necessary. We cannot think of a better way of introducing this study to beginners than as a part of the practical teaching of normal anatomy during the first years of the Medical Degree. To this purpose, we use our own collection of X-rays, ultrasound and tomographical images kindly provided by the staff of hospitals that are part of our Faculty of Medicine. On-line links to university and other professional websites are used and recommended for the student's use to facilitate personal study of imaging anatomy. As a full implement for studying normal imaging anatomy, we strongly recommend to our students the use of *Atlas of Anatomy by Sectional Imaging* (Sempere Durá, 2011), a CD-ROM that is backed by the Department of Anatomy and Human Embryology of Rovira i Virgili University (Reus, Spain) and the Spanish Anatomical Society (SAE, by its initialism in the Spanish Language). This CD-ROM contains a total of 10,560 images, including conventional X-rays, computed tomography, magnetic resonance imaging and ultrasonography. Covered sections are chest, abdomen, head and neck, musculoskeletal, vascular and nervous system. Study of each section is completed with the three-dimensional, virtual endoscopy, and volume rendering techniques.

Along with practical and theoretical knowledge of the subject taught, we think the student must attain and implement communication skills, verbal and written, which in our case include the rigorous use of the description and anatomical terminology. We strongly favour the use of verbal practice exams to improve the students' oral communication skills, inclusive those skills regarding auto control and self-confidence. This type of skills is also prompted by the regular presentation by every student's working-group of ten-minute oral communications followed by five minutes of discussion. Such presentations are congregated in three sessions,

of two hours each, per term. These presentations deal with topics suggested by the teachers. Students must distribute among teachers and classmates written abstracts (up to 350 hundred words) of every presentation before delivering it orally.

During terms and at the end of terms, practical exams of acquired abilities and knowledge of pre-clinical anatomy are to be passed by the student, in addition to multiple-choice tests. Together with the seminar sessions, the practical exams make up 60% of the student's final mark at the end of the term. The practical exams are done in extended viva voce acts. At them, the teachers discuss student's notebooks and dissections with the student; every student is also asked for detailed, both descriptive and conceptual knowledge of anatomy on dissected cadavers, plastinated pieces and imaging anatomy items. Nonetheless, every student has to reach an 80% of success altogether (multiple choice tests, practical work and seminars) in their final mark to pass the subject.

#### **SWITZERLAND: FACULTY OF BIOLOGY AND MEDICINE, UNIVERSITY OF LAUSANNE, MORPHOLOGY PLATFORM**

In this part we would like to address several issues, one is how to deal with an increasing number of students and consequences for pre-clinical teaching and secondly how to involve master thesis students for the preparation of medical imaging and setting up anatomy teaching modules, how to make use of the large collection of anatomical preparations, pot specimens and anatomical drawings and to use e-Learning to consolidate anatomical knowledge.

At the University of Lausanne, in the first year of medical studies about 500 students are enrolled, there is no numerus clausus and the exams at the end of the first year are used to select only the best students (up to 220) (Table 1). All courses are taught in French, this goes also for the anatomical nomenclature, (French translation of Latin names). One needs to know, that in the first year students have to learn the whole locomotor system. But due to the high number of students it is not possible to dissect. Practical courses are quadrupled and projected wet specimens as well as plastinates are used in self-directed learning (Fig. 2).

In order to reduce mental distress that may occur when approaching the cadaver labs, we have organized an introductory course. We first present the donation program and then approach two cadavers of a man and a woman, as well as some plastinated specimens. The bodies are at first covered with a blanket, which is gradually removed. The response of students was very positive to reduce psychological burden, and confirms a recent study (Böckers et al., 2012). During seven sessions of two hours each, students identify muscles and their insertions, innervation and vasculariza-



**Fig. 2 (left).** Self-directed learning at the University of Lausanne. Students follow the instructions of a guide to identify anatomical structures on prosected specimens. Per topic there are four tables with wet specimens. On two tables in the middle row plastinates and bones are on display. For the supervision and answering questions, there are two professors and 3-6 assistant students available. These practicals are quadrupled. For yellow asterisk and arrow see text.

**Fig. 3 (right).** Dissection course at the University of Lausanne (in 2010). Reaching an upper limit of student number the dissection got crowded and left no room for the computer set-up for informatics support (arrows). The dissection courses had to be doubled. In an ideal situation, for 50 students we need one professor and for 6 students per dissection table one student assistant for guiding through the dissection. For yellow arrow see text.

tion, particularities of joints of upper and lower limb and rachis. Assistant students and professors supervise and respond to the questions of the students. Because dissected specimens have to be renewed at a regular basis, we ask experienced student assistants to dissect specific body parts during several afternoon sessions in the presence of professors. By that way, they also learn in-depth the anatomical particularities of a specific body part and enlarge their anatomical formation. The high number of students in the first year makes dissection courses and oral exams nearly impossible, and anatomical knowledge is examined by multiple choice tests (MCT).

Several years ago we had to increase the number of students for the 2<sup>nd</sup> year of medical studies from 120 to 160, and now have to accept 220 students, due to the need of more physicians. This has also consequences for practical anatomy

teaching, since the number of cadavers and space in the dissection hall is limited (Fig. 3). As a consequence, students alternate dissections or dissect only one half as it was described above for Spain. Actually, all medical faculties in Switzerland still dissect. Practical courses had to be doubled and therefore required more teaching faculty for guiding students during dissection. From the second year onward problem-based learning is introduced. Students are presented with a clinical case and they have to describe the anatomy, physiology, biochemistry and histology involved. This type of teaching will be replaced by a new format, more focused on clinical aspects of the cases discussed. In the second and subsequent year students are examined by MCTs and an objective structured clinical examination (OSCE) that allows testing over 200 students in a single day. There is only one question related to anatomy (among the 10

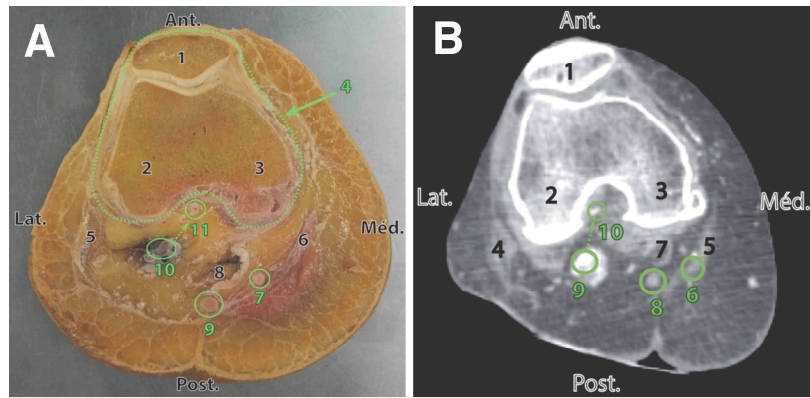
**Table 1.** Comparative table of practical preclinical teaching at the University of the Basque Country (UPV/EHU), Bilbao and at the University of Lausanne

Practical teaching	UPV/EHU Bilbao	University of Lausanne
Number of students 1st year	300	500
Number of students 2nd year	300	220
Contact hours per year	64	52
Personal work per year (in hours)	36	-
Use of - cadaver dissection	x	x
- prosected specimens	x	x
- plastinates	x	x
- plastic models	x	x
- cardboard reconstruction	x	
- web based / e-learning		x
- radiological imaging	x	x
- short presentations	x	
Professors per 100 students	3	2
Number of students per cadaver	8	6
Number of cadavers	10	22

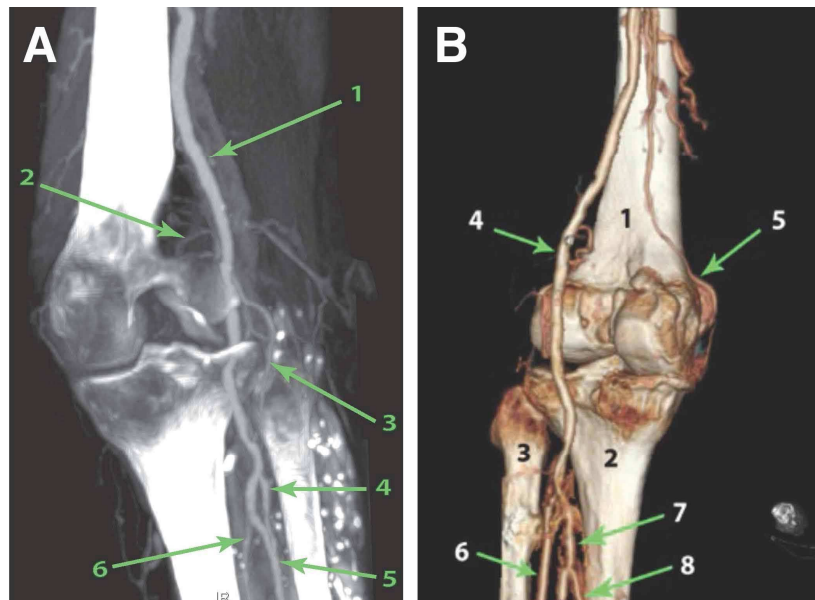
questions); but there are questions for anatomy in most of the MCT's, in proportion of the number of contact hours. For this, four identical prosected and plastinated organs or slices have to be produced. The importance of plastinated specimens becomes evident since they can be used outside the dissection hall and permanent preservation makes them a useful additional teaching tool (Jones, 2002; Riederer, 2014).

Since the introduction of the Bologna system, dividing the medical studies in Bachelor and Master, medical students have to do a master thesis before they can take the final board exam. We have proposed thesis projects that deal with medical imaging, dissection and preparation of a specific region and preparation of a teaching module in practicals as additional help for self-directed learning. Raphaël Ayer (2012), a master student in medicine, has prepared two knees to demonstrate the vascularization by computer tomography (CT) imaging and subsequent dissection and slicing for comparable sections (Fig. 4).

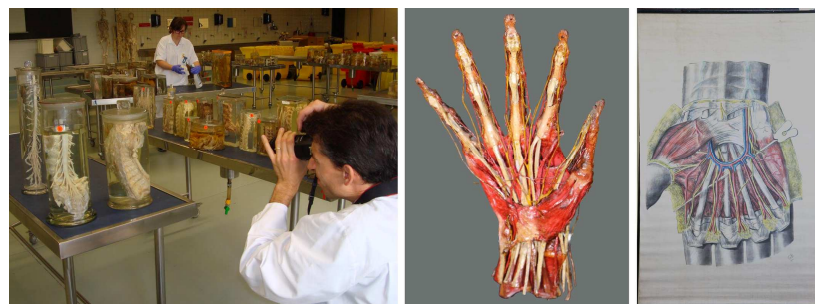
First, a cadaver was perfused with radio-opaque angiophil through the femoral arteries and veins and scanned with a CT. During the first year the locomotor system is taught and images of CT and slices were introduced in practical teaching in form of a quiz, comparing matching sections by CT and tissue slices. There are several advantages preparing slices and CT for comparing structural anatomy, it allows a comparison one to one, for differences in gray values and matching it to the corresponding texture of anatomical structures in slices (Fig. 5). This is also important for a 3D reconstruction and a subsequent dissection. It becomes clear, that the vascularization of the knee is quite diverse and may be different between subjects and from the anatomical description in textbooks (Damsin et al., 1995). However, such anatomical variations may



**Fig. 4.** Anatomical aspect of a slice and CT scan of the left knee at the level of the femoro-patellar joint. Numbers in (A,B) correspond to 1A/B: patella; 2A/B: lateral condyle; 3A/B: medial condyle; 4A: capsule; 5A/4B: femoral biceps muscle; 6A/5B: sartorius; 7A/6B: gracilis; 8A/7B: semimembranous muscle; 9A/8B: popliteal artery; 10A/9B: middle genicular artery.



**Fig. 5.** Reconstruction of the left knee. The presence of Angiofil allows the reconstruction of arteries. The structures in (A) represent 1: popliteal artery; 2: superior medial genicular artery; 3: inferior lateral genicular artery; 4: anterior tibial artery; 5: fibular artery; 6: posterior tibial artery. The structures in (B) represent 1: popliteal surface of femur; 2: posterior surface of the tibia; 3: Fibular head; 4: popliteal artery; 5: descending genicular artery; 6: anterior tibial artery; 7: posterior tibial artery; 8: fibular artery.



**Fig. 6.** Photographs of pot specimens are taken. They will provide part of the database for the preparation of labeled images, and are used to establish questionnaires on structures, in form of an e-Learning tool.



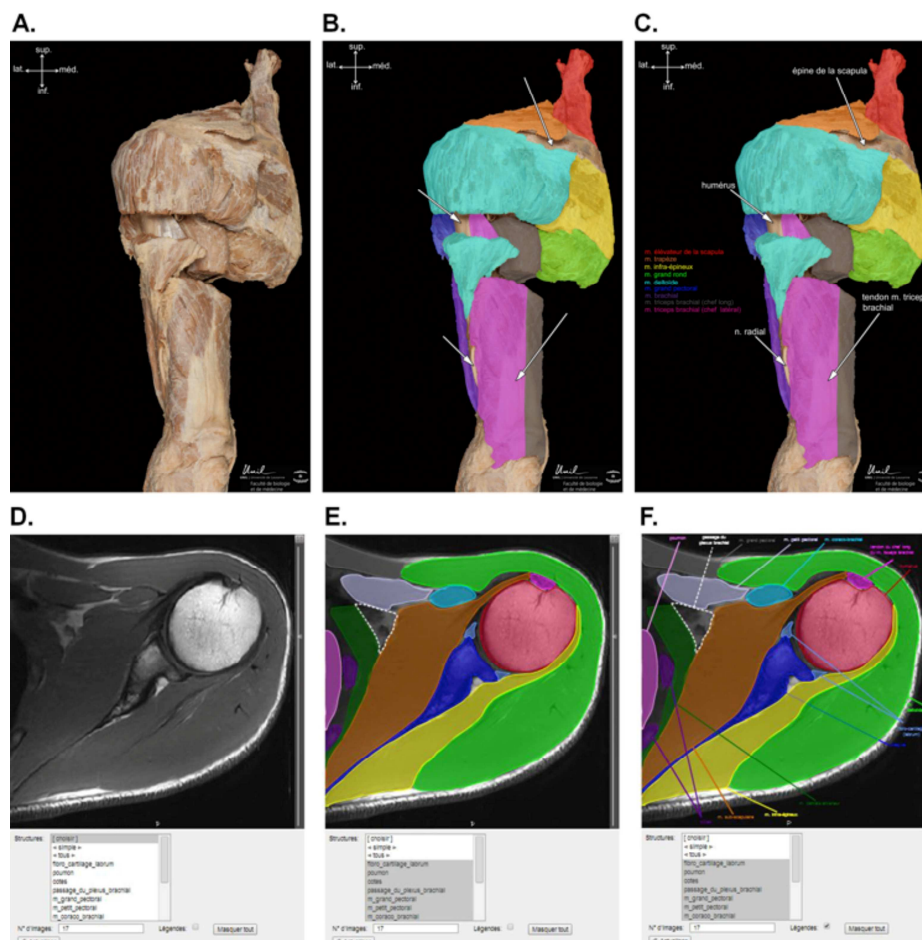
**Fig. 7.** Wet specimens are studied during practical courses. The same specimens are also accessible by web-based e-Learning.

not be relevant for preclinical teaching and such information may rather overload the already dense information given to students. However, it may be relevant in clinical anatomy and orthopedic teaching, since various deformities of the knee are common in young children who have suffered from fulminating purpura, a rare disorder characterized by irregular but symmetrical areas of rapidly advancing intracutaneous hemorrhage and necrosis (Van

der Horst & Med, 1968).

Many anatomical institutes have large collections of anatomical preparations, either at display in vitrines (Fig. 2, yellow arrow) or stored in cupboards, as well as many posters with anatomical drawings that were hanged on the wall of the dissection hall during practical teaching (yellow asterisk). However, the use of pot specimens and posters is limited. Currently we started with a project to make a photographic inventory of all specimens, and posters and to prepare a database with all images for web-based e-Learning (Fig. 6). Connections for computers are available, see yellow arrow in Fig. 3, or if needed with computer stations in place (Fig. 7).

Because the time that can be dedicated to both theoretical and practical anatomical courses for medical students at the University of Lausanne is relatively restricted, we recently developed a web-based learning supplement to give the opportunity to medical students in accessing to anatomical



**Fig. 8.** Examples of photographs of anatomical structures (A-C) and magnetic resonance images (MRI) (D-F) of the shoulder available for medical students in the web-based e-learning. (A,D) Photograph and MRI without legend. (B,E) Same photograph and MRI with (coloured) outlines and arrows indicating the main anatomical structures without legends. (C,F) Same photograph and MRI with (coloured) outlines and arrows indicating the main anatomical structures with legend. In this case, the students can verify whether they have correctly identified anatomical structures or not.

preparations outside the courses. The main principle is that the students can find in the e-learning internet site the same anatomical preparations as they used during the practical course. Photographs of these preparations were taken and then labeled (using arrows, lines, shape, outline ...) and proposed as interactive images (with or without labeling; see Fig. 8 A-C). The students have to identify or recognize the structures named in the legend and then click on the name of the anatomical structure to verify whether they succeed in the identification or not. In order to mimic the practical course conditions, the website organization follows the learning guide they used during the practical course. Then, we offer the possibility to use this web-based learning of anatomical structures during the practical course (to allow immediate testing) and outside the course. The same approach (interactive mode of e-learning) was done on consecutive magnetic resonance images (labeled or not) of the different parts of the locomotor system (see Fig. 8 D-F). Thus, web-based learning can be used by the students to revise and learn anatomy, as an accessory support to the theoretical and practical courses at any time that is convenient for the student.

From a historical point of view, it is important to see the anatomy and medical imaging development at Lausanne. The drawings are mostly made on linnen and cardboard and were made during the last century (Fig. 6). Some of these drawings may be still of use to supplement teaching, and by labeling/or not, to provide a complementary e-Learning tool for students for testing topographical anatomy knowledge, once introduced in an anatomical database. In addition, the radiology department of the University hospital will provide data sets of CT and MRI scans of a man and a woman. The dissection hall is equipped with 11 computer workstations allowing, next to the cadaver, to work on radiographic images and access to website resources.

## CONCLUSION

Teaching human anatomy to undergraduate medical students, as well as other medical trades still relies on the use of human cadavers for dissection and a practical approach of learning by doing. Every assistant student or master student confirms that by dissecting and preparing an anatomical specimen they have learned more than just by investigating an already dissected region. A successful anatomy course requires not just the acquisition of anatomical information but also the development of skills and attitudes (Moxham, 2007; Arráez-Aybar et al., 2014). Students have not to perfectly dissect, they have to learn from their mistakes and they will realize that it takes much work to prepare an anatomical specimen and

that they approach prosected specimens carefully and with respect.

## REFERENCES

- ARRÁEZ-AYBAR LA, BUENO-LÓPEZ JL, MOXHAM BJ (2014) Anatomist's views on human body dissection and donation: An international survey. *Ann Anat*, 196: 376-386.
- AYER R (2013) Etude d'un nouvel outil didactique pour l'apprentissage de la vascularization du genou en première année de médecine. Mémoire de Maitrise en Médecine No. 808, Faculté de Biologie et de Médecine, Université de Lausanne.
- BIASUTTO SN, SHARMA N, WEIGLEIN AH, MARTINEZ BENIA F, McBRIDE J, BUENO-LÓPEZ JL, KRAMER B, BLYTH P, BARROS MD, ASHIRU O., BALLESTROS LE, MOXHAM BJ, KRISHNAN S (2014) Debate: Human bodies to teach anatomy: Importance and procurement – experience with cadaver donation. *Rev Arg Anat Clin*, 6(2): 72-86.
- BOECKERS A, BAADER C, FASSNACHT UK, OECHSNER W, BOECKERS TM (2012) Reduction of mental distress in the dissection course by introducing the body donor experience through anatomical demonstrations of organ systems. *Anat Sci Edu*, 5(6): 321-329.
- CFTA-SAE (2001) Terminología Anatómica (Terminología Anatómica Internacional, Versión Oficial Española). Panamericana, Madrid. ISBN: 84-7903-614-1.
- DAMSIN JP, ZAMBELLI JY, MA R, ROUME J, COLONNA F, HANNOUN L (1995) Study of the arterial vascularization of the medial tibial condyle in the fetus. *Surg Radiol Anat*, 17: 13-17.
- FICAT-IFAA (1998) Terminologia Anatomica (International Anatomical Terminology). Stuttgart: Georg Thieme Verlag. Published on-line (open access) together with Terminologia Embryologica and Terminologia Histologica by FIPAT-IFAA: <http://www.unifr.ch/ifaa/>
- JONES DG (2002) Re-inventing anatomy: the impact of plastination on how we see the human body. *Clin Anat*, 15 (6): 436-440.
- M<sup>o</sup>HANWELL S, BRENNER E, CHIRCULESCU ARM, DRUKKER J, VAN MAMEREN H, MAZZOTTI G, PAIS D, PAULSEN F, PLAISANT O, CAILLAUD M, LAFORET E, RIEDERER BM, SANUDO JR, BUENO-LOPEZ JL, DOÑATE F, SPRUMONT P, TEOFILOVSKI-PARAPID G, MOXHAM BJ (2008) The legal and ethical framework governing Body Donation in Europe - A review of current practice and recommendations for good practice. *Eur J Anat*, 12(1): 1-24.
- RIEDERER BM, BOLT S, BRENNER E, BUEBOLOPEZ JL, CIRCULESCU ARM, DAVIES DC, DE CARO R, GERRITS PO, M<sup>o</sup>HANWELL S, PAIS D, PAULSEN F, PLAISANT O, SENDEMIR E, STABILE I, MOXHAM BJ (2012) The legal and ethical framework governing Body Donation in Europe - 1<sup>st</sup> update on current practice. *Eur J Anat*, 16(1): 1-21.



- MOXHAM BJ, MOXHAM S (2007) The relationships between attitudes, course aims and teaching methods for the teaching of gross anatomy in the medical curriculum. *Eur J Anat*, 11 (suppl 1): 19-30.
- RIEDERER BM (2014) Plastination and its importance in teaching anatomy: Critical point for long-term preservation of human tissue. *J Anat*, 224(3): 309-315.
- RIEDERER BM, BUENO-LÓPEZ JL (2014) Anatomy, respect for the body and body donation – a guide for good practice. *Eur J Anat*, 18(4): 361-368.
- SEMPERE DURÁ T (2011) *Atlas of Anatomy by Sectional Imaging*. Venal Edition. For information and/or order copies, send an e-mail to: info@lokidimas.com
- SMITH-AGREDA JM (2010) *Escolar: Reconstrucciones Humanas por Planos de Disección* (5<sup>a</sup> Edición). Panamericana, Madrid. ISBN 9788498353037.
- TURNEY BW (2007) Anatomy in a modern medical curriculum. *Ann R Coll Surg Engl*, 89(2): 104-107.
- VAN DER HORST RL, MED M (1968) Purpura fulminans – a brief report of three cases. *South African Med J*, Vol XLII: 1293-1295.