

# Twin reversed arterial perfusion sequence: acardiac-acephalic twin - a case report

Showkathali Iqbal<sup>1,\*</sup>, Mini Kariappa<sup>1</sup> and Ambooken P. Robert<sup>2</sup>

<sup>1</sup>Department of Anatomy, Amala Institute of Medical Sciences, Thrissur, Kerala, India. <sup>2</sup>Department of Radio diagnosis, Amala Institute of Medical Sciences, Thrissur, Kerala, India

## SUMMARY

Acardiac-acephalic twin is one of the bizarre complications of monozygotic, monochorionic twin pregnancies. It is commonly referred to as Twin Reversed Arterial Perfusion (TRAP) sequence, in which the primary malformation is the lack of a well-defined cardiac structure in one twin (acardiac), which is kept alive by its structurally normal co-twin (pump twin) through abnormal placental vascular anastomosis. The anomalous twin appears as a heterogenous mass simulating a teratoma, with absence of head, neck and upper limbs. Thoracic organs are either absent or underdeveloped. The majority of the acardiac twins are of female sex and have no chance of survival, and more than 50% of the fetuses have some chromosomal anomalies. The perinatal mortality rate of pump twin may be as high as 50 - 75%, mainly due to polyhydramnios, preterm labor and high-output cardiac failure. The diagnosis of the TRAP sequence can be established as early as 9<sup>th</sup> week by regular gray-scale ultrasonography and transvaginal Doppler ultrasonography. Assessment of extent of cardiac failure in the pump fetus and timing of the delivery are the key factors in the pregnancy management and in the survival of the normal co-twin. The majority of the pregnancies are managed conservatively, but in a minority group a minimally invasive procedure was needed to arrest the vascular anastomosis to improve the outcome of pump twins. The case presented here reports on

an acardiac-acephalic twin; it describes variable clinical presentations, pathophysiology and treatment modalities. It also reviews pertinent literature.

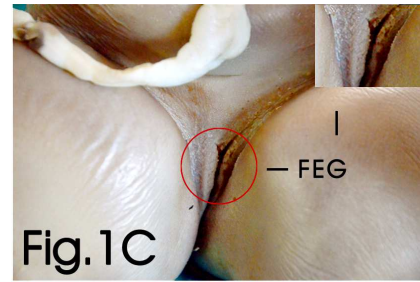
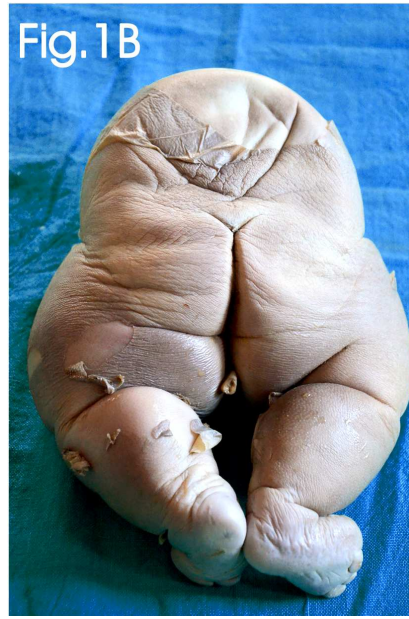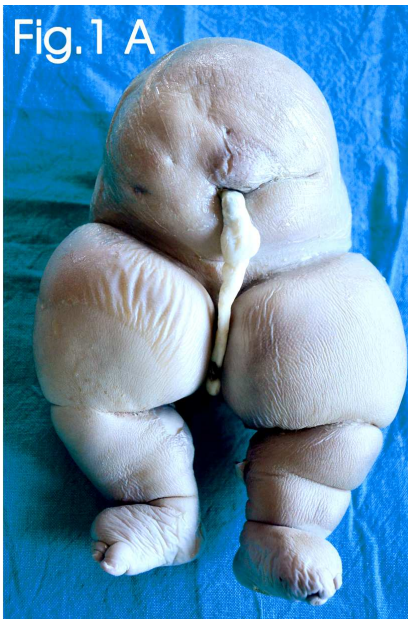**Key words:** Acardiac-acephalic – TRAP sequence – Pump twin – Monochorionic – Polyhydramnios – Teratoma – Ultrasonography

## INTRODUCTION

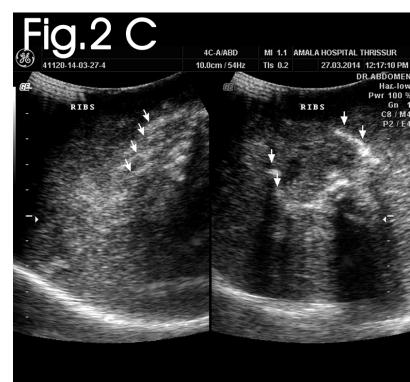
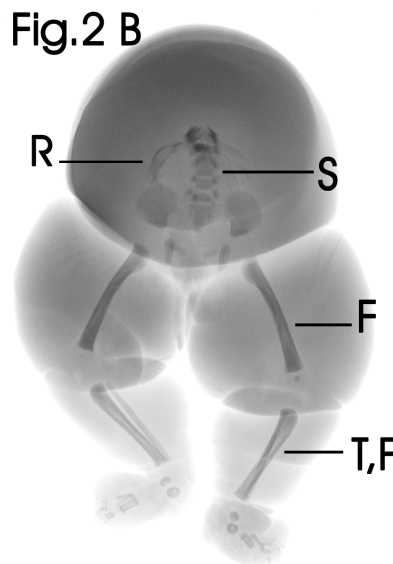
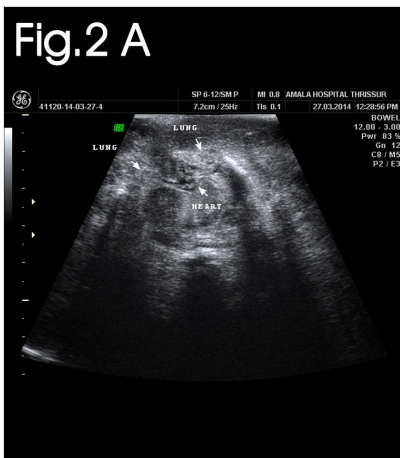
Acardiac-acephalic twin or chorioangiopagus parasiticus is a rare complication of monozygotic, monochorionic twins with an incidence of 1% of all monozygotic twins and was observed in 1 in 35,000 of all pregnancies (James, 1997). The risk of recurrence of acardiac twins was estimated to be 1 in 10,000 deliveries (Saritha et al., 2013). The primary malformation is the absence of a well-defined heart in one fetus (acardiac twin), which is kept alive by its structurally normal co-twin (pump twin) through superficial artery-artery and veno-venous placental anastomosis, without arterio-venous communication. This is commonly referred to as Twin Reversed Arterial Perfusion (TRAP) sequence, in which the arterial blood flows in a retrograde direction from the pump twin to the recipient acardiac twin through a common placenta (Abbound et al., 2000). The anomalous twin is a heterogenous mass of tissue, with a well-developed lower trunk and lower limbs. The upper half of the body including head, neck and upper limbs were totally absent. The thoracic organs including heart and lungs were either absent or poorly developed. Because of the absence of a

**Corresponding author:** Showkathali Iqbal. Department of Anatomy, Amala Institute of Medical Sciences, Amala Nagar, Thrissur 680-555. Kerala, India. Tel: + 91 9447085253. E-mail: dr.iqbal.s@gmail.com

Submitted: 20 April, 2014. Accepted: 12 May, 2014.



**Fig. 1. (A)** Anterior view of acardiac-acephalic twin - showing attachment of umbilical cord; both lower limbs were edematous with equinovarus deformity. **(B)** Posterior view of acardiac-acephalic twin. **(C)** Acardiac-acephalic twin - showing ambiguous female external genitalia (FEG).



**Fig 2. (A)** Ultrasonogram of thoracic cavity of acardiac twin showing rudimentary lungs and poorly developed heart. **(B)** Total body radiograph of acardiac twin - showing incomplete vertebral spines, rudimentary ribs and developing hip and lower limb bones. (R, ribs; S, spines; F, femur; T,F tibia, fibula). **(C)** Ultrasonogram of thoracic cavity of acardiac twin showing poorly developed ribs.

well-defined functional heart, the term “acardiac twin” has been used to describe the abnormal fetus and it has no chance of survival (Cardwell, 1988). The majority of these acardiac fetuses were of female sex (Frutiger, 1969). The TRAP sequence corresponds to the most extreme manifestation of twin-twin transfusion syndrome (TTTS) (Athwal et al., 2010). The perinatal mortality rate of pump twin, if left untreated may be as high as 50 - 75%, mainly due to polyhydramnios, preterm labor and high-output cardiac failure (Van Allen et al., 1983; Sogaard et al., 1999). The natural history of

TRAP sequence differs from patient to patient. The majority of pregnancies reach full-term with a normal surviving pump twin. Few cases may suffer from in-utero cardiac failure and sometimes intrauterine death (IUD). Thus, an aggressive invasive approach is to be performed to interrupt the inter-twin blood circulation to salvage the pump twin. Occlusion of circulation to acardiac twins has been advised to improve the perinatal outcome of the pump twin. Several intervention techniques including hysterotomy with selective delivery of acardiac twin, umbilical cord block using coils, laser coagu-

Fig.3 A

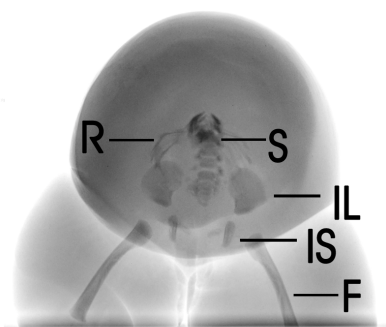


Fig.3 B

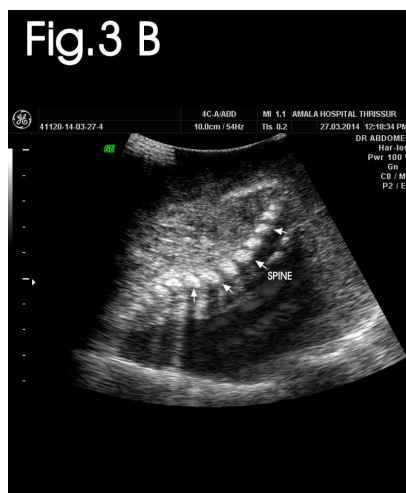
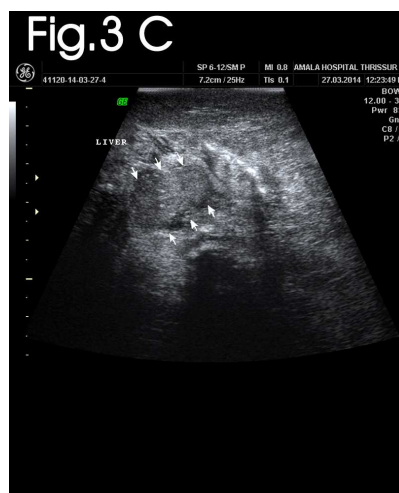
Fig.3 C



**Fig. 3. (A)** Radiograph of trunk of acardiac twin showing incomplete vertebral spines, rudimentary ribs and developing hip bones (R, ribs; S, spines; IL, ilium; IS, ischium; F, femur). **(B)** Ultrasonogram of trunk of acardiac twin showing incomplete vertebral spines. **(C)** Ultrasonogram of abdomen of acardiac twin showing poorly developed liver.

lation, alcohol ablation, bipolar coagulation and radiofrequency ablation are employed to save the pump twin (Robie et al., 1989; Porreco et al., 1991; Quintero et al., 1994; Sepulveda et al., 1995; Deprest et al., 2000; Tsao et al., 2002). The present article describes a case report of acardiac-acephalic twin and highlights its variable clinical presentations, aetio-pathogenesis, diagnosis and latest clinical intervention modalities.

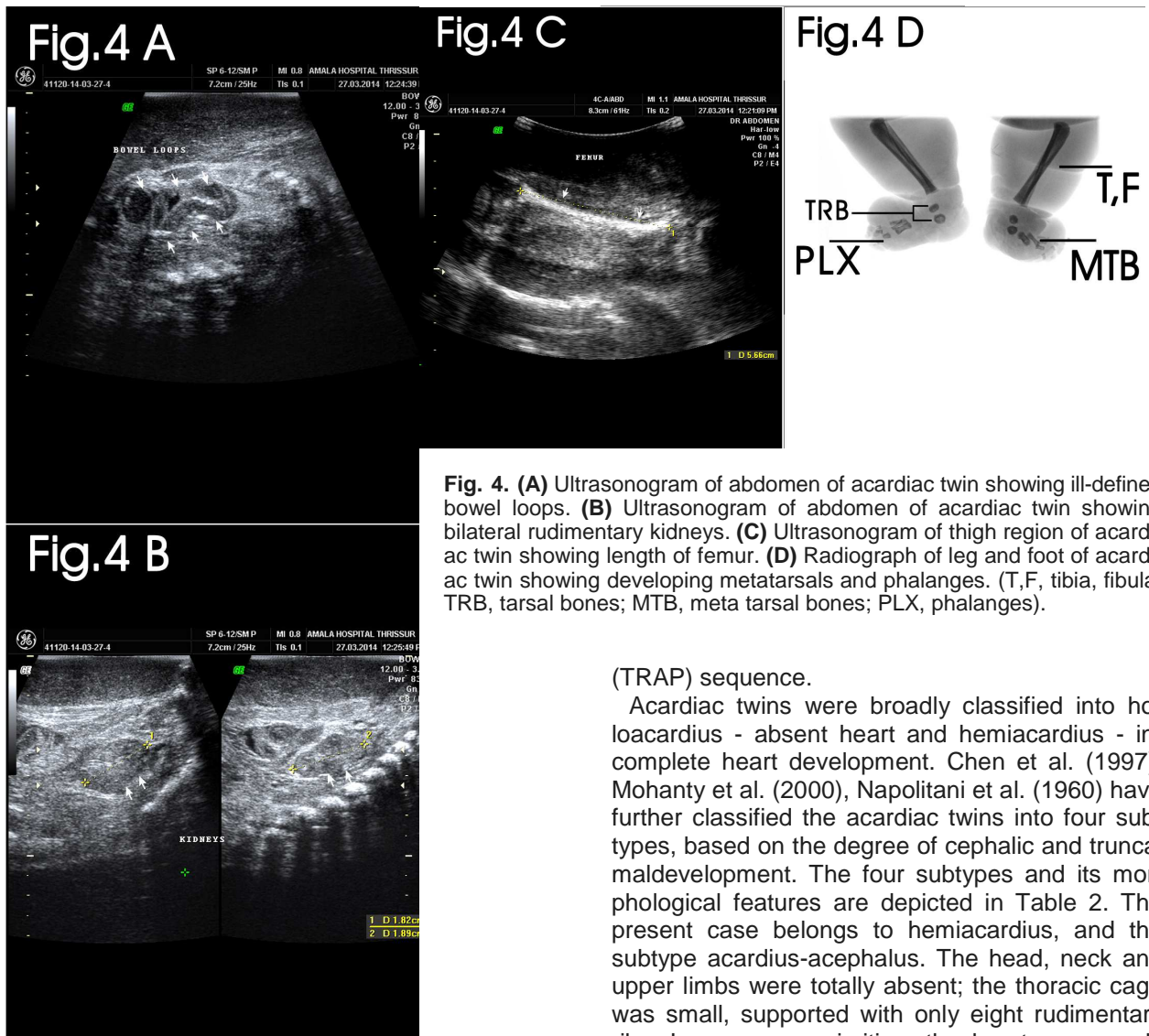
### CASE REPORT

A 28-year-old female, Gravida 4 Para 2 with previous history of normal delivery was admitted to a peripheral hospital, at 36 weeks of gestation with labor pains. Antenatal ultrasound revealed a twin pregnancy with monochorionic placenta. She had undergone a lower segment caesarean section,

because normal progress of the labor was delayed. The first twin was a live healthy female neonate, with birth weight of 2.9 kg. The second twin was an acardiac-acephalic fetus, size 24.5 x 12 x 10 cm, weight - 1830 grams, abdominal circumference - 38.5 cm and shows the following anomalies which were described in Table 1. Both twins share a common placenta, which was monochorionic and diamniotic, weighing about 500 grams. Two umbilical cords were noticed. The cord of the normal twin was long and edematous with a pair of umbilical arteries and one umbilical vein, while the cord of the acardiac twin was short with a single umbilical artery and a single vein. The acardiac fetus was covered with a reddish brown skin, which was soft and edematous with tendency to peel off. Total body radiographs and ultrasonographic scan confirm the above features.

**Table 1.** Morphological features of the acardiac-acephalic twin observed in the present case report

Serial number	Regions / parts	Morphological features observed
1	Head, neck and upper limbs	Totally absent (Figs. 1A, B and C).
2	Thoracic cavity	Small, contains a pair of rudimentary lungs and a poorly developed non-functioning heart (Fig. 2A).
3	Ribs	Rudimentary; five on left and three on right (Figs. 2B and C).
4	Vertebral column	Incomplete, ends abruptly in mid-thoracic region and contain only 14 lower spines, which include coccyx, sacrum, lumbar and lower thoracic spines (Figs. 3A and B).
5	Abdominal cavity	Wall is edematous; cavity is small and contains a small liver, multiple bowel loops and bilateral rudimentary kidneys (Figs. 3C, 4A, and B).
6	Hip	Shows developing ilium, ischium and pubis (Fig. 3A).
7	Female external genitalia	Ambiguous and ill-defined (Fig. 1C).
8	Lower limbs	Edematous, near total normal, shows bilateral genu varum and eqino-varus deformity of foot; right foot with medial three toes and left foot with medial four toes; developing femur with length - 5.66 cm, corresponds to gestational age 29 weeks and 5 days (Fig. 4C); legs show developing tibia and fibula; right foot shows developing talus, calcaneus, medial three metatarsals and proximal phalanges of medial three toes; left foot shows talus, calcaneus, medial two metatarsals and proximal and distal phalanges of medial three toes (Fig. 4D).



**Fig. 4.** (A) Ultrasonogram of abdomen of acardiac twin showing ill-defined bowel loops. (B) Ultrasonogram of abdomen of acardiac twin showing bilateral rudimentary kidneys. (C) Ultrasonogram of thigh region of acardiac twin showing length of femur. (D) Radiograph of leg and foot of acardiac twin showing developing metatarsals and phalanges. (T,F, tibia, fibula; TRB, tarsal bones; MTB, meta tarsal bones; PLX, phalanges).

Colour photographs of the acardiac twin fetus were taken using Nikon 7000-D with 16 megapixel camera. Radiography was done with a Siemens - Polydoros LX (800MA) machine and ultrasonographic scan was done with GE Voluson using two different probes - 1) 4C-A Curvilinear transducer (Frequency - 4 MHz) and 2) SP 6-12 Linear transducer (Frequency-10 MHz).

**DISCUSSION**

TRAP sequence is one of the severe complications of twin-twin transfusion syndrome (TTTS). It was first described by Grunewald in 1942 (Athwal et al., 2010). Acardiac twins have been classified according to the main anatomical abnormality - as holoacardius, pseudoacardius or based on the pathophysiology - TRAP sequence or parasitic dependence on co-twin - chorioangiopagus parasiticus. The most accepted terminology today is acardiac twin or Twin Reversed Arterial Perfusion

(TRAP) sequence.

Acardiac twins were broadly classified into holoacardius - absent heart and hemiacardius - incomplete heart development. Chen et al. (1997), Mohanty et al. (2000), Napolitani et al. (1960) have further classified the acardiac twins into four subtypes, based on the degree of cephalic and truncal maldevelopment. The four subtypes and its morphological features are depicted in Table 2. The present case belongs to hemiacardius, and the subtype acardius-acephalus. The head, neck and upper limbs were totally absent; the thoracic cage was small, supported with only eight rudimentary ribs. Lungs were primitive; the heart was poorly developed, remained in the tubular form and non-functioning. Great vessels were seen inside the thoracic cavity. The vertebral spines ended abruptly in the mid-thoracic region with only 14 lower spines. The abdominal cavity was small, contained a small liver, multiple bowel loops and bilateral rudimentary kidneys. The acardiac twin was female with ambiguous external genitalia. The lower extremities were edematous with bilateral equinovarus deformity. The length of the femur was 5.66 cm, which corresponds to gestational age of 29 weeks and five days (Callen et al., 1988). It is likely that with these severe deformities, the “growth age” lagged behind the “gestational age”. It had a mono chorionic and diamniotic placenta. Majority of the case reports received also belong to this category and are of female sex (Frutiger, 1969; Napolitani et al., 1960; Spencer et al., 2001; Dhall et al., 2005). About 75% of the cases of acardiac twins described in the literature have a short umbilical cord with one umbilical artery and one umbilical vein, which indicates the persistence of transitory single artery phase that corresponds to Carnegie

stage 12 (Monie, 1970). The umbilical cord of the acardiac fetus presented here had only one umbilical artery and one umbilical vein, suggesting that the pathology might have occurred at or earlier than Carnegie stage 12.

TRAP sequence was commonly encountered in monozygotic, monochorionic twins, in which there was a disruption in the organogenesis due to placental artery-artery anastomosis in early embryonic period. It represents a variant of conjoined twins in which the junction is the chorionic circulation. The normal twin pumps blood to the acardiac recipient twin through artery-artery connections in the placenta. The pump twin provides circulation for both itself and the acardiac twin. In this clinical case, there is no direct vascular connection between the acardiac twin and the placenta. Blood enters directly through the single umbilical artery and exits through the umbilical vein. The placental pressure of the normal twin overpowers that of the acardiac twin. So there is a reversal of blood flow in the acardiac twin; the deoxygenated arterial blood, on reaching the recipient, perfuses only the lower half of the body, thereby leading to disruption or deterioration of growth and development of the upper part of the body. Thus the hypoxic flow through arterial communications from pump twin results in partial reabsorption of normal tissues of acardiac twin (Manala et al., 2010; Levi et al., 2005; Wader et al., 2013). The acardiac-recipient twin is in a haemodynamically disadvantaged state and develops severe anomalies which are incompatible with life. So in routine antenatal ultrasonographic examination, acardiac twin appears as a heterogenous mass, like a teratoma or intrauterine fetal death (IUD) (Monteagudo et al., 2005).

Several hypotheses have been proposed to explain the development of this anomaly. First, during embryonic development, the inner cell mass separates very late into two cell masses resulting in the formation of monochorionic twins. Due to the anastomosis of vessels in the placenta, a connection has been established between two circulations that causes retrograde perfusion secondary to the pressure difference in the blood flow. This arrests development of the heart, which then remains in

primitive tubular form. Thus, the acardiac fetus remains as parasitic twin and completely depends on pump twin for its survival (Saritha et al., 2013). Second, a primary defect in the embryonic disc during 4-8 weeks of gestation, may lead to failure in the development of heart, which remains in tubular form. Then, the pump twin perfuses the acardiac twin through artery-artery anastomoses (Athwal et al., 2010). Third, Fusi et al., (1990) reported the presence of thrombi in the lungs, liver and kidneys of the acardiac fetus and concluded that acardia was due to the consequence of a localized vascular event in the form of thrombotic/thromboembolic manifestations of thoracic/abdominal vessels, followed by resorption of the affected tissues. In addition, genetic defects in the form of chromosomal aberrations - viz., mosaicism and trisomies have been found to be associated with the development of acardiac fetus in over 50% of the cases (Van Allen et al., 1983; Barth et al., 2000). Some authors described that during embryonic development, the cephalic pole of the embryo has been compressed, which results in inhibition of curving and fusion of primitive heart tubes, leading to the development of acardiac twins (Krause et al., 1948).

Acardiac-acephalic twins were first reported in 1533 by Beneditti (Napolitani et al., 1960). Acardiac fetuses are usually seen in multiple births and over 66% are monochorionic and diamniotic. The overall prevalence is estimated to be one in 340 deliveries; 1% of all monozygotic twin deliveries and one in 30 monozygotic triplets (James, 1997). The majority of acardiac twins were predominantly females (Frutiger, 1969). Two thirds of all acardiac fetuses are acardiac-acephalic, being the commonest variety among all acardiac twins (Napolitani et al., 1960; Spencer et al., 2001). The perinatal mortality of the pump twin is around 50-75%. This is due to congestive heart failure due to high cardiac output, prematurity and cord entanglement (Moore et al., 1990). Other poor prognostic indicators include polyhydramnios, preterm delivery (< 32 weeks gestation), hydrops fetalis and respiratory distress syndrome (Athwal et al., 2010). A larger, much developed acardiac twin with multi-

**Table 2.** Morphological classification of acardiac twins

Serial Number	Subtypes of Acardiac twins	Morphological features	Prevalence
1	Acardius acephalus	Absent head, cervical spines and upper limbs; abdomen, pelvis and lower limbs are well developed	Most common
2	Acardius anceps	Poorly developed head, neck and brain; trunk, upper and lower limbs are well developed	Highly developed
3	Acardius acornus	Well-developed head, neck and upper extremities; abdomen and lower limbs are not fully developed; umbilical cord attached to head region	Rare
4	Acardius amorphous	Amorphous mass without cephalic and truncal differentiation; differentiated from teratoma by attachment of umbilical cord	Poorly developed

ple internal organs significantly increases perinatal mortality of the pump twin (Paek et al., 2003). Although most pump twins are structurally normal, 10% shows some sort of congenital anomalies (Sogaard et al., 1999).

Pregnancies with acardiac twins should be carefully assessed based on the prognostic factors - viz., size and growth of the acardiac twins and the cardiovascular status of pump fetus. The pregnancy outcome is influenced by Twin Weight Ratio (TWR) viz., weight of acardiac/weight of pump fetus. If TWR exceeds 50%, the prognosis of pump fetus is grave. On the other hand, if TWR is less than 25%, the prognosis seems to be better (Moore et al., 1990). In the present case report, the TWR was 0.63 (63%), which was greater than 50%, but the pump fetus was normal without any signs of cardiac failure. Moreover, the kidneys were rudimentary in nature; polyhydramnios was not observed during gestation.

Differential diagnoses of acardiac twinning are hydrops fetalis, cystic hygromas, singleton pregnancies with intra-amniotic tumors, pseudocardiac twins, amniotic band syndrome and the heterogenic teratoma. Other less common conditions to be excluded are the possible arrest in evolution of one fetus from a twin pregnancy as well as anencephaly. Attachment of umbilical cord to the head end of the trunk with developed abdominal organs will exclude teratoma, while the pattern blood flow to the twin with development of lower extremities excludes hydrops (Wader et al., 2013).

The diagnosis of the twin pregnancies with acardiac-acephalic fetuses can be established by ultrasound examinations and Doppler studies as early as the 9th week of gestation, when the cephalic pole and limbs have been precisely determined. The absence of heart sounds, fetal movements, difficulty in visualization of trunk and cephalic poles, thickening and edema of subcutaneous tissue and the presence of reverse flow in the umbilical artery towards acardiac fetus pinpoint the diagnosis (Tan et al., 2003). Fetal ECHO along with USG is essential to evaluate signs of heart failure, cardiomegaly and hydramnios in pump twins (Stamatian et al., 2011).

The treatment options include either conservative or interventional approaches which differ from patient to patient and also depends on parameters such as amnionicity, morphology and cardiac status of pump twin, size of the acardiac twin and cord and their relationship with the pump twin. These factors must be taken into account before selecting the most suitable therapy (Blickstein et al., 2001). Conservative management is advised in patients where the acardiac twin is small and with no signs of cardiovascular involvement of pump twin or in cases with spontaneous closure of shunt due to tight umbilical cord wrapping. The main aim of the management is to monitor the pump twin for developing heart failure, polyhydramnios, prema-

ture birth and cord entanglement. Regular follow-up at two-week intervals with USG, fetal ECHO, non-stress test (NST), biophysical score, Doppler ultrasound and TWR are needed in all cases. In patients with decreased TWR, conservative management is appropriate and in cases with increased ratio, delivery must be induced (Sullivan et al., 2003).

The OBG specialists advised active and minimally invasive measures to stop supply of blood from pump to acardiac twin (Stamatian et al., 2011). In-utero treatment modalities include medical therapies - viz., inotropic drugs - Digoxin should be administered to treat heart failure; while Indomethacin along with amniocentesis should be advised in polyhydramnios (Simpson et al., 1983) and selective delivery of the acardiac twin during 2nd trimester, followed by prolongation of normal twin pregnancy (Dhall et al., 2005). Hysterotomy ligation of the umbilical cord of the acardiac twin by using fetoscopy was performed by Quintero et al (1994) with a success rate of 70-80%; about 10% of the cases showed premature rupture of membranes and significant risk of bleeding. Thrombosis of umbilical arteries, using thrombogenic materials, alcohol and sutures soaked in alcohol are primarily used to block supply to acardiac twins. These procedures have their own complications in the form of recanalization of the thrombosed vessels or migration of embolus towards pump twin, leading to death of both fetuses (Quintero et al., 1996). An intrafetal approach to interrupt the vascular supply to the acardiac twin seems to be safe and superior to cord occlusion techniques (Tan et al., 2003; Wong et al., 2005). The modern day managements of TRAP sequence is endoscopic coagulation of vessels using laser (Nd: YAG) during mid-pregnancy, radio frequency ablation under ultrasound guidance and thermal coagulation (Van Allen et al., 1983). The success rate of these procedures was better in the early second trimester and less successful in the third trimester because the umbilical cord is more edematous with higher content of Wharton's jelly. So the ultimate goal in the management of TRAP sequence is to salvage the pump fetus of its complications, mainly of high output failure.

### Conclusion

Acardiac-acephalic twin is a rare obstetric complication of monochorionic twin gestation. The present case reported an acardiac-acephalic female twin, with well-developed lower trunk and lower limbs; the upper half of the body was totally absent with a rudimentary non-functional heart. This is the most common form of all acardiac twins. Early and accurate antenatal diagnosis is essential to salvage the pump twin from its usual complications. Advanced imaging procedures, viz., 3D ultrasonography and transvaginal Doppler ultrasonography can be used to confirm the diagnosis during

the first trimester of pregnancy. Minimally invasive procedures might be required to arrest the vascular anastomosis and improve the outcome of pump twins.

#### ACKNOWLEDGEMENTS

The authors sincerely acknowledge TA Ajith, Ph.D., Professor of Biochemistry, Amala Institute of Medical Sciences, Thrissur, Kerala, India, for his expertise in the preparation of the manuscript. The authors also thank KR Sugathan, Tutor, CD Sindhu, Senior laboratory technician, PP Mathews, Senior theatre assistant, PP Suresh, Mortuary technician, Department of Anatomy, Amala Institute of Medical Sciences, Thrissur, Kerala, India, for their expertise and help in the preparation and proof reading of the case report.

**Consent.** Informed consent was obtained from parents prior to the preparation of the manuscript. The acardiac twin fetus was donated to the department museum and was preserved in 10% formalin, in the Department of Anatomy, Amala Institute of Medical Sciences, Thrissur, Kerala state in India.

#### REFERENCES

- ABBOUND P, GARNIER R, MANSOUR G, GABRIEL R, GAILLARD D, QUEREUX C (2000) Acardiac fetus in a triplet pregnancy: Ultrasound pitfalls - a case report. *Eur J Obstet Gynecol Reprod Biol*, 89: 75-80.
- ATHWAL S, MILLARD K, LAKHOO K (2010) Twin reversed arterial perfusion (TRAP) sequence in association with VACTERL association: a case report. *J Med Case Reports*, 4: 411.
- BARTH RA, CROW HC (2000) Ultrasound evaluation of multifetal gestations. In: Callen PW (ed). *Callen ultrasonography in obstetrics and gynaecology*. 4<sup>th</sup> ed. WB Saunders, Pennsylvania, pp 196-198.
- BLICKSTEIN I (2001) Twin reverse arterial perfusion sequence. In: Blickstein I, Keith LG (eds). *Multiple pregnancy. Epidemiology, gestation and perinatal outcome*. 2<sup>nd</sup> ed. Informa Healthcare, pp 594-600.
- CALLEN PW (1988) *Ultrasonography in Obstetrics and Gynecology*. 2<sup>nd</sup> ed. Saunders, Philadelphia.
- CARDWELL MS (1998) The acardiac twin: A case report. *J Reprod Med*, 33: 320.
- CHEN CP, SHIH SL, LIU FF, JAN SW, LIN YN, LAN CC (1997) Skeletal deformities of acardiac aniceps: The gross anatomical features. *Pediatr Radiol*, 27: 221-225.
- DEPREST JA, AUDIBERT F, VAN SCHOUBROECK D, HECHER K, MAHIEU-CAPUTO D (2000) Bipolar coagulation of the umbilical cord in complicated monochorionic twin pregnancy. *Am J Obstet Gynecol*, 182: 340-345.
- DHALL U, KAYALVIZHI I, MAGU S (2005) Acardiac acephalus monster - a case report. *J Anat Soc India*, 54: 26-28.
- FRUTIGER P (1969) Zum Problem der Akardie. *Acta Anat*, 74: 505-531.
- FUSI L, FISK N, TALBERT D, GAU G, RODECK C (1990) When does death occur in an acardiac twin? Ultrasound diagnostic difficulties. *J Perinat Med*, 18: 223-227.
- JAMES WH (1977) A note on the epidemiology of acardiac monster. *Teratology*, 16: 211-216.
- KRAUSE W, BEJDL W, BEISTRAG ZXUM (1948) Acardiac problem. *Acta Anat*, 6: 226-268.
- LEVI CS, LYONS EA, MARTEL MJ (2005) Sonography of multifetal pregnancy. In: Carol M, Rumack (ed). *Diagnostic ultrasound*. 3<sup>rd</sup> ed. Vol. 2. Elsevier Mosby, Missouri, pp 1207-1209.
- MANALA S, DAKSHAYANI KR (2010) Acardia acephalus twin - a case report. *Anatomica Karnataka*, 4: 76-80.
- MOHANTY C, MISHRA OP, SINGH CP, DAS BK, SINGLA PN (2001) Acardiac anomaly spectrum. *Teratology*, 62: 356-359.
- MONIE IW (1970) Genesis of single umbilical artery. *Am J Obstet Gynecol*, 108: 400-405.
- MONTEAGUDO A, ROMAN AS (2005) Ultrasound in multiple gestations: Twins and other multifetal pregnancies. *Clin Perinatal*, 32: 329-354.
- MOORE T, GALE S, BENIRSCHKE K (1990) Perinatal outcome of forty-nine pregnancies complicated by acardiac twinning. *Am J Obstet Gynecol*, 163: 907-912.
- NAPOLITANI FD, SCHREIBER I (1960) The acardiac monster: a review of the world literature and presentation of two cases. *Am J Obstet Gynecol*, 80: 582-589.
- PAEK B, GOLDBERG J, ALBANESE C (2003) Prenatal diagnosis. *World J Surg*, 27: 27-33.
- PORRECO RP, BARTON SM, HAVERKAMP AD (1991) Occlusion of umbilical artery in acardiac, acephalic twin. *Lancet*, 337: 326-327.
- QUINTERO RA, REICH H, PUDER KS, BARDICEF M, EVANS MI, COTTON DB, ROMERO R (1994) Brief report: Umbilical-cord ligation of an acardiac twin by fetoscopy at 19 weeks of gestation. *N Engl J Med*, 330: 469-471.
- QUINTERO R, ROMERO R, REICH H (1996) In utero percutaneous umbilical cord ligation in the management of complicated monochorionic multiple gestation. *Ultrasound Obstet Gynecol*, 8: 16-22.
- ROBIE GF, PAYNE GG, MORGAN MA (1989) Selective delivery of an acardiac, acephalic twin. *N Engl J Med*, 320: 512-513.
- SARITHA S, SUMEDHA S, ANJANKAR VP (2013) Twin Reversed Arterial Perfusion Sequence (TRAP Sequence). The acardiac/acephalic twin. *Int J Anat Res*, 03: 140-144.
- SEPULVEDA A, BOWER S, HASSAN J, FISK NM (1995) Ablation of acardiac twin by alcohol injection into the intra-abdominal umbilical artery. *Obstet Gynecol*, 86: 860-861.
- SIMPSON PC, TRUDINGER BJ, WALKER A, BAIRD PJ (1983) The intrauterine treatment of fetal cardiac failure in a twin pregnancy with an acardiac, acephalic

- monster. *Am J Obstet Gynecol*, 147: 842-844.
- SOGAARD K, SKIBSTED L, BROCKS V (1999) Acardiac twins: pathophysiology, diagnosis, outcome, and treatment. *Fetal Diagn Ther*, 14: 53-59.
- SPENCER R (2001) Parasitic conjoined twins: external, internal (fetuses in fetu and teratomas), and detached (acardiacs). *Clin Anat*, 14: 428-444.
- STAMATIAN F, MURESAN D, CARACOSTEA G, KOVACS T (2011) Advances in ultrasonic assessment of acardiac twin. *Donald School J Ultrasound Obstet Gynecol*, 5: 213-218.
- SULLIVAN AE, VARNER MW, BALL RH, JACKSON M, SILVER RM (2003) The management of acardiac twins: A conservative approach. *Am J Obstet Gynecol*, 189: 1310-1313.
- TAN TYT, SEPULVEDA W (2003) Acardiac twin: a systematic review of minimally invasive treatment modalities. *Ultrasound Obstet Gynaecol*, 22: 409-419.
- TSAO K, FELDSTEIN VA, ALBANESE CT, SANDBERG PL, LEE H, HARRISON MR, FARMER DL (2002) Selective reduction of acardiac twin by radiofrequency ablation. *Am J Obstet Gynecol*, 187: 635-640.
- VAN ALLEN MI, SMITH DW, SHEPARD TH (1983) Twin reversed arterial perfusion (TRAP) sequence: a study of 14 twin pregnancies with acardius. *Semin Perinatol*, 7: 285-293.
- WADER JV, KUMBHAR S, WHAWAL V, JOSHI SS (2013) Acephalic acardiac fetus. *Online J Health Allied Scs*, 12: 15. Available at URL: <http://www.ojhas.org/issue46/2013-2-15.html>
- WONG AE, SEPULVEDA W (2005) Acardiac anomaly: Current issue in prenatal assessment and treatment. *Prenatal Diagn*, 25: 796-806.