

A retrocaval right testicular artery with an arching left testicular artery

Jing Li

Department of Anatomy, Academy of Basic Medicine, Jining Medical University, Jining, Shandong, China

SUMMARY

Bilateral variations of the testicular arteries were found during the dissection of a 36-year-old Chinese male cadaver. The right testicular artery originated from the antero-lateral aspect of the abdominal aorta at the same level of the right renal artery. After a short course behind the inferior vena cava, it continued on its normal route distally with the right testicular vein. The left testicular artery arose from the abdominal aorta almost at the same level as the left renal artery, arching over the left renal vein to descend in front of it. Awareness of such variations of testicular arteries and their unusual origin and course could contribute to higher success of surgical procedures.

Key words: Testicular artery – Retrocaval course – Arching – Origin

INTRODUCTION

The anatomy of the testicular arteries has been well studied because of its importance in testicular physiology and testicular surgeries. Most commonly the testicular arteries arise from the abdominal aorta at the second lumbar vertebral level, descending on the posterior abdominal wall and entering the inguinal canal through the deep inguinal ring.

The anomalies of the testicular arteries include variations of their origin, course and number (Adachi, 1928; Notkovich, 1955). In 5-6% of cases the vessels originate from the main or accessory renal artery, and in 5-20% of cases it has a more superior origin (Asala et al., 2001). They may also

arise from a common trunk (Reddy et al., 2011), or may be doubled, tripled or quadrupled (Pai et al., 2008; Nayak et al., 2007). Very rarely they originated from the middle mesenteric artery (Naito et al., 2011) or the common iliac artery (Mamatha et al., 2011). In the present report we describe the testicular arteries arisen at the level of the renal arteries, as well as the left testicular artery arched over the left renal vein.

CASE REPORT

During a gross anatomy dissection of the abdomen of a 36-year-old male cadaver, we observed variations of the testicular arteries. The left testicular artery arose from the antero-lateral surface of the abdominal aorta at the same level of the left renal artery, dorsal to the left renal vein. It progressed in an upward course, arching over the left renal vein to descend in front of it. The artery coursed anterior to the left ureter, the psoas major muscle and entered the deep inguinal ring in the abdominal wall (Fig. 1B). The right testicular artery originated from the abdominal aorta at the same level of the ipsilateral renal artery, posterior to the left renal vein. It coursed obliquely behind the inferior vena cava over the psoas major muscle to enter the deep inguinal ring in the abdominal wall (Fig. 1A).

COMMENTS

Notkovich (1956) examined the testicular and ovarian arteries and described three different patterns in relation to the renal vein: group 1, the gonadal arteries arose from the abdominal aorta behind or below the renal vein, and proceeded downwards and laterally into the inguinal canal; group 2, the gonadal arteries arose above the level of the renal vein and crossed in front of it; group 3, the

Corresponding author: Jing Li. Department of Anatomy, Academy of Basic Medicine, Jining Medical University, Jining 272067, Shandong, China. Tel: (0086)0537-3616290. E-mail: Alexlijing800912@yahoo.com

Submitted: 29 April, 2014. Accepted: 18 September, 2014.

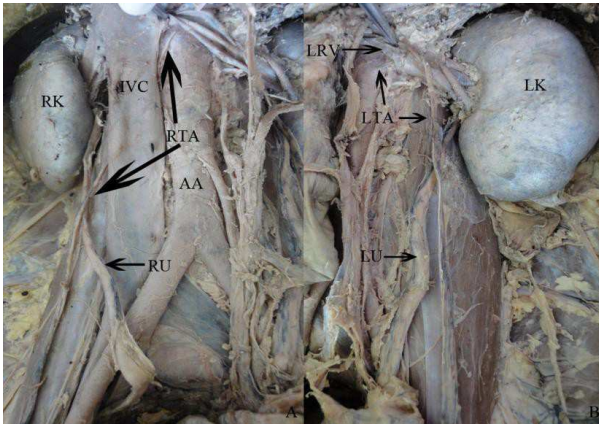


Fig. 1. Dissection of the retroperitoneal space, anterior view: **(A)** RTA - right testicular artery, IVC - inferior vena cava, RU - right ureter, RK - right kidney, AA - abdominal aorta. **(B)** LTA - left testicular artery, LRV - left renal vein, LK - left kidney, LU - left ureter.

gonadal arteries arose from the aorta behind or below the renal vein and coursed upwards to arch over the renal vein. In this case, the left testicular artery was in accordance with group 3; the right testicular artery belonged to group 1, with an unusual course behind the inferior vena cava (Notkovich, 1956).

A high origin of the gonadal arteries has been reported in the literature. They may originate from the abdominal aorta at the level of the renal artery (Brohi et al., 2001; Tanyeli et al., 2006), between the position of the superior mesenteric artery and renal artery (Shoja et al., 2007), or at the level of the superior mesenteric artery (Ozan et al., 1995). In the literature, a testicular artery arose 1 cm cranial to the origin of the left inferior phrenic artery, being the highest level of origin reported (Shinohara et al., 1990). A testicular artery may also branch off the inferior phrenic and supra renal arteries (Onderoglu et al., 1993). It was believed that the arching artery occurred more frequently on the left side (Lelli et al., 2007), but seldom on the right side (Mirapeix et al., 1996). In very rare cases, both the left and right testicular arteries arched over the left renal vein (Nathan et al., 1976).

This variation in our case is worth reporting in efforts to educate clinicians involved in abdominal and urogenital surgical procedures. A deep knowledge of these variations and their relations to the adjacent structures is very important in avoiding the complications in operative surgery. With the advent of new surgical and diagnostic techniques, understanding of atypical anatomical presentations gains more importance.

REFERENCES

- ADACHI B (1928) *Das Arteriensystem der Japaner, vol. II.* Maruzen, Kyoto, pp 73-74.
- ASALA S, CHAUDHARY SC, MASUMBUKO-KAHAMBA N, BIDMOS M (2001) Anatomical variations in the human testicular blood vessels. *Ann Anat*, 183:545-549.
- BROHI RA, SARGON MF, YENER N (2001) High origin and unusual suprarenal branch of a testicular artery. *Surg Radiol Anat*, 23:207-208.
- LELLI F, MAURELLI V, MARANILLO E, VALDERRAMA-CANALES FJ (2007) Arched and retrocaval testicular arteries: a case report. *Eur J Anat*, 11: 119-122.
- MAMATHA Y, PRAKASH BS, PADMALATHA K (2011) Rare variant origin of right testicular artery - a case report. *Asian J Med Sci*, 2:65-67.
- MIRAPEIX RM, SANUDO JR, FERREIRA B, DOMENECH-MATEU JM (1996) A retrocaval right testicular artery passing through a hiatus in a bifid right renal vein. *J Anat*, 189:689-690.
- NAITO M, HIRAI S, TERAYAMA H, QU N, YI SQ, MIYAKI T, ITOH M (2011) Multiple renal vessels associated with testicular vessels. *Surg Radiol Anat*, 33:637-639.
- NATHAN H, TOBIAS PV, WELLSTED MD (1976) An unusual case of right and left testicular arteries arching over the left renal vein. *Brit J Urol*, 48: 135-138.
- NAYAK SR, J JP, D'COSTA S, PRABHU LV, KRISHNAMURTHY A, PAI MM, PRAKASH (2007) Multiple anomalies involving testicular and suprarenal arteries: embryological basis and clinical significance. *Rom J Morphol Embryol*, 48:155-159.
- NOTKOVICH H (1955) Testicular artery arching over renal vein: clinical and pathological considerations with special reference to varicocele. *Brit J Urol*, 27: 267-271.
- NOTKOVICH H (1956) Variations of the testicular and ovarian arteries in relation to the renal pedicle. *Surg Gynecol Obstet*, 103:487-495.
- ONDEROGLU S, YUKSEL M, ARIK Z (1993) Unusual branching and course of the testicular artery. *Ann Anat*, 175:541-544.
- OZAN H, GUMUSALAN Y, ONDEROGLU S, SIMSEK C (1995) High origin of gonadal arteries associated with other variations. *Ann Anat*, 177:156-160.
- PAI MM, VADGAONKAR R, RAI R, NAYAK SR, JIJI PJ, RANADE A, PRABHU LV, MADHYASTHA S (2008) A cadaveric study of the testicular artery in the South Indian population. *Singapore Med J*, 49: 551-555.
- REDDY S, BHAT SM, MATHEW JG, SHETTY PC, GORANTLA VR, JETTI R, VOLLALA VR (2011) A common trunk of origin of the right testicular and middle suprarenal arteries with a retrocaval course. *Indian J Surg*, 73:314-315.
- SHINOHARA H, NAKATANI T, FUKUO Y, MORISAWA S, MATSUDA T (1990) Case with a high-positioned origin of the testicular artery. *Anat Rec*, 226:264-266.
- SHOJA MM, TUBBS RS, SHAKERI AB, OAKES WJ (2007) Origins of the gonadal artery: embryologic implications. *Clin Anat*, 20:428-342.
- TANYELI E, UZEL M, SOYLUOGLU AI (2006) Complex renal vascular variation: A case report. *Ann Anat*, 185: 455-458.