

Phenoxetol as a formaldehyde-removing agent for long-term preservation: our experience

A. Tandon, R. Bhatnagar, Rishi Pokhrel and Kirti Solanke

Dept. of Anatomy, Armed Forces Medical College, Pune- 40, India

SUMMARY

On 10 June 2011, the US National Toxicology Program described formaldehyde as "known to be a human carcinogen". However, formaldehyde is not just a human carcinogen but the cause of other many hazards; respiratory distress, red eyes, etc. Occupational health authorities throughout the world are therefore likely to increase the strictness of regulations for the use of formaldehyde within anatomical disciplines. This study evaluates an alternative for formaldehyde as a preservative for cadavers and human tissues. Tissue samples preserved in 4% formaldehyde were compared with those in 1% Phenoxetol (prefixed in formaldehyde) over a year. Histology slides prepared using Phenoxetol as a preservative were also compared with the conventional ones.

The soft consistency, color and flexibility, especially at joints of specimens preserved in Phenoxetol, were found to be suitable for dissection, demonstration and display purposes. Culture of the eleven tissue samples showed no growth after seventy-two h. Microscopic structure of the tissues remained satisfactory when processed with 1% Phenoxetol. Students also found experience with cadavers preserved in phenoxetol very pleasant as it has a fruity smell as compared to the offensive odor of formaldehyde. Phenoxetol is a suitable alternative for the preservation of specimens. However efforts have to be made to reduce or replace the use of formaldehyde as a primary fixative.

Key words: Dissection – Formaldehyde – Medical education – Propylene phenoxetol – Tissue fixation

INTRODUCTION

From a theoretical point of view one should distinguish between initial fixation and long-term preservation of animal tissue for dissection or exhibition purposes. The primary aim of the initial fixation is to arrest the tissue structures in a life-resembling fashion or to largely inactivate autolytic enzymes. The long-term preservation, on the other hand, should primarily prevent microbial overgrowth and tissue maceration.

Today there is no reason, beyond saving of labour, to maintain that the same chemicals are the most satisfactory ones for both purposes. On the contrary, there are overwhelmingly strong reasons to exclude our most widely used fixatives like formaldehyde and phenol from long-term preservation fluids. Both substances have prominent toxic, pungent and unpleasant properties. Formaldehyde has been shown to cause mutation in various primitive organisms (Nishioka 1973; Slizynska, 1957) and in cultured mammalian cells (Ragan and Boreiko, 1981; Ross and Shipley, 1980). Furthermore, inhaled formaldehyde caused nasal carcinoma in rats and mice (Albert et al., 1982) and subcutaneously injected formaldehyde caused sarcoma in rats (Watanabe et al., 1954). Recent epidemiologic surveys among embalmers and industrial workers exposed to formaldehyde indicated an

Corresponding author: Rishi Pokhrel. Armed Forces Medical College, Department: Anatomy, AFMC, Pune-4110400, India.
Tel: 0091-8390483376. E-mail: rongon28us@yahoo.com

Submitted: 25 December, 2013. *Accepted:* 11 March, 2014.

increased cancer risk to humans (Hauptmann et al., 2003).

The United States National Toxicology Program has classified formaldehyde as a "known human carcinogen" (Sebelius, 2011). However, formaldehyde is not just a human carcinogen but the cause of other many hazards; respiratory distress, red eyes, etc. (Chia et al., 1992; Akbar-Khanzadeh et al., 1994). Occupational health authorities throughout the world, accordingly, are likely to put strict regulations on the use of formaldehyde even in anatomy disciplines in the near future. In several countries including Denmark, Norway, Sweden, and Germany a ceiling concentration of 1-ppm formaldehyde in the working environment (equivalent to 1.2 mg formaldehyde per m air) has been practiced for some years. Only Russia has set a lower limit (0.4 ppm), whereas other countries still practice more liberal regulations (2 ppm in the United States). It has, however, been proposed that the ceiling concentration should be set as low as 0.03-0.3 ppm (Frølich et al., 1984).

Fixing and preserving tissues in formaldehyde easily results in atmospheric formaldehyde concentrations of 5-7 ppm (Bjorkman and Christensen, 1982). Thus, it can be reasonably inferred that the restrictions mentioned above will force many laboratories throughout the world to dramatically alter their procedures for tissue preservation.

Some laboratories have already found ways of abandoning the use of formaldehyde and phenol for long-term preservation of specimens for dissection and museum purposes. Most widely used among such methods is the immersion of previously formaldehyde- and phenol- fixed specimens in alcohol solutions ranging in concentration up to 75% (Spence and Zuckerman, 1967). This principle has recently been reinvestigated by Bjorkman and Christensen (1982), who found that the atmospheric formaldehyde concentration was lowered to below 0.5 ppm when the specimens had been extracted for about 3 months in 20-50% ethanol. However, ethanol in high concentrations is expensive, flammable and evaporates rapidly. In addition, most tissues are subject to excessive hardening and loss of natural colors. In lower concentrations the antimicrobial action of ethanol may be unsatisfactory.

Another alternative was described by Owen and Steedman (1958). They found various zoological specimens, previously fixed by any desirable method, to be well preserved for years in a solution of

1% Propylene Phenoxetol (1-phenoxy-propan-2-ol) alone or in combination with 0.2% "Nipa" esters (a mixture of alkyl esters of 4- hydroxybenzoic acid). This technique was recommended for general use by Spence and Zuckerman (1967), and Steinmann et al. (1975) reported good results on veterinary medical and zoological specimens. Wineski and English (1989) have described a method for long-term preservation of human tissue using Phenoxetol.

In view of the above, an attempt was made in our department to try out a modification of the above-mentioned technique on all human dissection material for medical and para-medical students with an aim to reduce the formaldehyde levels in the dissection hall by substituting formaldehyde with phenoxetol (CID: 31236, CAS: 122-99-6; Ethylene glycol monophenyl ether, 1-hydroxy-2-phenoxyethane or phenoxyethanol or phenyl cellusolve) (Dow, 2007) for preservation.

MATERIALS AND METHODS

This study was carried out at Armed Forces Medical College, India, over a period of six years from 2007 to 2012. Since 2007 a total number of 81 human cadavers have been received by our college for use in medical research and education. The bodies belonged to persons of both sexes, and were aged between 36 and 85 years (mean 72 years). Human cadavers were obtained by the body donation program of the department fulfilling ethical guidelines.

Single-point embalming was done, which was started between 8 and 48 hours post-mortem (mean 18 hours) by the injection of seven liters of fixative in the common carotid or femoral artery using embalming perfusion pump. The fixing fluid used is shown in Table 1.

After the initial vascular injection fixation the cadavers were observed for a few days and supplementary injections of the same fixative made locally wherever the initial injection proved unsatisfactory. The cadavers were then transferred to tanks filled with 4% formaldehyde and stored there for a period ranging between 2 and 4 months (see Table 1).

After this period the cadavers were transferred to tanks filled with 1% Phenoxetol in water, and kept there for a period of at least 3 months before they were used for the purpose of dissection (see Table 1). Phenoxetol in the tanks was renewed at about 3

Table 1. Composition of embalming and tank fluid used in the study. Tank fluid 1 was used for first stage and tank fluid 2 for second stages of preservation of cadavers.

Component of fluid used	Embalming fluid	Tank fluid 1	Tank fluid 2	Manufacturer
40% Formaldehyde	3	100	-	Merck
99% Ethanol	2	-	-	Merck
Glycerine	1	-	-	Johnson & Johnson
Tap water	1	900	990	-
100% Phenoxetol	-	-	10	Clariant
Total	7	1000	1000	-

-month intervals or when the solution was discoloured by exudate from the cadavers. The bodies were thus treated by a minimum of two successive baths of 1% Phenoxetol to remove most of the remaining free aldehydes left by the fixative solutions.

During the dissection schedule the bodies remained on stainless steel tables for the week, covered with sheets soaked in 1% Phenoxetol. During weekends and between dissections of distinct body regions the bodies were re-immersed in 1% Phenoxetol. According to the training curriculum prescribed by the Maharashtra University of Health Sciences (MUHS) and used by us, our medical students complete their dissection schedule over a period of 32 weeks. This is spread out through one year of first MBBS (Bachelor of medicine and bachelor of surgery – 4 ½ year medical undergraduate course). Dissected specimens kept for demonstration purposes were likewise stored in 1% Phenoxetol. Dissected specimens for permanent exhibition in the museum were mounted in Glass/Perspex jars filled with 1% Phenoxetol in water.

Samples of tissue treated as mentioned above and left in 1% Phenoxetol in water for one year were dehydrated by ethanol (Merck®), embedded in paraffin (Merck®), sectioned, and stained by hematoxylin and eosin (Merck®) according to standard procedures.

Eleven tissue samples from different regions of two cadavers subjected to their first dissection were taken by sterile means and submitted to the microbiological laboratory for cultivation of bacteria and fungi by aerobic and anaerobic techniques.

At the end of the dissection course all participating students of five successive years (684 in total) were asked to give their opinion about certain aspects of the working environment in the dissection hall and its influence on their health condition. Questionnaires with specified questions and predetermined reply alternatives, mainly concerning known effects of formaldehyde fumes, were used

for this purpose (Table 2).

Informed written consent was obtained from all the students who participated in the study.

RESULTS

For dissection purposes we found the preservation in 1% Phenoxetol very satisfactory. Much of the rigidity of the tissues caused by the initial aldehyde fixation disappears after some weeks in Phenoxetol and all tissues gain a flexible, partly elastic, consistency not unlike the consistency of fresh unfixed tissue, and well suited for dissection and demonstration purposes, especially for demonstra-

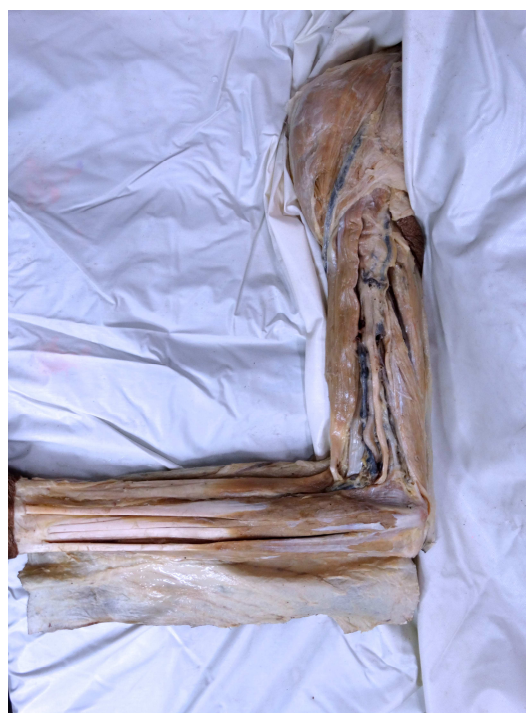

Fig. 1. Dissected specimen of superior extremity of a cadaver preserved in 1% Phenoxetol for more than six months showing the colors of muscle, nerves and vessels.

Table 2. Responses of first year medical students to questionnaire about their experience with dissection where cadavers were preserved using Phenoxetol. 0 = Not at all. Not recognizable; 1 = Faint, barely recognizable; 2 = Medium unpleasant; 3 = Strong, prominent, irritating

No.	Question	Reply Alternatives				Total Replies	Positive Replies as % of Total
		0	1	2	3		
1	Respiratory distress	641	27	5	2	675	5
2	Dry or sore nose	607	52	8	8	675	10
3	Running or congested nose	587	70	15	3	675	13
4	Dry or sore throat	574	84	17	-	675	15
5	Unusual thirst	621	50	1	3	675	8
6	Itching or sore eyes	459	200	16	-	675	32
7	Red eyes (conjunctivitis)	587	80	-	8	675	13
8	Excessive lacrimation	594	75	4	2	675	12
9	Disturbance of sight	648	25	2	-	675	4
10	Disturbed nocturnal sleep	655	20	-	-	675	3
12	Headache	439	184	31	21	675	35
13	Itching or sore skin on hands	648	19	2	6	675	4
14	Skin eruptions on face or neck	622	41	5	7	675	8

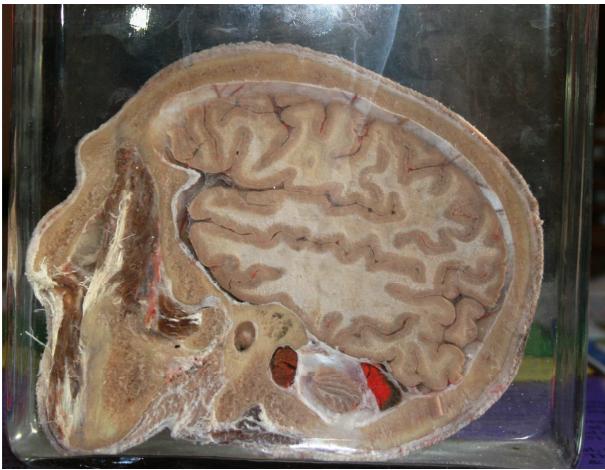


Fig. 2. Museum specimen of head preserved in 1% Phenoxetol for more than one year.

tion of movements across joints. We are of the opinion that 1% Phenoxetol enhances lifelike tissue colors (Fig. 1) rather than disturbing them. Detachment of epidermal layer of skin in some areas was noted, as is common with other methods of preservation.

These colors are stable for years although we have noted a slight fading in some of our museum exhibition samples subject to much daylight (Fig. 2). The tissue samples processed for routine histology after one year in 1% Phenoxetol revealed tissue preservation fully comparable to that of tissue stored in more traditional ways (Fig. 3).

We saw no sign of microbial activity in any of our histological sections and bacteria or fungi could not be grown from 11 samples given for testing to laboratory. However, in about 1 out of 10 cadavers we found minor fungal attacks on body parts lying above the level of Phenoxetol solution in our tanks, or on cadavers left on the dissection table for several weeks and moistened by towels soaked in water only. Such attacks were easily arrested by local application of concentrated Lysoformin solution or re-immersion in 1% Phenoxetol, and have never been seen on our samples after we moistened towels in 1% Phenoxetol rather than in water.

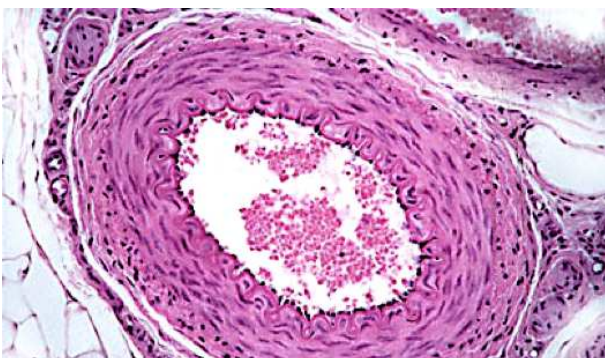


Fig. 3. Hematoxylin and Eosin stained muscular artery prepared from tissue preserved in 1% Phenoxetol.

The unpleasant and irritating formaldehyde and phenol smell present traditionally is markedly reduced in our dissection hall.

In our questionnaire (circulated to 684 students, with replies received from 675) headache, sore throat and eye irritation were mentioned by slightly more students than the remaining symptoms (Table 2). Since we no longer use formaldehyde as a preservative, comparison of data with formaldehyde could not be made but our subjective experience is these symptoms were much more common with formaldehyde.

DISCUSSION

Phenoxetol is an oily liquid with a density of about 1.1 g/ml and freezing point near 14°C. It has a faint aromatic (rose like) odor and is slightly soluble in water (2.67 g/100 ml) (Stecher 1968). When used in a watery solution, it has fairly good antiseptic properties. It was tried early in local treatment of burns and wounds, especially against *Pseudomonas aeruginosa* or *Pyocyanea* infections, because it proved to show little skin or tissue irritation on local application as a solution or ointment, as well as low toxicity when injected subcutaneously, intra-peritoneal, or intravenously in various laboratory animals (Gough et al., 1944). Based on these properties, phenoxyethanol alone or in combination with other bactericides (e.g., quaternary ammonium compounds) has practical medical applications such as in topical antiseptic solutions and creams. In addition, it is used as a fixative for cosmetics and as insect repellent (Stecher, 1968).

Phenoxetol is chemically related to propylene phenoxyethanol, which was used, by Owen and Steedman (1958), as a preservative for zoological specimens. Both substances have much the same antibacterial activity. However, whereas propylene phenoxyethanol acts more strongly against moulds and yeast accordingly, propylene phenoxyethanol should in principle be preferred for preservation purposes. However, this substance is more expensive than Phenoxetol and our experience indicates that Phenoxetol gives fully satisfactory results. Also, when compared with more conventional preservative techniques (Burke and Sheffner, 1976), our method seemed satisfactory from a microbiological point of view.

In fact, from the point of view of preservation, we see no major drawbacks to the use of Phenoxetol for long-term storage of human bodies for dissection purposes. The results of this study are in agreement with those reported by Owen and Steedman (1958) on zoological samples, by Steinmann et al. (1975) on veterinary and zoological samples, and by Wineski and English (1989) on human cadavers. It should, however, be stressed that Phenoxetol or propylene phenoxyethanol cannot be used for initial fixation purposes. It has no

ability to arrest autolysis, and unless other proper fixatives are used, the tissues will decompose rapidly.

From an anatomical point of view, Phenoxetol gives superior results to those of most other preservatives. The colour retention is good (Sehdev et al., 1963) and the tissue consistency softer and more flexible than that achieved by ethanol preservation. Since no mineral salts are used in the preservative fluid, other embalming methods using such salts will definitely be superior in terms of colour retention (Thiel, 1992; Eisma et al., 2013). However, this method is more convenient to perform, as a single arterial route is used for perfusion and the composition of embalming fluid used less complicated compared to other methods that are described in the literature (Eisma et al., 2013).

The most important advantage of Phenoxetol preservation still seems to be its low toxicity, as mentioned above. Skin contact which should be avoided using the phenyl-mercury compound seems to present no problem with phenoxetol (Breslin et al., 1991). On the contrary, Phenoxetol is recommended as an antiseptic ingredient in medical creams and ointments (Stecher, 1968).

According to the opinions expressed by our students, the preservative fluid we use causes little skin irritation. This is, however, a prominent and well-known effect of formaldehyde and phenol. Smell and mucosal irritation may be suspected at formaldehyde concentrations as low as 0.15 ppm (Bourne and Seferian, 1959). This explains some features of mucosal irritation (see Table 2) experienced by our students. It is also important to note here that our institute has a spacious and well-ventilated dissection hall conforming to the standards prescribed by Medical Council of India and five students dissect on each side of cadaver (MCI 1999). Despite its widespread use for many years, contact allergy to Phenoxetol has been very rarely described (Brenner, 2014). Erythema and scaling that occurred on intradermal injection of phenoxetol in rabbits were not associated with gross or histopathologic changes and were not considered toxicologically significant (Breslin et al., 1991).

In a very recent review article (Brenner, 2014), Phenoxetol has been described as relatively inexpensive, non-flammable, slow to evaporate, effectively antimicrobial and an excellent tissue preservative and softener. Though it is merely a preservative, not a fixative, it appears to be an effective bactericide at a 1% concentration. It has a broad spectrum of antimicrobial activity and is particularly effective against strains of *P. aeruginosa*.

Our objective to replace formaldehyde as long term preservative with a less toxic alternative was thus achieved. It must be stressed however that any of such alternatives will have its adverse effects too. Some animal experiments have shown that oral or parenteral administration of 0.5 to 2%

phenoxetol can cause liver and reproductive toxicity in Swiss CD-1 mice (Heindel et al., 1990) and hemolysis in rabbits (Breslin et al., 1991). However, phenoxetol being a high boiling liquid with a low vapor pressure, exposure to vapors to a concentration sufficient to cause such effects is unlikely at room temperature (OECD-SIDS 2005). A case of an immediate hypersensitivity reaction has been reported (Bohn and Bircher, 2001).

Limitations of the present study are unavailability of control group, which could not be produced because of the obvious ethical concerns. Thus far, our efforts to improve the working conditions in the dissection hall will benefit mainly the students and teachers rather than the staff in charge of the embalming procedure itself. The prolonged exposure of the latter group to formaldehyde fumes in the embalming room seems equally important to consider. We believe that a reduced exposure of this group to formaldehyde vapors must be sought via the reduction or replacement of formaldehyde as primary fixative and improved ventilation at critical places within the embalming room. Towards addressing this issue the Thiel method (Thiel, 1992; Thiel, 2002) of embalming or its modification (Eisma et al., 2013) can be tried and evaluated subsequently.

Conclusion: In our experience in the last six years Phenoxetol proves to be a viable replacement of formaldehyde for long-term preservation of cadavers, human tissue and museum specimens. It is also suitable for the purpose of preserving tissue, which are to be subsequently processed for histological purposes. In addition to avoiding the well-known hazardous effects of formaldehyde, the use of Phenoxetol also prevents the pungent smell and other local and systemic manifestations of its toxicity. No major changes need to be made in the infrastructure of the department in the transition between two preservatives. Initial fixation however needs to be done with formaldehyde until a practical and economically sound alternative can be found.

ACKNOWLEDGEMENTS

To all those who donated their bodies to our department without whom this study would have never been possible.

REFERENCES

- AKBAR-KHANZADEH F, VAQUERANO MU, AKBAR-KHANZADEH M, BISESI MS (1994) Formaldehyde exposure, acute pulmonary response, and exposure control options in a gross anatomy laboratory. *Amer J Indust Med*, 26: 61-75.
- ALBERT RE, SELLA Kumar AR, LASKIN S, KUSCHNER M, NELSON N, SNYDER CA (1982) Gaseous formaldehyde and hydrogen chloride induction of nasal cancer in the rat. *J Natl Cancer Inst*, 68:

- 597-603.
- BJORKMAN N, CHRISTENSEN KM (1982) Extraction of dilute ethanol of formaldehyde-fixed dissecting specimens. *Acta Anat*, 112: 1-8.
- BOHN S, BIRCHER AJ (2001) Phenoxyethanol-induced urticaria. *Allergy*, 56: 922-923.
- BOURNE HG JR, SEFERIAN S (1959) Formaldehyde in wrinkle-proof apparel produces tears for milady. *Indust Med Surg*, 28: 232-233.
- BRENNER E (2014) Human body preservation - old and new techniques. *J Anat*, 224: 316-344.
- BRESLIN WJ, PHILLIPS JE, LOMAX LG, BARTELS MJ, DITTENBER DA, CALHOUN LL, MILLER RR (1991) Hemolytic activity of ethylene glycol phenyl ether (EGPE) in rabbits. *Fundam Appl Toxicol*, 17: 466-481.
- BURKE PA, SHEFFNER AL (1976) The antimicrobial activity of embalming chemicals and topical disinfectants on the microbial flora of human remains. *Health Lab Sci*, 13: 267-270.
- CHIA SE, ONG CN, FOO SC, LEE HP (1992) Medical students' exposure to formaldehyde in a gross anatomy dissection laboratory. *J Amer College Health*, 41: 115-119.
- DOW Product Safety Assessment ethylene glycol phenyl ether (2007) Accessed on 07 feb 2014. Available at: http://msdssearch.dow.com/PublishedLiteratureDOWCOM/dh_00d2/0901b803800d29f2.pdf?filepath=productsafety/pdfs/noreg/233-00323.pdf and from Page=GetDoc
- EISMA R, LAMB C, SOAMES RW (2013) From formalin to Thiel embalming: What changes? One anatomy department's experiences. *Clin Anat*, 26: 564-571.
- FRØLICH KW, ANDERSEN LM, KNUTSEN A, FLOOD PR (1984) Phenoxyethanol as a nontoxic substitute for formaldehyde in long-term preservation of human anatomical specimens for dissection and demonstration purposes. *Anat Rec*, 208: 271-278.
- GOUGH J, BERRY H, STILL B (1944) Phenoxetol in the treatment of pyocyanea infections. *The Lancet*, 244: 176-178.
- HAUPTMANN M, LUBIN JH, STEWART PA, HAYES RB, BLAIR A (2003) Mortality from lymphohematopoietic malignancies among workers in formaldehyde industries. *J Natl Cancer Inst*, 95: 1615-1623.
- HEINDEL JJ, GULATI DK, RUSSELL VS, REEL JR, LAWTON AD, LAMB IV JC (1990) Assessment of ethylene glycol monobutyl and monophenyl ether reproductive toxicity using a continuous breeding protocol in Swiss CD-1 mice. *Fundam Appl Toxicol*, 15: 683-696.
- MCI (1999) *Minimum Standard Requirement for The Medical College for 150 Admissions Annually Regulations*. Available at: http://www.mciindia.org/helpdesk/how_to_start/Standard_for_150.pdf. Accessed 05/11/2014.
- NISHIOKA H (1973) Lethal and mutagenic action of formaldehyde in Hcr+ and Hcr,Δ strains of Escherichia coli. *Mutation Res/Fundam Mol Mech Mutagenesis*, 17: 261-265.
- SIDS Initial Assessment Report Ethylene Glycol Phenyl Ether (2005) Accessed on 6 feb 2014. Available at: <http://www.chem.unep.ch/irptc/sids/OECD/SIDS/122996.pdf>
- OWEN G, STEEDMAN H (1958) Preservation of molluscs. *J Molluscan Studies*, 33: 101-103.
- RAGAN DL, BOREIKO CJ (1981) Initiation of C3H/10T1/2 cell transformation by formaldehyde. *Cancer Lett*, 13: 325-331.
- ROSS WE, SHIPLEY N (1980) Relationship between DNA damage and survival in formaldehyde-treated mouse cells. *Mutat Res*, 79: 277-283.
- TWELTH Report on Carcinogens (RoC) (2011) Available at: <http://ntp.niehs.nih.gov/ntp/roc/twelfth/roc12.pdf>
- SEHDEV H, MCBRIDE J, FAGERLUND U (1963) 2-Phenoxyethanol as a general anaesthetic for sockeye salmon. *J Fisheries Board Canada*, 20: 1435-1440.
- SLIZYNSKA H (1957) Cytological analysis of formaldehyde induced chromosomal changes in Drosophila melanogaster. *Proceed Royal Soc Edinburgh, Section B, Biology*, 66: 288-304.
- SPENCE TF, ZUCKERMAN S (1967) Teaching and display techniques in anatomy and zoology. Pergamon Press.
- STECHEER PG (1968) In: The Merck Index: an encyclopedia of chemicals and drugs. Merck and Co, Rahway, NJ.
- STEINMANN W, EBELING R, GOEPEL U (1975) The preservation of medical and zoological preparations in Phenoxetol. *Der Präparator (Bochum)*, 21: 8-11.
- THIEL W (1992) The preservation of the whole corpse with natural color [Article in German: Die Konservierung ganzer Leichen in natürlichen Farben]. *Ann Anat*, 174: 185-195.
- THIEL W (2002) Supplement to the conservation of an entire cadaver according to W. Thiel. *Ann Anat*, 184: 267.
- WATANABE F, MATSUNAGA T, SOEJIMA T, IWATA Y (1954) Study on the carcinogenicity of aldehyde. I. Experimentally produced rat sarcomas by repeated injections of aqueous solution of formaldehyde. *Japan J Cancer Res*, 45: 451-452.
- WINESKI LE, ENGLISH AW (1989) Phenoxyethanol as a nontoxic preservative in the dissection laboratory. *Cells Tissues Organs*, 136: 155-158.