

Variant termination of the left coronary artery: pentafurcation is not uncommon

Julius A. Ogeng'o, Musa K. Misiani*, Beda O. Olabu, Bethleen M. Waisiko and Acleus Murunga

Department of Human Anatomy, University of Nairobi, Nairobi, Kenya

SUMMARY

Variant termination of the left coronary artery is important in interpreting effects of its occlusion, and in guiding cardiac surgery and intervention procedures. It also constitutes a geometric risk factor for atherosclerosis. These features show ethnic variations, but data from African populations are scarce. This study therefore aimed at describing the variant patterns of termination of the left coronary artery in an indigenous Kenyan population. Left coronary arteries of 208 formalin-fixed hearts were studied by dissection at the Department of Human Anatomy, University of Nairobi. The number of terminal branches was recorded. Images of representative patterns were taken using a high resolution camera. Frequencies were calculated. Results are presented using tables and macrographs. Single left coronary arteries from the left aortic sinus were present in all the 208 hearts studied. The most frequent termination pattern was bifurcation (54.8%), followed by trifurcation (32.2%), quadrifurcation (9.6%) and pentafurcation (3.4%). Over 45% of left coronary arteries have variant patterns of termination. Pentafurcation is not uncommon. This calls for extra caution during interventional coronary artery angiography, instrumentation and surgery. Preoperative angiographic evaluation is recommended.

Key words: Left coronary artery – Trifurcation – Quadrifurcation – Pentafurcation – African

* **Corresponding author:** Musa K. Misiani. Department of Human Anatomy, University of Nairobi, P.O. Box 30197-00100, Nairobi, Kenya. E-mail: musa.misiani@gmail.com

INTRODUCTION

The left coronary artery (LCA) usually divides into left anterior descending (LAD) and left circumflex (LCx) arteries (Reig, 2003; Moore and Dally, 2006; Tuccar and Elhan, 2002).

This artery displays wide variability in number of terminal branches (Ballesteros and Ramirez, 2008). Knowledge of branching pattern of LCA is important in determining complexity and effects of arterial occlusive disease, in haemodynamics, procedures of handling cardiac trauma, their implication in heart surgery, proper interpretation of coronary angiography, surgical myocardial revascularization, and interventional cardiac procedures (Lujinovic et al., 2005; Ballesteros and Ramirez, 2008; Moore et al., 2010; Dombe et al., 2012). The frequency of these variations displays population differences (Baptista et al., 1991). As the incidence of coronary heart disease increases among African populations (Mbewu and Mbanya, 2006; Mensah, 2008; Mbewu, 2009), a commensurate rise in the frequency of cardiac procedures is expected. Accordingly, knowledge of the branching pattern of the LCA is important to minimize misinterpretation of coronary angiograms and inadvertent vascular injury. Data on the anatomy of the LCA is, however, generally scarce. This study therefore aimed at describing the anatomical features of the artery in a black Kenyan population.

MATERIALS AND METHODS

Two hundred and eight hearts were dissected at the Department of Human Anatomy, University of

Submitted: 20 August, 2013. *Accepted:* 14 November, 2013.

Nairobi, Kenya. The pericardium was removed and ascending aorta exposed by retracting the pulmonary trunk and veins. The left auricle was also retracted to the left and the LCA, originating from the left aortic sinus identified. The artery was cleared of fat and followed to its terminal division. The number of terminal branches was recorded. These branches were identified as the LAD, intermediate/median and LCx. Photographs of representative patterns were taken with a high-resolution digital camera. The results have been analyzed for frequencies and means, and are presented in frequency tables and macrographs.

RESULTS

Branching Pattern

The most common branching pattern was bifurcation (Fig. 1A), followed by trifurcation (Fig. 1B), quadrifurcation (Fig. 1C) and pentafurcation (Fig. 1D). There were no cases of absent common trunk observed.

DISCUSSION

Majority (54.5%) of LCA terminated as bifurcation. This is within the range of 41-69.3% reported in various populations. Trifurcation frequency of

Table 1. Branching pattern of the left coronary artery

Branching pattern	Frequency	(%)
Bifurcation	114	(54.8)
Trifurcation	67	(32.2)
Quadrifurcation	20	(9.6)
Pentafurcation	07	(3.4)
Total	208	(100)

31.8% is within the 9-47.5% reported in literature (Reig, 2003; Kosar et al., 2009; Candir et al., 2009; Surucu et al., 2004). The quadrifurcation frequency of 9.1% is also within the range of 5-11% reported in literature (Reig and Petit, 2004; Kalpana, 2003) (Table 2).

A notable observation of the present study is the comparatively high frequency of pentafurcation. A few other studies reported only a single case of pentafurcation (Kalpana, 2003; Surucu et al., 2004; Bhimalli et al., 2011). Observations of the current study reveal frequency of 3.4% (N = 7). These variant patterns of termination may arise from disturbances in usual regression of vascular sprouts from the network of vessels in the inter-ventricular and atrioventricular grooves during early development (Ogden, 1968; Larsen 1993; Kulkarni and Mehta, 2012). Recognition of these variant branching patterns is important because they may cause technical difficulties during coronary catheterization and stenting; and it may be a source of complications or misdiagnosis (Earls, 2006; Zimet and Miller, 2006; Mountandon et al., 2007). The additional arteries are functionally important because of their potential to supply a significant territory of the myocardium. In such cases, they constitute an important source of collateral circulation in case of occlusion of LAD or LCX (Reig, 2003). Occlusion of these arteries in atherosclerosis such as in trifurcation disease (Shammas, 2007) may be as dangerous as that of the other two (Levin, 1983; Roberts et al., 1986). The high frequency of additional arteries implies that catheterization of LCA is more complicated and since their presence alters the angle of bifurcation (Furuichi et al., 2007, Rubinshtein et al.,

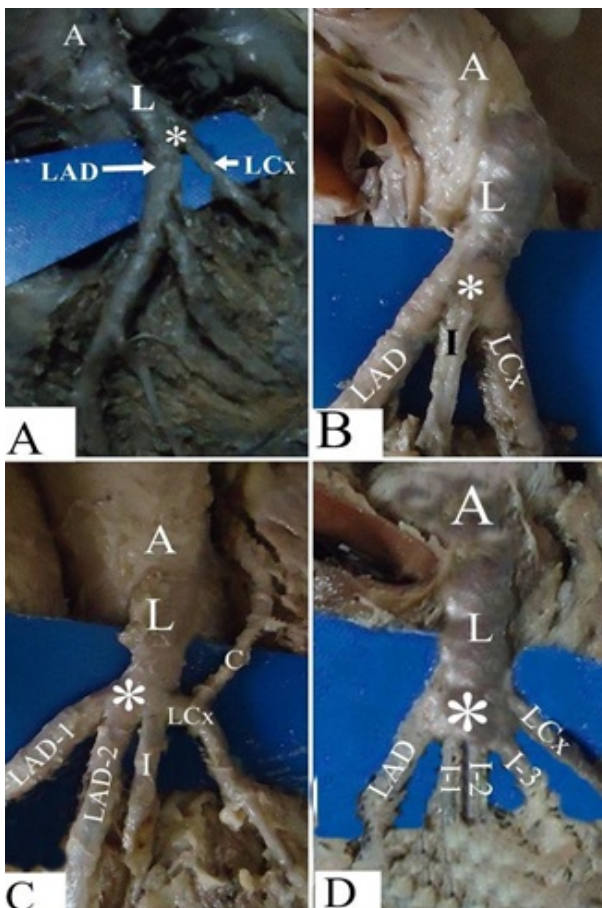


Fig. 1. Branching pattern of the left coronary artery among black Kenyans. **(A)** Bifurcation (*) of the left coronary artery (L). Note its origin from the aorta (A) and its subsequent division into the anterior interventricular (LAD) and the circumflex artery (LCx). **(B)** Trifurcation (*) of the left coronary artery (L) into LAD, Intermediate (I) and LCx. Note its origin from the aorta (A). **(C)** Quadrifurcation (*) of the left coronary artery (L) into double left anterior descending artery (LAD1 and LAD2) intermediate (I) and left circumflex (LCx). Note that the LCx gives rise to large left conal branch (C). Note its origin from the aorta (A). **(D)** Pentafurcation (*) of the left coronary artery (L) into LAD, three intermediate branches I-1, I-2, I-3, and LCx. Note its origin from the aorta (A).

Table 2. Terminal branching patterns of the LCA in various populations

Study	Population	Pattern of Termination (%)			
		Bifurcation	Trifurcation	Quadrifurcation	Pentafurcation
Kalbfeisch and Hort, 1976	German	41	53	6	-
Leguerrier et al., 1976	French	65-70	20-30	5-10	-
Lo et al., 1994	French	69.35	36.6	-	-
Kalpana, 2003	Indian	47	40	11	1
Reig and Petit, 2004	Spanish	64	31	05	-
Ballesteros and Ramirez, 2008	Colombian	52	42.2	5.8	-
Fazliogullari et al., 2010	Turkish	46	44	10	-
Dombe et al., 2012	Indian	54.7	35.9	7.8	-
Baptista, 1991		54.7	38.7	6.7	-
Bhimalli et al., 2011	Indian	56.7	33.3	8.3	1
Udhayakumar and Yasawardene, 2012	Srilankan	75	22.5	2.5	-
Surucu et al., 2004	Turkish	47.5	47.5	2.5	2.5
Cavalcanti et al., 1995	Portuguese	60	38.2	1.8	-
Agnihotri et al., 2013	Indian	66	30	4.0	-
Current study	Kenyan	54.8	32.2	9.6	3.4

2012) they increase vulnerability to atherosclerosis.

CONCLUSION

These figures indicate wide population variations in the frequency of various branching patterns which must be taken into account during cardiac catheterization for coronary angiography and stent placement. Further, they may constitute part of the explanation for the variation in occurrence of atherosclerosis. Over 45% of left coronary arteries have variant pattern of termination. Pentafurcation is not uncommon. This calls for extra caution during interventional coronary artery angiography, instrumentation and surgery. Preoperative angiographic evaluation is recommended.

ACKNOWLEDGEMENTS

We wish to thank Jacob Gimongo, Martin Inyimili and Peter Nzioka for technical support and Antonina Odock – Opiko for typing the manuscript.

REFERENCES

- AGNIHOTRI G, KAUR M, KALYAN GS (2013) Branching pattern of left coronary artery among North Indians. *Anat J Afr*, 2: 145-150.
- BALLESTEROS LE, RAMIREZ LM (2008) Morphological expression of the left coronary artery: a direct anatomical study. *Folia Morphol*, 67: 135-142.
- BAPTISTA CA, DIDIO LJ, PRATES JC (1991) Types of division of the left coronary artery and ramus diagonalis of the human heart. *Jpn Heart J*, 32: 323-335.
- BHIMALLI S, DIXIT D, SIDDIBHAVI M, SHIROL VS (2011) A study of variations in coronary arterial system in cadaveric human heart. *World J Sci Tech*, 1: 30-35.
- CAVALCANTI JS, DE LUCENA AM, PAIS MAV, BALABAN G, ANDRADE OCL, DE LUCENA OE (1995) Anatomic variations of the coronary arteries. *Arq Bras Cardiol*, 65: 489-492.
- CHRISTENSEN KN, HARRIS SR, FROEMING AT, BRINJIKJI W, ARAOZ P, ASITVATHAN SJ, LACHMAN N (2010) Anatomic assessment of the bifurcation of the left main coronary artery using multidetector computed tomography. *Surg Radiol Anat*, 32: 903-909.
- DAS HIRAK (2005) Termination of left coronary in the population of Assam. *Nat J Basic Med Sci*, 1: 145-148.
- DOMBE DD, ANITHA T, GIRI PA, DOMBE SD, AMBIYE MV (2012) Clinically relevant morphometric analysis of the left coronary artery. *Int J Biol Med Res*, 3: 1327-1330.
- DVIR D, MAROM H, ASSALI A (2007) Bifurcation lesions in coronary arteries: early experience with a novel 3-D imaging and quantitative analysis before and after stenting. *Eur Intervention*, 3: 95-99.
- EARLS JP (2006) Coronary artery anomalies. *Tech Vasc Interv Radiol*, 9: 210-217.
- FAZLIOGULLARI Z, KARABULUT AK, UNVER DOGAN N, UYSAL II (2010) Coronary artery variations and median artery in Turkish cadaver hearts. *Singapore Med J*, 51: 775-780.
- FURUICHI S, SANGIORGI GM, PALOSHI, A, GODINO C, AIRLOLDI, MONTOFARNO M, CHIEFLO A, MICHEV I, CARLINO M, COLOMBO A (2007) Drug-eluting stent implantation in coronary trifurcation lesions. *J Invasive Cardiol*, 19: 157-162.
- KALPANA R (2003) A study of principal branches of coronary arteries in humans. *J Anat Soc India*, 52: 137-140.
- KOSAR P, ERGUN E, OZTURK C, KOSAR U (2009) Anatomic variations and anomalies of the coronary arteries: 64-slice CT angiographic appearance. *Diagn Interv Radiol*, 15: 275-283.

- KULKARNI JP, MEHTA L (2012) Study of angiographic anatomy of right coronary artery. *IOSR JDMS*, 2: 39-41.
- LARSEN WJ (1983) Development of Vasculature. In: *Larsen Human Embryology*. Churchill Livingstone, New York, Edinburgh. Chapter 7, pp 191.
- LEVIN DC (1983) Anomalies and anatomic variations of coronary arteries. In: Abrahams HL (Ed). *Coronary arteriography. A practical approach*. Little Brown Co. Boston, pp 283-299.
- LO EA, DIA A, NDIAYE A, SOW ML (1994) Anatomy of coronary arteries. *J Dakar Med*, 39: 23-29.
- MENSAH GA (2008) Ischaemic heart disease in Africa. *Heart*, 94: 836-843.
- MOUNTANDON M, LATRABE V, IRIART X, CAIX P, LAURENT F (2007) Congenital coronary arteries anomalies: review of the literature and multidetector computed tomography (MDCT) – appearance. *Surg Radiol Anat*, 29: 343-355.
- OGDEN J (1968) The origin of coronary arteries. *Circulation*, 38 (suppl 6): 150.
- REIG J (2003) Anatomical variations of the coronary arteries. I. The most frequent variations. *Eur J Anat*, 7 suppl 1: 29-41.
- REIG J, PETIT M (2004) Main trunk of the left coronary artery: anatomic study of the parameters of clinical interest. *Clin Anat*, 17: 6-13.
- ROBERTS WC, SILVA MA, SAPALA JC (1986) Intussusception of a coronary associated with sudden death in a college football player. *Am J Cardiol*, 57: 179-180.
- SHAMMAS NW (2007) Trifurcating coronary artery disease: A proposed classification and treatment methodology. *J Invasive Cardiol*, 19: 32-35.
- SURUCU HS, KARAJAN ST, TANYELI E (2004) Branching pattern of the left coronary artery and an important branch. The median artery. *Saudi Med J*, 25: 177-181.
- TUCCAR E, ELHAN A (2002) Examination of coronary artery anomalies in an adult Turkish population. *Turk J Med Sci*, 32: 309-312.
- UDHAYAKUMAR S, YASAWARDENE SG (2012) A preliminary study on Anatomy of the main trunk of left coronary artery of SriLankans. *Proc Jaffna Univ Int Res Conf*, pp 108.
- VATHSALA V, JOHNSON WMS, DURGA DY, PRABHU K, ARCHANA R (2011) Multiple variations of coronary arteries - An anatomic study: A case report. *JCDR*, 5 (suppl-2): 1454-1457.
- ZIMMET JM, MILLER JM (2006) Coronary artery CTA: Imaging of atherosclerosis in the coronary arteries and reporting of coronary artery CTA findings. *Tech Vasc Interv Radiol*, 9: 218-226.