

# Retro-oesophageal right subclavian artery associated with a non-recurrent laryngeal nerve - case report

Chinnawut Suriyonplengsaeng and Krai Meemon

Department of Anatomy, Faculty of Science, Mahidol University, Bangkok, Thailand

## SUMMARY

A retro-oesophageal right subclavian artery (RRSA) was detected in an 81-year-old Thai male cadaver. It originated from the proximal thoracic aorta and ascended posterior to the oesophagus continuing as the axillary artery beyond the level of the right first rib. Abnormal vascular branches and a right non-recurrent inferior laryngeal nerve were associated with the RRSA. Moreover, the ansa subclavia was prominently discernible to enclose the RRSA. The embryonic development and associated anatomical variations of the RRSA are discussed.

**Key words:** Retro-oesophageal right subclavian artery – Aortic arch variation – Arteria lusoria – Brachiocephalic trunk – Right non-recurrent inferior laryngeal nerve – Ansa subclavia

## INTRODUCTION

A variation of the right subclavian artery is the most common type of aortic arch variation, having an incidence of 0.5 to 2.5 % (Almenar-García et al., 2002). It is usually a retro-oesophageal structure which can cause compression of the oesophagus or trachea, leading to difficulty in swallowing solid food and dyspnea, or chronic cough in some patients. More rarely, this variation can depict a pretracheal course and even more seldom, a tract between the tra-

chea and oesophagus. The retro-oesophageal course, called a retro-oesophageal right subclavian artery (RRSA), is the most common disposition of this variation. Because of the first case report of a variation of the right subclavian artery being called arteria lusoria by Hanault in 1735, dysphagia caused by this variation was later termed dysphagia lusoria (Bayford, 1794). Since then, further patient and autopsied cadaver cases with this variation had been reported (Loukas et al., 2004; Triantopoulou et al., 2005). The right inferior laryngeal nerve travelled in a non-recurrent fashion, which is constantly present in the case with RRSA because of a common embryologic origin, is prone to be inadvertently injured during thyroidectomy (Hermans et al., 2003). Moreover, this nerve could be confused with other potential structures, i.e. communicating branch between the sympathetic trunk and the inferior laryngeal nerve (Maranillo et al., 2008). Aneurysmal dilatation at the origin of the RRSA, known as the Kommerell's diverticulum, can also be detected (Nakatani et al., 1996; van Son et al., 2002).

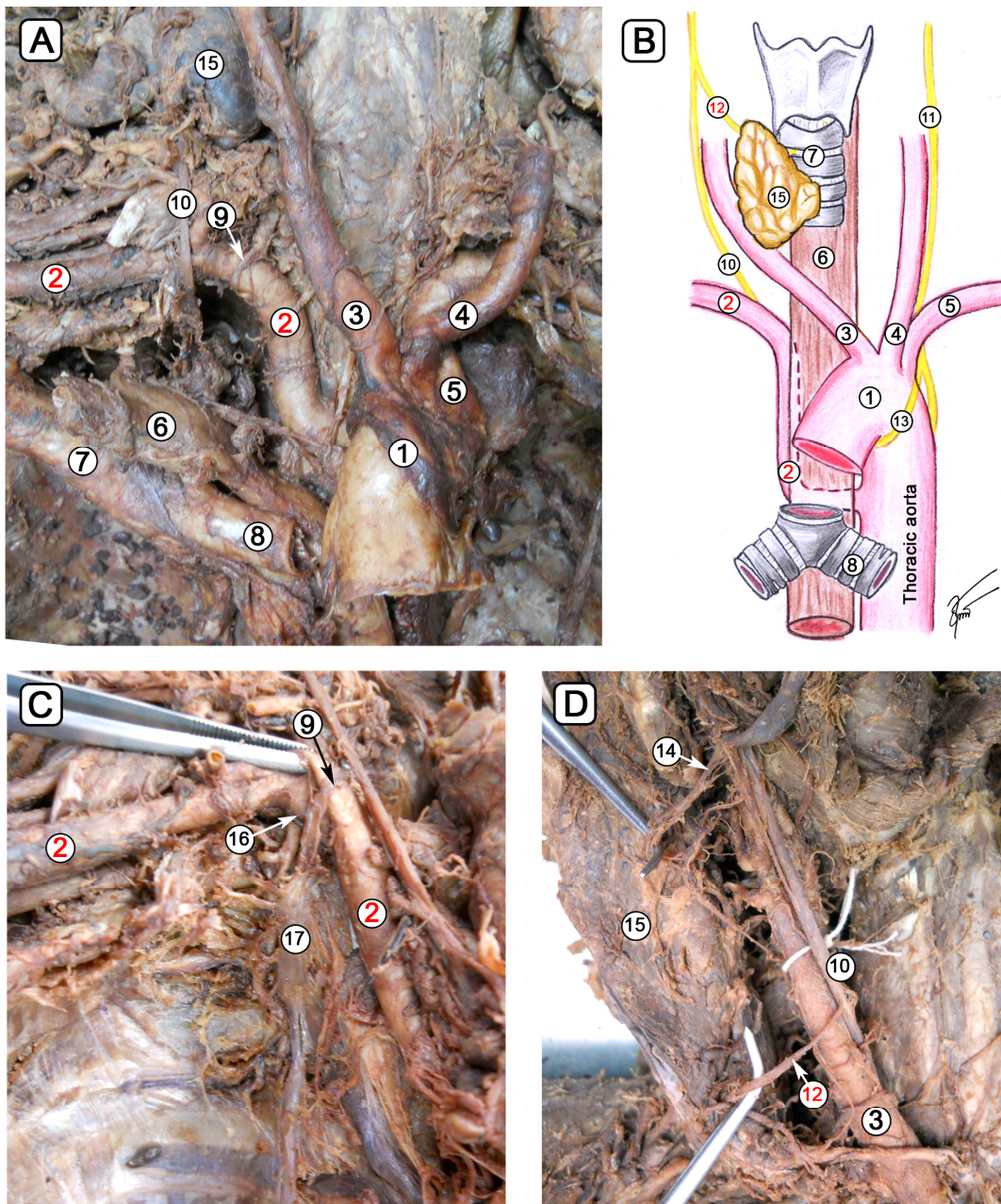
In this study, we reported the anatomical details of the RRSA found in a Thai cadaver and its relationship with surrounding structures including the inferior laryngeal nerve. Associated variations were detected and thus they are important and beneficial for physicians and surgeons when treating patients with this abnormality.

## CASE REPORT

During gross anatomy dissection course in 2012, the RRSA was observed in an 81-year-

**Corresponding author:** Krai Meemon. Department of Anatomy, Faculty of Science, Mahidol University, Rama VI Rd., Bangkok 10400, Thailand. Tel: +662-201-5417. E-mail: krai.mee@mahidol.ac.th

Submitted: 10 March, 2013. Accepted: 20 June, 2013.



1 = aortic arch ; 2 = retro-oesophageal right subclavian artery; 3 = right common carotid artery; 4 = left common carotid artery; 5 = left subclavian artery; 6 = esophagus; 7 = trachea; 8 = left main bronchus; 9 = ansa subclavia; 10 = right vagus nerve; 11 = left vagus nerve; 12 = right non-recurrent inferior laryngeal nerve; 13 = left recurrent laryngeal nerve; 14 = right superior laryngeal nerve; 15 = thyroid gland; 16 = right superior intercostal artery; 17 = right stellate ganglion

**Fig. 1.** (A) Anterior view of the aortic arch with right-laterally-reflected trachea and oesophagus showing the retro-oesophageal right subclavian artery (RRSA) originating from the thoracic aorta. (B) Orientation drawing of the RRSA (2) and the right non-recurrent inferior laryngeal nerve (NRILN) (12). (C) Anterior view of the thoracic cavity showing the right superior intercostal artery (16) and its first four posterior intercostal arteries, and the discernible right ansa subclavia (9). (D) At the cervical region, the right vagus nerve gives off the superior laryngeal nerve (14) and NRILN (12).

old Thai male cadaver who died from coronary artery disease. It was found to originate from the proximal descending thoracic aorta at a level of the fourth thoracic vertebra, and then ascended posterior to the oesophagus to its normal position above the superior surface of the right first rib (Fig. 1A-B). There was no evidence of the Kommerell's diverticulum at the origin of the RRSA. The brachiocephalic trunk was absent. The total length of this RRSA from its origin to the lower border of the first rib was approximately 22.8 cm long. The distance between the origins of the left subclavian artery and the RRSA was approximately 1.7 cm. The circumference of this RRSA at its origin was approximately 4 cm, whereas its diameter was approximately 1.2 cm. The branches of the RRSA, including the vertebral artery, internal thoracic artery, and thyrocervical trunk, presented no variation. The superior intercostal artery, however, originated directly from the RRSA medial to the first rib and gave rise to the first four posterior intercostal arteries (Fig. 1C). Moreover, the right inferior laryngeal nerve did not form a loop with the RRSA and was found at posterior surface of the right lobe of thyroid gland where it pierced the membrane between the cricoid and the first tracheal cartilages (Fig. 1D). It was therefore termed as the right non-recurrent inferior laryngeal nerve (NRILN). The distance between the right NRILN and the right superior laryngeal nerve was approximately 5.7 cm long. In addition, the ansa subclavia was found distinctly between the middle cervical and cervicothoracic ganglia to enclose the RRSA. The thoracic duct was located posterior to the RRSA. Any variant of left-sided structures including subclavian artery, recurrent laryngeal nerve, and cervical sympathetic ganglions was not identified.

## DISCUSSION

The subclavian artery is a major artery supplying the brain stem, the lower neck, the upper thorax and the upper limb. Embryologically, the left subclavian artery arises from the left 7th intersegmental artery, whereas the right subclavian artery arises from the right 4th aortic arch, the right dorsal aorta, and the right 7th intersegmental artery. A RRSA is thought to develop as a result of abnormal regression of the right 4th aortic arch. The right 7th intersegmental artery thereby forms a connection with the descending aorta via the persistent right dorsal aorta. A normal involution of the distal portion of the right 6th aortic arch and an abnormal regression of the right 4th aortic arch result in the right inferior laryngeal nerve

not forming a loop around the right subclavian artery (Almenar-García et al., 2002).

Although the right superior intercostal artery is usually a branch of costocervical trunk, in this case it originated directly from the first part of the RRSA providing the first four right posterior intercostal arteries. This was a new finding which has not been demonstrated before in the case with RRSA. Variation of the 3rd and 4th posterior intercostal arteries connecting the right superior intercostal artery was proposed to result from the loss of the intersegmental connections to the aorta of the right 3rd and 4th thoracic intersegmental arteries and longitudinal anastomosis between the first four right thoracic intersegmental arteries.

The route of right NRILN in the patient with RRSA is important for clinicians during surgical and angiographic settings. It is necessary to identify it clearly before performing thyroid, parathyroid or any neck surgery for prevention of nerve injury due to its unusual route in a non-recurrent situation. It has been proposed that an algorithmic guideline is used to screen patients with right NRILN by using preoperative CT of the neck (Wang et al., 2011). As a result, nine cases of right NRILN have been identified prior to thyroid surgery, and six of them were new cases of asymptomatic RRSA. This evidence was supported by a previous study that right NRILN was present in conjunction with RRSA (Avisse et al., 1998).

Therefore, preoperative CT identifying the presence of RRSA would be strongly recommended, and the surgical procedure should be performed carefully, as the preexisting NRILN is prone to be damaged during the surgery of thyroid or parathyroid glands. The surgical incidence of the right NRILN was 0.21% (Hermans et al., 2003). Nevertheless, left-sided NRILN, only occurring in the presence of situs inversus totalis combined with variation of the left subclavian artery, was rarely reported (0.04 %) (Henry et al., 1988).

An ansa subclavia had been reported to enclose the RRSA which emerged immediately distal to the left subclavian artery (Nakatani et al., 1996). Although the route of the RRSA from their study was different from our finding, these data suggested that the ansa subclavia enclosed the arterial segment which was originated from the 7th intersegmental artery rather than the aortic arch or dorsal aorta. The ansa subclavia in this case report was prominently discernible if compared to the left one and cadaver without RRSA.

In conclusion, this case report provided the details of abnormal development and anatomo-

my of the RRSA with the right NRILN, which enhance the comprehension in clinical presentation and associated symptoms.

## REFERENCES

- ALMENAR-GARCÍA V, TEROL FF, CORREA-LACARCEL J, LLORET J, ROBLES J, DEL CAMPO FS (2002) Retro-esophageal subclavian artery: a case report. *Surg Radiol Anat*, 24: 231-234.
- AVISSE C, MARCUS C, DELATTRE JF, MARCUS C, CAILLIEZ-TOMASI JP, PALOT JP, LADAM-MARCUS V, MENANTEAU B, FLAMENT JB (1998) Right nonrecurrent inferior laryngeal nerve and arteria lusoria: the diagnostic and therapeutic implications of an anatomic anomaly. Review of 17 cases. *Surg Radiol Anat*, 20: 227-232.
- BAYFORD D (1794) Account of singular case of obstructed deglutition. *Mem Med Soc*, 2: 271-282.
- HENRY JF, AUDIFFRET J, DENIZOT A, PLAN M (1988) The nonrecurrent inferior laryngeal nerve: review of 33 cases, including two on the left side. *Surgery*, 104: 977-984.
- HERMANS R, DEWANDEL P, DEBRUYNE F, DELAERE PR (2003) Arteria lusoria identified on preoperative CT and nonrecurrent inferior laryngeal nerve during thyroidectomy: a retrospective study. *Head Neck*, 25: 113-117.
- LOUKAS M, GIANNIKOPOULOS P, FUDALEJ M, DIMOPOULOS C, WAGNER T (2004) A retroesophageal right subclavian artery originating from the left aortic arch – a case report and review of the literature. *Folia Morphol (Warsz)*, 63: 141-145.
- MARANILLO E, VAZQUEZ T, QUER M, NIEDENFÜHR MR, LEON X, VIEJO F, PARKIN I, SANUDO JR (2008) Potential structures that could be confused with a nonrecurrent inferior laryngeal nerve: an anatomic study. *Laryngoscope*, 118: 56-60.
- NAKATANI T, TANAKA S, MIZUKAMI S, OKAMOTO K, SHIRAISHI Y, NAKAMURA T (1996) Retroesophageal right subclavian artery originating from the aortic arch distal and dorsal to the left subclavian artery. *Ann Anat*, 178: 269-271.
- TRIANTOPOULOU C, IOANNIDIS I, KOMITOPOULOS N, PAPAILIOU J (2005) Aneurysm of retroesophageal right subclavian artery causing Dysphagia lusoria in an elderly patient. *Am J Roentgenol*, 184: 1030-1032.
- VAN SON JA, KONSTANTINOV IE (2002) Burckhard F. Kommerell and Kommerell's diverticulum. *Tex Heart Inst J*, 29: 109-112.
- WANG Y, JI Q, LI D, WU Y, ZHU Y, HUANG C, SHEN Q, WANG Z, ZHANG L, SUN T (2011) Preoperative CT diagnosis of right non recurrent inferior laryngeal nerve. *Head Neck*, 33: 232-238.