

Ansa cervicalis - variable course of the superior root

Neeru Goyal and Anjali Jain

Department of Anatomy, Christian Medical College, Ludhiana, India

SUMMARY

In the past few years, techniques have been developed using ansa cervicalis to innervate muscles of the larynx paralyzed due to surgical procedures performed in the area of the chest and neck. In the present report, during routine dissection in a middle-aged male cadaver, we observed an unusual course of the superior root of the ansa cervicalis on right side. The superior root of the ansa cervicalis fused with the vagus, and ran within the carotid sheath before joining the inferior root forming the ansa cervicalis in the anterior wall of the carotid sheath. The present case should add to our existing knowledge of ansa cervicalis, and should help surgeons in avoiding injury to the nerve during various surgical procedures.

Key words: Anatomical variation – Ansa cervicalis – Descendens hypoglossi – Hypoglossal nerve

INTRODUCTION

Ansa cervicalis is a nerve loop seen in the carotid triangle which is formed by the union of superior and inferior roots. The superior root (descendens hypoglossi) contains fibres from the first cervical spinal nerve. It leaves the hypoglossal nerve when it curves around the occipital artery and runs down on the carotid sheath. It provides a branch to the superior belly of omohyoid before joining the inferior root (descendens cervicalis, which contains fibres

from second and third cervical spinal nerves) to form a loop, which is termed the ansa cervicalis. From the convexity of this loop branches pass to supply the sternohyoid, the sternothyroid and the inferior belly of the omohyoid (Stranding, 2008).

In the past few years, there has been a development in the techniques using ansa cervicalis to innervate muscles of the larynx paralyzed due to surgical procedures performed in the area of the chest and neck (surgeries of esophagus, thyroid). Recurrent laryngeal nerve paralysis represents a major complication in oesophageal and thyroid cancer surgery. Nerve-muscle transplantation to the paraglottic space after resection of the recurrent laryngeal nerve with the ansa cervicalis has recently become the procedure of choice (Loukas et al., 2007). Ansa is used during nerve anastomosis with the recurrent laryngeal nerve due to its proximity to the larynx. Good knowledge of topographical relationships existing in the area, including possible variations, is one of the key prerequisites for successful surgery (Machalek et al., 2009).

Reports regarding the variations in the origin, course and branching of ansa cervicalis are many in the literature. Machalek et al. (2009) reported a case where ansa cervicalis was formed posterior to the carotid sheath, while Venugopal and Mallula (2010) observed a case where no loop of nerves was formed and the superior root directly supplied the infrahyoid muscles. Abu-Hijleh (2005) reported a case of bilateral absence of ansa cervicalis, and the infrahyoid muscles were then supplied by a vagocervical plexus. Manjunath (2000), Vollala et al. (2005) and Ayyoubian and Koruji (2011) reported the superior root arising from vagus and Verma et al. (2005) and Patel et al. (2010) ob-

Corresponding author: Neeru Goyal. Department of Anatomy, Health Sciences Block, Christian Medical College, Ludhiana, India. Tel: +91- 9815288988.
E-mail: meetneeru24@yahoo.co.in

Submitted: 27 February, 2013. Accepted: 25 June, 2013.

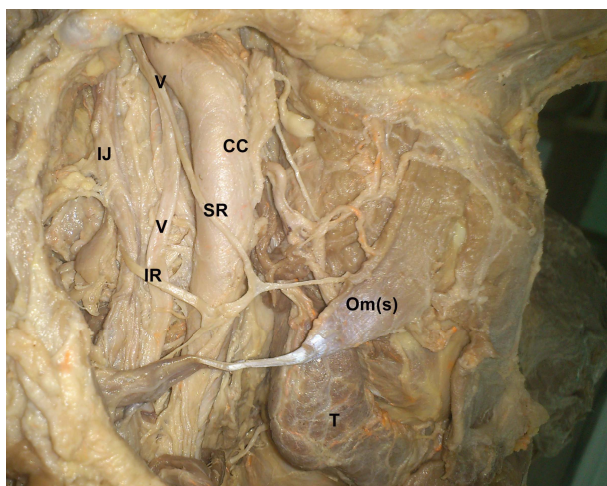


Fig. 1. Ansa cervicalis on right side. Abbreviations: CC, common carotid artery; IJ, internal jugular vein; IR, inferior root of ansa cervicalis; Om(s), superior belly of omohyoid; SR, superior root of ansa cervicalis; T, thyroid gland; V- vagus nerve.

served extracranial fusion of hypoglossal and vagus nerves.

In the present report we observed an unusual course of the superior root of the ansa cervicalis.

CASE REPORT

During the routine dissection for MBBS students in the department of Anatomy, Christian Medical College, Ludhiana, India, we detected an unusual course of the superior root of ansa cervicalis on the right side in a middle-aged male cadaver.

The hypoglossal nerve had a usual course. When the hypoglossal turned round the occipital artery, it gave off two branches- one small branch ran in the anterior wall of the carotid sheath and supplied the superior belly of the omohyoid muscle. The other branch formed the superior root of ansa cervicalis (descendens hypoglossi). This superior root, instead of running in the anterior wall of carotid sheath, immediately joined the vagus and fused with it. It then ran within the carotid sheath fused with the vagus for a distance of 3.5cm. The superior root then pierced the carotid sheath to join the inferior root forming ansa cervicalis in the anterior wall of the carotid sheath (Fig 1). From the loop of ansa cervicalis, two branches were given off – one supplied the superior belly of the omohyoid, sternothyroid and sternohyoid muscles; and the other supplied the inferior belly of the omohyoid. Therefore, the superior belly of the omohyoid was supplied by two different branches. Thyrohyoid muscle was supplied by a branch from hypoglossal nerve.

On left side, the formation and distribution of ansa cervicalis was usual.

DISCUSSION

Numerous variations in the origin and course of ansa cervicalis have been described (Table 1). The ansa may arise from first, second and third, or only from the second and third cervical nerves. Descendens hypoglossi may be replaced by vagus. When no ansa is present, the innervation of the infrahyoid muscles is by branches arising directly from C2 and C3. The nerve to the thyrohyoid may arise as a branch of descendens hypoglossi. The phrenic nerve may also receive a contribution from the descendens hypoglossi. Variable connections of ansa cervicalis with cervical sympathetic trunk have also been reported (Bergman et al., 2006).

Normally, the superior root of ansa cervicalis runs down on the carotid sheath before joining the inferior root. In the present case, the fibres of the first cervical spinal nerve joined the hypoglossal as usual. The superior root of ansa branched off from the hypoglossal nerve as usual, but, instead of running in the anterior wall of the carotid sheath, the superior root joined the vagus and ran within the carotid sheath before forming the loop. Vollala et al. (2005) also described a case where the superior root came from the vagus, but in their report they did not specify whether the fibres from first cervical spinal nerve joined the hypoglossal and then accompanied the vagus, or they directly joined the vagus nerve. Accord et al. (2010), while performing carotid endarterectomy, observed the superior root of ansa arising from the vagus, but they did not specify where and how the fibres of C1 joined the vagus.

Banneheka et al. (2008) described two broad categories of communications between the ansa cervicalis complex and the vagus nerve: (i) false (pseudo) communications, where the two nerves were attached only by the connective tissue with no fiber exchange; and (ii) true communications, with nerve fiber involvement. Fiber analysis showed that the majority of the ansa-vagal communications observed during gross dissection were of the first category. True communications, when present, were only scanty contributions and always directed towards the side of the vagus. In addition, the vagus (region of the inferior ganglion) and hypoglossal nerves were found to be in close contact at the base of the skull and usually could not be separated by gross dissection. But such attachments, too, were shown to be almost entirely of false nature except for the possible presence of a few fine nerve filaments. It seems that the ansa-vagal communications are merely a result of the close physical relationship between the two structures and serve no significant functional purpose. But at the same time the ansa-vagal communications become very important

Table 1. Comparison of results of previous authors

Author	Year	Type of Article	No of cases	Side	sex	Variation
Verma et al.	2005	Case report	1	Left	Male	Extracranial fusion of vagus and hypoglossal
Vollala et al.	2005	Case report	1	Left	Male	Superior root from vagus
Machalek et al.	2009	Case report	1	Bilateral	Male	Ansa lying posterior to carotid sheath
Venugopal and Mallula	2010	Case report	1	Right	Male	No loop was formed
Patel et al.	2010	Case report	1	Right	Male	Extracranial fusion of vagus and hypoglossal
Mwachaka et al.	2010	Study	4 out of 38 on right side and 7 out of 38 on left side.			No loop found in 14.5% cases. Ansa lying medial to internal jugular vein (18.5% cases)
D'Souza and Ray	2010	Study	3 out of 100 cases	2 left, 1?		1 case: Ansa absent. The muscular branches arose from vagus nerve. 2 cases: the superior root of the ansa arose from vagus nerve
Abu-Hijleh	2005	Case report	1	Bilateral	Male	No loop was formed. Muscular branches arose from vago-cervical plexus
Ayyoubian and Koruji	2011	Case report	1	Right	Male	Superior root coming from vagus
Present study	2013	Case report	1	Right	Male	Superior root after arising from hypoglossal joined the vagus

from a surgeon's point of view, as such communications may hinder the prospects of using ansa cervicalis in surgical procedures, such as re-innervation of laryngeal and facial muscles, following damage to recurrent laryngeal and facial nerves, respectively.

The ansa cervicalis is used with success for laryngeal re-innervation in the event of vocal cord paralysis caused by recurrent laryngeal nerve damage due to pathological or iatrogenic causes (Crumley and Izdebski, 1986; Miyauchi et al., 1998). The superior root and the branch to the sternothyroid muscle are commonly used for this purpose due to their close proximity to the recurrent laryngeal nerve (Frazier and Mosser, 1926). Further, ansa cervicalis is also used for reanimation of the face after facial nerve palsy. Ansa cervicalis is preferred over the traditional use of hypoglossal nerve in this procedure, because it avoids late complications such as defective speech and swallowing due to scarred degeneration of the target muscles of the hypoglossal nerve. It has also been reported that such defects could be minimized by combining facial-hypoglossal anastomosis with simultaneous myoplasty and anastomosis of the distal hypoglossal stump to the ansa cervicalis (Kukwa et al., 1994), again underlining the importance of ansa cervicalis in this type of treatment procedures (Banneheka et al., 2008).

Developmentally, the myotome part of a somite divides into a dorsal portion, or epimere, and a ventral portion, or hypomere. These portions are innervated respectively by the dorsal and ventral rami of the spinal nerves. The developing transverse processes of the vertebrae help separate the epi- and hypomeres. The hypomeres further divide into dorsomedial, lateral and ventral portions. The ventral portions of the hypomeres of the cervical myotomes give rise to the strap muscles of the neck, including the scalene and infrahyoid muscles, which are innervated by the ventral rami of the cervical spinal nerves. The fourth and sixth pharyngeal arches are innervated by the superior laryngeal and recurrent laryngeal branches of the vagus nerve (cranial nerve X). The occipital myotomes extend ventrally and shift cranially, and form the intrinsic and extrinsic musculature of the tongue. These are innervated by the hypoglossal nerve (cranial nerve XII). The proximity between the cervical and the occipital myotomes could probably explain the embryological basis for this variation (Arey, 1961; Hamilton and Mossman, 1976).

To conclude, the present case showed a variable course of the superior root of ansa cervicalis, which after branching off from the hypoglossal nerve joined the vagus before forming the loop. Such ansa-vagal communications should add to the existing knowledge of ansa cervicalis, and should help the surgeons in avoiding injury to the

nerve during various surgical procedures.

REFERENCES

- ABU-HIJLEH MF (2005) Bilateral absence of ansa cervicalis replaced by vagocervical plexus: case report and literature review. *Ann Anat*, 187: 121-125.
- ACCORD RE, REYNTJENS P, SAMYN M, REUWER J (2010) Unusual origin of the ansa cervicalis observed during carotis endarterectomy. *Ann Vas Surg*, 24: 692.e17-9.
- AREY LB (1961) *Developmental Anatomy*. 6th edit. Asia Publishing House, Bombay, pp 431-432.
- AYYOUBIAN M, KORUJI M (2011) A rare anatomical variant of ansa cervicalis: case report. *Med J Islam Repub Iran*, 24: 238-240.
- BANNEHEKA S, TOKITA K, KUMAKI K (2008) Nerve fiber analysis of ansa cervicalis-vagus communications. *Anat Sci Int*, 83: 145-151.
- BERGMAN RA, AFIFI AK, MIYAUCHI R (2006) Ansa cervicalis. Illustrated encyclopaedia of human anatomy. www.anatomyatlases.org/anatomicvariants/anatomyhp.html
- CRUMLEY RL, IZDEBSKI K (1986) Voice quality following laryngeal reinnervation by ansa hypoglossi transfer. *Laryngoscope*, 96: 611-616.
- D'SOUZA AS, RAY B (2010) Study of the formation and distribution of the ansa cervicalis and its clinical significance. *Eur J Anat*, 14: 143-148.
- FRAZIER CH, MOSSER WB (1926) Treatment of recurrent laryngeal nerve paralysis by nerve anastomosis. *Surg Gynecol Obstet*, 43: 134-139.
- HAMILTON WJ, MOSSMAN HW (1976) Hamilton, Boyd and Mossman's Human Embryology. 4th edit. Macmillan Press Ltd, London, pp 551-558.
- KUKWA A, MARCHEL A, PIETNICZKA M, RAKOWICZ M, KRAJEWSKI R (1994) Reanimation of the face after facial nerve palsy resulting from resection of a cerebellopontine angle tumor. *Br J Neurosurg*, 8: 327-332.
- LOUKAS M, THORSELL A, TUBBS RS, KAPO S T, LOUIS RG Jr, VULIS M, HAGE R, JORDAN R (2007) The ansa cervicalis revisited. *Folia Morphol (Warsz)*, 66: 120-125.
- MACHALEK L, CHARAMZA J, KIKALOVA K, BEZDEKOVA M (2009) A variant case of ansa cervicalis. *Int J Anat Variations*, 2: 150-152.
- MANJUNATH KY (2000) Vagal origin of the ansa cervicalis nerve: report of two cases. *Indian J Otolaryngol Head Neck Surg*, 52: 257-258.
- MIYAUCHI A, MATSUSAKA K, KIHARA M, MATSUZUKA F, HIRAI K, YOKOZAWA T, KOBAYASHI K, KOBAYASHI A, KUMA K (1998) The role of ansa to recurrent laryngeal nerve anastomosis in operations for thyroid cancer. *Eur J Surg*, 164: 927-933.
- MWACHAKA PM, RANKETI SS, ELBUSAYDI H, OGENG'O J (2010) Variations in the anatomy of ansa cervicalis. *Folia Morphol (Warsz)*, 69: 160-163.
- PATEL JP, SHAH RK, SHAH KP, NIRVAN AB, MERCHANT SP (2010) Superior root of ansa cervicalis arising from vagus nerve. *Gujarat Med J*, 65: 11-13.
- STANDRING S (2008) Neck. In: *Gray's Anatomy*. 40th edit. Churchill Livingstone Elsevier, p 460.
- VENUGOPAL SP, MALLULA SB (2010) Ansa cervicalis - without loop. *Int J Anat Variations*, 3: 153-155.
- VERMA R, DAS S, SURI R (2005) Unusual organization of the ansa cervicalis - a case report. *Braz J Morphol Sci*, 22: 175-177.
- VOLLALA VR, BHAT SM, NAYAK S, RAGHUNATHAN D, SAMUEL VP, RODRIGUES V, MATHEW JG (2005) A rare origin of upper root of ansa cervicalis from vagus nerve- a case report. *Neuroanatomy*, 4: 8-9.