

# Anthropometric references for reconstruction of the anterior cruciate ligament in the anatomical position

Gustavo A. Compeán-Martínez<sup>1</sup>, Félix Vilchez-Cavazos<sup>2</sup>, Carlos Acosta-Olivo<sup>2</sup>, Oscar F. Mendoza-Lemus<sup>2</sup>, Oscar de la Garza-Castro<sup>1</sup>, Rosa I. Guzmán-Avilán<sup>1</sup>, Rodrigo E. Elizondo-Omaña\*<sup>1</sup> and Santos Guzmán López<sup>1</sup>

<sup>1</sup>Department of Human Anatomy, School of Medicine, Universidad Autónoma de Nuevo León, Mexico and  
<sup>2</sup>Department of Traumatology and Orthopedics, Hospital Universitario, Universidad Autónoma de Nuevo León, Mexico

## SUMMARY

Recent anatomical and biomechanical studies have established that the anatomical position in the reconstruction of the anterior cruciate ligament (ACL) is ideal because this position results in a lower placement of the femoral tunnels, which provides optimal biomechanical function of the graft, and because anterior translation and rotational stability are controlled. Ten femurs (five left and five right) and ten tibias (five left and five right) were dissected to analyze the various bony prominences of the lateral wall of the intercondylar fossa. Parameters were also established for the measurement of the ACL and its anteromedial and posterolateral bundles. Regarding the results in the medial wall of the lateral femoral condyle, different bony landmarks were considered, such as the distances from the bone-cartilage transition of anterior and posterior point of femoral condyle to the bifurcated ridge obtaining  $7.68 + 2.15$  mm and  $7.99 + 2.15$  mm, respectively. On the tibial bone we considered the length between the free edges of lateral and medial menisci, to the medial and lateral edges of anterior cruciate ligament (ACL), finding a distance of  $2.5$  cm +  $1.20$ mm. All these references during knee arthroscopy are useful to the sur-

geon, providing tools for the proper placement of the tunnels used in the reconstruction surgery of the ACL.

**Key words:** Anterior cruciate ligament – Femoral tunnels – Reconstruction of ACL – Anterior cruciate ligament bundles

## INTRODUCTION

The rupture of the anterior cruciate ligament (ACL) is one of the most common pathologies in orthopedics, especially for patients who participate in sports (Fu, 1999; Griffin, 2000; Myklebust, 1997; Prodromos et al., 2007). Recent studies have reported that between 30% and 35% of patients with ACL ruptures who undergo reconstructive surgery do not return to performing at the same level of athletic activity after the surgery (Biau, 2007; Freedman et al., 2003).

The clinical results of ACL repair are not satisfactory in all patients. (Aglietti, 1997; Carson, 2004; Colosimo, 2001; Getelman, 1999; Martinek, 2002; Taggart, 2004). The principal cause of this dissatisfaction is attributed to the fact that the position of the ACL in surgical reconstruction is not optimal. (Howell, 1998; Sommer, 2000; Diamantopoulos, 2008). Originally, repairs to the ACL by arthroscopic means were not performed in the anatomical position of the ACL because of

**Corresponding author:** C. Rodrigo E. Elizondo Omaña. Ave. Madero y Dr. Aguirre Pequeño s/n, Col. Mitras Centro, Monterrey, Nuevo León 64460, Mexico. Tel: 00 (52) 81 83294171. E-mail: rod\_omana@yahoo.com

Submitted: 9 February, 2013. Accepted: 13 April, 2013.

the technical difficulty of such approach. Currently, there is an increasing trend to position the ACL according to the anatomical insertion points of the ligament during reconstruction to obtain a better clinical outcome. Two fundamental aspects for improving the clinical outcome are a proper anatomical position when placing the graft during surgery and separate reconstruction of the anteromedial (AM) and posterolateral (PL) bundles of the ACL (Shen et al., 2007).

Previous studies have reported the anatomical positions of the tibial and femoral insertions of the ACL, as well as the positions of the AM and PL bundles (Shen et al., 2007). However, the anthropometric measures between bony and/or soft tissue reference points and the ACL have not been specifically established. These measures might assist the surgeon in correctly positioning the ACL during reconstruction.

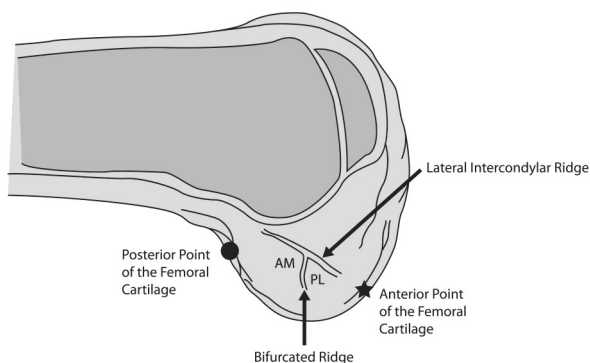
The goal of our study was to describe the position of the ACL and to establish the necessary anatomical points of reference for the correct placement of the femoral and tibial tunnels in the anatomical position during ACL repair.

## MATERIALS AND METHODS

We dissected ten femurs (five left and five right) and ten tibias (five left and five right), which were collected from the Department of Human Anatomy of the Faculty of Medicine at the Autonomous University of Nuevo León, to analyze the various bony prominences of the lateral wall of the intercondylar fossa. Parameters were also established for the measurement of the ACL and its AM and PL bundles. No cadaver presented any sign of injury or abnormality in the knee joint.

### Knee preparation

The anatomical pieces were refrigerated at 4°C prior to use and were brought to room temperature 12 hours prior to their handling. To access



**Fig. 1.** The bony references of the lateral wall of the intercondylar fossa.

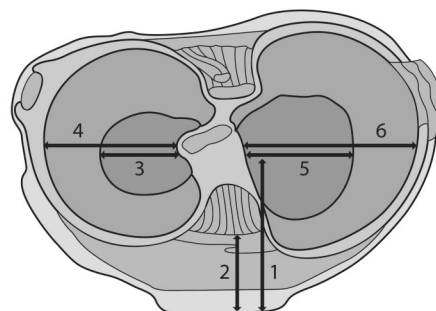
the ACL, an incision was made in the distal part of the quadriceps tendon to retract it, and to analyze the ACL as well as its two bundles and bony prominences at 90° of flexion. To improve the visibility of the menisci and the tibial and femoral insertions of the ACL, the posterior cruciate ligament (PCL) was displaced. In addition, a transverse cut was made in the collateral ligaments.

### Measurements

The perimeters of the tibial and femoral insertions of the ACL, as well as their bundles and related structures, were measured using digital Vernier calipers (TED PELLA with a millimeter scale and a margin of error of 0.01 mm), which were introduced into the joint capsule to obtain the parameters that will be discussed below. For greater ease, we proceeded to completely disinsert the ACL to obtain the measurements outside the joint. This approach achieved more exact results for this structure.

### Femoral references

The bony references that were considered include the lateral wall of the intercondylar fossa: a) the lateral intercondylar ridge, b) the bifurcated ridge, c) the posterior point of the femoral cartilage, and d) the anterior point of the femoral cartilage. The lateral intercondylar ridge is an elevation that is located in the lateral wall of the femoral condyle and that is used as a reference for the placement of the femoral tunnel because this ridge demarcates the anterior edge of the ACL. The bifurcated ridge is a bony reference that runs perpendicular to the lateral intercondylar ridge with the knee flexed at 90°, and marks the sepa-



- |               |                |                |
|---------------|----------------|----------------|
| 1 AET - PEACL | 3 FEEM - LEACL | 5 FEIM - MEACL |
| 2 AET - AEACL | 4 CEEM - LEACL | 6 CEIM - MEACL |

**Fig. 2.** The parameters for the tibial location of the ACL. **ACL**, Anterior Cruciate Ligament; **AET**, Anterior Edge of the Tibia; **AEACL**, Anterior Edge of the Anterior Cruciate Ligament; **PEACL**, Posterior Edge of the Anterior Cruciate Ligament; **FELM**, Free Edge of the Lateral Meniscus; **LEACL**, Lateral Edge of the Anterior Cruciate Ligament; **CELM**, Capsular Edge of the Lateral Meniscus; **FEIM**, Free Edge of the Internal Meniscus; **MEACL**, Medial Edge of the Anterior Cruciate Ligament; **CEIM**, Capsular Edge of the Internal Meniscus.

**Table 1.** The lengths of the structures of the lateral wall of the femoral intercondylar fossa

	LIR	BR-APFC	BR-PPFC	BR
Average	18.35	7.68	7.99	6.96
SD	3.09	2.15	2.15	1.76

LIR, Lateral Intercondylar Ridge; APFC, Anterior Point of the Femoral Cartilage; PPFC, Posterior Point of the Femoral Cartilage; BR, Bifurcated Ridge; SD, Standard Deviation. \*Millimeter scale (mm)

ration between the AM and PL bundles of the ACL. The posterior point refers to the posterior bone-cartilage transition area of the lateral wall of the intercondylar fossa with the knee flexed. The anterior point corresponds to the anterior bone-cartilage transition area of the lateral wall of the intercondylar fossa with the knee flexed (Fig. 1).

### Tibial references

The tibial bony references that were considered were the traces left by the ACL at the site of removal from its tibial insertion. The distance between the anterior edge of the tibia and the anterior and posterior edge of the ACL trace was measured. Similarly, cartilaginous references, such as the menisci and the lateral and medial edges, were determined. To measure the menisci, the two edges were accounted for using a) the "free edge", which is in close relation to the midline of the knee, and b) the "capsular edge", which is located proximal to the joint capsule (Fig. 2).

## RESULTS

### Femoral parameters

*Lateral intercondylar ridge.* This ridge was ob-

served in all of the knees that were dissected at 90° of flexion; an average length of 18.35 mm ( $\pm 3.09$  mm) was measured.

*Bifurcated ridge.* The bifurcated ridge was palpated and observed in all of the knees that were dissected. The average length of the bifurcated ridge was 6.96 mm ( $\pm 1.76$  mm). Table 1 shows the results of the anatomical points of reference in the intercondylar fossa.

### Parameters of tibial insertion of the ACL

*Anterior edge of the tibia.* The average length between the anterior edge of the tibia and the anterior edge of the trace left by the ACL was 11.00 mm ( $\pm 2.20$  mm). The average length between the anterior edge of the tibia and posterior edge of the trace left by the ACL was 25.01 mm ( $\pm 4.17$  mm).

*Menisci.* An average length of 25.01 mm ( $\pm 4.17$  mm) from the free edge of the lateral meniscus to the lateral edge of the ACL was measured. The average length from the free edge of the internal meniscus to the medial edge of the ACL was 24.99 mm ( $\pm 3.11$  mm). Table 2 shows the results of the anatomical points of reference and ACL on the tibia.

### Parameters of the ACL

The length of the femoral insertion of the ACL and length of the tibial insertion of the ACL (Table 3) were considered as well as each of the measurements for the previously separated AM (Table 4) and PL bundles (Table 5).

## DISCUSSION

This study morphometrically describes the ana-

**Table 2.** The parameters for tibial insertion of the ACL

	AET-AEACL	AET-PEACL	FEEM-LEACL	CEEM-LEACL	FEIM-MEACL	CEIM-MEACL
Average	11.00	25.01	25.01	17.63	24.99	19.51
SD	2.20	4.17	2.71	3.05	3.11	4.52

ACL, Anterior Cruciate Ligament; AET, Anterior Edge of the Tibia; AEACL, Anterior Edge of the Anterior Cruciate Ligament; PEACL, Posterior Edge of the Anterior Cruciate Ligament; FEEM, Free Edge of the External Meniscus; LEACL, Lateral Edge of the Anterior Cruciate Ligament; CEEM, Capsular Edge of the External Meniscus; FEIM, Free Edge of the Internal Meniscus; MEACL, Medial Edge of the Anterior Cruciate Ligament; CEIM, Capsular Edge of the Internal Meniscus; SD, Standard Deviation. \*Millimeter scale (mm)

**Table 3.** The lengths of the ACL

	Length		
	TI	FI	CP
Average	9.59	11.74	8.28
SD	1.55	4.19	1.41

TI, Tibial Insertion; FI, Femoral Insertion; CP, Central Portion; SD, Standard Deviation. \*Millimeter scale (mm)

**Table 4.** The anteromedial bundle length of the ACL

	Length		
	TI	FI	CP
Average	5.23	7.55	4.69
SD	1.03	1.78	1.28

TI, Tibial Insertion; FI, Femoral Insertion; CP, Central Portion; SD, Standard Deviation. \*Millimeter scale (mm)

tomical relationships of the ACL and its femoral and tibial insertions, as well as the lengths and areas of insertion of the ACL and its AM and PL bundles. The data provided by this study will help the surgeon to better understand the insertions of the ACL and perform the reconstruction of the ACL, using more exact insertion sites based on the anatomy of the joint.

In the literature, there are many studies regarding the anatomy of the ACL. (Colombet, 2006; Mochizuki, 2006; Takahashi, 2006; Arnoczky, 1983; Girgis, 1975; Harner, 1999; Noorwood, 1979; Odenstein, 1985). In general, the majority of authors agree that the ACL has two functional bundles, the AM and PL (Colombet, 2006; Mochizuki, 2006; Takahashi, 2006; Arnoczky, 1983; Girgis, 1975; Harner et al., 1999). In our study, we corroborated what is described by Ferreti et al. (2007) regarding the bifurcated ridge, which separates the insertions of the AM and PL bundles at their insertion into the intercondylar fossa. The presence of the bifurcated ridge supports the notion that the ACL has two bundles with different femoral insertions.

The bony references used in the medial wall of the lateral femoral condyle are the lateral intercondylar ridge; bifurcated ridge; posterior point, which corresponds to the posterior bone-cartilage transition zone of the lateral wall of the intercondylar fossa with the knee flexed; and anterior point, which corresponds to the anterior bone-cartilage transition zone of the lateral wall of the intercondylar fossa with the knee flexed. The lateral intercondylar ridge is an important point of reference during surgery because it is well defined in all knees, as described in other studies (Anderson, 1987; Good, 1991; Muneta et al., 1997) and serves as a point of reference to define the anterior border of the femoral insertion of the ACL. The length of the lateral intercondylar ridge in our study was  $18.35 \pm 3.09$  mm, and the results are consistent with those reported by Ziegler et al. (2011), which stated an average of 18 mm, but greater than those reported by Ferreti et al., which stated an average of  $14.9 \pm 2$  mm. The bifurcated ridge is slightly more difficult to localize in arthroscopic surgery than the intercondylar ridge. In our anatomical study, this feature was found in all of the knees that were studied and

was located perpendicular to the intercondylar ridge, thereby separating the femoral insertion of the AM and PL bundles of the ACL. The bifurcated ridge is found more forward relative to the average point of the lateral intercondylar ridge, which is in the zone where the insertion of the ACL into the femur becomes thinner, as described by Mochizuki et al. (2006) (Fig. 1).

The results of the insertion lengths of the AM and PL bundles were  $7.55 \pm 1.78$  mm and  $7.56 \pm 1.24$  mm, respectively; these results are similar to those reported by Ferreti et al., which were  $9.8 \pm 1$  mm and  $7.3 \pm 0.5$  mm, respectively, and those reported by Mochizuki et al. (Mochizuki et al., 2006), which were 9.2 mm and 6.0 mm, respectively. In our study, we described the distances of the points anterior and posterior to the bifurcated ridge, which were  $7.68 \pm 2.15$  mm and  $7.99 \pm 2.15$  mm, respectively. We consider this reference highly useful for the surgeon during arthroscopic reconstruction of the ACL, because the bifurcated ridge can serve as a point of reference for the placement of the ACL in the anatomical position.

Although previous studies have evaluated the anatomy of the ACL and its femoral and tibial insertions, these studies have used the central point of the ligament as a reference for the femoral and tibial insertions. In our study, in order to obtain more precision regarding the points of insertion of the ACL in the tibia, the circumferential edges of the ACL in its tibial insertion were used as reference points. Specific distances from the ACL to bony structures and soft tissues were quantified. Our study describes the anatomical references of the ACL in its tibial insertion by accounting for the anterior, posterior, medial and lateral edges of insertion, which results in greater precision than in studies that only used the central point of ACL insertion. Our approach provides the surgeon with more points of reference and additional tools when arthroscopically repairing the ACL. When using a single or double tunnel technique, one should not lose the total area of insertion of the ACL in the tibia. In this study, we provide quantitative data for the distance from the edges of the anterior ACL to the anterior edge of the tibia and free and capsular edges of the medial and lateral meniscus. In the study, we observed that the distance between the free edge of the internal meniscus and internal edge of the ACL on the tibia was  $24.99 \pm 3.11$  mm and that the distance between the free edge of the external meniscus and exterior edge of the ACL on the tibia was  $25.01 \pm 4.17$  mm. These results are useful for the surgeon during arthroscopic reconstruction of the cruciate ligament, because it is easy to locate the free edges of the internal and external menisci. Considering that the distance

**Table 5.** The posterolateral bundle length of the ACL

	Length		
	TI	FI	CP
Average	5.34	7.56	5.26
SD	1.38	1.24	1.22

TI, Tibial Insertion; FI, Femoral Insertion; CP, Central Portion; SD, Standard Deviation. \*Millimeter scale (mm)

between the edges of the menisci and internal and external edges of the ACL on the tibia is  $2.5 \text{ cm} \pm 1.20 \text{ mm}$ , these measurements constitute an additional tool for the correct location of the ACL on the tibia. In addition, the study quantitatively shows the diameter of the ACL at its tibial and femoral insertions, as well as the diameter of the AM and PL bundles at the femoral and tibial insertion sites.

Ziegler et al. (2011) used the centers of the ACL as well as the AM and PL bundles for the quantitative description of the insertion of the ACL in the tibia. We decided to use the edges of the ACL at its tibial insertion site as opposed to the center and its bundles, because we believe that the surgeon, when deciding between this approach or the tunnel approach as the technique to use, needs to keep the safe area of insertion in the visual field of the arthroscope and establish the margins that must not be crossed by the insertion.

This research confirmed what was described by Ziegler et al. (2011), who stated that the AM bundle is found anterior and covers the PL bundle, and that insertion of the AM bundle in the tibia has the form of a comma. When the knee is flexed at  $90^\circ$ , the portion of the ACL that is observed is the AM bundle. The insertion of the PM bundle at the tibia is  $5.23 \text{ mm} (\pm 1.03)$ , and it consists of a small thinning in the medial portion and increases by more than 2 mm at its femoral insertion. These results are important in surgery, because the surgeon should be aware of this discordance in diameter between the points of insertion.

The results obtained in this study assist in improving the position of the ACL placement during arthroscopic reconstruction, regardless whether with a double tunnel or a conventional single-tunnel technique is applied by always seeking the anatomical position as a central reference during reconstructive surgery of the ACL. By improving the placement of the tunnels, better functional results are obtained, and errors in ACL reconstruction are minimized.

## REFERENCES

AGLIETTI P, BUZZI R, GIRON F, SIMEONE AJ, ZACCHEROTTI G (1997) Arthroscopic-assisted anterior cruciate ligament reconstruction with the central third patellar tendon: A 5-8 year follow-up. *Knee Surg Sports Traumatol Arthrosc*, 5: 138-144.

AMIS AA, DAWKINS GP (1991) Functional anatomy of the anterior cruciate ligament. Fiber bundle actions related to ligament replacements and injuries. *J Bone Joint Surg Br*, 73: 260-267.

ANDERSON AF, LIPSCOMB AB, LIUDAHL KJ, AD-

DLESTONE RB (1987) Analysis of the intercondylar notch by computed tomography. *Am J Sports Med* 15: 547-552.

ARNOCZKY SP (1983) Anatomy of the anterior cruciate ligament. *Clin Orthop Relat Res*, 172: 19-25.

BIAU DJ, TOURNOUX C, KATSAHIAN S, SCHRANZ P, NIZARD R (2007) ACL reconstruction: a meta-analysis of functional scores. *Clin Orthop Relat Res*, 458: 180-187.

CARSON EW, ANISKO EM, RESTREPO C, PANARIELLO RA, O'BRIEN SJ, WARREN RF (2004) Revision anterior cruciate ligament reconstruction: etiology of failures and clinical results. *J Knee Surg*, 17: 127-132.

COLOMBET P, ROBINSON J, CHRISTEL P, FRANCESCHI JP, DJIAN P, BELLIER G (2006) Morphology of anterior cruciate ligament attachments for anatomic reconstruction: a cadaveric dissection and radiographic study. *Arthroscopy*, 22: 984-992.

COLOSIMO AJ, HEIDT RS JR, TRAUB JA, CARLONAS RL (2001) Revision anterior cruciate ligament reconstruction with a reharvested ipsilateral patellar tendon. *Am J Sports Med*, 29: 746-750.

DIAMANTOPOULUS AP, LORBACH O, PAESSLER HH (2008) Anterior cruciate ligament revision reconstruction: results in 107 patients. *Am J Sports Med*, 36: 851-860.

FERRETTI M, EKDAHL M, SHEN W, FU FH (2007) Osseous landmarks of the femoral attachment of the anterior cruciate ligament: an anatomical study. *Arthroscopy*, 23: 1218-1225.

FREEDMAN KB, D'AMATO MJ, NEDEFF DD, KAZ A, BACH BR, JR (2003) Arthroscopic anterior cruciate ligament reconstruction: a meta-analysis comparing patellar tendon and hamstring tendon autografts. *Am J Sports Med*, 31: 2-11.

FU FH, BENNETT CH, LATTERMANN C, MA CB (1999) Current trends in anterior cruciate ligament reconstruction. Part 1: Biology and biomechanics of reconstruction. *Am J Sports Med*, 27: 821-830.

GETELMAN MH, FRIEDMAN MJ (1999) Revision anterior cruciate ligament reconstruction surgery. *J Am Acad Orthop Surg*, 7: 189-198.

GIRGIS FG, MARSHALL JL, MONAJEM A (1975) The cruciate ligaments of the knee joint. Anatomical, functional and experimental analysis. *Clin Orthop Relat Res*, 106: 216-231.

GOOD L, ODENSTEN M, GILLQUIST J (1991) Intercondylar notch measurements with special reference to anterior cruciate ligament surgery. *Clin Orthop Relat Res*, 263: 185-189.

GRIFFIN LY, AGEL J, ALBOHM MJ, ARENDT EA, DICK RW, GARRETT WE (2000) Noncontact anterior cruciate ligament injuries: risk factors and prevention strategies. *J Am Acad Orthop Surg*, 8: 141-150.

HARNER CD, BAEK GH, VOGRIN TM, CARLIN GJ, KASHIWAGUCHI S, WOO SL (1999) Quantitative analysis of human cruciate ligament insertions. *Arthroscopy*, 15: 741-749.

HOWELL SM (1998) Principles for placing the tibial

- tunnel and avoiding roof impingement during reconstruction of a torn anterior cruciate ligament. *Knee Surg Sports Traumatol Arthrosc*, 6 (suppl 1): S49-S55.
- MARTINEK V, IMHOFF AB (2002) Revision of failed anterior cruciate ligament reconstruction. *Orthopade*, 31: 778-784.
- MOCHIZUKI T, MUNETA T, NAGASE T, SHIRASAWA S, AKITA KI, SEKIYA I (2006) Cadaveric knee observation study for describing anatomic femoral tunnel placement for two-bundle anterior cruciate ligament reconstruction. *Arthroscopy*, 22: 356-361.
- MUNETA T, TAKAKUDA K, YAMAMOTO H (1997) Intercondylar notch width and its relation to the configuration and cross-sectional area of the anterior cruciate ligament. A cadaveric knee study. *Am J Sports Med*, 25: 69-72.
- MYKLEBUST G, MAEHLUM S, ENGBRETSSEN L, STRAND T, SOLHEIM E (1997) Registration of cruciate ligament injuries in Norwegian top-level team handball. A prospective study covering two seasons. *Scand J Med Sci Sports*, 7: 289-292.
- NORWOOD LA, CROSS MJ (1979) Anterior cruciate ligament: functional anatomy of its bundles in rotatory instabilities. *Am J Sports Med*, 7: 23-26.
- ODENSTEN M, GILLQUIST J (1985) Functional anatomy of the anterior cruciate ligament and a rationale for reconstruction. *J Bone Joint Surg Am*, 67: 257-262.
- PRODROMOS CC, HAN Y, ROGOWSKI J, JOYCE B, SHI K (2007) A meta-analysis of the incidence of anterior cruciate ligament tears as a function of gender, sport, and a knee injury-reduction regimen. *Arthroscopy*, 23: 1320-1325.e6.
- SHEN W, JORDAN S, FU F (2007) Review article: anatomic double bundle anterior cruciate ligament reconstruction. *J Orthop Surg*, 15: 216-221.
- SOMMER C, FRIEDERICH NF, MÜLLER W (2000) Improperly placed anterior cruciate ligament grafts: Correlation between radiological parameters and clinical results. *Knee Surg Sports Traumatol Arthrosc*, 8: 207-213.
- TAGGART TF, KUMAR A, BICKERSTAFF DR (2004) Revision anterior cruciate ligament reconstruction: a midterm patient assessment. *Knee*, 11: 29-36.
- TAKAHASHI M, DOI M, ABE M, SUZUKI D, NAGANO A (2006) Anatomical study of the femoral and tibial insertions of the anteromedial and posterolateral bundles of human anterior cruciate ligament. *Am J Sports Med*, 34: 787-792.
- ZIEGLER CG, PIETRINI SD, WESTERHAUS BD, ANDERSON CJ, WIJDICKS CA, JOHANSEN S (2011) Arthroscopically pertinent landmarks for tunnel positioning in single-bundle and double-bundle anterior cruciate ligament reconstructions. *Am J Sports Med*, 39: 743-752.