

Topographical mapping of the posterior interosseous nerve in surgical approaches to the proximal third of the radius

Gargi Soni, Lovesh Shukla, Neha Gaur, Suryamani Pandey

Maharaja Agrasen Medical College, Agroha-125047, Hisar, Haryana, India

SUMMARY

The posterior interosseus nerve, the deep branch of the radial nerve, is vulnerable to injury during internal fixation of radial head fractures. It arises from the radial nerve in front of the lateral epicondyle of the humerus. The aims of this study are to find the distance of the posterior interosseus nerve from the lateral epicondyle of the humerus at its entry point into the supinator muscle and its exit point from the supinator muscle; to evaluate the correlation between these distances with the length of the forearm and epicondylar width; and also to find a safe zone for approaching the proximal part of the radius, in order to minimize the chances of injury to the posterior interosseus nerve. 23 upper limbs obtained from formalin-fixed cadavers were dissected for their posterior interosseus nerve. All distances were measured with the help of sliding calipers and a measuring tape. Statistical analyses were performed using 'SYSTAT 12 Pearson coefficient analysis'. The mean distance of the posterior interosseous nerve from the lateral epicondyle of the humerus to the posterior interosseus nerve, at its entry point into the supinator muscle and its exit point from supinator muscle, were found to be 4 cm and 8 cm, respectively. A

statistically significant correlation between the length of the forearm and the exit of the posterior interosseous nerve from the supinator muscle was found (p -value=0.003). The present study concludes that the safe zone for the posterior interosseous nerve is 3.1 cm distal to the lateral epicondyle of the humerus. These data should be of help to orthopedic surgeons in minimizing the risk of injury to the posterior interosseus nerve while approaching the proximal part of the radius.

Key words: Posterior interosseus nerve – Supinator muscle – Lateral epicondyle

INTRODUCTION

The posterior interosseus nerve (PIN), the deep terminal branch of the radial nerve, arises from the radial nerve in front of the lateral epicondyle of the humerus (LEH), and reaches the back of the forearm by passing round the lateral aspect of the radius between the two heads of the supinator muscle (SM). It supplies the extensor carpi radialis brevis and supinator muscles before entering the SM; as it passes to the supinator it gives additional branches to it. As it emerges from the SM, the PIN gives off three short branches to the

extensor digitorum, the extensor digiti minimi and the extensor carpi ulnaris muscles, together with two long branches: a medial branch to the extensor pollicis longus and extensor indicis muscles, and a lateral branch to the abductor pollicis longus and extensor pollicis brevis muscles (Gray and Cater, 2000). The nerve at first lies between the superficial and deep extensor muscles, but at the distal border of the extensor pollicis brevis it passes deep into extensor pollicis longus, diminishes to a fine thread, descends on the interosseous membrane to the dorsum of the carpus. The articular branches from the PIN supply the carpal, distal radioulnar and some intercarpal and intermetacarpal joints (Gray and Cater, 2000). The causes of PIN palsy include trauma and inflammatory swellings. When fully developed, there is inability to extend the fingers at the metacarpophalangeal joints, weakness of thumb extension and abduction. The PIN is vulnerable to injury during all operating approaches for the proximal radius (Hoppenflied and Deboer, 2003). In these approaches, the PIN is of most concern as it provides motor innervation to the muscles of the extensor compartment of the forearm, whose injury may lead to wrist drop. To reach the extensor compartment of the forearm the PIN winds around the lateral aspect of the radial head, passing between the two heads of the supinator muscle (Hoppenflied and Deboer, 2003). Fracture of the head, neck and shaft of the radius are common reasons for operating in the region of the proximal radius (Wiss, 2006).

Aim and objectives of this work are:

1. To find the distance of the PIN from the LEH at its entry point into the SM and at the exit point from the SM.
2. To evaluate the correlation between these distances with the length of the forearm and epicondylar width.
3. To find a safe zone for approaching the proximal part of the radius to minimize the chances of injury to the PIN.

MATERIALS AND METHODS

Twenty-three upper limbs obtained from formalin-fixed adult cadavers were dissected to obtain the posterior interosseous nerves. Proximally, the PIN was identified following a dissection between the brachioradialis and

the extensor carpi radialis longus and extensor carpi radialis brevis muscles. At the exit site from the supinator muscle, the PIN was identified following a dissection between the extensor carpi radialis longus and the extensor carpi radialis brevis and extensor digitorum communis muscles. In the mid-prone position of the forearm the following measurements were made:

1. With the help of sliding calipers, the distance from the LEH to the: a) entry point of the PIN into SM, b) the exit point of the PIN from the SM (Figs. 1, 2, 3)
2. The epicondylar width was measured from the most projecting point on the medial epicondyle to the most projecting point on the LEH with the help of sliding calipers.



Fig. 1. Measurement of distance from the lateral epicondyle (LE) of humerus to the entry point of posterior interosseous nerve (PIN) into the supinator muscle.



Fig. 2. Measurement of distance from the lateral epicondyle (LE) of humerus to the exit point of posterior interosseous nerve (PIN) from the supinator muscle.

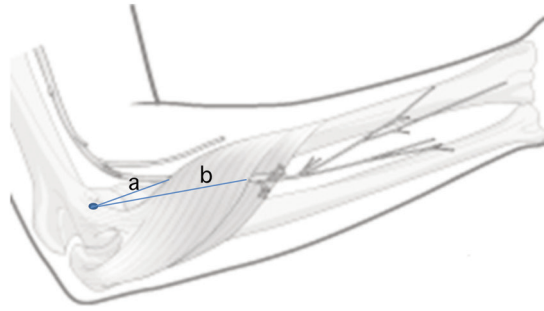


Fig. 3. Schematic diagram of measurement of: a) The distance from the lateral epicondyle (LE) of humerus to the entry point of posterior interosseous nerve (PIN) into the supinator muscle; b) The distance from the lateral epicondyle (LE) of humerus to the exit point of posterior interosseous nerve (PIN) from the supinator muscle.

3. The length of the forearm was measured from the most projecting point on LEH to the tip of the styloid process of the radius with the help of a measuring tape.

Linear regression analysis (SYSTAT 12 Pearson correlation) was used for statistical analyses. The correlation between the length of the forearm and epicondylar width to the entry point of the PIN into the SM and with the exit point of the PIN from the SM was studied. The safe zone for the PIN, which is the minimum distance from the LEH to the entry point of the PIN into the SM, was also found.

RESULTS

Table 1 shows the means and ranges of distance of the PIN from the lateral epicondyle of the humerus to the entry into the supinator muscle and exit from the supinator muscle.

Using 'SYSTAT (12) Pearson correlation analysis' software, a significant correlation was found between the length of the forearm and the exit point of the PIN from the SM (p 0.003). A hypothesis was formulated to determine the exit point of the PIN from the SM: Exit = length of forearm (mm) \times 0.370 (regression coefficient) - 22.08 (constant).

This hypothesis was tested by applying the formula to the data collected here and exit was predicted with 95% confidence level. No statistically significant correlation was found between the length of the forearm and the entry of the PIN into the SM; and no statistically significant correlation was found between these distances of the PIN and epicondylar width. A safe zone for the PIN was observed to be at a distance of 3.1cm distal to the lateral epicondyle.

Table 1. Mean and range of distance of PIN from the lateral epicondyle of humerus to entry and exit from supinator.

Distance from the lateral epicondyle of humerus to	Mean (cm)	Range (cm)
Entry into supinator muscle	4.0	3.1-5.3
Exit from supinator muscle	8.0	6.3-10.3

DISCUSSION

The posterior interosseous nerve (PIN) has been studied by various authors. Table 2 shows the comparison of the means and ranges of distance of the PIN from the lateral epicondyle to entry into the supinator and exit from the supinator. The literature addressing the correlation between the length of the forearm or epicondylar width and the entry point of the PIN into the supinator muscle or the exit point of the PIN from the supinator muscle is scarce (Vergara, 2008; Tubbs et al. 2006), whereas the present study shows that there is a significant correlation between the length of the forearm and the exit point of the PIN from supinator muscle. In the present study, a formula is hypothesized to determine the exit point of the PIN from the supinator: Exit = length of forearm (mm) \times 0.370 (regression coefficient) - 22.08 (constant). This correlation can be utilized to predetermine the approximate exit point of the PIN from the SM. No statistically significant correlation was found between the length of the

Table 2. Comparison of the results of the present study with previous studies.

Distance from lateral epicondyle to	Vergara (2008)		Tubb's et al. (2006)		Present study	
	Mean (cm)	Range (cm)	Mean (cm)	Range (cm)	Mean (cm)	Range (cm)
Entry into supinator muscle	3.8	-	6.0	4.5-7.5	4.0	3.1-5.3
Exit from supinator muscle	6.0	4.8-8.0	12.0	10.0-15.0	8.0	6.3-10.3

forearm and the entry point of the PIN into the SM or between epicondylar width and these distances. This shows that the distance of entry of the PIN from the LEH into the supinator is independent of forearm length and epicondylar width. Several authors have defined a safe zone (3.8-4.2 cm) in relation to the proximal radius using different landmarks within which the chances of injury to the PIN are minimal (Diliberti et al., 2000; Schimizzi et al., 2009). Lawton et al. (2007) defined a safe zone as extending 4.0 cm proximal to the radio-capitellar joint, irrespective of the position of the forearm and this safe zone can be used even without formal identification of the PIN. This safe zone was also confirmed by Diliberti et al. (2000) with the forearm in pronation. Schimizzi et al. (2009) reported that the PIN is generally safe when dissecting up to 2.9 cm from the radio-capitellar joint and up to 4.2 cm from the LEH with the forearm in pronation. In the present study the shortest distance from the LEH to the entry of the PIN into the supinator was 3.1 cm which can be considered as the safe zone with the forearm in the mid-prone position.

CONCLUSIONS

1. The mean distance of the posterior interosseous nerve from the lateral epicondyle to the entry into the supinator is 4 cm and the mean distance from the lateral epicondyle to the exit of the posterior interosseous nerve from the supinator is 8 cm.

2. The exit of the PIN from the supinator muscle is directly related to the length of the forearm. A hypothesis was formulated to determine the exit point of the PIN from the SM: exit = length of the forearm (mm) x 0.370 (regression coefficient) - 22.08 (constant). This predetermination of distance can be used in surgical decompression of the posterior interosseous nerve in cases of radial tunnel syndrome.

3. The present study concludes that the safe zone for the posterior interosseous nerve is 3.1 cm from the lateral epicondyle of the humerus. Within this distance from the lateral epicondyle of the humerus the chances of injury to the PIN while operating on the proximal part of the radius are slim.

Prior identification of a safe zone should guide operating surgeons in interventions on the proximal part of the radius. There is no statistically significant correlation between the length of the forearm and the entry of the PIN into the supinator. There is no statistically significant correlation between epicondylar width and the entry or exit of the PIN into the supinator. These data should be of help to orthopedic surgeons in minimizing the risk of injury to the PIN when approaching the proximal part of the radius.

REFERENCES

- DILIBERTI T, BOTTE MJ, ABRAMS RA (2000) Anatomical considerations regarding the posterior interosseous nerve during posterolateral approaches to the proximal part of the radius. *J Bone Joint Surg Am*, 82: 809-813.
- GRAY H, CATER HV (2000) Forearm. I: Standring S (ed). *Gray's Anatomy. The Anatomical Basis of Clinical Practice*. Elsevier, Churchill Livingstone.
- HOPPENFLED S, DEBOER P (2003) *Surgical Exposures in Orthopaedics: The Anatomic Approach*. Lippincott Williams & Wilkins, Philadelphia.
- LAWTON JN, CAMERON-DONALDSON M, BLAZAR PE, MOORE JR (2007) Anatomic considerations regarding the posterior interosseous nerve at the elbow. *J Shoulder Elbow Surg*, 16: 502-507.
- SCHIMIZZI A, MACLENNAN A, MEIER KM, CHIA B, CATALANO LW 3rd, GLICKEL SZ (2009) Defining a safe zone of dissection during the extensor digitorum communis splitting approach to the proximal radius and forearm: an anatomic study. *J Hand Surg Am*, 3: 1252-1255.
- TUBBS RS, SALTER EG, WELLONS JC, BLOUNT JP, OAKES WJ (2006) Superficial surgical landmarks for identifying the posterior interosseous nerve. *J Neurosurg*, 104: 796-799.
- VERGARA AE (2008) Anatomic aspects of the posterior interosseous nerve in the proximal approach to the radius. *Acta Ortop Mex*, 22: 309-315.
- WISS DA (2006) *Master Techniques in Orthopaedic Surgery: Fractures*. Lippincott Williams & Wilkins, Philadelphia.