

Variations in the vascular supply of the upper one third of the sciatic nerve

Vaishali Paranjape*, Jyoti Kulkarni and P. Vatsalaswamy

Dept. of Anatomy, Dr. D.Y. Patil Medical College, Pimpri, Pune, D.Y. Patil University, India

SUMMARY

The arteria comitans nervi ischiadica (ACNI), which is a branch of the inferior gluteal artery and represents the axial artery of the inferior extremity, supplies the sciatic nerve in gluteal region. The vascular supply of the upper 1/3rd of the sciatic nerve and the morphological details of the ACNI have not been characterized yet in detail. Hence, we studied the extraneuronal blood supply of the upper 1/3rd of the sciatic nerve by cadaveric dissection. The upper 1/3rd of the sciatic nerve was dissected in the gluteal region by reflecting the gluteus maximus muscle in 33 formalin-fixed cadavers. Variations in the number of ACNI arising from the inferior gluteal artery and length of segments of ACNI were noted. The source of other nutrient branches supplying the sciatic nerve in the gluteal region was also noted. In 86.6% of cases one ACNI was found. 9% of limbs had two ACNI and 1.8% had three ACNI arising respectively from the inferior gluteal artery (IGA). The morphology of the ACNI was studied in three segments and it showed variation in length. Blood supply to the sciatic nerve was assisted by the nutrient branches from trochanteric & cruciate anastomosis in 71% of cases, and branches from the artery accompanying the posterior cutaneous nerve of the thigh in 34% of cases. Both sources assisted blood supply in 3% of cases. Detailed knowledge of blood supply to the peripheral nerve is essential for surgeons dealing with peripheral nerve injuries.

Key words: Sciatic nerve – Inferior gluteal artery – Arteria comitans nervi Ischiadica – Axial artery – Peripheral nerve

* Corresponding author: Vaishali M. Paranjape.

Dept. of Anatomy, Dr. D.Y. Patil Medical College, B3, Sarita Society, Near Karve Statue, Behind Kothrud Petrol Pump, 411038, Pune, India. E-mail: vmp1997@gmail.com

INTRODUCTION

Nervi ischiadica, more commonly known as the sciatic nerve, is related to the ischium, and it is the largest and longest nerve in the human body. This nerve is a branch of the sacral plexus (Root value – L4 L5 S1 S2 S3). The nerve passes through the greater sciatic notch below the piriformis muscle, and is seen under the cover of the gluteus maximus muscle. It is composed of peroneal and tibial components. Its tibial part gives branches to hamstrings, and its peroneal part supplies the short head of the biceps femoris muscle in the thigh. The nerve normally divides into two terminal branches, namely the common peroneal branch and the tibial branch at the upper border of the popliteal fossa. They together supply the leg and the sole. Higher division of the sciatic nerve is seen in 12% of cases. In such situation the common peroneal branch either pierces the piriformis muscle, or it lies above the piriformis muscle, whereas the tibial part lies below the piriformis muscle. The sciatic nerve is accompanied on its medial aspect by the posterior femoral cutaneous nerve and the inferior gluteal artery. The branch of the IGA, classically known as Arteria Comitans Nervi Ischiadica (ACNI), supplies the sciatic nerve. ACNI is the remnant of the axial artery of the inferior extremity, and is the source of major arterial supply to the lower limb bud at an early embryological stage. The sciatic nerve also receives nutrient twigs from adjacent arteries taking part in formation of cruciate and trochanteric anastomoses, and from the artery accompanying the posterior cutaneous nerve of the thigh. These branches are referred as nutrient branches in current study. Trochanteric anastomosis is formed by the descending branch of the superior gluteal artery with the ascending branches of both the medial and lateral circumflex femoral arteries, while cruciate anastomosis is formed by transverse branches of both

Submitted: 1 April, 2013. Accepted: 4 September, 2013.

the medial and lateral circumflex femoral arteries, the ascending branch of the first perforating artery and the descending branch of the inferior gluteal artery (Last, 1990).

The peripheral nerves are associated with visible arteries running on the surface as ACNI in the case of the sciatic nerve. These arteries are regarded as embryological remnants. The peripheral nerves also receive nutrient twigs from adjacent arteries which are sources of local blood supply to

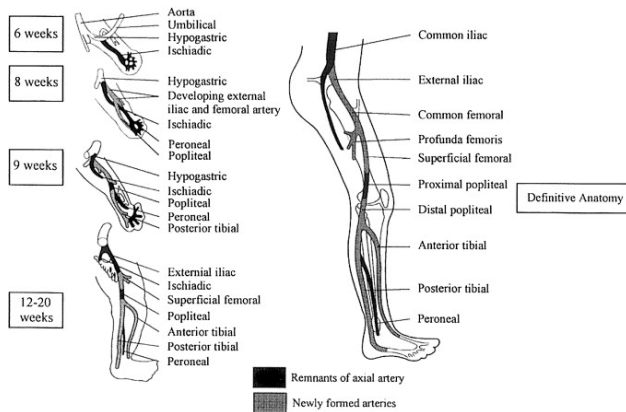


Fig.1. Axial artery of the lower limb.

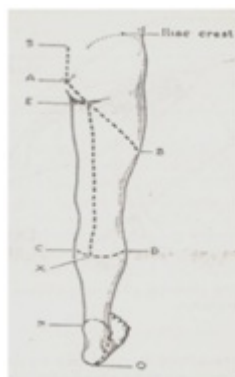


Fig. 2. Skin incisions for dissection of the sciatic nerve.

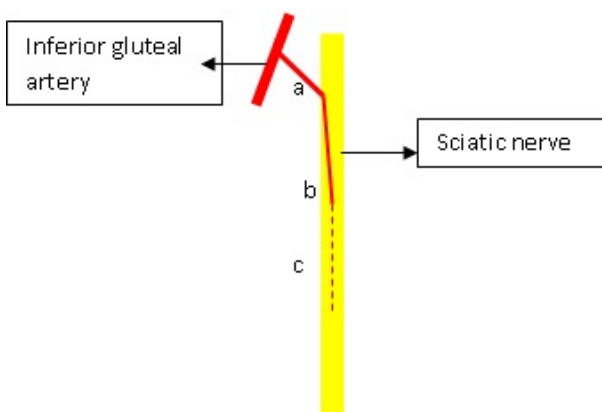


Fig. 3. Schematic representation of blood supply to the sciatic nerve.

the nerve. On reaching the surface of the peripheral nerve, these vessels course in the epineureum and further form an interfascicular plexus. The intrafascicular plexus is of capillary order and is fed at intervals through nutrient arteries (Adams, 1942).

Interest in the study of blood supply of the sciatic nerve arose from an increasing number of peripheral nerve casualties due to vehicular accidents. The sciatic nerve is the largest and longest nerve of the body with a documented supply from a branch of inferior gluteal artery named as arteria comitans nervi ischiadica. However, there is very little information available on the blood supply of the sciatic nerve. Keeping this in mind, a cadaveric study was undertaken to study the extraneuronal blood supply of the sciatic nerve in the gluteal region.

MATERIALS AND METHODS

The present study was carried out in 33 formalin-preserved cadavers, which included 30 male and 3 female cadavers. The sciatic nerve was exposed in the gluteal region by the following method: first, the cadaver was turned into prone position; second, in order to steady the limb blocks were put under the anterior superior iliac spine and the an-

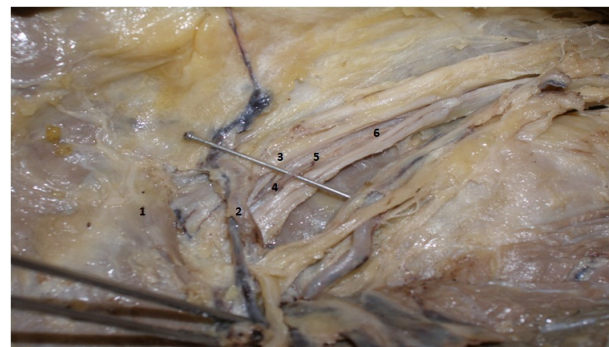

Fig. 4. 1: Piriformis muscle, 2: Inferior gluteal artery, 3: Sciatic nerve, 4: Segment 'a', 5: Segment 'b', 6: Segment 'c'.

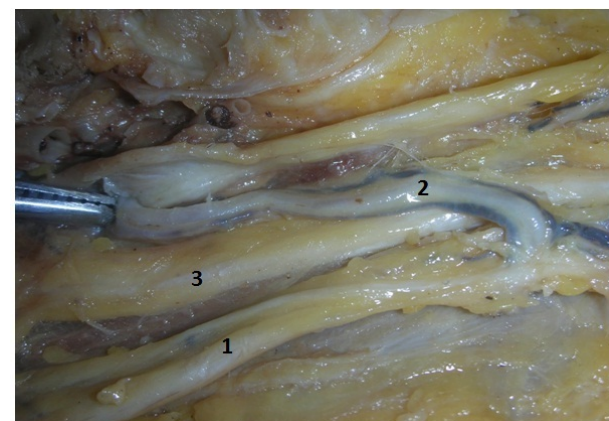


Fig. 5. 1: Inferior gluteal artery, 2: Recurrent branch of inferior gluteal artery, 3: Sciatic nerve.

kle; third, skin incisions were given according to the Fig. 1 mentioned below and the skin was reflected.

The deep fascia covering the gluteus maximus was removed, and the borders of the gluteus maximus were defined. The posterior cutaneous nerve of the thigh was identified at the inferior border of the gluteus maximus. The inferior border of the gluteus maximus was defined and the structures underneath were separated from the muscle. The gluteus maximus was detached from its origin at the sacrotuberous, sacrospinous ligaments, and the dorsal segment of the iliac crest and the muscle was reflected laterally. The sciatic nerve was identified and the inferior gluteal artery was also identified medial to the sciatic nerve below the piriformis muscle.

The blood supply of the sciatic nerve was studied in light of following points:

A. The number of branches from the inferior gluteal artery called as ACNI, supplying the segment of the sciatic nerve between the piriformis muscle and the greater trochanter of the femur.

B. The length of the three segments (Segment a, b, c) (Fig. 3) of ACNI was measured separately with the help of thread and mm scale. Segment “a” is the proximal segment extending from the inferior gluteal artery to the sciatic nerve. Segment “b” is the segment of the artery running on the surface of the nerve. Segment “c” is the segment of the artery that has pierced the substance of the nerve and could be dissected up to the point where it is visible to the naked eye. This segment of the artery can be called as vasa nervori.

D. Any other blood vessels (nutrient branches) supplying the sciatic nerve in the gluteal region were also noted.

RESULTS

The vascular supply of the upper 1/3rd of the sciatic nerve was seen as depicted in Table 1.

A total of 73 ACNI were detected in 66 limbs. In 30 limbs ACNI was assisted by vena comitans.

Single ACNI was found in 57 (86.36%) limbs (Fig. 3). In one case (1.8%) the sciatic nerve was supplied by a single ACNI, which was a recurrent branch from the inferior gluteal artery (Fig. 6). Six limbs (9%) had two ACNI and only one limb (1.8%) had three ACNI (Figs. 4, 5). The upper one third of

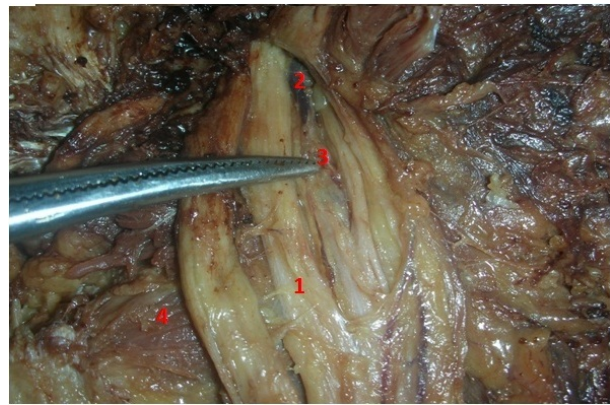


Fig. 6. 1: Common peroneal nerve, 2: Superior gluteal artery, 3: ACNI branch of superior gluteal artery, 4: Piriformis muscle.

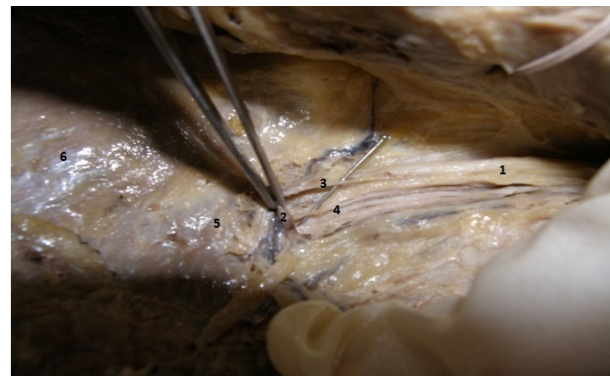

Fig. 7. 1: Sciatic Nerve, 2: Inferior gluteal artery, 3 & 4: Two branches from inferior gluteal artery supplying the sciatic nerve, 5: Piriformis muscle, 6: Gluteus medius.

the sciatic nerve was most commonly supplied by the ACNI i.e 65 out of 66 limbs. In one case ACNI was absent: here the blood supply to the sciatic nerve was from a nutritive branch from the superior gluteal artery (Fig. 7) supplying the common peroneal component of the sciatic nerve. In this case the inferior gluteal artery was also absent, and the sciatic nerve showed higher division into tibial and

Table 1. ACNI as the vascular supply of the upper 1/3rd of the sciatic nerve

Sr. No.		No. of limbs	Percentage
1.	One ACNI from IGA	57	86.36%
2.	Two ACNI from IGA	06	09%
3.	Three ACNI from IGA	01	1.8%
4.	ACNI as single recurrent branch of IGA	01	1.8%
5.	ACNI Accompanied by vena comitans	30	45.4%

Table 2. Associated nutrient branches supplying the upper 1/3 of the sciatic nerve

1.	Nutrient branch from the Superior gluteal artery	01	1.8%
2.	Nutrient branches assisting blood supply from trochanteric and cruciate anastomoses	47	71.2%
3.	Nutrient branches assisting blood supply from artery accompanying posterior cutaneous nerve of thigh	23	34.8%
4.	Nutrient branches from both i.e the trochanteric/cruciate anastomoses and artery accompanying posterior cutaneous nerve of thigh assisting the blood supply	02	3.03%

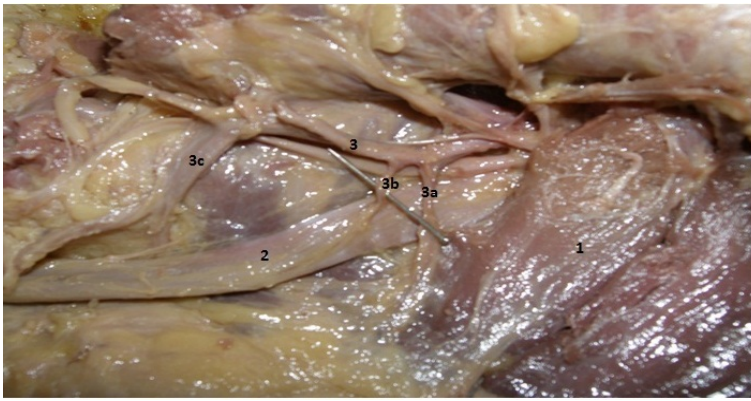


Fig. 8. 1: Piriformis muscle, 2: Sciatic nerve, 3: Inferior gluteal artery, 3a,3b,3c: Three branches from inferior gluteal artery supplying the sciatic nerve.

common peroneal component. Although the upper one third of sciatic nerve was predominantly supplied by the ACNI (98.48% of cases i.e in 65 out of 66 limbs), it was assisted by nutrient branches from trochanteric / cruciate anastomosis in 47 limbs (71.2% of cases) (Fig. 8) and nutrient branch from an artery accompanying the posterior cutaneous nerve of the thigh in 23 limbs (34.8% of cases) (Fig. 9). Nutrient branches were also forming the surface blood vessels in the form of an arterial network around the sciatic nerve (Fig. 10).

In 2 limbs (3.03% of cases) the blood supply to the sciatic nerve was assisted by both a nutrient branch from the trochanteric/ cruciate anastomosis and a nutrient branch from an artery accompanying the posterior cutaneous nerve of the thigh.

In 30 limbs (45% of cases) the ACNI was seen to be accompanied by vena comitans (Figs. 3b and 10).

The length of three segments of ACNI show a wide range. The segment 'a' ranges from 0 to 9 cm, with an average length of 2.15 cm. The segment 'b' ranges from 0 to 10.2 cm and the average

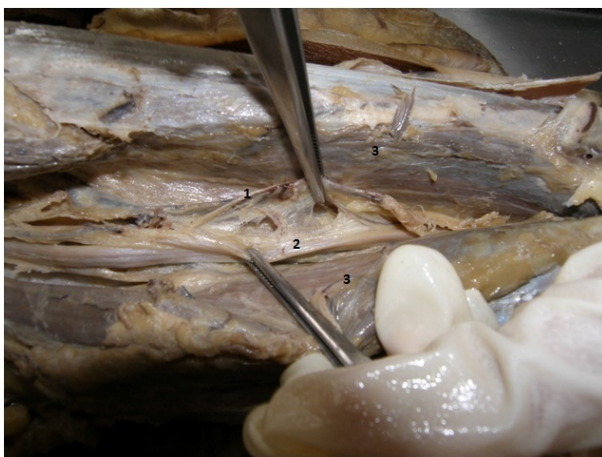


Fig. 9. 1: ACNI branch from trochanteric anastomosis, 2: Sciatic nerve, 3: Hamstring muscles.

length is 2.75 cm. The segment 'c' ranges from 0 to 5.5 cm, and the average length of segment 'c' is 0.98 cm. The total length (seg a+b+c) of ACNI is from 1.4 to 14 cm, the average total length of ACNI being 5.9 cm.

DISCUSSION

Karmanska et al. (1993) studied 32 sciatic nerves from 28 cadavers and found that the sciatic nerve is supplied by 4-8 nutrient arteries arising from the inferior gluteal artery, the medial circumflex femoral artery and the perforating arteries.

Ugrenovic et al. (2007, 2012) conducted studies on blood supply of sciatic nerves on 48 and 36 fetal lower limbs respectively. Ugrenovic et al. (2007) state that nutritional branches to the human foetal sciatic nerve arise from the inferior gluteal artery, the medial circumflex femoral artery, the perforating branches and the popliteal artery. These authors also mention the occurrence of an anastomotic arterial chain of the sciatic nerve in all the cases. 75% of cases the arterial chain of the sciatic nerve in the gluteal region is supplied by branches from the inferior gluteal artery, the medial circumflex femoral artery and the first two perforating arteries, and less frequently (14.5% of cases) from the third perforating branch. Ugrenovic et al. (2012) mention that the extraneural arterial chain is composed of 2 to 6 arterial branches from the inferior gluteal artery, the medial circumflex femoral artery, the perforating arteries and the popliteal artery.

Sreenivasulu et al. (2007) reported a case of an absent inferior gluteal artery.

Georgakis and Soames (2008) studied 20 human lower limbs. They could identify at least one sciatic artery supplying the sciatic nerve in the gluteal region. The authors further state that a total of 28 sciatic arteries were identified, of which 14 arose from the medial circumflex femoral artery, 11 from the inferior gluteal artery, 2 from the first perforat-

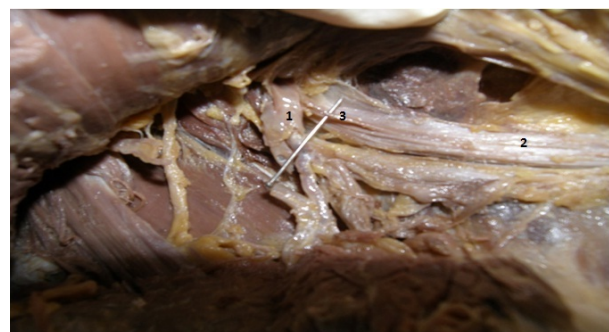

Fig. 10. 1: Inferior gluteal artery, 2: Sciatic nerve, 3: Segment 'b' of ACNI.

ing artery, and one from the internal pudendal artery. In 5 limbs, 2 sciatic arteries were observed. In 4 out of 5 limbs, they were independent branches from the medial circumflex femoral artery and the inferior gluteal artery, and as separate branches of medial circumflex femoral artery in one limb. In one limb, 4 sciatic arteries were observed, one branch from the inferior gluteal artery, 2 branches from the medial circumflex femoral artery and one branch from the first perforating artery. In the remaining limbs a single sciatic artery was observed. A single sciatic artery in one case arose from the internal pudendal artery.

Karmanska et al. (1993) uses the term nutrient artery for all the arteries supplying the sciatic nerve. In the study conducted by Georgakis and Soames (2008), every branch supplying the sciatic nerve is referred to as the 'sciatic artery'. In the present study the branch/branches arising only from the inferior gluteal artery and supplying the sciatic nerve are labelled ACNI. Branches arising from other sources like the cruciate / trochanteric anastomoses and the artery accompanying the posterior cutaneous nerve of the thigh are called as nutrient arteries.

In the present adult cadaveric study, the vascular supply of the upper one third of the sciatic nerve is most commonly from ACNI, and ACNI shows considerable variation in its morphology. The morphology of ACNI is studied in three segments. The morphology of ACNI has not been studied by any of the previous authors.

In 98.48% of cases, i.e. in 65 out of 66 limbs the sciatic nerve is supplied by ACNI, which is a branch of the inferior gluteal artery. The sciatic nerve is supplied by either single or multiple arteries, as reported by Karmanska et al. (1993) and Georgakis and Soames (2008). In the present study 86.6% of cases only one branch (single ACNI) was arising from IGA, while in 9% of cases two branches (two ACNI) from inferior gluteal artery were seen, and in 1.8% of cases three branches (three ACNI) from the IGA were found. ACNI was found to be a recurrent branch from inferior gluteal artery in one limb (1.8% of cases), presence of the recurrent branch is a new finding not reported by any of the previous researchers.

In the present study a branch or multiple branches from the inferior gluteal artery supplied the sciatic nerve in 98.48% of the limbs. In addition to ACNI, in 71.2% of cases the blood supply of the sciatic nerve was assisted by nutrient arteries from the trochanteric & cruciate anastomoses, whereas a branch of an artery accompanying the posterior cutaneous nerve of the thigh assisted the blood supply in 34.8% of cases. The nutrient arteries from both the sources i.e trochanteric / cruciate anastomoses and the artery accompanying the posterior cutaneous nerve of the thigh assisted

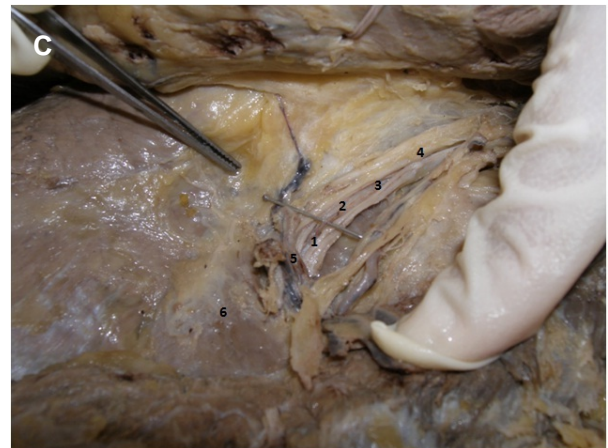
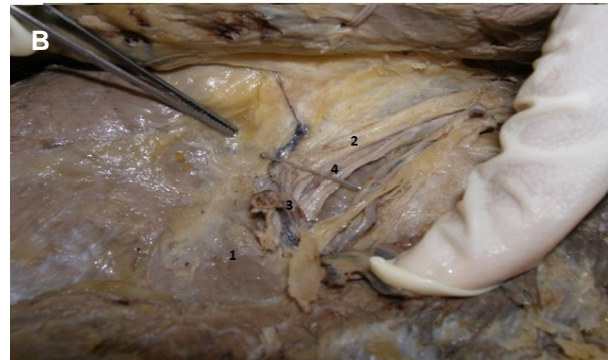
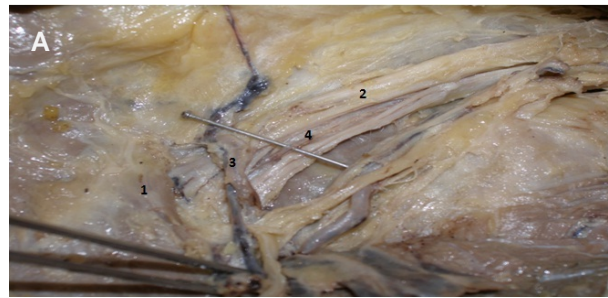


Fig. 11. (A) 1: Piriformis muscle, 2: Sciatic nerve, 3: Inferior gluteal artery, 4: Segment 'c' of ACNI. (B) 1: Piriformis muscle, 2: Sciatic nerve, 3: Inferior gluteal artery, 4: Segment 'c' of ACNI. (C) 1: Segment 'a', 2: Segment 'b', 3: Segment 'c', 4: Sciatic nerve, 5: Inferior gluteal artery, 6: Piriformis muscle.

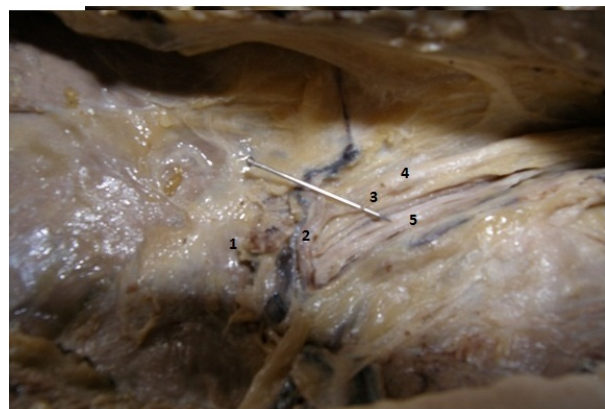

Fig. 12. 1: Piriformis muscle, 2: Inferior gluteal artery, 3: ACNI, 4: Sciatic nerve, 5: Posterior cutaneous nerve of thigh and the artery accompanying it.

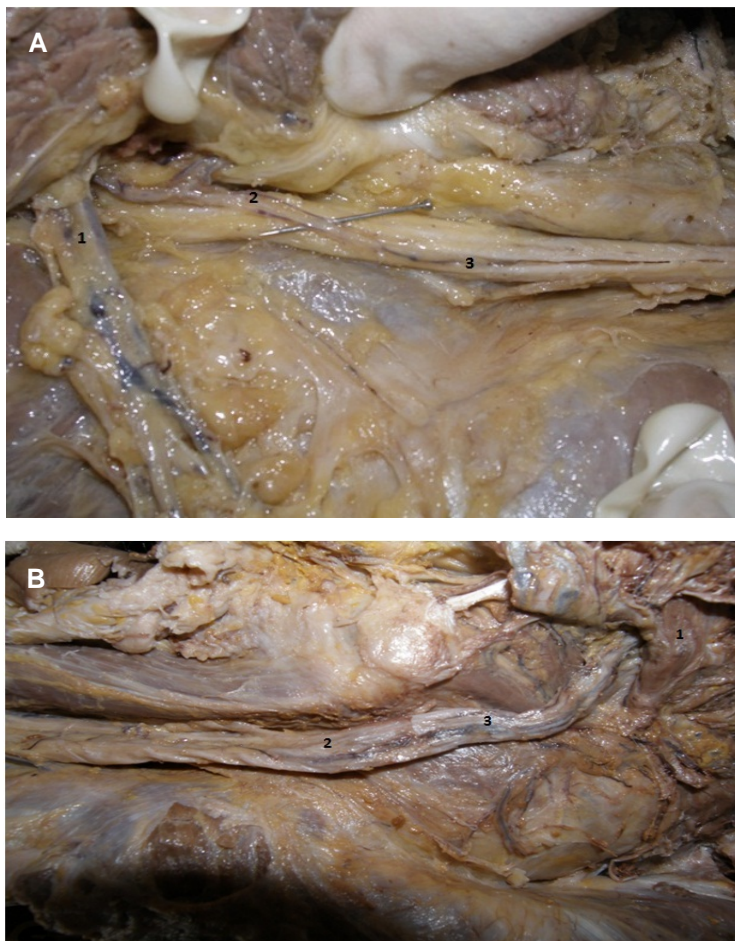


Fig. 13. (A) ACNI is accompanied by vena comitans. 1: Inferior gluteal artery, 2: Segment 'b' of ACNI, 3: Segment 'c' of ACNI. **(B)** 1: Piriformis muscle, 2: Sciatic nerve, 3: ACNI accompanied by vena comitans.

blood supply in 3.03% of cases. Karman-ska et al. (1993) and Georgakis and Soames (2008) have also found branches from medial circumflex femoral and perforating arteries supplying the sciatic nerve. They have used the terms "nutrient artery" and "sciatic artery" respectively for these branches in their study. Hence we can say that the sciatic nerve is also supplied by nutritional branches from surrounding arteries in addition to ACNI. We also feel that in future studies an uniform system of nomenclature could be adapted to avoid this ambiguity.

In the present study, in 1.8% of cases the sciatic nerve was supplied by a nutrient branch from the superior gluteal artery. In this case the sciatic nerve was showing a higher division, and the nutrient branch from the superior gluteal artery was supplying the common peroneal component, which was piercing the piriformis muscle. The tibial component arising below the piriformis muscle was supplied by a nutrient branch from the trochanteric anastomosis. The inferior gluteal artery was absent in this case. This finding concurs with the study done by Sreenivasulu et al. (2007).

In the present study, the ACNI was studied in three segments. These three segments showed variations in the length. The average length of segment 'a' was

Table 3. Comparison of findings of the present study and other studies

Present Study	Karmanska et al. (1993)	Ugrenovic et al. (2007)	Georgakis and Soames (2008)	Ugrenovic et al. (2012)
No. of limbs dissected - 66	No. of limbs dissected - 28	No. of limbs dissected - 48	No. of limbs dissected - 20	No. of limbs dissected - 36
One ACNI from IGA – 57 cases (86.36%)			28 single sciatic arteries were found as 14 from medial circumflex femoral artery, 11 from IGA, 2 from first perforating artery, 1 from internal pudendal artery	
Two ACNI from IGA – 06 cases (9%)				
Three ACNI from IGA – 01 case (1.8%)				
ACNI as single recurrent branch – 01 case (1.8%)		75% of cases the anastomotic arterial chain of human sciatic nerve was composed of branches of IGA, medial circumflex femoral & first two perforating arteries.		The extra neural arterial chain of sciatic nerve is composed of 2 to 6 arterial branches of IGA, medial circumflex femoral artery, perforating arteries, popliteal artery.
Nutrient branches from trochanteric & cruciate anastomoses - 47 cases (71.2%)	4-8 nutrient arteries arise from IGA, medial circumflex femoral, perforating & popliteal		In 5 limbs 2 sciatic arteries were found arising from medial circumflex femoral & IGA.	
Nutrient branches from artery accompanying posterior cutaneous nerve of thigh – 23 cases (34.8%)			In 1 limb 4 sciatic arteries were seen – 1 from IGA, 2 from medial circumflex femoral, 1 from 1 st perforating.	
Nutrient branches from both cruciate, trochanteric anastomosis & artery accompanying posterior cutaneous nerve of thigh – 2 cases (3.03%)				

2.15 cm, ranging from 0 to 9 cm. The average length of segment 'b' was 2.75 cm ranging from 0 to 10.2 cm. The segment 'C' in the present study has an average length of 0.98 cm, ranging from 0 to 5.5 cm. This segment corresponds to the intra-fascicular vascular net studied by Mikusek et al. (1997).

The average total length of ACNI was 5.9 cm, ranging from 1.4 to 14 cm. Previous researchers do not mention the morphological details of ACNI.

Presence of vena comitans makes identification of blood vessel easier. This could be an important factor in case of ACNI as its length ranges from 1.4 to 14 cm as seen in the present study. In our study, 45.4% of cases the ACNI is accompanied by vena comitans. This is surgically important, and as mentioned by Adams (1942) in his historical review of blood supply of nerves, the varices of vena comitans can cause phlebogenic neuropathy. However, Mikusek et al. (1997) is of the opinion that the number of venous vessels draining blood from fasciculi is much greater than the arterial vessels.

In the present study, the ACNI which is an axial artery of the inferior extremity and the chief artery supplying the sciatic nerve is found in 98.48%. Knowledge of the persistence of this axial artery in adults is crucial because, if this axial artery persists as mentioned by Cowan (2010), it may be at the risk of aneurysm, and it may cause difficulty during orthopedic manipulation, hip joint surgery, transplant surgery and it may be associated with developmental vascular deformities of the lower limb. Persistent sciatic artery is a vascular variant with a prevalence of 0.05%, according to Cavallo et al. (2012).

Ugrenovic (2007, 2012) mentions the arterial anastomotic chain on the surface of the sciatic nerve in foetal limbs constituted by arteries like the inferior gluteal artery, the medial circumflex femoral artery, the first two perforating arteries and the popliteal artery. In our study we have found nutrient branches from trochanteric / cruciate anastomosis and from the branch of an artery accompanying posterior cutaneous nerve of the thigh forming the surface blood vessels in the form of a delicate arterial network around the sciatic nerve. These anastomotic branches along with ACNI supply the upper 1/3 of sciatic nerve. Arterial anasto-

motoc chains in adults are important as timely intervention and perfect orientation of injured nerve ends, while suturing of nerve after any trauma is a crucial factor for minimising functional loss after any peripheral nerve injury. The nutrient arteries and pattern of surface blood vessels act as a guide for the alignment of nerve ends in nerve suturing techniques. Hence, knowledge of variations in vascular supply of the upper one third of the sciatic nerve would be of definite help to a surgeon dealing with peripheral nerve surgeries.

REFERENCES

- ADAMS WE (1942) The blood supply of nerves. Historical Review. *J Anat*, 76: 323-341.
- CAVALLO B, NAPOLI A, ANZEIDEI M, MAROTTA E, BONI F, CARTOCCI G, BERTACCINI L, NOCE V, PACILE MA, CATALANO C (2012) Persistence of the sciatic artery: a case report of a combined (complete & incomplete) type causing leg ischemia. *Case Rep Vasc Med*, 2012: 196798. doi: 10.1155/2012/196798.
- COWAN MM, HAMWEYAH KM, SABBAGH MD, SWAID BA, ALKATTAN AK, GANGULY P (2010) Persistent bilateral sciatic artery: Report of a rare case. *Int J Angiol*, 19: e43-44.
- GEORGAKIS E, SOAMES R (2008) Arterial supply to the sciatic nerve in the gluteal region. *Clin Anat*, 21: 62-65.
- KARMANSKA W, MIKUSEK J, KARMANSKI A (1993) Nutrient arteries of the human sciatic nerve. *Folia Morphol*, 52: 209-215.
- LAST RJ (1990) Last's Anatomy Regional and Applied, 8th edit. R.M.H. McMinn, ELBS publication, pp 166.
- MIKUSEK J, KARAMANSKA W, KARMANSKI A (1997) Vascularisation of the human sciatic nerve fasciculi. *Folia Morphol*, 56: 175-181.
- SREENIVASULU R, VENKATA RAMANA V, MOHANDAS R (2007) Absence of inferior gluteal artery: A rare observation. *Int J Morphol*, 25: 95-98.
- UGRENOVIC SZ, JOVANOVIC ID, VASOVIC LP, STEFANOVIC BD (2007) Extraneural arterial blood vessels of human fetal sciatic nerve. *Cells Tissues Organs*, 186: 147-153.
- UGRENOVIC SZ, JOVANOVIC ID, KOVACEVIC P, PETROVIC S, SIMIC T (2012) Similarities and dissimilarities of the blood supply of the human sciatic, tibial and common peroneal nerves. *Clin Anat*, Dec 19. doi: 10.1002/ca.22135. [Epub ahead of print].