

# Immunohistochemical localization of the cytoskeletal proteins in the abdominal and scrotal testes of mature and immature naturally unilateral cryptorchid West African dwarf goats

**Peter Chuka Ozegbe**

*Department of Veterinary Anatomy, University of Ibadan, Ibadan, Nigeria*

## SUMMARY

This study reports the immunohistochemical localization of alpha-smooth muscle actin, cytokeratin, desmin and vimentin cytoskeletal proteins in the abdominal and contralateral scrotal testes of mature and immature spontaneously unilateral cryptorchid West African Dwarf Goats (WADGs). Smooth muscle actin and desmin were co-expressed in the capsule, peritubule and the interstitium of the mature (scrotal) and immature (scrotal and abdominal) testes. Only smooth muscle actin, however, was variably immunorexpressed in the mature abdominal testes. Mature (scrotal) and immature (scrotal and abdominal) were variably immunopositive for cytokeratin. The mature abdominal testis was immunonegative for both cytokeratin and desmin. Vimentin was very weakly to moderately immunolocalized in the capsule and the interstitium of the immature abdominal testes, while the contralateral immature scro-

tal testis showed moderate to very strong immunoreactivity in the peritubule and interstitium. The interstitium of the mature scrotal testes was weakly to moderately immunopositive for vimentin. The interstitium of mature abdominal testis was, however, either negatively or weakly immunostained for vimentin. The perinuclear zone of each Sertoli cell showed vimentin immunoreactivity that was generally more intense in immature testes. The results of the study show that the cytoskeletal proteins in the Sertoli cells of WADGs are immunohistochemically similar to those reported in bovine and ovine species. The results also show that the testicular capsule of WADGs is immunopositive for vimentin, contrary to what has been reported in bulls and rams. The study demonstrates that spontaneous cryptorchidism in WADGs affects the co-expression of cytoskeletal proteins in a somewhat different way from the situation observed in humans, bulls and rams.

Corresponding author:

Dr. Peter Chuka Ozegbe. Department of Veterinary Anatomy, University of Ibadan, Ibadan, Nigeria. Phone: +234 (0) 8056010341.

E-mail: pcozegbe@yahoo.com / pc.ozegbe@ui.edu.ng

Submitted: February 27, 2012  
Accepted: April 9, 2012

**Key words:** West African dwarf goats – Cryptorchid – Cytoskeletal proteins – Immunohistochemistry

## INTRODUCTION

Cryptorchidism, hidden testis, is the failure of the testes to descend into the scrotum (Dyce et al., 2002; Devkota et al., 2006a). Testicular descent is completely accomplished during the intra-uterine life span of the pig, horse, cattle, goats and sheep, in contrast to the process in the dog (Baumann et al., 1981). Maldescent of the testis may be unilateral or bilateral, and may reveal the testis held within the abdomen or trapped within the inguinal canal (Dyce et al., 2002). Unilateral cryptorchidism is a common condition amongst the West African Dwarf goats (WADGs) of South-eastern Nigeria, the right testis being retained constantly with an abdominal location (Ezeasor, 1985).

The morphology of the scrotal and abdominal testes of naturally occurring or spontaneous unilateral cryptorchid goats (Ezeasor, 1985; Ôzyiğit, 2007; Igbokwe et al., 2009), horses, cats, rabbits (Fell, 1923), boars (Fell, 1923; van Straaten and Wensing, 1977; Pinart et al., 1999; 2000; 2001), rams (Hochereau-De Reviers et al., 1979) and camels (Vyas et al., 1996) have been described previously. The results from earlier immunohistochemical studies indicated that experimentally induced cryptorchidism causes a marked disruption of the cytoskeletons of Sertoli cells and peritubular tissues in the rat (Maekawa et al., 1995, Wang et al., 2002) and rhesus monkey (Zhang et al., 2004). Spontaneous cryptorchidism (Rogatsch et al., 1996; Loose et al., 2002), postnatal development (Steger and Wrobel, 1994; Zhu et al., 1997; Devkota et al., 2006b), pathologic conditions (Aumüller et al., 1988; Rogatsch et al., 1996) and ageing processes (de Miguel et al., 1997) have also been reported as factors that could alter the distribution pattern of the various cytoskeletal proteins in the seminiferous tubules of humans and, bovine, ovine, porcine and rat species. Most previous works have focused on the pattern of distribution of the intermediate filaments and/or microfilaments of the seminiferous tubules and their peritubular tissue in both health and in disease. Also, Arenas et al. (1997) have reported

an age-related variation in the immunoreactions of the cytoskeletal proteins of normal tunica albuginea of the testis in young and ageing men. However, there few or no reports addressing the comparative immunocharacterization of the capsular, peritubular and intertubular tissues of either the scrotal or the contralateral abdominal testes of spontaneously unilateral cryptorchid small ruminants, especially WADGs. According to Gall (1996), the West African Dwarf Goat constitutes about thirty eight percent of about thirty eight million goats in fifteen countries of the West African humid zone.

The testicular capsule and the peritubular tissue, with their smooth muscle cells, are important components of the contractile mechanism of the testis (Hargrove et al., 1977; Middendorff et al., 2002; Maretta and Maretta, 2004; Banks et al., 2006; Aire and Ozegbe, 2007; Ozegbe et al., 2008). These smooth muscle cells have been shown to be immunopositive for  $\alpha$ -smooth muscle actin, desmin, vimentin and smooth muscle myosin (Arenas et al., 1997; Rodríguez et al., 1999; Middendorff et al., 2002; Aire and Ozegbe, 2007; Ozegbe et al., 2008; Sasaki et al., 2010). There are, however, no reports on the distribution patterns of these cytoskeletal proteins in either type of testis (normal or cryptorchid) in mature and immature naturally unilateral cryptorchid West African dwarf goats.

The present study thus aims at determining the presence or absence, as well as the distribution patterns, of  $\alpha$ -smooth muscle actin microfilament (MF), and cytokeratin, desmin and vimentin intermediate filaments (IFs) in the testicular capsule and the parenchyma of both the scrotal and the contralateral abdominal testes of spontaneously unilateral cryptorchid, mature as well as immature, West African dwarf goats by means of immunohistochemical methods. The observations should provide baseline data on aspects of the reproductive biology of this socio-economically important domesticated small ruminant.

## MATERIALS AND METHODS

Pieces of testicular tissues (containing both the capsule and the parenchyma) from sexually mature (n=5) and immature (n=5) naturally unilateral cryptorchid West African Dwarf

goats (WADGs) were used in the present study. The samples, obtained from each of the abdominal testes and the contralateral scrotal testis, were collected 15-20 minutes after slaughter at the Nsukka abattoir, Enugu State, Nigeria, employing a standard slaughter protocol.

The tissue samples were immersion-fixed in 10% buffered formalin for 120 hours. After fixation, tissues were processed routinely for histology, embedded in paraffin wax, and sectioned (5  $\mu$ m). Immunohistochemical staining was carried out as earlier described (Aire and Ozegbe, 2007), using a LSAB-plus kit (Dakocytomation, Denmark). Briefly, tissue sections were mounted on slides precoated with polylysine, deparaffinized, and rehydrated. Thereafter, the slides were immersed in citrate buffer (pH 6) and microwaved at 750 W for three cycles of 7 minutes each. After being allowed to cool for 20 minutes the sections were rinsed copiously with distilled water. Endogenous peroxidase activity was blocked using a 3% hydrogen peroxide solution in distilled water (v/v) for 5 minutes in a humidified chamber. The slides were then rinsed in a 0.01M phosphate buffered saline solution containing bovine serum albumin (PBS + BSA, pH 7.6) for 5 minutes. Subsequently, the sections were incubated with  $\alpha$ -smooth muscle actin (M085101; diluted 1:50), cytokeratin (M082101; 1:100), desmin (A0611; 1:300) and vimentin (M072501; 1:100) antibodies for 30 minutes, following the protocol of the LSAB+<sup>®</sup> kit (DakoCytomation, Denmark). All antibodies were purchased from Dakocytomation,

Denmark. After rinsing in PBS, each slide was incubated for 15 minutes in a link antibody (Biotinylated secondary antibody) and then in peroxidase-labelled streptavidin. Antigen localization was visualised after the addition of either a 3,3'-diaminobenzidine tetrachloride solution (DAB) from the LSAB+<sup>®</sup> kit (actin, cytokeratin and desmin) or VECTOR<sup>®</sup> NovaRED<sup>™</sup> (vimentin) solutions. Finally, the sections were counterstained with haematoxylin.

On the basis of visual examination, the relative intensities of actin, cytokeratin, desmin and vimentin immunoreactions were designated as absent (-), weak (+), moderate (2+) and strong (3+).

## RESULTS

The relative intensities of  $\alpha$ -smooth muscle actin ( $\alpha$ -SMA) MF, cytokeratin, desmin and vimentin IFs in the capsule and the parenchyma of both the mature and the immature abdominal and scrotal testes of WADGs are shown in Table 1. Generally, the cytoplasm of Sertoli cells was immunonegative for  $\alpha$ -SMA MF, cytokeratin and desmin IFs.

### *Actin microfilament ( $\alpha$ -SMA MF)*

Immunoreaction to  $\alpha$ -SMA MF was very weak to strong throughout the testicular capsule of the mature and immature testes, irrespective of the location of the testis (Table 1, Figs. 1 and 2). The  $\alpha$ -SMA MF was moderately immunoreacted in the tunica serosa and the outer layer of tunica albuginea of the mature scrotal testis (Fig. 1). The localization of  $\alpha$ -SMA MF in the tunica serosa and tunica

Table 1. Summary of the relative intensities of the immunoreaction of cytoskeletal proteins in the testicular capsule and parenchyma of the West African Dwarf Goat.

	Mature scrotal	Mature abdominal	Immature scrotal	Immature abdominal
Outer layer of t. albuginea	a(2+); c(-/+); d(2+/3+); v(-)	a(-/+); c(-); d(-); v(-)	a(+2+); c(2+); d(3+); v(-)	a(+2+); c(2+); d(2+); v(-/+) <sup>†</sup>
Inner layer of t. alb. /t. vascul.	a(3+);c(2+); d(2+/3+); v(-)	a(-/+); c(-); d(-); v(-)	a(+2+); c(2+); d(3+); v(-)	a(+3+);c(2+/3+); d(3+); v(-/+) <sup>†</sup>
Capsular blood vessels	a(3+)*; c(-); d(-); v(-)	a(3+)*; c(-); d(-); v(-)	a(3+); c(-); d(-/+); v(-/+)	a(3+); c(-); d(-); v(-/+)
Peritubular muscle cell layer	a(3+); c(-); d(3+); v(-)	a(2+/3+); c(-); d(-); v(-)	a(3+); c(2+) d(3+); v(3+)	a(3+); c(2+/3+) d(3+); v(-)
Interstitial tissue	a(+2+); c(2+/3+); d(+2+)*; v(+2+)	a(-); c(-); d(-); v(- /+)	a(-/+)*; c(2+/3+); d(+2+)*; v(+2+)	a(-2+); c(-2+); d(2+/3+); v(-/+)
Perinuclear (Sertoli cell)	a(-); c(-); d(-); v(+3+)	a(-); c(-); d(-); v(2+)**	a(-); c(-); d(-) v(3+)	a(-); c(-); d(-) v(3+)***

albuginea in the immature scrotal testis varied from weak to moderate (Fig. 2). The tunica vasculosa as well the inner layer of the tunica albuginea of the mature and immature scrotal testes showed strong and variably moderate  $\alpha$ -SMA MF immunoreactions, respectively (Figs. 1 and 2). However, the mural elements of the capsular blood vessels in both the mature and immature scrotal testes were uniformly and strongly immunopositive.

The tunica serosa as well as the outer layer of the tunica albuginea of both the mature and immature abdominal testes showed varying intensities of  $\alpha$ -SMA MF (Table 1, Figs. 1 and 2). Negative to very weak immunoreactions were observed in the tunica serosa and the outer layer of the tunica albuginea in the mature abdominal testes while the same tunica in immature abdominal testis showed weak to moderate immunoreactivities (Table 1, Figs. 1 and 2). The  $\alpha$ -SMA MF was very distinctly

and highly uniformly immunolocalized in the mural elements of the capsular blood vessels of the immature abdominal testis. The mural elements in the capsular blood vessels of the mature abdominal testes, however, showed strands of fibres that were very strongly immunopositive for  $\alpha$ -SMA MF.

The immunolocalization of  $\alpha$ -SMA MF in the testicular parenchyma of the mature and immature abdominal and scrotal testes is shown in Table 1 and Figures 1 and 2. Smooth muscle actin was very strongly/distinctly immunolocalized in the seminiferous peritubular boundary tissues of both the mature and immature scrotal and abdominal testes (Table 1, Figs. 1 and 2), the intensity of immunostaining being higher in the immature abdominal testis than that of the mature abdominal testis. In addition, smooth muscle actin was weakly to moderately immunolocalized in the interstitial tissue of the mature

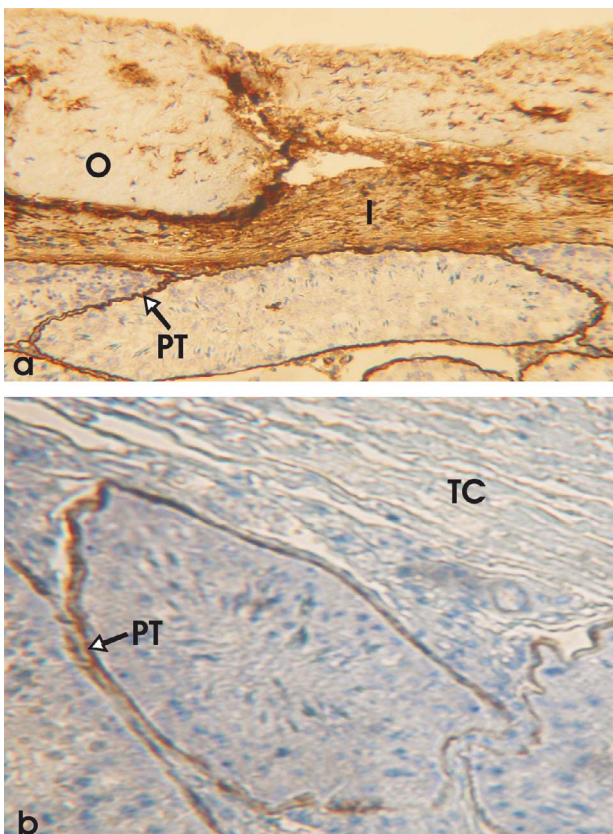


Fig. 1. The testis of mature West African Dwarf Goats immunostained for  $\alpha$ -smooth muscle actin. (a) Scrotal testis showing seminiferous peritubular tissue (PT) and inner zone (I) of the testicular capsule with strong actin immunoreaction. The outer zone of the testicular capsule (O) exhibits weak-to-moderate immunopositivity. (b) Abdominal testis, showing PT with moderate immunostaining and a testicular capsule (TC) devoid of immunoreaction.  $\times 100$ .

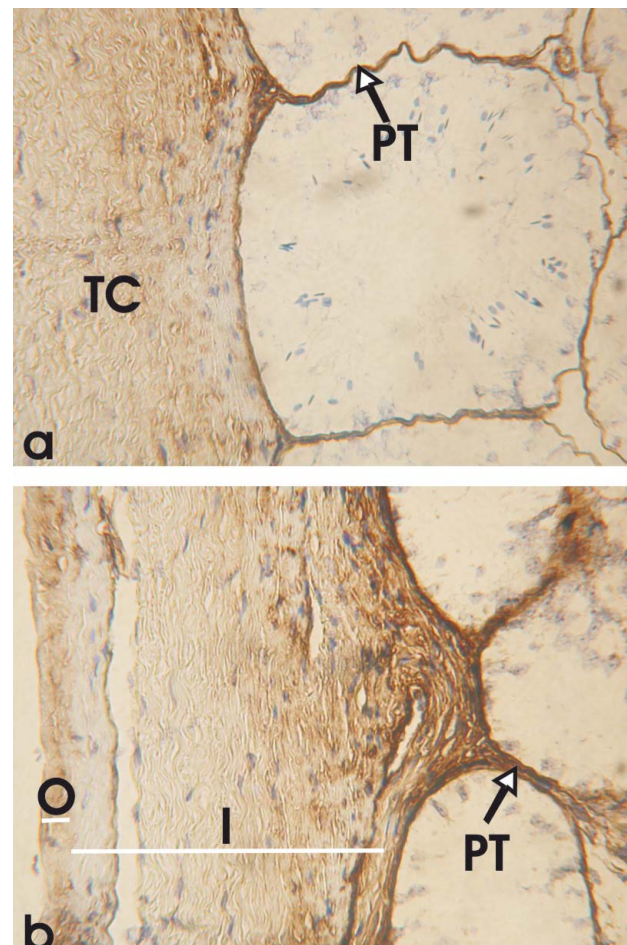


Fig. 2. Inner (I) and outer (O) zones of the testicular capsule (TC) and seminiferous peritubular tissue (PT) of immature West African Dwarf Goats immunostained for  $\alpha$ -smooth muscle actin. (a) Scrotal testis showing strongly immunostained PT and moderately stained TC. (b) Abdominal testis showing strongly immunostained PT and variably immunopositive I and O.  $\times 100$ .

scrotal testes. However, negatively and/or weakly immunostained strands of  $\alpha$ -SMA MF were observed in the interstitial tissue of the immature scrotal testes, unlike the immature abdominal testes with uniformly negative to moderate immunopositivities for  $\alpha$ -SMA MF. There was, however, no observable immunoreactive  $\alpha$ -SMA MF in the interstitial tissue of the mature abdominal, as shown in Figure 1.

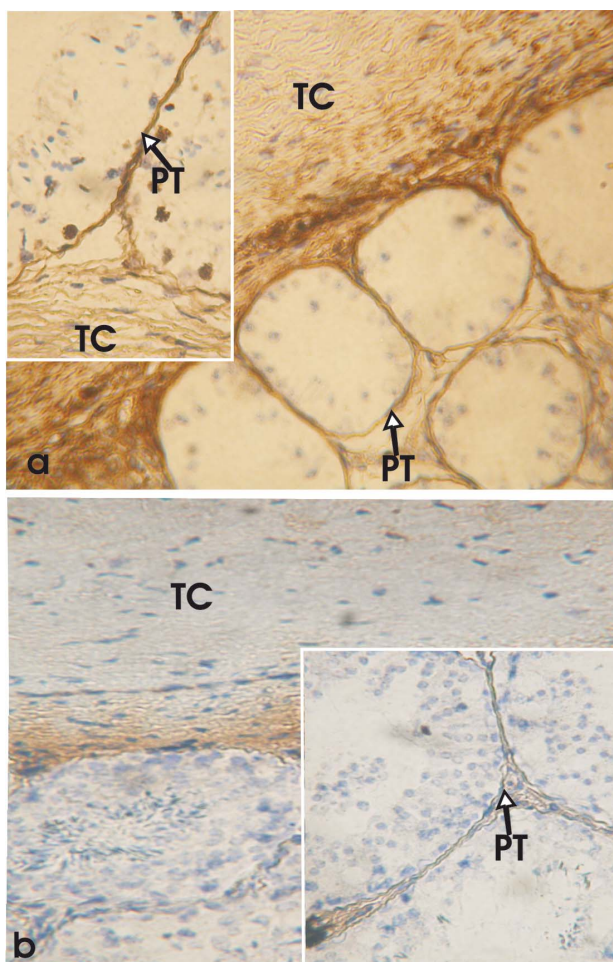
#### *Cytokeratin intermediate filaments (IF)*

Remarkable variations in the intensity of the immunoexpression of cytokeratin IF were observed in the capsule of the four groups of testes under study (Fig. 3 and Table 1). However, the mural elements of the capsular blood vessels in all testes were uniformly immunonegative for cytokeratin IF.

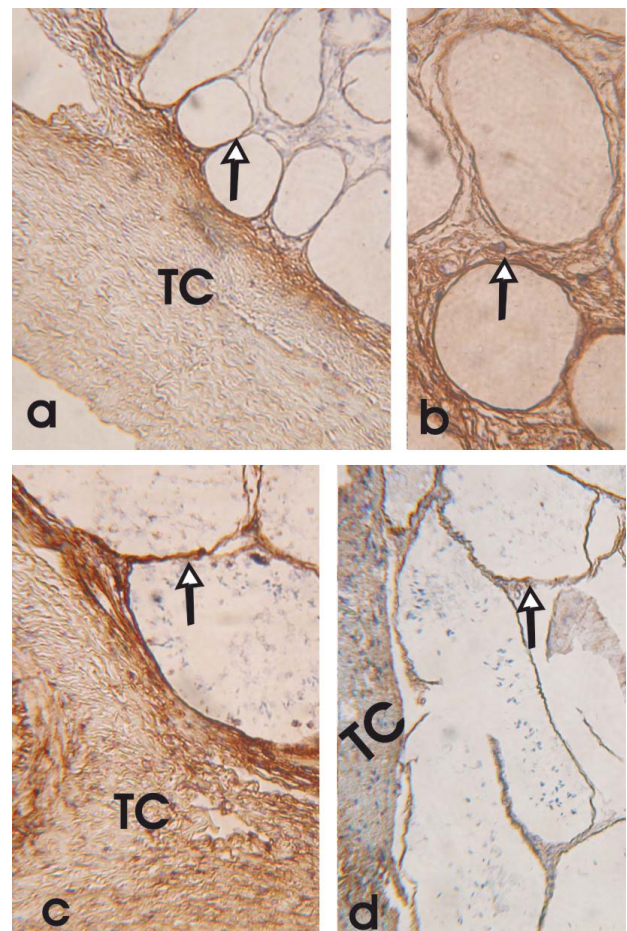
The tunica serosa and the outer layer of the tunica albuginea of the mature scrotal testes

showed a negative to weak immunoreaction for cytokeratin IF. Both layers were, however, uniformly and moderately immunopositive for cytokeratin IF in the immature scrotal. Although the tunica vasculosa and the inner layer of the tunica albuginea of the mature and immature scrotal testes were immunopositive for cytokeratin IF, the mature scrotal testes exhibited a more intense reactivity than that observed in the immature scrotal testes (Table 1 and Fig. 3).

The tunica serosa, tunica albuginea and tunica vasculosa were immunonegative for cytokeratin IF in the mature abdominal testes. The immature abdominal testes, however, showed a moderate to strong immunolocalization of cytokeratin IF, the tunica vasculosa and the inner zone of the tunica albuginea being more intensely immunopositive than



**Fig. 3.-** Testicular capsule (TC) and seminiferous peritubular tissue (PT) of immature (a) and mature (b) testes immunostained for cytokeratin. (a) The PT of immature scrotal (Inset) and abdominal testes showing moderate immunopositivity. The tunica vasculosa of the TC (abdominal testis) showing strong immunopositive reaction. (b) Mature scrotal testis showing variably immunostained PT (Inset) and TC.  $\times 100$ .



**Fig. 4.-** Testicular capsule (TC) and seminiferous peritubular tissue (arrow) of the West African Dwarf Goats immunostained for desmin. The TC and/or seminiferous peritubular tissue (arrow) of (a; b) immature abdominal, (c) immature scrotal and (d) mature scrotal testes showing immunopositive reactions for desmin.  $\times 100$ .

the tunica serosa and the outer zone of the tunica albuginea (Fig. 3 and Table 1).

The seminiferous peritubular boundary tissues of the mature (scrotal) as well as immature (scrotal and abdominal) were immunopositive for cytokeratin IF. Cytokeratin IF was, however, very strongly immunolocalized in the seminiferous peritubular boundary tissue of the immature abdominal testes (Fig. 3 and Table 1).

Cytokeratin IF was moderately immunolocalized in the interstitial tissues of both mature and immature scrotal testes. There was no observable immunoreaction of cytokeratin in the interstitial tissue of mature abdominal testes. The interstitial tissue of immature abdominal testes was, however, negatively to moderately immunopositive for cytokeratin (Fig. 3 and Table 1).

*Desmin intermediate filaments (IF)*

Desmin IF was strongly immunolocalized in the capsules as well as in the seminiferous peritubular boundary tissues of both imma-

ture and mature scrotal testes (Fig. 4, Table 1). Immunoreaction to desmin was absent in the mural elements of the capsular blood vessels of mature scrotal testes. However, the mural elements of the capsular blood vessels of immature scrotal testes were negatively to moderately immunostained for desmin.

There was no observable immunoreaction to desmin in the mature abdominal testes. The mural elements of the capsular blood vessels in the immature abdominal testes were also immunonegative for desmin. The desmin immunoreaction was, however, moderate and/or very strong throughout the tunics, the seminiferous peritubular boundary tissue and the interstitial tissue of immature abdominal testes (Fig. 4 and Table 1). Weak and/or moderately immunopositive strands of desmin were observed in the interstitial tissues of both mature and immature scrotal testes.

*Vimentin intermediate filaments (IF)*

Vimentin immunoreaction was absent in all the tunics (tunica serosa, tunica albuginea

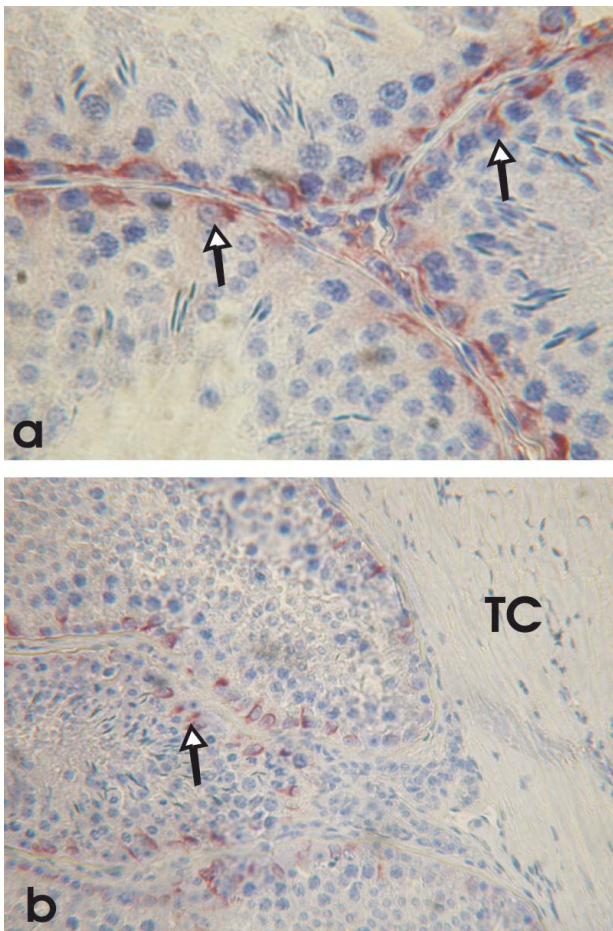


Fig. 5.- Mature scrotal (a) and mature abdominal (b) testes of West African Dwarf Goats immunostained for vimentin showing immunopositive Sertoli cells (arrows) and an immunonegative testicular capsule (TC). (a)  $\times 400$ ; (b)  $\times 100$ .

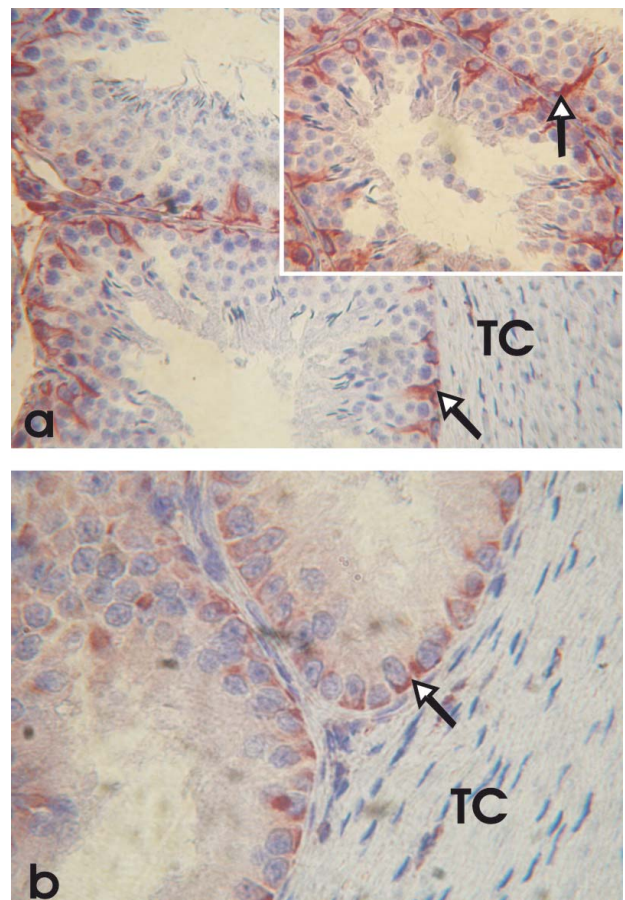


Fig. 6.- Immature scrotal (a) and abdominal (b) testes of West African Dwarf Goats immunostained for vimentin showing immunopositive Sertoli cells (arrows). Inset: Immature scrotal testis ( $\times 200$ ). TC = testicular capsule. (a) and (b)  $\times 100$ .

and tunica vasculosa), the mural elements of the capsular blood vessels and the seminiferous peritubular boundary tissue of the mature scrotal testes (Fig. 5). Neither was vimentin observed in the capsule of the immature scrotal testes, except for some weakly stained strands along the capsular blood vessels (Table 1). The seminiferous peritubular boundary tissue as well as the interstices of the immature scrotal testes were moderately to strongly immunopositive for vimentin (Fig. 6 and Table 1).

There was no observable Vimentin IF in the capsule or the seminiferous peritubular boundary tissue of the mature abdominal testes. However, negatively and/or weakly immunopositive vimentin IF was observed in the interstitium of the mature abdominal testes (Fig. 5). The capsule and the parenchyma of the immature abdominal testes showed negative and/or weak to moderate vimentin immunoreexpression (Fig. 6, Table 1).

Vimentin IF was variably immunoreexpressed in the cytoplasm of the Sertoli cells of both the mature and immature testes, as shown in Table 1 and Figures 5 and 6. A weak and/or strong vimentin immunoreexpression was observed in the cytoplasm of the Sertoli cells of both the mature and immature scrotal testes. The Sertoli cells of the immature scrotal testes, however, showed more immunopositive vimentin IF at their basolateral borders than that observed in the basolateral borders of the mature scrotal testes (Figs. 5a and 6a, and Table 1). Vimentin immunoreexpression was also very strong at the basolateral borders of the Sertoli cells in the immature abdominal testis, unlike the faint and moderate immunostaining observed in the mature abdominal testes.

## DISCUSSION

Smooth muscle cells of the capsule and the peritubule of WADGs exhibited variable degrees of actin immunoreactivity. The capsules of mature scrotal and immature abdominal testes were more intensely immunostained than those of immature abdominal testes, which in turn were more immunopositive than those of mature abdominal testes. Smooth muscle actin is abundant in the testicular capsule of the rat (Maekawa et al., 1991; 1995), monkey (Schlatt et al., 1993) and the

emu and ostrich (Ozegbe et al., 2008). The observation that SMA was more intensely immunolocalized in the tunica vasculosa and the inner layer of the tunica albuginea of mature scrotal and immature abdominal testes of WADGs confirms an earlier report by Ozegbe et al. (2008) in the ratite birds.

The Sertoli cells of all the WADGs used in this study immunoreexpressed variable intensities and localizations of vimentin intermediate filament, depending on the age of the animal and the location of the testis. Similar observations have been reported in the cryptorchid porcine (Loose et al., 2002) and in the postnatally developing bovine (Devkota et al., 2006a). The Sertoli cells were immunonegative for  $\alpha$ -smooth muscle actin microfilaments, cytokeratins and desmin intermediate filaments. This confirms the earlier report of Steger and Wrobel (1994) and Devkota et al. (2006a, b) in the ovine and bovine, respectively. Rogatsch et al. (1996) and Zhang et al. (2004), however, reported that the Sertoli cells of both spontaneous and the experimentally-induced cryptorchid testes of humans and rhesus monkeys, respectively, co-expressed vimentin, desmin and cytokeratins.

The tunica albuginea of men (Arenas et al., 1997) and birds (Aire and Ozegbe, 2007; Ozegbe et al., 2008; 2012) present myoid and fibroblast-like cells. Lazarides (1980) reported that many mesenchyme-derived cells, including fibroblasts, muscle cells, endothelial cells, microglial cells, and chondroblasts contain vimentin intermediate filaments. The observed vimentin immunonegative reaction in the smooth muscle cell layers of the capsule (mature abdominal and scrotal, and immature scrotal) and the peritubule (mature abdominal and scrotal, and immature abdominal) of the testes of WADGs is similar to that reported in the ostrich and masked weaver bird (Ozegbe et al., 2008; 2012) but contrary to the observations made in the adult ram and bull (Steger et al., 1994), humans (Arenas et al., 1997), quail and the emu (Aire and Ozegbe 2007; Ozegbe et al., 2008).

The moderate to strong immunoreexpression of desmin in the peritubular tissue (mature and immature scrotal testes) and/or co-expression of cytokeratin and desmin by the testicular capsule (mature and immature scrotal, and immature abdominal testes), peritubular tissue (immature abdominal testes) and the interstitium (mature and immature scrotal,

and immature abdominal testes) of WADGs is contrary to the observation of Steger and Wrobel (1994) that desmin vanishes completely in the ovine testis as soon as animals reach puberty. Thus, the immunoexpressions of desmin in the caprine scrotal testes may be peculiar and not age-related.

## REFERENCES

- AIRE TA, OZEGBE PC (2007) The testicular capsule and peritubular tissue of birds: morphometry, histology, ultrastructure and immunohistochemistry. *J Anat*, 210: 731-740.
- ARENAS MI, BETHENCOURT FR, FRAILE B, PANIAGUA R (1997) Immunocytochemical and quantitative study of the tunica albuginea testis in young and ageing men. *Histochem Cell Biol*, 107: 469-477.
- AUMÜLLER G, STEINBRÜCK M, KRAUSE W, WAGNER H-J (1988) Distribution of vimentin-type intermediate filaments in Sertoli cells of the human testis, normal and pathologic. *Anat Embryol*, 178: 129-136.
- BANKS FCL, KNIGHT GE, CALVERT RC, TURMAINE M, THOMPSONCS, MIKHAILIDIS DP, MORGAN RJ, BURNSTOCK G (2006) Smooth muscle and purinergic contraction of the human, rabbit, rat, and mouse testicular capsule. *Biol Reprod*, 74: 473-480.
- BAUMANN V, DIJKSTRA G, WENSING CJG (1981) Testicular descent in the dog. *Anat Histol Embryol*, 10: 97-110.
- DE MIGUEL MP, BETHENCOURT FR, ARENAS MI, FRAILE B, PANIAGUA R (1997) Intermediate filaments in the Sertoli cells of the ageing human testis. *Virchows Arch*, 431: 131-138.
- DEVKOTA B, SASAKI M, MATSUI M, AMAYA-MONTOYA C, MIYAKE Y-I (2006a) Alterations in the immunohistochemical localization patterns of  $\alpha$ -smooth muscle actin (SMA) and vimentin in the postnatally developing bovine cryptorchid testis. *J Reprod Dev*, 52: 329-334.
- DEVKOTA B, SASAKI M, TAKAHASHI KI, MATSUZAKI S, MATSUI M, HANEDA S, TAKAHASHI M, OSAWA T, MIYAKE Y-I (2006b) Postnatal developmental changes in immunohistochemical localisation of  $\alpha$ -smooth muscle actin (SMA) and vimentin in bovine testes. *J Reprod Dev*, 52: 43-49.
- DYCE KM, SACK WO, WENSING CJG (2002) The Urogenital Apparatus. In: *Textbook of Veterinary Anatomy*. 3<sup>rd</sup> Edition, Saunders, Philadelphia, pp 166-209.
- EZEASOR DN (1985) Light and electron microscopical observations on the Leydig cells of the scrotal and abdominal testes of naturally unilateral cryptorchid West African dwarf goats. *J Anat*, 141: 27-40.
- FELL HB (1923) A histological study of the testis in cases of pseudo-intersexuality and cryptorchism with special reference to the interstitial cells. *Q J Exp Physiol*, 13: 145-158.
- GALL C (1996) *Goat Breeds of the World*. CTA/Margraf Verlag, Weikersheim, Germany.
- HARGROVE JL, MACINDOE JH, ELLIS LC (1977) Testicular contractile cells and sperm transport. *Fertil Steril*, 28: 146-157.
- HOCHEREAU-DE REVIERS M-T, BLANC MR, CAHOREAU C, COUROT M, DACHEUX JL, PISSELET, C (1979) Histological testicular parameters in bilateral cryptorchid adult rams. *Ann Biol Anim Bioch Biophys*, 19 (4A): 1141-1146.
- IGBOKWE IO, GREMA HA, IKPO AE, MSHELBWALA FM, IGBOKWE NA (2009) Unilateral cryptorchidism in Nigerian sahel bucks. *Int J Morphol*, 27: 805-810.
- LAZARIDES E (1980) Intermediate filaments as mechanical integrators of cellular space. *Nature*, 283: 249-256.
- LOOSE H, AUPPERLE H, SCHNURRBUSCH U, SCHOON HA (2002) Morphological and immunohistochemical studies in testes of normal and cryptorchid boars. *Berl Münch Tierärztl Wochenschr*, 115: 407-411.
- MAEKAWA M, KAZAMA H, KAMIMURA K, NAGANO T (1995) Changes in the arrangement of actin filaments in myoid cells and Sertoli cells of rat during postnatal development and after experimental cryptorchidism. *Anat Rec*, 241: 59-69.
- MAEKAWA M, NAGANO T, KAMIMURA T, ISHIKAWA H, DEZAWA M (1991) Distribution of actin-filament bundles in myoid cells, Sertoli cells, and tunica albuginea of rat and mouse testes. *Cell Tissue Res*, 266: 295-300.
- MARETTA M, MARETTOVA E (2004) Immunohistochemical demonstration of myoid cells in the testis and its excurrent ducts in the domestic fowl. *Br Poult Sci*, 45: 585-589.
- MIDDENDORFF R, MULLER D, MEWE M, MUKHOPADHYAY AK, HOLSTEIN AF, DAVIDOFF MS (2002) The tunica albuginea of the human testis is characterized by complex contraction and relaxation activities regulated by cyclic GMP. *J Clin Endocrinol Metab*, 87: 3486-3499.
- OZEGBE PC, AIRE TA, MADEKUROZWA M-C, SOLEY JT (2008) Morphological and immunohistochemical study of the testicular capsule and peritubular tissue of the emu (*Dromatus novaehollandiae*) and ostrich (*Struthio camelus*). *Cell Tissue Res*, 332: 151-158.
- OZEGBE PC, AIRE TA, DEOKAR M (2012) The cytoskeletal proteins in the contractile tissues of the testis and its excurrent ducts of the passerine bird, Masked Weaver (*Ploceus velatus*). *Tissue Cell*, 44: 22-31. doi:10.1016/j.tice.2011.10.002
- ÖZYIĞIT G (2007) Left abdominal cryptorchidism in a native Goat. *Turk J Vet Anim Sci*, 31: 419-421.
- PINART E, BONET S, BRIZ M, PASTOR LM, SANCHO S, GARCÍA N, BADIA E, BASSOLS J (2001) Morphological and histochemical characteristics of the lamina propria in scrotal and abdominal testes from postpubertal boars: correlation with the appearance of the seminiferous epithelium. *J Anat*, 199: 435-448.
- PINART E, SANCHO S, BRIZ M, BONET S (1999) Morphologic study of the testes from spontaneous unilateral and bilateral abdominal cryptorchid boars. *J Morphol*, 239: 225-243.
- PINART E, SANCHO S, BRIZ MD, BONET S, GARCIA N, BADIA E (2000) Ultrastructural study of the boar seminiferous epithelium: changes in cryptorchidism. *J Morphol*, 244: 190-202.
- RODRÍGUEZ A, ROJAS MA, BUSTOS-OBREGON E, URQUIETA B, REGADERA J (1999) Distribution of keratins, vimentin, and actin in the testis of two South American Camelids: Vicuña (*Vicugna vicugna*) and Llama (*Lama glama*). An immunohistochemical study. *Anat Rec*, 254: 330-335.
- ROGATSCH H, JEZEK D, HITTMAIR A, MIKUZ G, FEICHTINGER H (1996) Expression of vimentin, cytokeratin, and desmin in Sertoli cells of human fetal cryptorchid, and tumour-adjacent testicular tissue. *Virchows Arch*, 427: 497-502.
- SASAKI M, ENDO H, KIMURA J, RERKAMNUAYCHOKE W, HAYAKAWA D, BHUMINAND D, KITAMURA N, FUKUTA K (2010) Immunohistochemical localization of the



- cytoskeletal proteins in the testes of the lesser mouse deer (*Tragulus javanicus*). *Mammal Study*, 35: 57-64.
- SCHLATT S, WEINBAUER GF, ARSLAN M, NIESCHLAG E (1993) Appearance of  $\alpha$ -smooth muscle actin in peritubular cells of monkey testes is induced by androgens, modulated by follicle-stimulating hormone, and maintained after hormonal withdrawal. *J Androl*, 14: 340-350.
- STEGER K, WROBEL K-H (1994) Immunohistochemical demonstration of cytoskeletal proteins in the ovine testis during postnatal development. *Anat Embryol*, 189: 521-530.
- STEGER K, SCHIMMEL M, WROBEL K-H (1994) Immunohistochemical demonstration of cytoskeletal proteins in seminiferous tubules of adult rams and bulls. *Arch Histol Cytol*, 57: 17-28.
- VAN STRAATEN HWM, WENSING CJG (1977) Histomorphometric aspects of testicular morphogenesis in the naturally unilateral cryptorchid pig. *Biol Reprod*, 17: 473-479.
- VYAS S, RAI AK, KHANNA ND (1996) Case report of bilateral cryptorchidism in Bikaneri camel. *Indian Vet J*, 73: 1080-1081.
- WANG ZQ, WATANABE Y, TOKI A, ITANO, T (2002) Altered distribution of Sertoli cell vimentin and increased apoptosis in cryptorchid rats. *J Paediatr Surg*, 4: 648-652.
- ZHANG Z, HU Z-Y, SONG X-X, XIAO L-J, ZOU R-J, HAN C-S, LIU Y-X (2004) Disrupted expression of intermediate filaments in the testis of rhesus monkey after experimental cryptorchidism. *Int J Androl*, 27: 234-239.
- ZHU L-J, ZONG S-D, PHILLIPS DM, MOO-YOUNG AJ, BARDIN CW (1997) Changes in the distribution of intermediate filaments in rat Sertoli cells during the seminiferous epithelium cycle and postnatal development. *Anat Rec*, 248: 391-405.