

# A duplication of the cystic duct – case report

Sharmila Aristotle, Christilda F. Jebakani

Department of Anatomy, SRM University and SRM Medical College Hospital and Research Institute, Kattankulathur, Kancheepuram dt., 603203 Tamilnadu, India

## SUMMARY

Extrahepatic biliary system presents with numerous variations. Anatomical knowledge of the cystic duct, common hepatic duct, common bile duct and the surrounding vessels is necessary to avoid iatrogenic ductal injuries and inadvertent complications during biliary surgery. This study reports the presence of duplicated cystic duct in a fifty-year old male cadaver. The gallbladder in this case was single and not duplicated. The additional cystic duct was observed to arise from the neck of the gallbladder just above and parallel to the normal cystic duct. It terminated into the main cystic duct itself.

The normal cystic duct also originated from the neck of gall bladder and descended down and joined with the common hepatic duct to form the common bile duct. The vessels related to this biliary ductal system namely the proper hepatic artery and the portal vein were found to be situated normally within the hepatoduodenal ligament.

**Key words:** Duplication of cystic duct – Extrahepatic biliary system – Gall bladder

## INTRODUCTION

Double cystic duct is usually associated with double gallbladder. Though variations

and anomalies of the components of the hepatobiliary system are frequently reported in literature such as duplication of cystic duct with simultaneous occurrence of double gall bladder, supernumerary cystic duct occurring with single gallbladder has been scarcely documented. The various types of duplicated cystic ducts reported are (a) the *Y type*-two cystic ducts meet to form a common channel, (b) *H type*-accessory cystic duct enters separately into right, left or common hepatic duct, and (c) *Trabecular type*-accessory cystic duct enters the substance of liver directly (Huston and Dakin, 2008). Failure to identify these anomalies leads to serious morbidity and mortality resulting from inadvertent iatrogenic injuries (Lamah et al., 2001). Hence correct interpretation of preoperative cholangiogram is necessary for the correct diagnosis and treatment in a scenario that presents with the condition as stated above (Causey et al., 2010).

## CASE REPORT

This variation was noted in a fifty year old male cadaver while doing routine abdominal dissection for undergraduate students. The gallbladder was identified and found to be single and not duplicated. Cystic duct arose from the neck of gallbladder, descended down and joined the common hepatic duct. The right

Correspondence to:  
Dr. A. Sharmila. SRM Medical College Hospital and Research Institute, SRM University, Dept. of Anatomy, Kattankulathur, Kancheepuram dt., 603203 Tamilnadu, India. Phone: +919790807674. E-mail: drsharmiaris@gmail.com

Submitted: April 12, 2011  
Accepted: August 19, 2011

and left hepatic ducts united intrahepatically to form the common hepatic duct. The common bile duct was normal in its anatomy. Apart from this we also observed a duplicated cystic duct. It arose from the neck of gallbladder just above the normal cystic duct. This duplicated cystic duct ran parallel to and drained into the cystic duct itself. The other related structures namely the portal vein and proper hepatic artery which were present in the hepatoduodenal ligament were found to be normal and no variations were noted in them (Fig. 1).

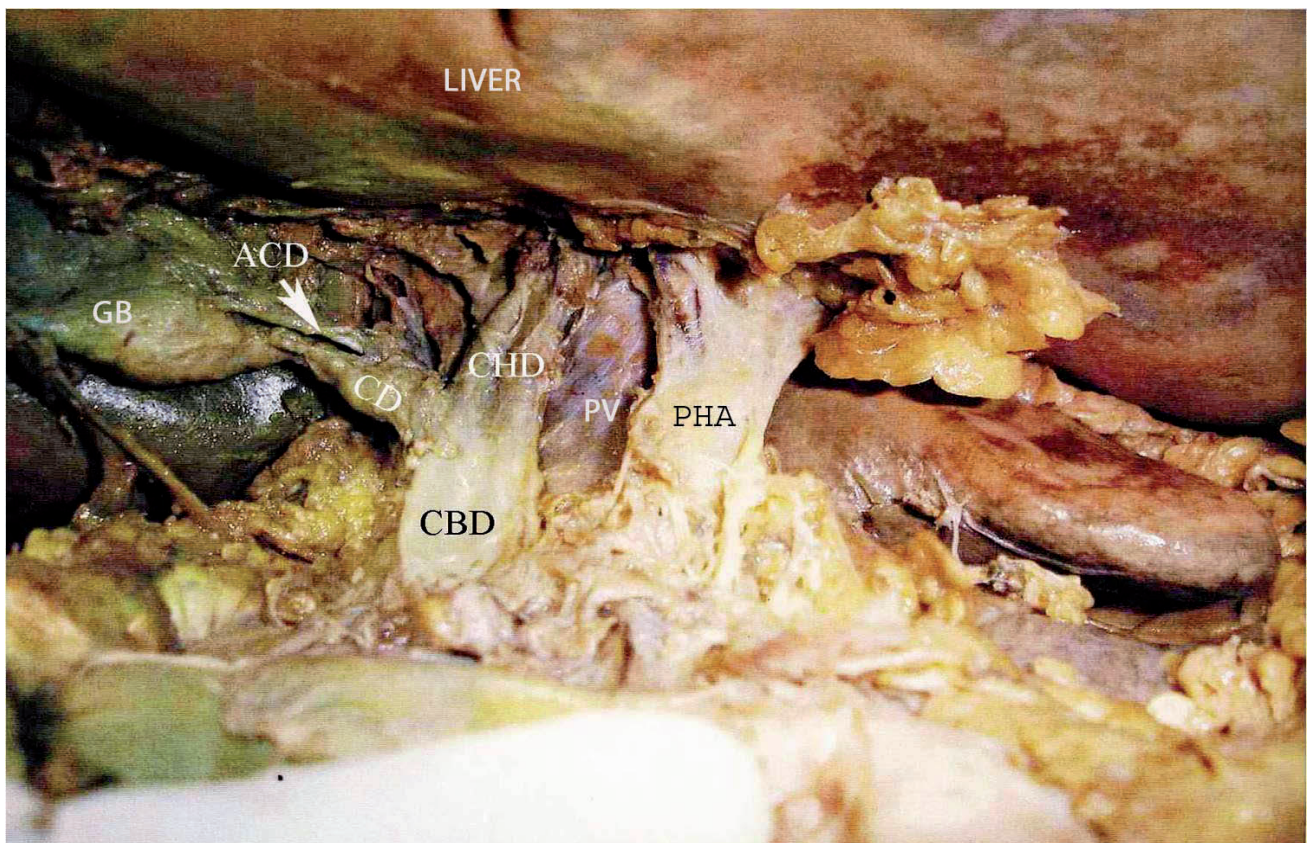
## DISCUSSION

During the fourth week of embryological development, the liver, gallbladder and the extra hepatic biliary tree arises from the hepatic diverticulum of foregut. This diverticulum rapidly proliferates into the septum transversum and divides into pars cystica and pars hepatica. At the time of appearance of the pars cystica the cells at the junction of the hepatic and cystic ducts proliferate to form the common bile duct. The embryogenesis of this case is initially the gallbladder is a hollow organ, but as a result of proliferation of its epithelial

lining it becomes temporarily solid. Formation of the definitive lumen (recanalisation) occurs by vacuolation of the epithelium (Kaushik and Atrri, 2005). Any departure from the normal sequence or pattern of events in the biliary tract embryology results in the formation of duplicated bile ducts.

Persistence of foetal connection between the liver and gallbladder or the extrahepatic ductal system leads to the formation of accessory bile ducts. Developmental anomalies of the extra-hepatic biliary system present varying incidence rates in the population ranging from 9-28% (Klotz et al., 1992).

The commonly occurring cystic duct variations can be summed up as situations presenting: (a) Low union of cystic duct, cystic and common hepatic duct are parallel, insertion of cystic duct into the right and left hepatic ducts (Lamah et al., 2001); (b) drainage of cystic duct directly into the liver, anterior and posterior spiral types of opening of cystic duct on the left side of common hepatic duct; (c) Parahepatic duct termination into the cystic duct, absence or short cystic duct (length <5mm), double cystic duct Bernard et al., 2001), right hepatic duct emptying into cystic duct (Hashimoto et al., 2002); (d) hepatic-



**Fig. 1.** Figure shows the small accessory duct originating from the neck of gallbladder and draining into the cystic duct. Note the position of the accessory duct above and parallel to the main duct. GB: gallbladder; CD: cystic duct; ACD: accessory cystic duct; CHD: common hepatic duct; PV: portal vein; PHA: proper hepatic artery; CBD: common bile duct.

ocystic duct, a rare congenital anomaly in which the common hepatic duct enters the gallbladder; the left, right and common hepatic ducts are all defective with cystic duct draining the entire biliary system into the duodenum (Losanoff et al., 2002).

In a normal circumstance, the cystic duct arises from the neck of gallbladder and joins with the common hepatic duct to form the common bile duct. The standard relationship between the cystic duct, extrahepatic biliary ducts and related arteries is present only in 33% of cases. The duplicated cystic duct as mentioned above is classified into 3 types. In our case the accessory cystic duct entered directly into the cystic duct itself and doesn't come in any of this classification.

According to Nakasugi et al. (1995) the two cystic ducts led separately from the gallbladder they combined into a single duct and drained into the common bile duct. Other authors classified the common biliary variations that may give the appearance of a double duct as follows: Drainage of segment V1 into the cystic duct, drainage of the right posterior sector duct into the cystic duct, drainage of the distal right posterior sector duct into the neck of gallbladder and drainage of the proximal right posterior sector duct into the body of gallbladder (Huston and Dakin, 2008).

Lamah et al. (2001) reported 12 surgically significant anatomical variations, in which they encounter double cystic duct in a single specimen and abnormal termination of cystic duct into the right hepatic and left hepatic ducts. They also noted absence of cystic duct and accessory bile ducts in a retrospective study of per-operative cholangiogram in 2080 cases.

The present case describes a rare condition where the cystic duct is duplicated as an additional conduit above the normal duct with a 'normal' commencement and termination. It is important to register the possibility of such variation in the duct system in isolation, with-

out any duplication of the gall bladder. The prior knowledge of the presence of such variation would not only prevent any inadvertent injury to the accessory duct at surgery, but it also would be helpful for the post-operative wound drainage management in such cases.

### Conclusion

Starting from cholecystectomy to living donor liver transplantation with duct to duct anastomosis, grading of tumours like hilar cholangiocarcinoma and investigations like magnetic resonance cholangiopancreatography (MCRP), it is imperative to have the definitive knowledge of both normal and variational ductal anatomy. It is thus, the anticipation of the probable existence of such bile duct variation that serves as the most important factor in preventing iatrogenic bile duct injuries.

### REFERENCES

- BERNARD P, LETESSIER E, DENIMAL F, LENEEL JC (2001) Accessory cystic duct discovered by intraoperative cholangiography during cholecystectomy. *Ann Chir*, 126: 1020-1022.
- CAUSEY MW, MILLER S, FERNELIUS CA, BURGESS JR, BROWN TA, NEWTON C (2010) Gallbladder duplication: evaluation, treatment, and classification. *J Paediatric Surg*, 45: 443-446.
- HASHIMOTO M, ISHIKAWA T, LIZUKA T, MATSUDA M, WATANABE G (2002) Right hepatic duct emptying into the cystic duct: report of a case. *Surg Endosc*, 16: 359.
- HUSTON TL, DAKIN GF (2008) Double cystic duct. *Can J Surg*, 51: 9-10.
- KAUSHIK R, ATRRI AK (2005) Hepaticocystic duct: A case report. *Internet J Surg*, 6: 1.
- KLOTZ HP, SCHLUMPF R, LARGIADER F (1992) Injury to an accessory bile duct during laparoscopic cholecystectomy. *Surg Laparosc Endosc*, 2: 317-320.
- LAMAH M, KARANJIA ND, DICKSON GH (2001) Anatomical variations of the extrahepatic biliary tree: review of the world literature. *Clin Anat*, 14: 167-172.
- LOSANOFF JE, JONES JW, RICHMAN BW, RANGNEKAR NJ (2002) Hepaticocystic duct: a rare anomaly of the extrahepatic biliary system. *Clin Anat*, 15: 314-315.
- NAKASUGI H, KOBAYASHI S, SAKAMOTO K, INAYOSHI T, MATSUMURA M, URABE M (1995) A case of double cystic duct with cholecystolithiasis treated by laparoscopy. *J Hep Pancr Surg*, 2: 68-71.