

Abnormal originating of vertebral artery in the superior mediastinum: A case report

Parvin-Dokht Bayat¹, Ali Ghanbari², Sepideh Esmaeili³,
Katayon Esmaeili⁴

1- Department of Anatomy, Arak University of Medical Sciences, Arak, Iran

2- Fertility and Infertility Research Center, Kermanshah University of Medical Sciences, Kermanshah, Iran

3- Student Research Committee, Kermanshah University of Medical Sciences, Kermanshah, Iran

4- Nursing Department, Kermanshah University of Medical Sciences, Kermanshah, Iran

SUMMARY

This study reports the anomalous origin of the left vertebral artery from the beginning of the subclavian artery at the superior mediastinum with no other variation in the pattern of the great vessels of the aortic arch. Indeed, the length of the prevertebral segment (first part) of the left vertebral artery was longer than that of right vertebral artery.

Key words: Embryology – Iran – Prevertebral segment – Variations – Vertebral Artery

INTRODUCTION

Understanding the anatomic and morphological variations of the great vessels of the aortic arch and other arterial patterns is important in both invasive and non-invasive treatment procedures (Matula et al., 1997; Quain and Maclise, 1844; Satti et al., 2007).

An abnormal origin of the right vertebral artery is rare. It occurs the right or left side with different embryonic mechanism (Chi-Jen et al., 1998). The vertebral arteries (VA) may arise: a) from the first part of the subclavian, nearer than normal to the brachiocephalic trunk (1% of cases) or to the anterior scalene

muscle; b) directly from the arch of the aorta (3% of cases); c) from the right common carotid, when the right subclavian arises from the aorta beyond the left subclavian; or d) from the brachiocephalic trunk. The right vertebral artery may pass behind the esophagus (Bergman et al., 2008).

The left vertebral artery may arise directly from the left common carotid or the root of the subclavian, close to the aortic arch (Chi-Jen et al., 1998). It may arise from the arch of the aorta (Jayanthi et al., 2010). There are occasionally two left vertebral arteries. In one such case, one arose from the arch of the aorta. The other arose from the left subclavian artery in the normal position; the latter was smaller than normal (Bergman et al., 2008).

The origin of the left vertebral artery from the aorta is a very common variation (1.79%), but the origin of the vertebral artery from the right side of the arch is very rare (Bergman et al., 2008). The course of VA is divided into four segments (Matula et al., 1997; Satti et al., 2007; Chi-Jen et al., 1998). The first vertebral (V1) segment, or pre-transverse segment, extends from the subclavian artery (SCA) to its entry into the foramen of the transverse process of cervical vertebra 6 (C6). The V1 segment; the pretransverse or prevertebral segment arises from the craniodorsal, but

rarely from the caudoventral half of the SCA; it is tortuous and often describes a significant loop prior to entering the transverse foramen of C6. The significance of the V1 segment of the vertebral artery is because it is the most prone to atherosclerotic change, particularly at its origin. The second vertebral (V2) segment extends from the transverse process of C6 to where the VA exits the axis. The third vertebral (V3) segment extends from the point of exit from the axis to its entry into the spinal canal. The fourth vertebral (V4) segment is intracranial and terminates as the basilar artery (Buckenham, 2004).

In the present study, the length of the pre-vertebral segment of left artery was greater than that of right vertebral artery and the artery originated from the beginning of the left subclavian artery at the superior mediastinum.

CASE REPORT

A 70 year-old female cadaver was formalin-fixed at the Department of Anatomy at Arak University of Medical Sciences, Iran. The case presented was subjected to MR angiography (MRA). In the head and neck region and the region of the superior mediastinum, an arch arteriogram revealed the pattern of distribution of the great vessels as follows (Fig. 1).

The patent innominate artery (Brachiocephalic artery) had a normal origin from aortic arch and ascended to the right and then divided into two branches; right common carotid and right subclavian arteries.

The left subclavian artery arose from the aortic arch as a tertiary branch, after the left common carotid artery; therefore it has a normal origin (Fig. 1). It ascended into the superior mediastinum, behind the left common carotid artery and its vertebral branch arose from it immediately. The left subclavian artery ascends into the root of the neck and arches laterally (Fig. 1).

The right vertebral artery had a normal origin and coursed in the neck. It coursed superiorly through its foramina in the transverse process and magnum, and after a short course, joined the other vertebral artery to form the basilar artery.

The left vertebral artery arose from the left subclavian artery in the superior mediastinum and accordingly it did not have a

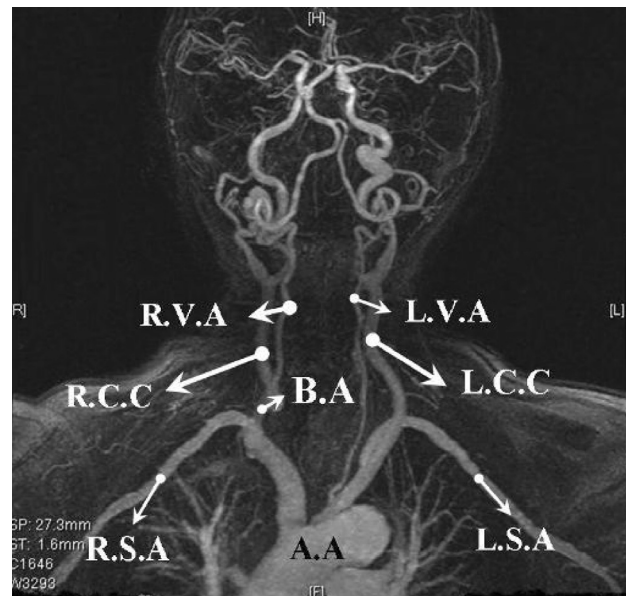


Fig. 1. Angiogram (anterior view) of the arterial distribution pattern in head and neck and superior mediastinum.

normal origin. It coursed upward into the mediastinum and was 4-5 centimeters longer than the normal position. It coursed superiorly, posterior to the left common carotid in the superior mediastinum, and ascended into the root of the neck. It coursed superiorly in the same way as the right vertebral artery.

DISCUSSION

The present study shows that because the prevertebral (first) part of the left vertebral artery is longer than usual it originates from the base of subclavian artery in the superior mediastinum.

Usually the first part of the vertebral artery develops from the proximal part of the dorsal branch of 7th cervical intersegmental artery proximal to the post-costal anastomosis. The second part is divided from longitudinal communications of the post costal anastomoses (Vorster et al., 1998). In the present case, the left sixth dorsal intersegmental artery might have persisted as the first part of the vertebral artery, and hence the left vertebral artery arises from the initial part of subclavian artery or aortic arch (Iyer, 1927). The importance of the proximal part of the segmental arteries is revealed when they are exposed to longitudinal tension and bending due to caudal shifting of the aorta, resulting in retarded blood flow and abnormal connections between the longitudinal channels (vertebral artery) and

the subclavian artery or aorta (Vorster et al., 1998).

The abnormal course of the first part of vertebral artery has been addressed previously. Panicker et al. (2002) reported a case with an anomalous origin of the left vertebral artery but with variation in the branching pattern of the subclavian artery. Another study described a case with the left vertebral artery originating from the arch of the aorta, such as in the present case, but the right vertebral artery had a dual origin, in contrast with the present case (Cavdar and Arisan, 1989). The present case with an abnormal origin of the left vertebral artery with a normal course of the right vertebral and the remainder of left one is similar to another case reported by Jayanthi et al. (2010).

The clinical importance of the prevertebral segment of the vertebral artery is that the segments are frequently affected with atherosclerosis (Vicko et al., 1999) and may be responsible of alterations in cerebral hemodynamica, an abnormal origin of the vertebral artery may favor cerebral disorders (Bernardi and Deton, 1975). Evidently, variations of all parts of the vertebral artery are important in head and neck surgery (Bernardi and Deton, 1975; Jayanthi et al., 2010; Komiyama et al., 2001; Nizanowski et al., 1982; Panicker et al., 2002; Vicko et al., 1999).

It has been shown that variations of the branches arising from the aortic arch, especially in the case of the vertebral artery, vary among ethnicities (Adachi 1928; Jayanthi et al., 2010; Lippert and Pabst, 1985; Panicker et al., 2002; Satti et al., 2007). A case in Iran revealed that the left vertebral artery with a normal origin had an unusual extracranial termination (Shoja et al., 2006). In another case there was an abnormal course of the right vertebral artery in the neck and at the level of C3 that pierced the prevertebral fascia to reach the transverse foramen of C3 (Bayat, 2010). The present report is unique for an Iranian ethnic subgroup and shows the origin of left vertebral artery in the mediastinum with the usual cervical and intracranial course. Thus, the present study, together with the above two, describes variations at all levels of the course of the vertebral arteries among the Iranian population.

Summing up, with respect to individual variations of the vertebral artery, a thorough knowledge of vertebrobasilar variations may improve the outcome of skull-base and other

head and neck operations and aid in the interpretation of imaging.

ACKNOWLEDGEMENTS

We are thankful to the staff of the radiography center of Arak for their kind cooperation.

REFERENCES

- ADACHI B (1928) Das Arterien system der Japaner, vol I. Kenkyusha, Tokyo.
- BAYAT PD (2010) Rare variation in the right vertebral artery. *J Iranian Anat Sci*, 7 (28-29): 185-188.
- BERGMAN RA, AFIF AK, MIYAHUICHI R (2008) Vertebral Arteries. Illustrated Encyclopedia of Human Anatomic Variations; Opus II: Cardiovascular System: Arteries: Head, Neck, and Thorax. A digital Library of Anatomy. <http://www.anatomyatlases.org>
- BERNARDI L, DETON P (1975) Angiographic study of a rare anomalous of the vertebral artery. *Neuroradiology*, 9: 43-47.
- BUCKENHAM TM (2004) Ultrasound of the extracranial vertebral artery. *Brit J Radiol*, 77: 15-20.
- CAVDAR S, ARISAN E (1989) Variations in the extracranial origin of the human vertebral artery. *Acta Anat*, 135: 163-178.
- CHI-JEN C, LI-JEN W, YON-CHEON W (1998) Abnormal origin of the vertebral artery from the common carotid artery. *Am J Neuroradiol*, 19: 1414-1416.
- IYER AA (1927) Some anomalies of origin of the vertebral artery. *J Anat*, 62: 121-122.
- JAYANTHI V, PRAKASH, DEVI MN, GETHANJALI BS, RAJINI T (2010) Anomalous origin of the left vertebral artery from the arch of the aorta: review of the literature and a case report. *Folia Morphol*, 69: 258-260.
- KOMIYAMA M, MORIKAWA T, NAKAJIMA H, NISHIKAWA M, YASUI T (2001) High incidence of arterial dissection associated with left vertebral artery of aortic origin. *Neurology Medical chir (Tokyo)*, 41: 8-11.
- LIPPERT H, PABST R (1985) Arterial variations in man. Classification and frequency. Bergmann Verlag, München.
- LEMKE AJ, BENNDORF G, LIEBIG T, FELIX R (1999) Anomalous origin of the right vertebral artery: review of the literature and case report of right vertebral artery origin distal to the left subclavian artery. *Am J Neuroradiol*, 20: 1318-1321.
- MATULA C, TRATTING S, TSCABITSCER M, DAY JD, KOOS WT (1997) The course of the prevertebral segment of the vertebral artery: anatomy and clinical significance. *Surg Neurol*, 47: 125-131.
- NIZANWSKI C, NOCZYNSKI E, SUNDER E (1982) Variability of origin of ramifications of the subclavian artery in human. *Folia Morphologica*, 41: 281-294.
- PANIKER HK, TARNEKAR A, DHAWANE V, GHOSH SK (2002) Anomalous origin of left vertebral artery - embryological basis and applied aspects - a case report. *J Anat Soc India*, 51: 234-235.
- QUAIN R, MACLISE J (1844) The anatomy of the arteries of the human body with its applications to pathology and operative surgery. Taylor and Walton, London.

SATTI SR, CERNIGLIA CA, KOENIGSBERG RA (2007) Cervical vertebral artery variations; an anatomic study. *AJNR*, 28: 976-980.

SHJA MM, TUBBS RS, KHAKI AA, SHOKOUI G, FARAHANI RM, MOEIN A (2006) A rare variation of the vertebral artery. *Folia Morphol*, 65: 167-170.

VICKO G, GORAN I, DAMJAN M, SANJA P (1999). Anomalous origin of both vertebral arteries. *Clin Anat*, 12: 281-284.

VORSTER W, DU PLOOY PT, MEIRING JH (1998) Abnormal origin of thoracic and vertebral arteries. *Clin Anat*, 11: 33-37.