

Maximal rotation at atlanto-axial joint: analysis of changes in mid-sagittal space within atlas vertebra

Niladri Kumar Mahato

Department of Anatomy, SRM Medical College, Kattankulathur, Kanchipuram District, Tamil Nadu, India

SUMMARY

The present study was conducted to analyse changes that may occur in the available antero-posterior dimension (behind the dens) within the ring of the atlas vertebra resulting from optimal axial rotation of the neck. Radiographs were obtained from twenty-five healthy volunteers of both sexes between the age group 25-50 years. The subjects recruited for the study were healthy individuals, with no any history of major ailments of the spine and did not show any unilateral or bilateral restriction of axial rotation at the neck. Outcome measures were evaluated by data obtained with and without axial rotation and were statistically compared for difference in means, their ratios, correlation and dependence.

The anterior (AS) as well as the posterior spaces (PS) available respectively in front of and behind the odontoid process reduced in rotation. The reduction at the PS (average .89 mm) was 4.10 % of the available space observed without rotation.

Although the reduction at the PS may not compress the spinal cord, extreme axial rotation with flexion may possibly compress the contents of the spinal canal, where atlas rings are smaller or accommodate a space-occupying lesion.

Key words: Atlanto-axial – Dens – Translation – Space occupying lesion

INTRODUCTION

Motion between the C1-C2 vertebrae has been the focus of intense research and controversy (Werne, 1957; Shapiro et al., 1973; White and Panjabi 1978; Roche et al., 2002). Movements at the C1-C2 junction (atlanto-axial joint) have been documented as moderate degrees of flexion and extension around the x axis ($\pm\theta_x$) (Werne, 1957), and extensive axial rotation ($>45^\circ$) around the y axis ($\pm\theta_y$) (Werne, 1957; Penning and Wilmink, 1987). Lateral bending at the atlanto-axial joint -i.e., rotation around the z axis ($\pm\theta_z$)- is negligible and may be associated with other movements at the neck (Werne, 1957; Zhang et al., 2006). Apart from rotatory movements around these three planes, the C1-C2 articulation also exhibits a certain degree of translatory movements. Translation in the sagittal plane ($\pm z$ axis) is limited to 2-3 mm. A greater degree of anterior translation of C1 over C2 may indicate inadequacy of the transverse ligament of the atlas (that snugly fits the odontoid process to the anterior arch of the atlas), either due to laxity or failure (Hohl and Baker, 1964). Translation at the C1-C2 junction in the coronal plane ($\pm x$ axis) is a con-

tentious issue. Apparently, an axial rotation ($\pm\theta y$) between the C1 and C2 vertebrae brings about a change in the relative position of the lateral mass of the atlas in relation to the dens (Werne, 1957; Shapiro et al., 1973). For example, if the head is turned to the left, the right lateral mass of the atlas vertebra swings forwards in an arc to move slightly antero-laterally to the dens. The distance between the right lateral mass and the dens is slightly diminished (x axis / lateral translation). Meanwhile, the left mass on the ipsilateral side of the head-turn moves backwards, postero-laterally to the dens. The distance between the dens and the left mass of the atlas is now slightly increased (x axis / lateral translation). The instantaneous axis of rotation (IAR) in C1-C2 axial rotation ($\pm\theta y$) passes through the centre of the dens (Roche et al., 2002). It is important to note that a lateral or horizontal ($\pm x$ axis) displacement of up to 4 mm between the dens and the lateral mass has been considered normal and does not indicate dislocation or subluxation at the C1-C2 joint capsule. Axial rotation ($\pm y$ axis) is also associated with a vertical translation ($\pm y$ axis) between the atlas and the axis. A vertical translation carries the atlas backwards or vertically upwards, depending on the direction of the long axis of the dens.

The mid-sagittal diameter of the ring of the atlas between its anterior and posterior arches is quite variable in its dimensions, ranging from 16-33 mm (Wolf et al., 1956). This ring accommodates from front to back, (a) the dens in the anterior 1/3rd; (b) the spinal cord in the middle 1/3rd, and (c) an empty space behind the cord in the posterior 1/3rd. This is commonly referred to as Steele's rule of thirds (Steel, 1968). This limited space within the atlas ring may become compromised in several situations. Abnormal (>3 mm) displacement between the anterior part of the dens and posterior aspect of the anterior arch of atlas may result from bilateral subluxation and bilateral anterior translatory displacement of the C1. This is a clinically unstable condition of the spine. Unilateral anterior rotatory subluxations show the lateral mass swinging antero-laterally in an arc around the dens and producing a large gap between the anterior arch of atlas and the dens (Shapiro et al., 1973). Both bilateral and unilateral anterior displacements of C1 reduce the space within the ring of the atlas (behind the dens). Excessive flexion at the atlanto-axial joint may reduce the space in the posterior 2/3rd of the

ring. Axial rotation at this joint, as mentioned earlier, is accompanied by antero-lateral displacement of the contra-lateral lateral mass and postero-lateral movement of the ipsi-lateral lateral mass. This unilateral offset of the contra-lateral mass is considered 'normal' and is associated with a minimal anterior displacement of the anterior arch with respect to the dens (Dankmeijer and Rethmeier, 1942; Paul and Moir, 1949; Hohl and Baker, 1964; Shapiro et al., 1973). Although this anterior displacement of the arch observed during a 'normal' axial rotation at C1-C2 interface is accounted for, it is hard to find references documenting the change in the sagittal dimension of the ring behind the dens in extreme degrees of C1-C2 axial rotation in normal subjects.

Few data are available concerning the changes in dimensions within the ring of the atlas (behind the dens), in extreme circumstances of C1-C2 axial rotation or the possibility of neuro-vascular compression in susceptible individuals. Dried bone specimens (Tucker and Taylor, 1998) demonstrating decreased transverse dimensions and a vertebral space within the atlas vertebra have been documented. The present study evaluates the available mid-sagittal linear dimensions within the atlas vertebra from X-rays of normal living individuals, before and after optimal rotation at the neck, and addresses the following issues: (1) Does the available antero-posterior dimension within the ring of the atlas (behind the dens) change due to optimal / maximum axial rotation at the atlanto-axial joint? (2) If so, does it increase or decrease in dimension and at what percentage of the space that is available without any rotation at the C1-C2 junction. Also, it would be interesting to see whether the changes in dimensions might have any clinical significance in certain clinical settings.

MATERIAL AND METHODS

Lateral as well as antero-posterior (AP) radiographs (with optimal rotation of the neck to the left) (Fig. 1) were acquired from volunteers ($n=25$). Linear measurements were obtained from all the X-rays for: (1) the space available between the posterior aspect of the anterior arch of the atlas and the anterior limit of the dens (AS); and (2) the diameter of the ring of the atlas extending from the posterior

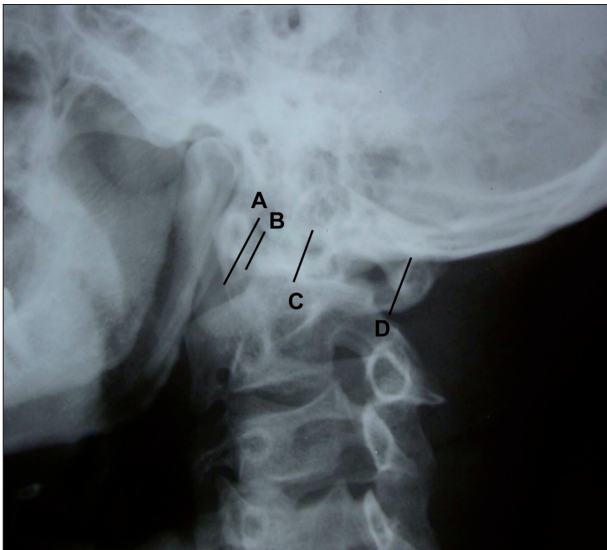


Fig. 1A. Antero-posterior view of the cervical spine with the neck in axial rotation. The distance between the lines A and B denotes the space anterior to the dens (AS). The distance between lines C and D is the measurement for space behind the dens (PS).

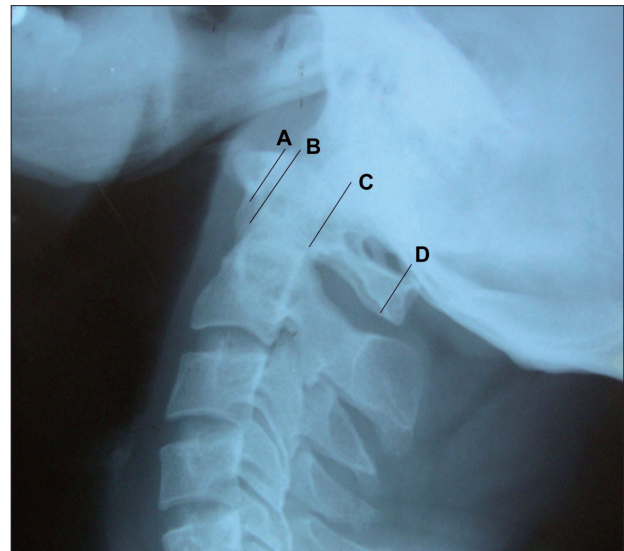


Fig. 1B. Lateral view of the cervical vertebrae without any rotation. A to B= AS; C to D= PS.

surface of the dens up to the anterior aspect of the posterior arch of the atlas (PS) (Figs. 1a, 1b). All measurements were obtained by two independent observers using a digital Vernier caliper (sensitivity=0.01mm) and the mean values of all measurements were considered.

All the twenty-five volunteers, of both sexes, belonged to the 25-50-year age group. Subjects with history of major neck ailments and with limitations to optimal unilateral or bilateral axial rotation of the neck were excluded from the study. Descriptive statistical values were compared between the results obtained from each individual before and after rotation at the atlanto-axial joint. Correlations between the changing parameters in an individual were calculated. Inter-Tester reliability demonstrated high values of agreement between observations recorded by the independent observers.

Data analysis

Descriptive statistics were obtained for each parameter in each of the two groups. The data were scrutinized statistically for the presence of significant differences in the measurements between the two views. Student's *t* test was applied to evaluate the significance of the differences between the means of the parameters before and after axial rotation (Table 1). The Total Sagittal Diameter (TSD) of the space between the anterior and posterior arches of atlas was measured in both the views for comparison of the completeness of the axial rotation of the atlas in the AP views. The Chi-square test was applied to detect the presence of any dependence among the parameters (calculated individually for each dimension, before and after head rotation) (Table 1). The parameters within a group were explored for the existence of significant correlations among

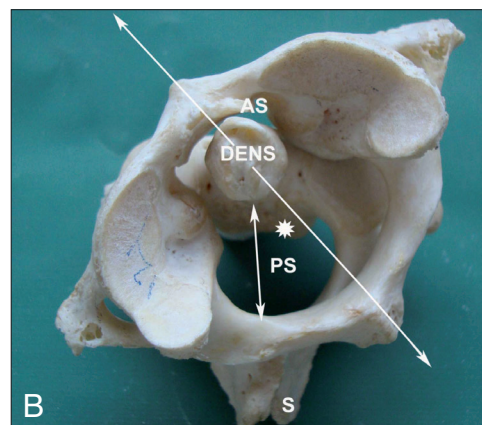
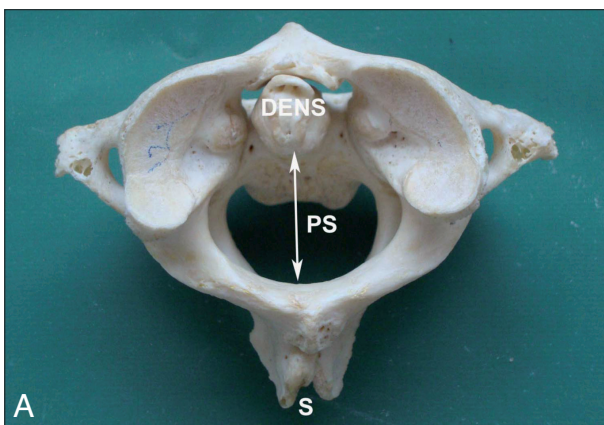


Fig. 2. - A: The atlas and axis vertebrae viewed from above (without axial rotation). The mid-sagittal diameter (behind the dens) within the ring of the atlas is shown by the double-headed arrow (PS). S=Spine of the axis vertebra. **B:** Relationship between the axially rotated atlas and the axis as seen from above. The mid-sagittal dimension within the spinal canal at the level of the atlas is represented as PS. S= Spine of the axis.

them by using the Pearson product-moment correlation (Table 2).

RESULTS

Table 1 shows that the measurement of TSD (a fixed anatomical entity) varied very little in the two groups, indicating a procedural limitation. The smaller dimension in axial rotation might have resulted from the obliqueness of the anterior arch, which could have caused a wider shadow of the anterior arch in the radiograph. The anterior space (AS) was marginally reduced in axial rotation in comparison with that found without rotation. The difference between the means is maximal at the posterior space (PS) (>0.89 mm). Although none of the parameters had a statistically significant value, all of them showed a high level of dependence between the groups in the Chi-squared values (Table 1). Table 2 shows the correlation values among the different parameters in the two groups.

DISCUSSION

The average mid-sagittal diameter in the atlas vertebra found in this study was >35mm. The documented range (Wolf et al., 1956) is 16-33 mm. This space accommodates the dens of the axis vertebra, the spinal cord, and an empty area behind the cord, all three sharing an equivalent space in the mid-sagittal plane within the atlas. Jackson has reported the presence of a space between the posterior aspect of the anterior arch of atlas and the anterior surface of the dens (reported as the

anterior space ‘AS’ in this study). According to Jackson (1950), in adults this space remained constant even in full flexion and extension. This space is wider in children and may exhibit some forward subluxation during flexion, (Hinck et al., 1962; Carella, 1973). The present study detected an average of 2.48 mm for this space, with a maximum value of 4.34 mm (Table 1). A value of > 5 mm indicated clinical instability at the C1-C2 junction (Shapiro et al., 1973). A normal allowance of space anterior to the dens reciprocally reduces the available space behind the dens. As discussed earlier, axial rotation at the atlanto-axial joint causes displacement of the lateral mass of the atlas antero-lateral to the dens (Fig. 2a and b). The mid-sagittal diameter of the atlas now lies oblique to and at an angle with the sagittal plane and with that of the mid-sagittal dimension of the axis. This rotation brings one half of the posterior arch of the atlas closer to the spinal cord. Axial rotation has also been associated with vertical translation of the atlas due to the configuration of the C1-C2 articulations, as seen in cine-radiographs (Hohl and Baker, 1964). This upward translation of C1 may be directed strictly vertically or inclined posteriorly, depending upon the inclination of the dens. A vertical or slightly anterior ascent of the atlas may further reduce the space for the spinal cord behind the dens. In our hands this posterior space ranged between 17.31-25.32 mm (mean 21.71 mm). The literature contains references documenting the change in this space in flexion / extension movements at this joint but it is rare to find accounts of the status of

	AP views with maximum C1-C2 Axial Rotation (n=25)	Range	Lateral views (n=25)	Range	Difference in means	‘P’ value	χ ² value	‘r’ values
Total Sagittal Diameter (TSD)	35.12 (±2.60)	31.01-40.29	35.39 (±2.76)	31.48-40.66	0.27	0.40	0.98	0.00
Anterior Space between the anterior arch and the dens (AS)	2.02 (±0.56)	1.15-3.38	2.48 (±0.87)	1.54-4.34	0.46	0.20	0.94	-0.54
Posterior Space between the dens and posterior arch (PS)	21.71 (±2.25)	17.31-25.32	22.60 (±1.55)	19.66-25.03	0.89	0.39	0.99	0.26

Table 1. Mean values and ranges of linear parameters within the ring of the atlas. Each parameter has a P value comparing the differences in the means between the two groups of radiographs and a Chi-Square test result (χ²) showing the degree of association in a given parameter for two different positions of X-ray exposure. All measurements are given in millimeters, with the standard deviation (SD) in brackets.

*Significant at P ≤ 0.05

	TSD vs AS	TSD vs PS	AS vs PS	
AP views with Axial Rotation (n=25)	4.91	7.24	5.77	'P' values
	0.01	0.91	0.04	'r' values
Lateral views (n=25)	2.42	2.14	1.9	'P' values
	0.53	0.84*	0.21	'r' values

Table 2. Pearson's Product Moment Correlation Coefficient values calculated between parameters within each group of X-rays demonstrating the reciprocal interrelationship of these parameters. *Significant at $P \leq 0.05$.

this space in the full range of axial rotation at the atlanto-axial joint (Shapiro et al., 1973). C1-C2 axial rotation is associated with vertebral artery compromise (Fielding, 1957; Selecki, 1969) and prolonged axial rotation at optimal ranges of axial rotation may significantly reduce flow in the vertebral artery. The results of the present study indicate that extreme axial rotation of the C1 vertebra with a baseline small mid-sagittal diameter may significantly reduce the space available for the spinal cord. This situation may be compounded by congestion in the internal vertebral plexus of veins if such extreme rotation is prolonged. The average reduction in this space behind the dens was 0.89 mm in this study (4.10% of PS at maximum axial rotation; taking into account the changes at the AS). The reduction at the PS may become maximal with anterior angulation of the dens with respect to the body of the axis. The PS may also be reduced if the two posterior arch components meet each other acutely at the spine. In this situation, rotation of the atlas may bring the ipsilateral half (on the side of head-rotation) of the posterior arch of atlas too close to the back of the spinal cord (Fig. 2). A similar pronounced reduction of the vertebral space within the atlas may occur with axial rotation in slightly anomalous atlases. These anomalies usually exhibit variations in the mid-sagittal dimensions of the atlas (Carella, 1973). The change in the dimension of the PS was strongly correlated with the TSD but not with the change in the AS, probably due to the predominant role of the posterior arches in the reduction of the PS, and possibly due to the greater degree of change (mean=0.89 mm) observed at the PS, in contrast to the smaller (mean=0.46 mm) and inconsistent change seen at the AS. Axial rotation at the atlanto-axial joint with the head held in full flexion may lead to a further reduction of the PS; especially in individuals susceptible to C1-C2

anterior translation / subluxation during flexion at the joint. Thus, extreme axial rotation at the C1-C2 junction may possibly complicate situations with space-occupying lesions at the cephalic segments of the spinal cord, especially in persons with a comparatively smaller ring of the atlas vertebra. Conditions such as alar ligament instability (Panjabi et al., 1991) and rheumatoid arthritis (Puttlitz et al., 2000) have been implicated in predisposing the C1-C2 junction to subluxation during axial rotation at the joint. Excessive rotation at this junction has also been reported to be associated with traumatic dislocations at the vital C1-C2 articulation (Born et al., 1994). An abnormal rotation at this region in susceptible individuals may complicate a C1-C2 dislocation, compromising vertebral artery flow (Sawhani et al., 2006).

It may be concluded that maximal rotation at the neck contributes significantly to rotation at the atlanto-axial joint. This rotation marginally reduces the mid-sagittal space within the atlas vertebra. A reduction of this space may be enhanced when C1-C2 rotation is unrestrained due to ligament insufficiencies and may possibly result in C1-C2 dislocations.

REFERENCES

- BORN CT, MURE AJ, IANNAcone WM, DELONG WG JR (1994). Three-dimensional computerized tomographic demonstration of bilateral atlantoaxial rotatory dislocation in an adult: report of a case and review of the literature. *J Orthop Trauma*, 8: 67-72.
- CARELLA A (1973). Variations of the sagittal diameter of the atlas and axis in cases of slight anomaly of the atlas. *Neuroradiology*, 5: 195-196.
- DANKMEIJER J, RETHMEIER B (1942). The lateral movement in the atlanto-axial joint and its clinical significance. *Acta Radiologica*, 24: 55-66.
- FIELDING JW (1957). Cineoentgenography of the normal cervical spine. *J Bone Joint Surg*, 39: 1280-1288.

- HINCK VC, HOPKINS CE, SAVARA BS (1962). Sagittal diameter of the cervical spinal canal in children. *Radiology*, 79: 97-108.
- HOHL M, BAKER HR (1964). The atlantoaxial joint. *J Bone Joint Surg*, 8: 1739-1752.
- JACKSON H (1950). The diagnosis of minimal atlanto-axial subluxation. *Br J Radiol*, 23: 672-674.
- PANJABI M, DVORAK J, CRISCO JJ III, ODA T, WANG P, GROB D (1991). Effects of alar ligament transection on upper cervical spine rotation. *J Orthop Res*, 9: 584-593.
- PAUL LW, MOIR WW (1949). Non-pathological variations in relationship of the upper cervical vertebrae. *AJR*, 62: 519-524.
- PENNING L, WILMINK JT (1987). Rotation of the cervical spine: a ct study in normal subjects. *Spine*, 12: 732-738.
- PUTTLITZ CM, GOEL VK, CLARK CR, TRAYNELIS VC, SCIFERT JL, GROSLAND NM (2000). Biomechanical rationale for the pathology of rheumatoid arthritis in the craniovertebral junction. *Spine*, 25: 1607-1616.
- ROCHE CJ, KING SJ, DANGERFIELD PH, CARTY HM (2002). The atlanto-axial joint: Physiological range of rotation on MRI and CT. *Clin Radiol*, 57: 103-108.
- SAWLANI V, BEHARI S, SALUNKE P, JAIN VK, PHADKE RV (2006). "Stretched loop sign" of the vertebral artery: a predictor of vertebrobasilar insufficiency in atlantoaxial dislocation. *Surg Neurol*, 66: 298-304.
- SELECKI BR (1969). The effects of rotation of the atlas on the axis: Experimental work. *Med J Aust*, 1: 1012-1015.
- SHAPIRO R, YOUNGBERG AS, ROTHMAN SLG (1973). The differential diagnosis of traumatic lesions of the occipito-atlanto-axial segment. *Radiol Clin North Am*, 11: 505-526.
- STEEL H (1968). Anatomical and mechanical consideration of the atlanto-axial articulation. *J Bone Joint Surg*, 50A: 1481.
- TUCKER SK, TAYLOR BA (1998). Spinal canal capacity in simulated displacements of the atlantoaxial segment. A skeletal study. *J Bone Joint Surg*, 80-B: 1073-1078.
- WERNE S (1957). Studies in spontaneous atlas dislocation. *Acta Orthop Scand [Suppl]*, 23: 78-79.
- WHITE AA, PANJABI MM (1978). The basic kinematics of the human spine. A review of past and current knowledge. *Spine*, 3: 12-20.
- WOLF BS, KHILNANI M, MALIS L (1956). The sagittal diameter of the bony cervical canal and its significance in cervical spondylosis. *J Mt Sinai Hosp*, 23: 283-292.
- ZHANG QH, TEO EC, NG HW, LEE VS (2006). Finite element analysis of moment-rotation relationships for human cervical spine. *J Biomechanics*, 39: 189-193.