

Bilateral variations in the formation of the median nerve associated with the absence of musculocutaneous nerve and radial nerve with two roots

Hasem H. Darwish, M. Mujahid Khan, Maha A.F. Alkokani, Walid A. Zaher

Department of Anatomy, College of Medicine, King Khalid University Hospital, King Saud University, Riyadh, Saudi Arabia

SUMMARY

We report a case of bilateral multiple variations of the brachial plexus in a 60-year old Caucasian female cadaver. In the right upper limb the musculocutaneous nerve was absent. The flexors of the arm and skin of the lateral aspect of forearm were supplied by branches from the medial cord of the brachial plexus and median nerve. In the left upper limb, the median nerve was formed by four roots; three from the lateral cord and one from the medial cord of the brachial plexus. The radial nerve also had two roots, one from the posterior cord and another from the medial cord, which formed a loop anterior to the subscapular artery.

Such a combination of variations in a single cadaver is rare. The frequent anatomic variations of the brachial plexus should always be considered as an important risk factor while performing surgery of the axilla.

Key words: Variations – Brachial plexus – Median, musculocutaneous, radial nerves

INTRODUCTION

Variations of the brachial plexus and its branches are not uncommon (Tountas and

Bergman, 1993). Twenty-nine types of brachial plexus have been reported (Kerr, 1918). Variations were observed in 107 brachial plexuses out of 200 dissected (Uysal et al., 2003). Anomalies in the terminal branches and connections between these branches of the brachial plexus have been reported previously (Miller, 1939; Hollinshead, 1982; Aktan et al., 2001). Knowledge of such variations is important for anatomists, radiologists and surgeons, and it has gained more significance due to the evolution of computer imaging (Harry et al., 1997). Here we report a case of multiple bilateral variations of brachial plexus in a 60-year old Caucasian female cadaver in which the median nerve formation was complex bilaterally, associated with the absence of the musculocutaneous nerve in the right upper limb and a radial nerve with two roots in the left upper limb. According to the literature reviewed, such a combination of variations in a single cadaver is extremely rare.

CASE REPORT

Right Upper Limb

The musculocutaneous nerve was absent, whereas the coracobrachialis muscle took its nerve supply via a branch from the lateral

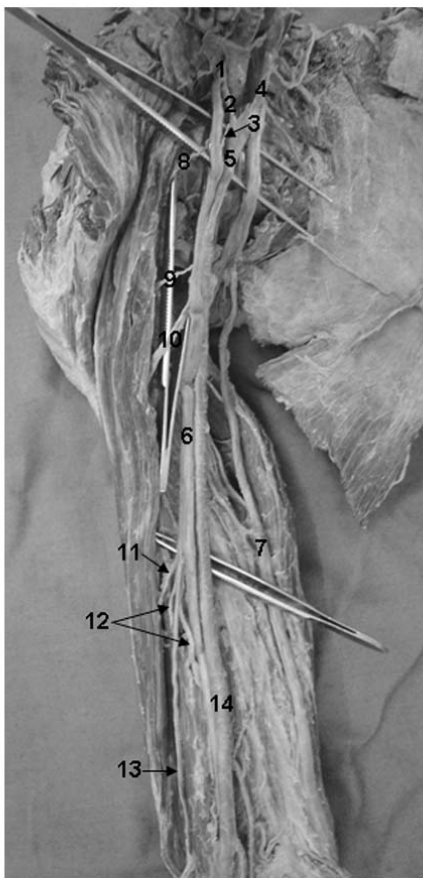
cord, 2 cm below the tip of the coracoid process. The median nerve was formed 4 cm below the coracoid process by two roots. The lateral root was the continuation of the lateral cord, while the medial root was a branch from the medial cord at the level of the coracoid process and its length was 4.5 cm. The medial root received a contributing branch from the lateral cord joining the beginning of the medial root of median nerve; its length was 2 cm. Midway along its course, it gave off a 1 cm-long connecting branch that rejoined the lateral cord just below the branch to the coracobrachialis muscle. The median nerve gave off two separate branches to both the long and short heads of the biceps muscle, which originated 2 cm and 3 cm respectively after the formation of the median nerve and a third branch in the mid arm 16 cm from the coracoid process, which further divided into four branches: one to the common belly of the biceps muscle; two branches to the brachialis

muscle, while the fourth one continued as a lateral cutaneous nerve of the forearm (Fig. 1a and b).

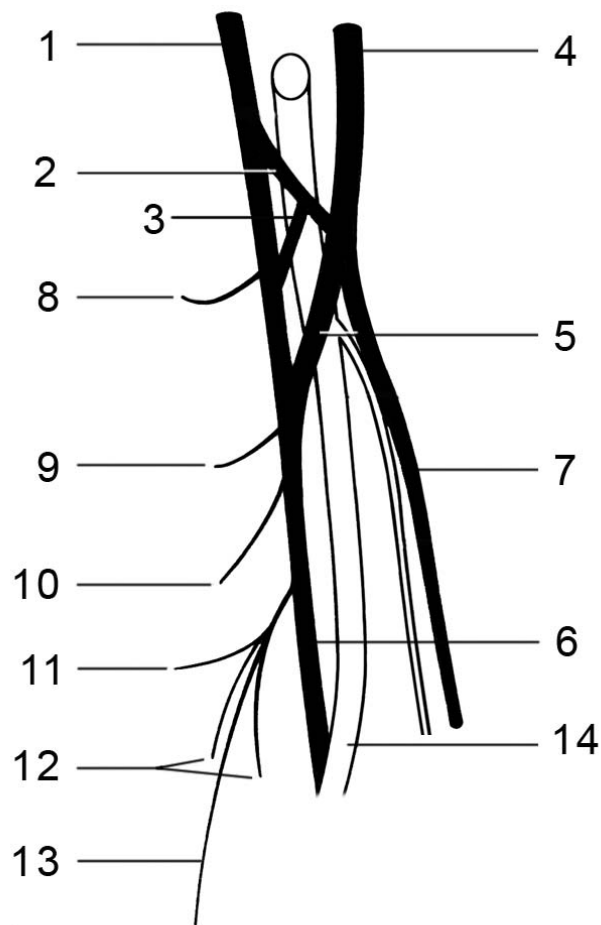
Left Upper Limb

In the axilla, the lateral cord of the brachial plexus gave off two branches at the level of the coracoid process, which passed anterior to the axillary artery to join the medial root of the median nerve. They measured 3.5 cm and 4 cm, respectively. The lateral cord gave off a third branch, sharing in the formation of median nerve that originated 3 cm below the coracoid process, then passed posterior to the brachial artery to unite with the medial root of the median nerve just below the insertion of the teres major, 9.5 cm below the coracoid process.

The medial root of median nerve originated from the medial cord 3 cm below the coracoid process and was 7 cm in length.



a



b

Fig. 1. Right upper limb showing the absence of the musculocutaneous nerve: 1 = lateral cord, 2 = 1st connection, 3 = 2nd connection, 4 = medial cord, 5 = medial root of median nerve, 6 = median nerve, 7 = ulnar nerve, 8 = branch to coracobrachialis, 9 = branch to short head of biceps, 10 = branch to long head of biceps, 11 = branch to biceps belly, 12 = two branches to brachialis, 13 = lateral cutaneous nerve of forearm, 14 = brachial artery.

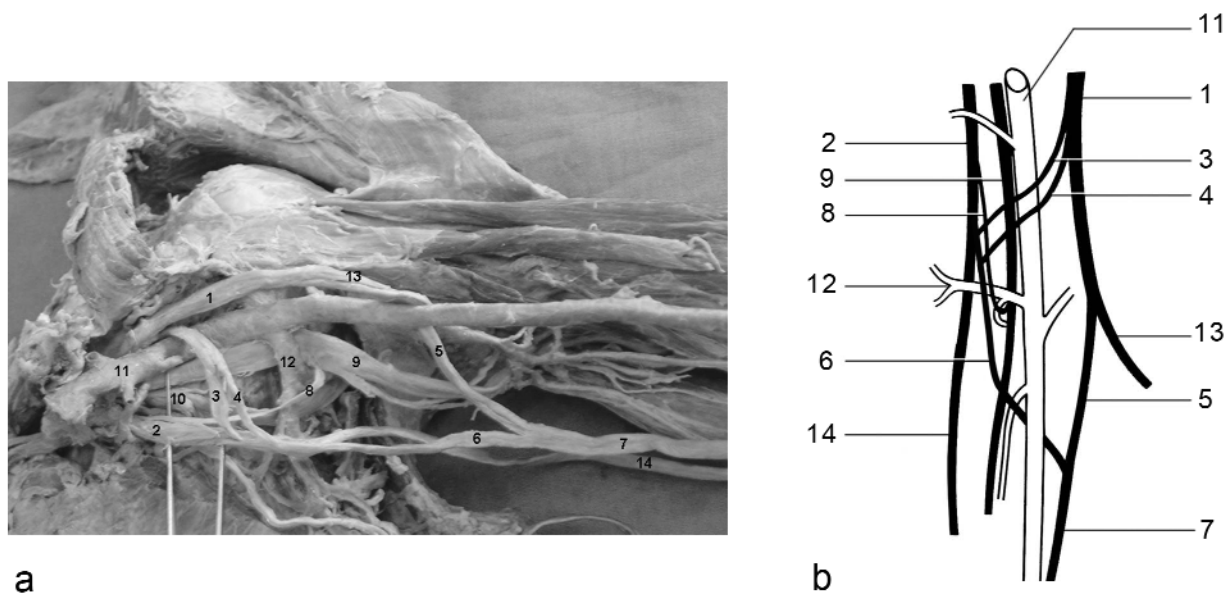


Fig. 2. Left axilla showing a connection between medial cord and radial nerve. 1 = lateral cord, 2 = medial cord, 3 = 1st connection, 4 = 2nd connection, 5 = lateral root of median nerve, 6 = medial root of median nerve, 7 = median nerve, 8 = connection between medial cord and radial nerve, 9 = radial nerve, 10 = axillary nerve, 11 = axillary artery, 12 = subscapular artery, 13 = musculocutaneous nerve, 14 = ulnar nerve.

The radial nerve was formed 4 cm below the coracoid process by two roots, one from the posterior cord and the other from the medial cord, which measured 4.5 cm in length, forming a loop anterior to the subscapular artery (Fig. 2a and b).

DISCUSSION

The musculocutaneous nerve is a branch from the lateral cord opposite the lower border of the pectoralis minor muscle, its root value is C5 to C7 ventral rami. It pierces the coracobrachialis muscle and descends laterally between the biceps and brachialis muscles to the lateral side of the arm. Just below the elbow, it pierces the deep fascia, lateral to the tendon of the biceps, and continues as the lateral cutaneous nerve of the forearm (Williams et al., 1995). It supplies the flexors of the arm and the skin of the lateral forearm (Tountas and Bergman, 1993). Several studies have described the different ways of innervation of the biceps muscle via the musculocutaneous nerve (Yang et al., 1995; Chiarpattanakom et al., 1998). The absence of a musculocutaneous nerve has been reported previously in a case in which the nerve supply to the coracobrachialis, brachialis and both heads of the biceps muscles arose directly from the lateral cord. Also, the lateral cutaneous nerve of the forearm was derived from the lateral cord,

with a small contribution from the medial root of median nerve (Nakatani et al., 1997). Two cases of the absence of the musculocutaneous nerve have also been described (Rao and Choudhary, 2001). In the first case, the lateral cord gave off a branch to the coracobrachialis muscle, while the median nerve gave off the branch that supplied the biceps and brachialis muscles, and continued as the lateral cutaneous nerve of the forearm. In the second case, the lateral cord gave off a branch to the coracobrachialis, whereas the median nerve supplied the muscular branches to the coracobrachialis and biceps muscles. It also gave off another branch that supplied the brachialis muscle and then continued as the lateral cutaneous nerve of the forearm. Our case is similar to those reported by Nakatani and Rao in which coracobrachialis took a direct branch from the lateral cord. Such variations have been reported previously (Kerr, 1918), but the pattern of both the cutaneous and muscular innervation is different from the present case.

The median nerve is a mixed nerve that arises by two roots: the lateral root (C5-C7) from the lateral cord and the medial root (C8-T1) from the medial cord. The medial root tends to be constant in size and course, while the lateral root may vary (Johnson et al., 2006). Variations in the formation and course of the median nerve are found in 7% of cases

(Pandey and Shukla, 2007). The literature contains many reports of median nerves with three roots, in which two originated from the lateral cord and one from the medial cord (Saeed and Rufai, 2003; Goyal et al., 2005; Ramachandran et al., 2006). Several different patterns of connections between the musculocutaneous nerve and the median nerve have also been described (Veneratos and Anagnostopoulou, 1998; Choi et al., 2002; Uzun and Seeling, 2001). However, reports did not describe a median nerve with four roots. Only Kerr (1918) described a similar variation; he also observed two cases of a radial nerve receiving a second root from the medial cord.

Such variations may lead to a complex deformity of the arm with a single puncture wound (Tountas and Bergman, 1993). The intimate relationship between these variant nerve connections and the arteries in the axilla may result in arterial compression, leading to ischemic pain or variable arterial insufficiency during certain postural manoeuvres of the shoulder joint (Goyal et al., 2005). Knowledge of such variations is essential in the evaluation of unexplained sensory or motor loss after trauma or surgical intervention of the upper limb (Singhal et al., 2007). The frequent anatomic variations of the brachial plexus should always be considered as an important risk factor while performing surgery of the axilla.

ACKNOWLEDGEMENTS

The authors are thankful to Mr. V. Salvador for drawing the illustrations and Dr. Ibrahim Khawaji for his technical assistance.

REFERENCES

- AKTAN Z, OZTURK L, BILGE O, OZER M, PINAR Y (2001). A cadaveric study of the anatomic variations of the brachial plexus nerves in the axillary region and arm. *Turk J Med Sci*, 31: 147-150.
- CHIARATTANAKOM P, LEECHAVENGVONGS S, WITONCHART K, UERPAIROJKIT C, THUVASETHZKUL P (1998). Anatomy and internal topography of the musculocutaneous nerve: the nerves to the biceps and brachialis muscle. *J Hand Surg*, 23: 250-255.
- CHOI D, RODRIGUEZ-NIEDENFUHR M, VÁZQUEZ T, PARKIN I, SANUDO JR (2002). Patterns of connections between the musculocutaneous and median nerves in the axilla and arm. *Clin Anat*, 15: 11-17.
- GOYAL N, HARJEET, GUPTA M (2005). Bilateral variant contributions in the formation of median nerve. *Surg Radiol Anat*, 27: 562-565.
- HARRY WG, BENNETTE JD, GUHA SC (1997). Scalene muscles and the brachial plexus: anatomical variations and their clinical significance. *Clin Anat*, 10: 250-252.
- HOLLINSHEAD WH (1982). Pectoral region, axilla and shoulder. In: *Anatomy for Surgeons. Vol. 3. The back and limbs*. 3rd ed. Harper & Row, Philadelphia, pp 259-340.
- JOHNSON EO, VEKRIS MD, ZOUBOS AB, SOUCACOS PN (2006). Neuroanatomy of the brachial plexus: The missing link in the continuity between the central and peripheral nervous systems. *Microsurgery* DOI 10.1002/micr.
- KERR AT (1918). The brachial plexus of nerves in man: The variations in its formation and branches. *Am J Anat*, 23: 285-392.
- MILLER RA (1939). Observations upon the arrangement of the axillary artery and brachial plexus. *Am J Anat*, 64: 143-163.
- NAKATANI T, TANAKA S, MIZUKAMI S (1997). Absence of musculocutaneous nerve with innervation of coracobrachialis, biceps brachii, brachialis and the lateral border of the forearm by branches from the lateral cord of the brachial plexus. *J Anat*, 191: 459-460.
- PANDEY SK, SHUKLA VK (2007). Anatomical variations of the cords of brachial plexus and the median nerve. *Clin Anat*, 20: 150-156.
- PRASADA RAO PV, CHOUDHARY SC (2001). Absence of musculocutaneous nerve: Two cases. *Clin Anat*, 14: 31-35.
- RAMACHANDRAN K, KANAKASABAPATHY I, HOLLA SJ (2006). Multiple variations involving all the terminal branches of the brachial plexus and the axillary artery – a case report. *Eur J Anat*, 10: 61-66.
- SAEED M, RUGAI AA (2003). Median and musculocutaneous nerves. *Clin Anat*, 16: 453-457.
- SINGHAL S, RAO VV, RAVINDRANATH R (2007). Variations in brachial plexus and the relationship of median nerve with the axillary artery: a case report. *J Brach Plex & Per N Inj*, 2: 21.
- TOUNTAS CP, BERGMAN RA (1993). Anatomic variations of the upper extremity. Churchill Livingstone, pp 193-210.
- UYSAI II, SEKER M, KARABULUT AK, BUYUKMUMCU M, ZIALAN T (2003). Brachial plexus variations in human fetuses. *Neurosurgery*, 53: 676-684.
- UZUN A, SEELING LL JR (2001). A variation in the formation of the median nerve: communication branch between the musculocutaneous and median nerves in man. *Folia Morphol*, 60: 99-101.
- VENERATOS D, ANAGNOSTOPOULOU S (1998). Classification of communications between the musculocutaneous and median nerve. *Clin Anat*, 11: 327-331.
- WILLIAMS PL, BANNISTER LH, BERRY MM, COLLINS P, DYSON M, DUSSEK JE, FERGUSON MWJ (1995). Gray's Anatomy, 38th ed. Churchill Livingstone, New York, pp 1537-1544.
- YANG Z, PHO RWH, KOUR A, PREIRA BP (1995). The musculocutaneous nerve and its branches to the biceps and brachialis muscles. *J Hand Surg*, 20A: 671-675.