

Anatomo-radiological correlation of the superior aspect of the temporal lobe (planum supratemporale)

Fernando Martínez^{1,2,3}, Osmar Telis⁴, Gabriela Castro Pozzoli¹, Gonzalo Estapé Carriquiry¹, Ariel Rocca¹, Brenda Chiaradia⁵

1- Department of Anatomy, Facultad de Medicina CLAEH, Maldonado, Uruguay

2- Department of Anatomy, Facultad de Medicina (Universidad de la República, UDELAR) Montevideo, Uruguay

3- Department of Neurological Surgery, Hospital de Clínicas, Facultad de Medicina (UDELAR), Montevideo, Uruguay

4- Department of Clinical Radiology, Hospital de Clínicas, Facultad de Medicina (UDELAR), Montevideo, Uruguay

5- Medical student, Facultad de Medicina CLAEH, Maldonado, Uruguay

Part of this work was presented at the VI Uruguayan Congress of Radiology, 12-14 October 2007, Montevideo, Uruguay. The authors of the article have not financial or ethical conflicts.

SUMMARY

The superior aspect of the temporal lobe or planum supratemporale (PS) forms the inferior limit of the sylvian fissure. It is related to the frontal, parietal and insular lobes, and with the sylvian vessels (arteries and veins). Recognition of the portions of PS in imaging studies, such as MRI or cranial CT, is important for neuroradiologists, neurologists and neurosurgeons. We used 10 formalin-fixed cerebral hemispheres. We injected red latex into the arterial system in one. We made horizontal, coronal and sagittal cuts in 7 hemispheres, and performed white matter dissection in two. We compared the anatomical specimens with MRI, cranial CT and cerebral angiographies.

The PS can be divided into three portions from front to back: the planum polare (PP), Heschl's gyrus (HG) and the planum temporale (PT). PP and PT are flat, and HG is elevated. The obliquity of HG is oriented in such a way that it delineates the location of the ventricular atrium. The three parts of PS can be readily identified in MRI, but a certain degree of brain atrophy facilitates its identification in CT. In cerebral angiography, the different segments of the middle cerebral artery serve as a

guide for recognizing the anatomical structures of the temporal lobe and insular region.

Anatomical knowledge is of paramount importance to recognize the different parts of the PS in radiological studies. This anatomic-image-based knowledge can be applied in surgical planning.

Key words: Temporal lobe – Heschl's gyrus – Trans-sylvian approach – Insular lobe

INTRODUCTION

The temporal lobe is one of the most complex parts of the brain. Because of its connections and its functional areas located in its cortex it has been implicated in many functions such as vision, language, hearing and memory. It also participates in the three circuits of the limbic system (Fried, 1997).

Since the '80s, MRI and functional MRI images have been able to show the brain anatomy of living humans in great details. Accordingly, it is necessary that neurosurgeons, neurologists and radiologists reaffirm their knowledge of anatomy in general and the functional anatomy of the brain in particular (Binder, 1997).

In addition, the temporal lobe, and in particular its superior aspect is in close relationship with the sylvian fissure and sylvian cistern. This important area of the subarachnoidal space offers a surgical corridor to lesions located in the middle cranial fossae and interpeduncular region. Thus, it is very important to recognize the different portions of the

superior aspect of the temporal lobe (also called the planum supratemporale) in CT, MRI and other imaging techniques. In the present article, we performed an anatomic-image correlation of the planum supratemporale.

MATERIAL AND METHODS

We used ten formalin-fixed cerebral hemispheres of adult cadavers without neurological pathology. We obtained sagittal, coronal or horizontal sections in seven hemispheres, and performed white matter dissection techniques (Klingler's technique) in two hemispheres and red latex injection in the arterial system in one hemisphere.

Then, we reviewed cranial CT, MRI and cerebral angiographies of individuals with and without pathology for an anatomic correlation. The imaging studies were obtained from patients of the Hospital de Clínicas (Universidad de la República).

RESULTS

The superior aspect of the temporal lobe (PS) is hidden by the sylvian fissure, and only

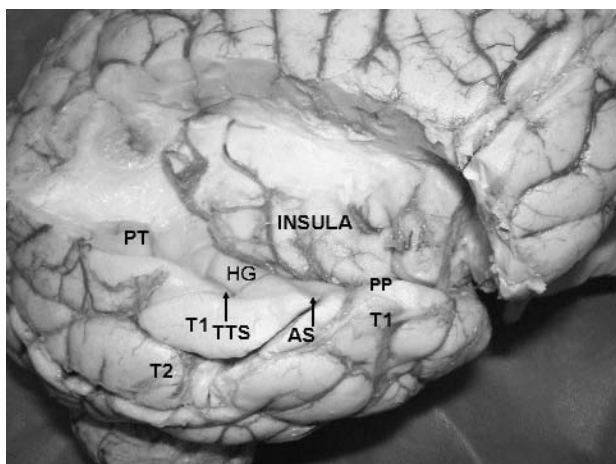


Fig. 1. Lateral and superior aspect of the temporal lobe, right cerebral hemisphere. In this anatomical specimen, the frontal and parietal opercula were resected. In the center of the figure, Heschl's gyrus (HG) can be seen. In front of it are the auditory sulcus and the planum polare (PP). In the posterior aspect of HG, the transverse temporal sulcus (TTS) and the planum temporale (PT) can be observed. T1 and T2: superior and middle temporal gyrus, respectively.

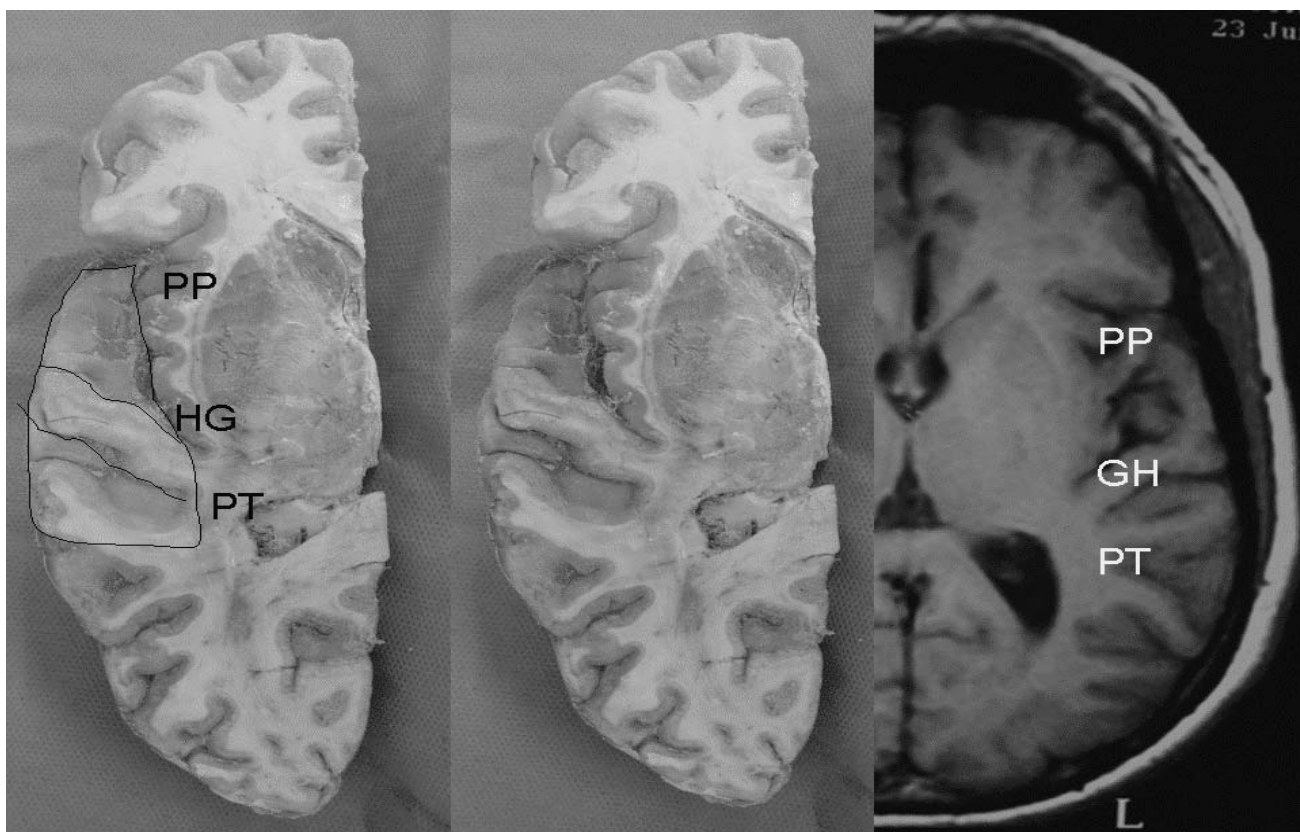


Fig. 2. Superior aspect of temporal lobe, left hemisphere. In the center of the figure, there is an anatomical specimen showing the anatomy of the supratemporal planum (SP). At the left, a schematic figure of the three portions of the SP. At the right, an MRI image of the superior aspect of the right temporal lobe. PP: planum polare; HG: Heschl's gyrus; PT: planum temporale.

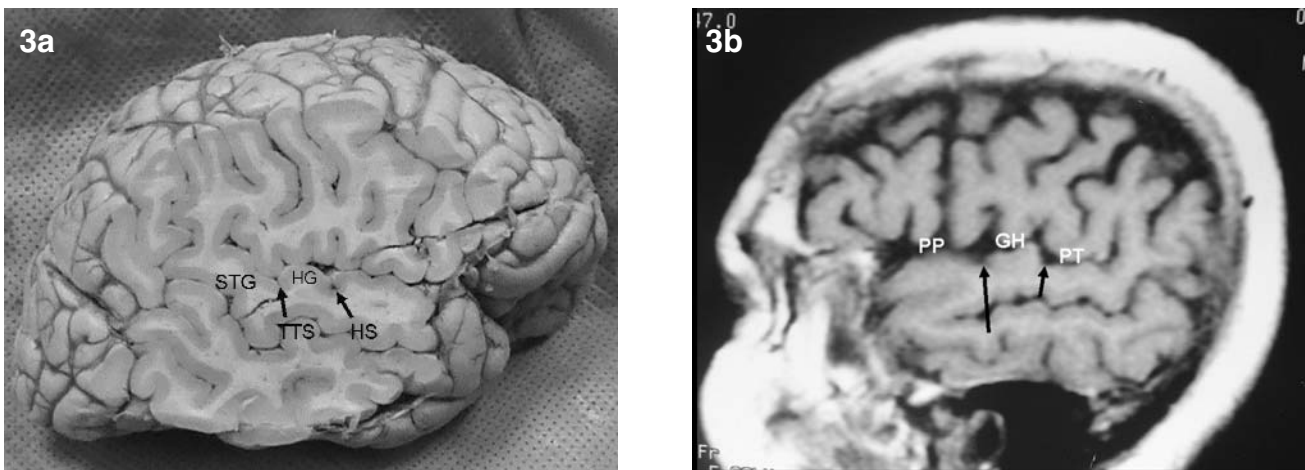


Fig. 3. Parasagittal sections of an anatomical specimen and an MRI. 3a) Right cerebral hemisphere, parasagittal section. In this anatomical specimen note the morphology of the three parts of the supratemporal plane. STG: superior temporal gyrus; HG: Heschl's gyrus; TTS: transverse temporal sulcus; HS: Holl's sulcus. 3b) Image correlation with an MRI. Long arrow: TTS; Short arrow: HS.

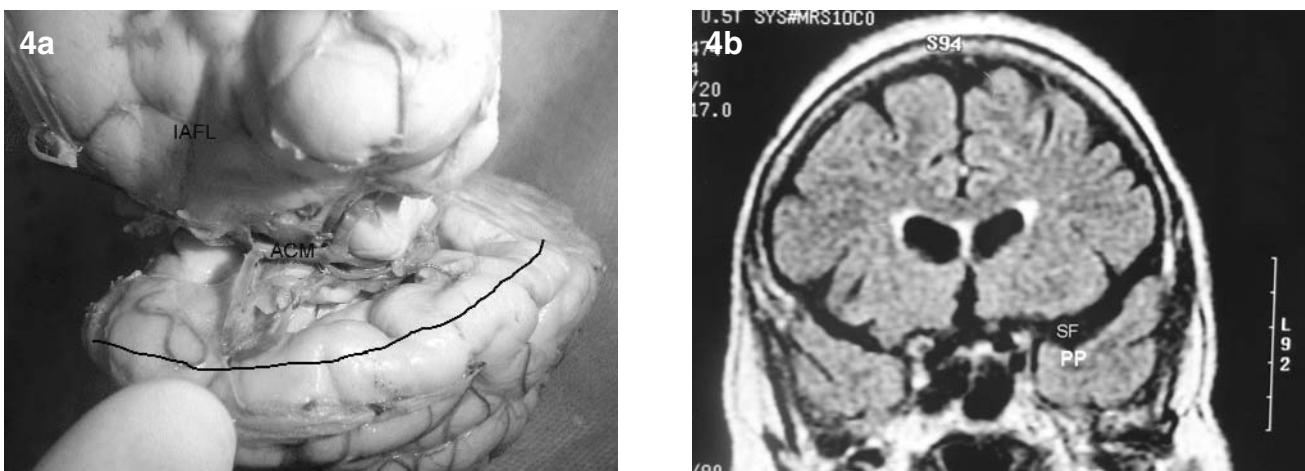


Fig. 4. Planum polare. 4a) Anterior view of an anatomical specimen, left cerebral hemisphere. After the arachnoid membrane had been resected, we observed the middle cerebral artery (MCA) and the curvature of the planum polare (line). IAFL: inferior aspect of frontal lobe. 4b) Image correlation with a coronal MRI. SF: sylvian fissure, sphenoidal part; PP: Planum polare.

its lateral-most part is visible from a lateral view of the intact brain (Fig. 1). If the sylvian fissure is opened by anatomic or surgical dissection, it is possible to visualize the superior aspect of the temporal lobe. Thus, in the surgical setting, the surgeon faces the planum supratemporale in all trans-sylvian approaches (Campero et al., 2006; Nagata and Sasaki, 2005; Tanriover et al., 2004). On average, the total length of the PS is 90 mm (Comair and Tamraz, 2001).

From an anatomic point of view, the PS can be divided into three sectors from front to back (Fig. 2): the planum polare (PP), Heschl's gyrus (HG) and the planum temporale (PT) (Rhoton, 2002a; Russell and Golfinos, 2003; Wen et al., 1999). The PS is seen to display a "wind surf sail" that can be divided into an anterior triangular area (PP), an intermediate quadrangular area orientated anteriorly

and laterally (HG), and a posterior quadrangular area (PP) (Fig. 2).

Morphologically, PP and PT are flat, and HG is elevated (Fig. 3a and 3b). Heschl's gyrus has two sulci at the front and at the back: Holl's sulcus and the transverse temporal sulcus, respectively. These sulci separate HG from the PP and PT, respectively, but the sulcus separating HG from PP is less clear (Fig. 2) (Russell and Golfinos, 2003).

Planum polare

This is the most anterior part of PS, located in front of Heschl's gyrus and Holl's sulcus. The planum polare has a triangular shape and because of the oblique disposition of HG, the length of the PP is longer in its inner than in its external part (Fig. 2, left). The planum polare is flat, but its orientation is oblique and curves from lateral to medial, rather than horizontal (Fig. 4a and 4b) (Rhoton, 2002a).

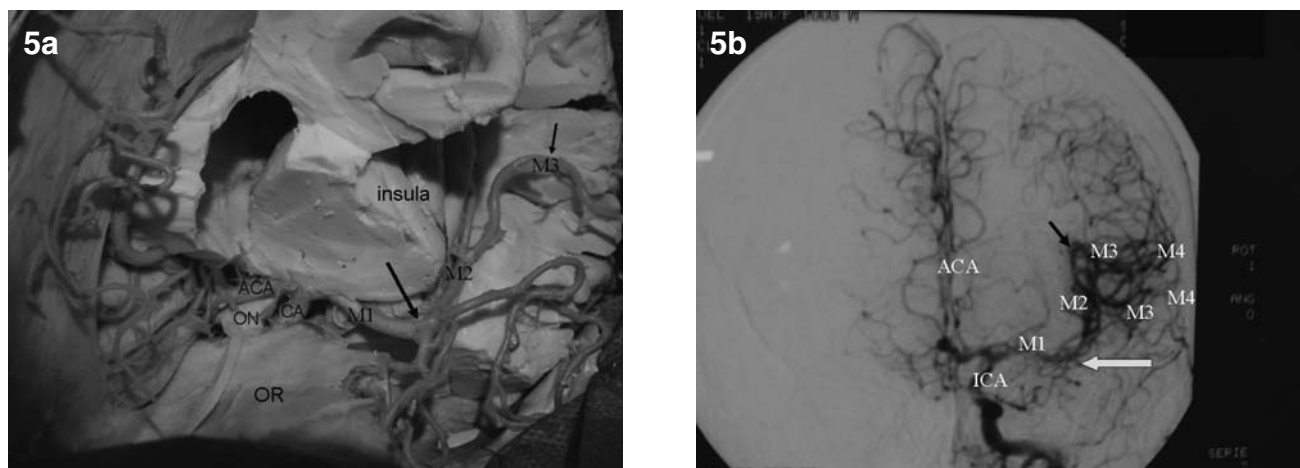


Fig. 5. Arterial relationships of the supratemporal planum. 5a) Superior lateral view of a left cerebral hemisphere. Parts of the frontal and temporal lobes, and superior and inferior aspects of the sylvian operculum were resected. The initial portion (M1) of the middle cerebral artery is related to the planum polare and the inferior aspect of frontal lobe. The M2 segment is in close relationship with the posterior part of the planum polare, insula, inferior insular sulcus and Heschl's gyrus. M1 and M2 transition is marked by the "sylvian knee" (long arrow), located at the level of the limen insulae. The M3 portion contains branches that crosses the superior aspect of the temporal lobe. The anterior-most branches cross over the planum polare and the posterior-most branch (short arrow) crosses the planum temporale. OR: Orbital roof; ON: left optic nerve; ICA: internal carotid artery; ACA: anterior cerebral artery. 5b) Cerebral angiography, frontal view. The different sectors of the middle cerebral artery can be identified in the cerebral angiography. The M1 portion is related to the basal part of the sylvian cistern, the planum polare and basal surface of frontal lobe. The middle cerebral artery knee (big arrow) marks the position of the limen insulae. M2 is related to the inferior insular sulcus, the insula itself, and the superior aspect of the temporal lobe. The M3 segment is located in close relationship with the opercular surfaces of the frontal, temporal and parietal lobes. The inferior-most branches of M3 segment are related to the planum polare and frontal lobe, and the posterior-most ones with the planum temporale. The transition between M2 and M3 (small arrow) marks the superior insular sulcus. M4 are cortical branches radiating from the sylvian fissure to the temporal (inferior) or frontal and parietal lobes (superior). ICA: internal carotid artery; ACA: anterior cerebral artery.

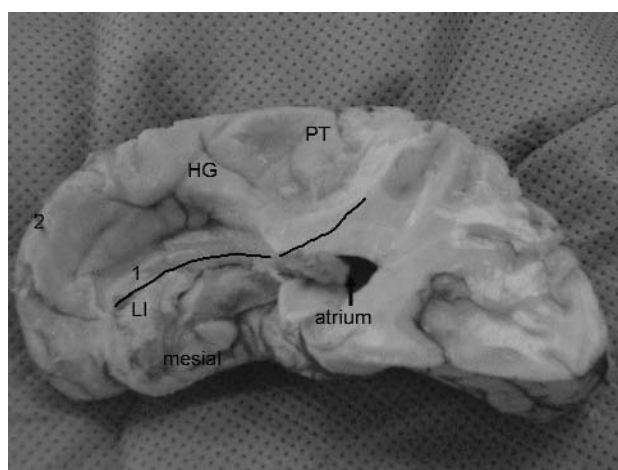


Fig. 6. Superior aspect of the temporal lobe, right hemisphere. The temporal lobe is separated from the hemisphere by cutting the inferior insular sulcus and the white matter of the temporal-occipital lobe (line). The limen insulae (LI) separates the anterior from the posterior parts of the planum temporale. The anterior part of the line demarcates the inferior insular sulcus related to the PP. The different extension of the PP in the inner (1) and lateral aspects (2) can also be seen. HG: Heschl's gyrus; PT: planum temporale; mesial: mesial aspect of the temporal lobe; atrium: atrium of the lateral ventricle.

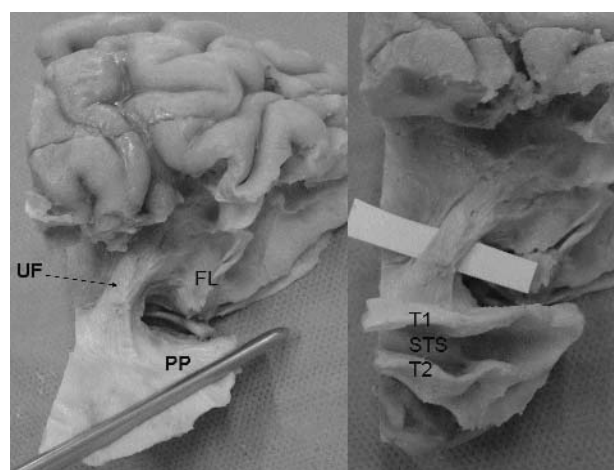


Fig. 7. Anatomic specimen, right cerebral hemisphere, white matter dissection. At the left, the uncinata fasciculus (UF) can be seen, connecting the planum polare (PP) with the frontal lobe (FL). At the right, the uncinata fasciculus is better seen. T1 and T2: white matter of superior and middle temporal gyrus; STS: white matter of the superior temporal sulcus.

The planum polare and the inferior aspect of the frontal lobe form the sphenoidal part of the sylvian fissure and cistern (or sylvian stem), where the M1 portion of the middle cerebral artery is located (Fig. 5a and 5b) (Rhoton, 2002b). The anterior-most part of the planum polare forms the temporal tip, and is related to the lesser wing of the sphenoid bone.

The planum temporale has two parts: an anterior "movable" and a posterior "fixed" part. The limen insulae is the limit between these two parts (Fig. 6). The posterior part of PP is in close relation with the inferior insular sulcus and the insula itself (Figs. 1 and 2). When the limen insulae and the adjacent inferior insular sulcus are dissected with white-matter techniques, the uncinata fasciculus connecting with the frontal and the temporal lobes is seen (Fig. 7).

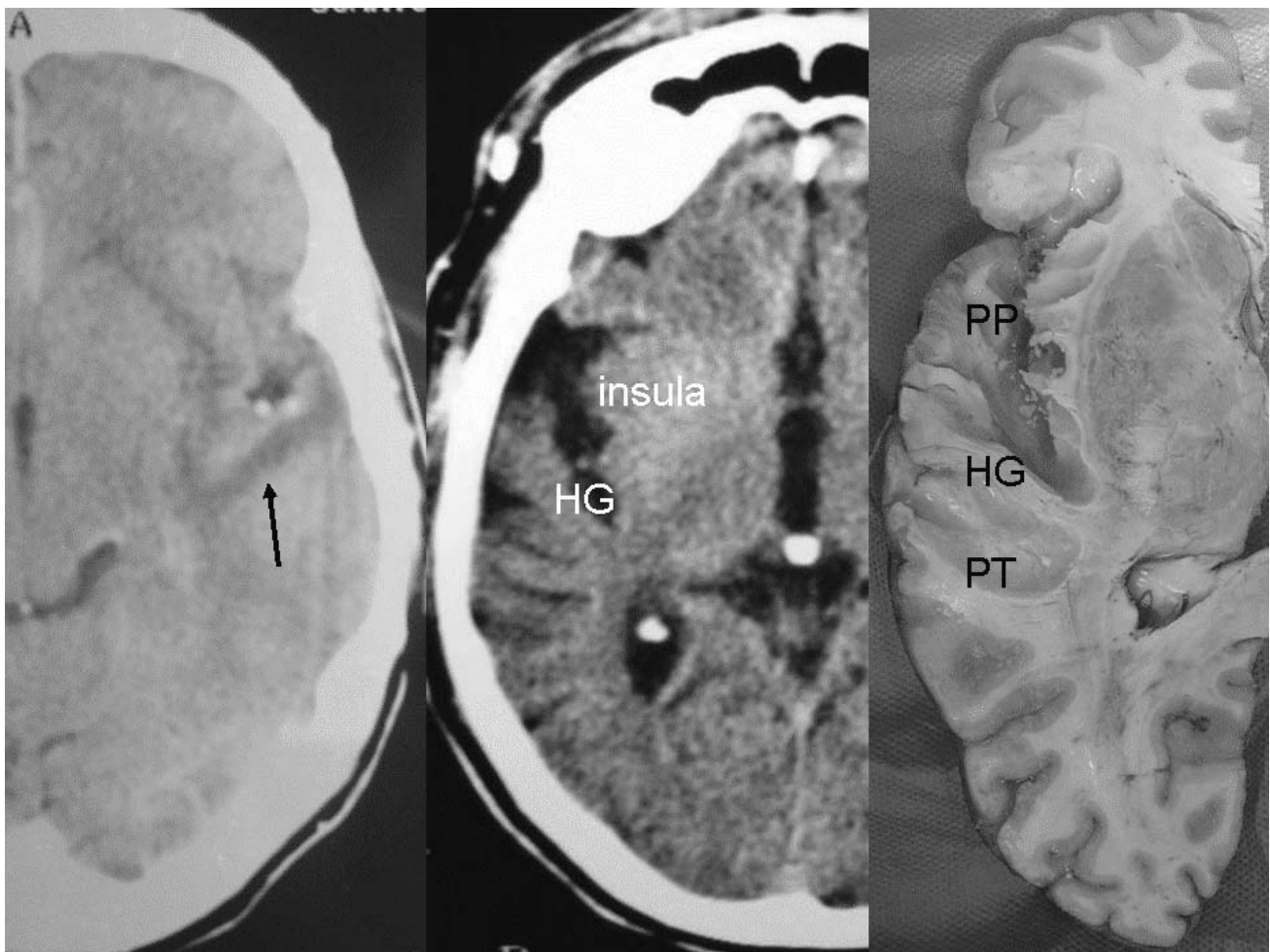


Fig. 8. Heschl's gyrus. At the center, Heschl's gyrus is seen in a CT. At the left, the white matter of Heschl's gyrus is well visible (arrow) in a patient with white matter oedema. At the right, white matter of planum polare (PP), Heschl's gyrus (HG) and planum temporale (PT).

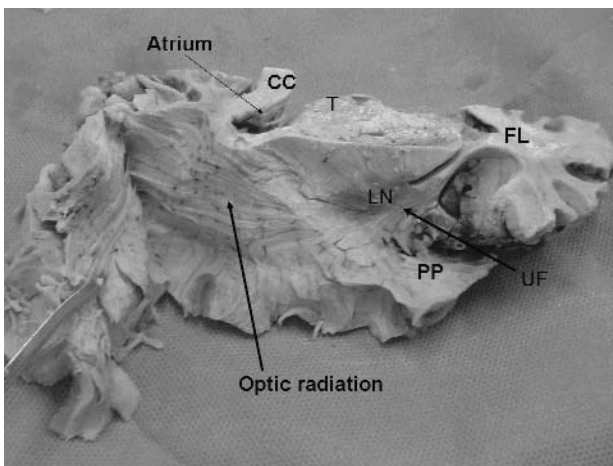


Fig. 9. White matter dissection of the temporal stem, right cerebral hemisphere. In the anterior part of the temporal stem, the uncinate fasciculus (UF) is located, connecting the planum polare (PP) with the frontal lobe (FL). In the posterior part of the temporal stem, the optic radiation is located, in close relationship with the occipital horn and atrium of the ventricular system. CC: corpus callosum; LN: lenticular or ventricular nucleus; T: thalamus.

Transverse temporal gyrus or Heschl's gyrus

This is located at the back of the planum polare, and is separated from it by Holl's limiting sulcus. When this sulcus reaches the lat-

eral aspect of the temporal lobe is called auditory sulcus, and here this sulcus is more prominent (Comair and Tamraz, 2001; Russell and Golfinos, 2003).

Heschl's gyrus is oblique from medial to lateral and from back to front, and the direction of HG can be used as a guide to the ventricular atrium (Fig. 8, right). The inferior insular sulcus corresponds to the temporal stem and in this area of the temporal stem the optic radiation is located (Fig. 9).

We found two cases with double HG: one at the right and another at the left (Fig. 10). HG can be easily recognized in horizontal sections of the brain, but may also be recognized in coronal and parasagittal sections because of its oblique and elevated morphology (Figs. 3 and 11).

Planum temporal

This is the posterior-most part of the planum supratemporale, and it is located at the back of HG. Its anatomical limits are: on the medial side, the inferior insular sulcus; on

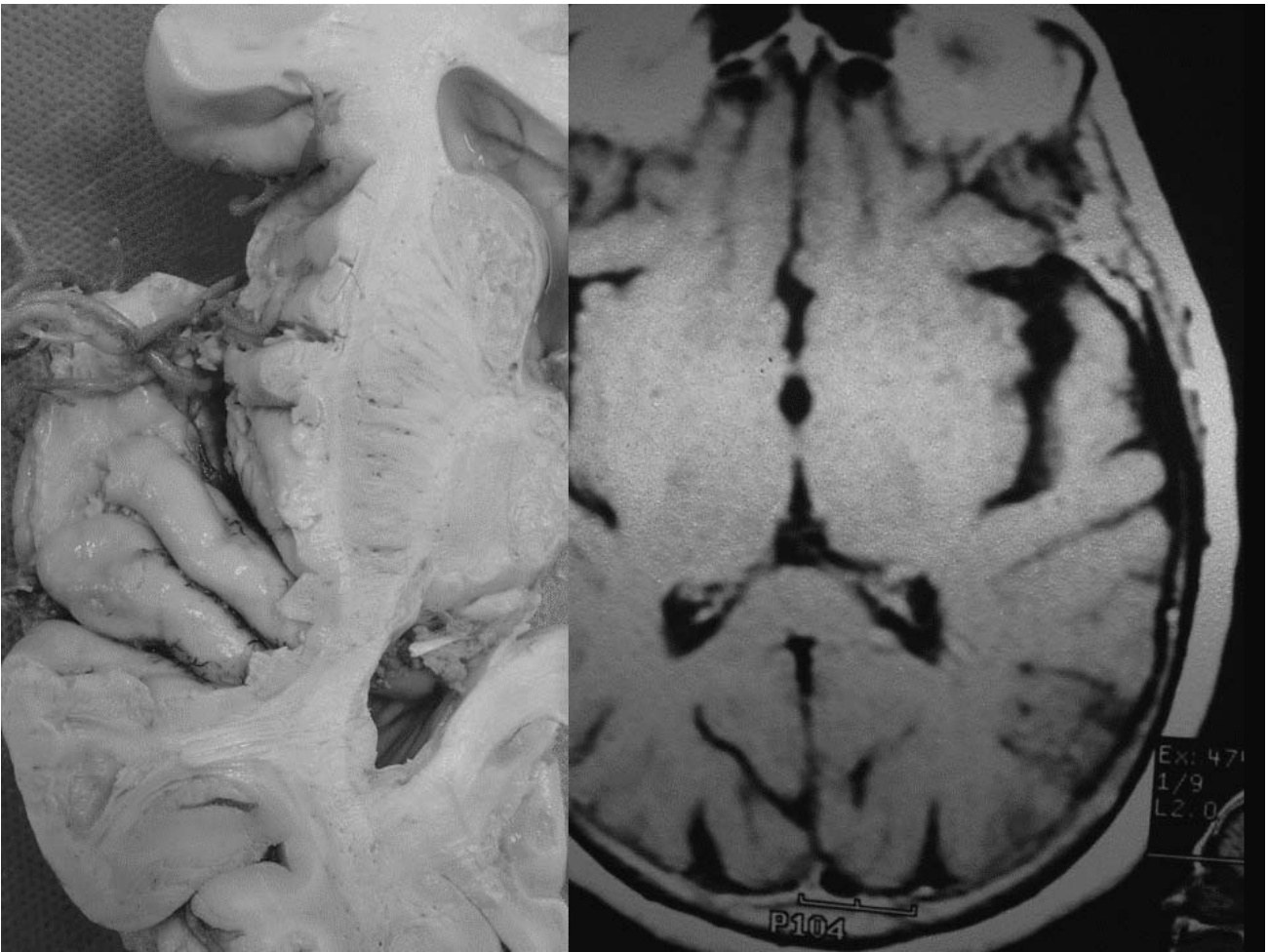


Fig. 10. Double Heschl's gyrus. At the left, there is an anatomical specimen with a double Heschl's gyrus, at the right, the MRI correlation.

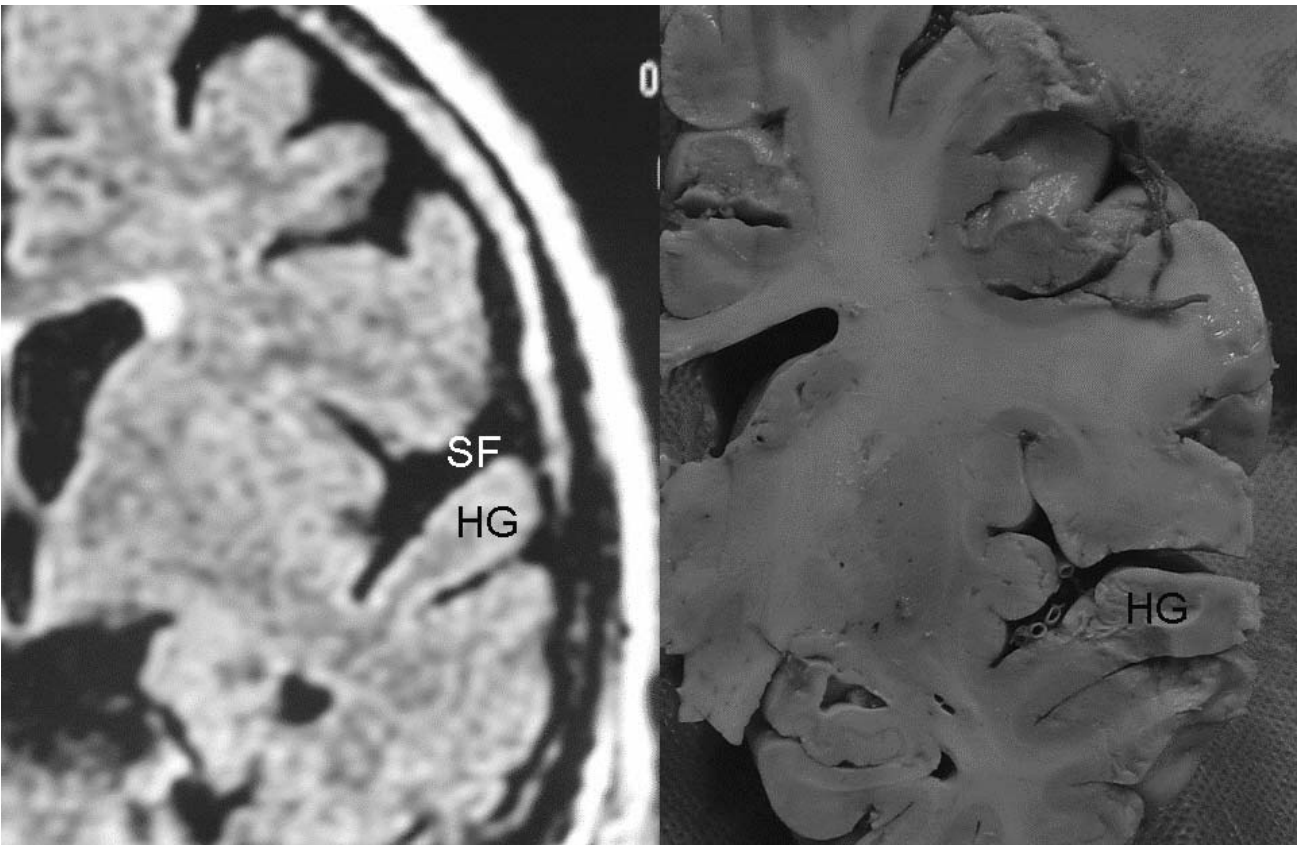


Fig. 11. Heschl's gyrus in coronal sections of brain and MRI image. HG: Heschl's gyrus; SF: Sylvian fissure.

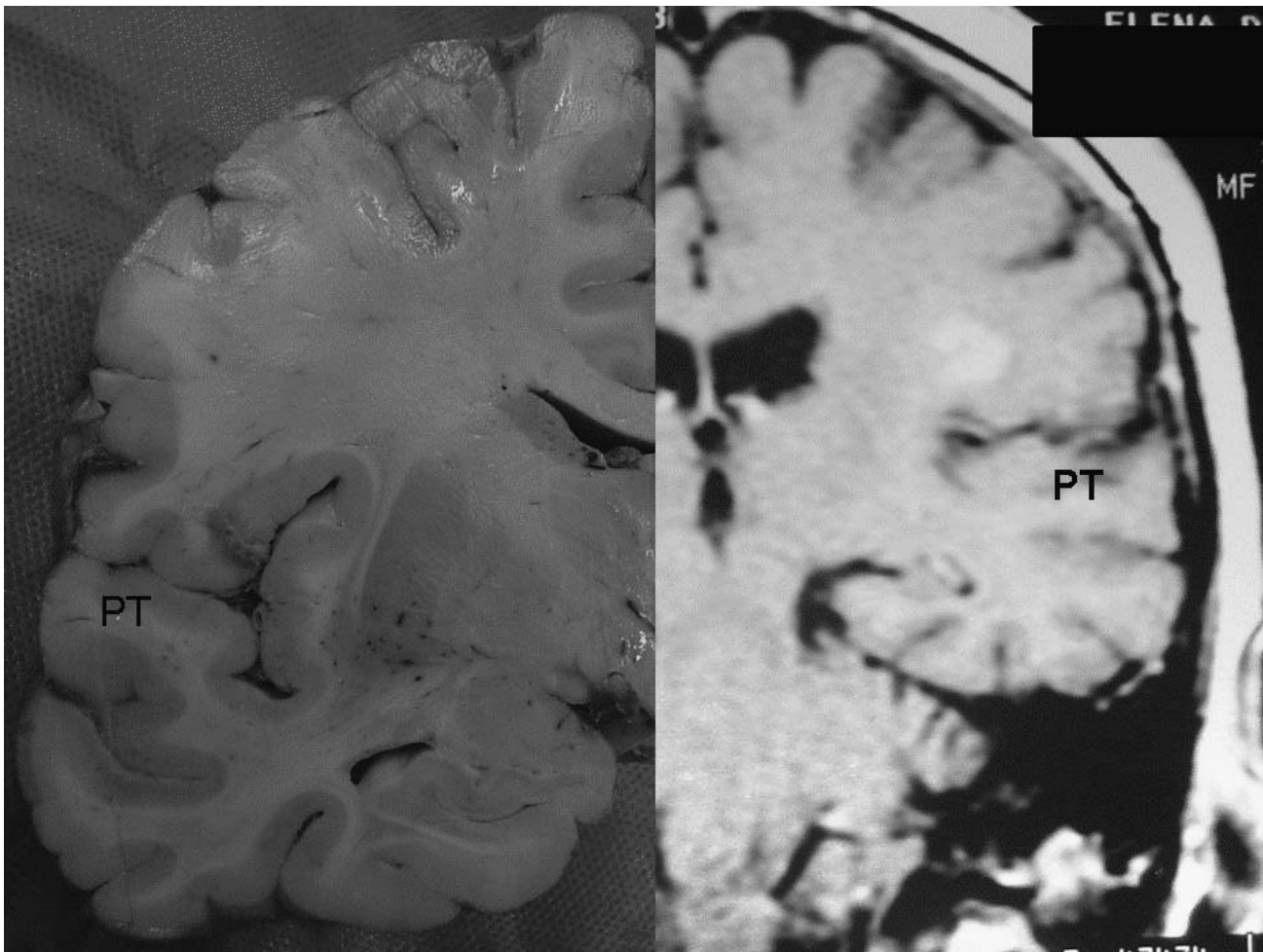


Fig. 12. Planum temporale in an anatomical specimen and in coronal section (MRI). PT: planum temporale.

the lateral side, the union of the lateral and superior aspects of temporal lobe; its anterior limit is the transverse temporal sulcus and the posterior limit is the prolongation to the midline of the end of sylvian fissure (Moffat et al., 1998; Ratnanather et al., 2003).

The planum temporale (PT) is flat and horizontal, but has a small sulcus and gyrus. The planum temporale can be recognized in coronal and sagittal sections by its horizontal disposition (Figs. 3 and 12). Figure 13 shows a CT reconstruction of the temporal lobe with its parts.

DISCUSSION

Most anatomical articles have dealt with the mesial aspect of the temporal lobe ever since its importance in epilepsy surgery was noted (Wen et al., 1999). However, the planum supratemporale is also important because it forms the limits of the sylvian fissure and the sylvian cistern, whose contents are the sylvian artery and the sylvian veins

(superficial and deep). The sylvian fissure is a very important landmark in the lateral aspect of the cerebral hemispheres and is the route for trans-sylvian approaches. This kind of approach is used in: 1) cerebro-vascular surgery of the anterior circle of Willis, 2) some aneurysms of the posterior part of the circle of Willis, 3) lesions located in the cavernous sinus, 4) some lesions in the mesial aspect of the temporal lobe, 5) tumor lesions located in the hypophysis gland or the suprasellar area, 6) hematomas or tumors of the insula, the external basal ganglia area and ventricular atrium (Campero et al., 2006; Nagata and Sasaki, 2005).

All parts of the PS can be seen with imaging studies, such as MRI or cranial CT. In MRI images, all the structures are better seen than in CT, and some degree of cerebral atrophy is needed to clearly see these structures in CT images. In cerebral arteriography, these structures can be seen “indirectly” from the relationships that they develop with branches of middle cerebral artery (Fig. 5b).

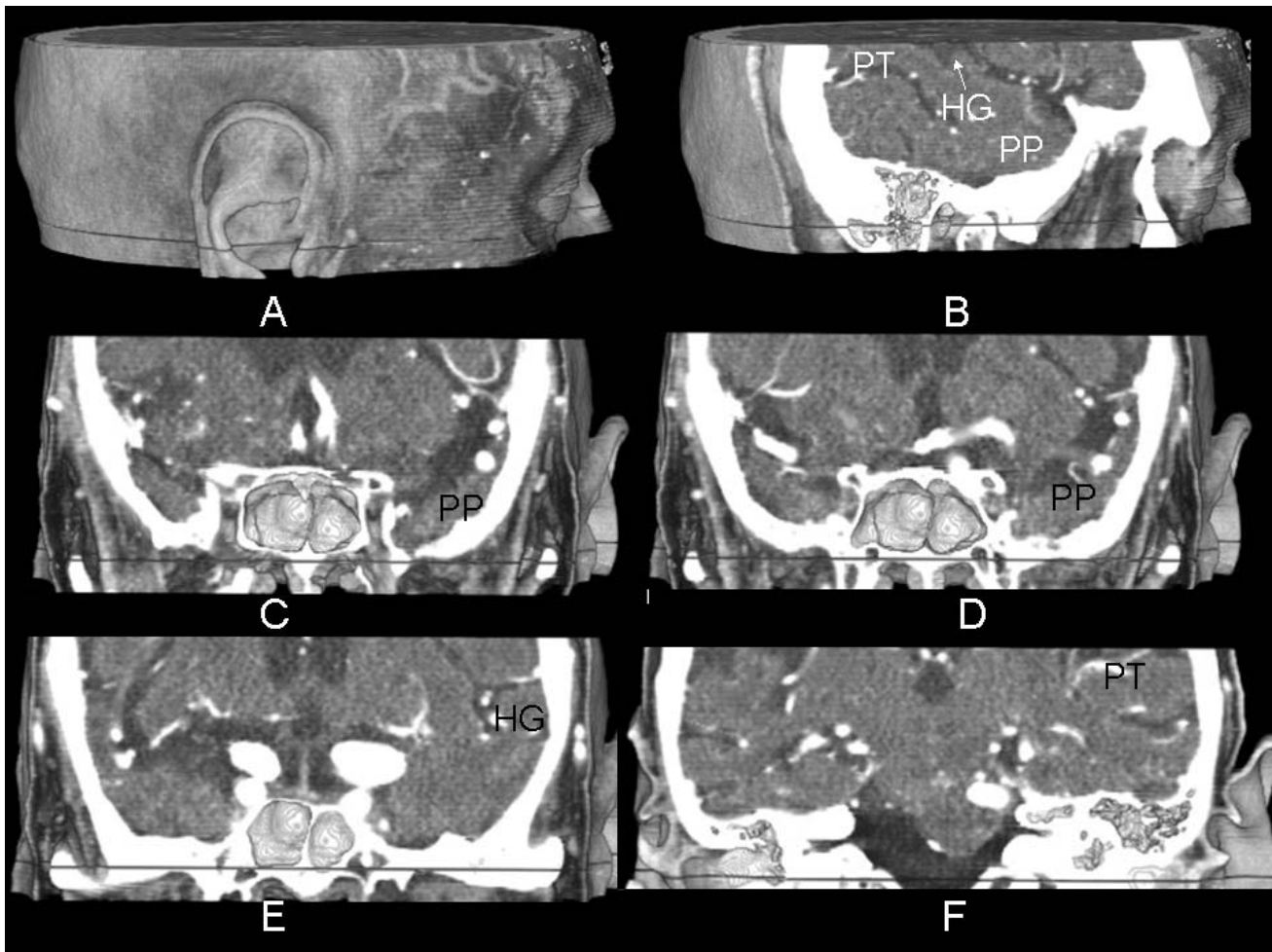


Fig. 13. 3D CT reconstruction. A: 3D reconstruction of the temporal region; B: Parasagittal section showing the planum polare (PP), Heschl's gyrus (HG) and the planum temporale (PT). C-F: coronal sections from the front to the back showing the different parts of the planum supratemporale.

Planum polare

This is the anterior-most part of the planum supratemporale, and functionally it forms the lateral basal circuit of the limbic system with the basal and internal frontal lobe.

The anterior part of the planum polare, located anterior to the limen insulae, can be retracted with a brain spatula with relatively little damage to insular structures if an appropriate arachnoid dissection is performed. However, in the posterior part of the PP the surgeon must be very careful to not exert too much pressure on the inner aspect of the planum polare, where it is fixed to the insula by the inferior insular sulcus. The inferior insular sulcus is the anatomical landmark to the temporal stem, where we found the arcuate and temporo-pontine fasciculus, and in the most posterior part, the geniculocalcarine fasciculus.

Heschl's gyrus

The transverse temporal gyrus, or Heschl's gyrus, is recognized because of its oblique

direction. Functionally, Heschl's gyrus is the primary auditory area and has a tonotopic organization (Carpentier et al., 2002; Roper and Rhoton, 1997). It also has a right-left specialization, with the right HG being specialized in spatial discrimination (music) and the left in temporal discrimination (speech) (Russell and Golfinos, 2003). Some studies show that the left HG is larger than the right one (Leonard et al., 2001). Epileptic discharges from Heschl's gyrus produce auditory hallucinations (Zeman, 2005).

Generally, it is simple, but in 15% of individuals it can be double. Such a condition is more frequent on the right side (Carpentier et al., 2002) (Fig. 8). Some pathological entities such as dyslexia or attention deficit have been associated with a high incidence of perisylvian cortex anomalies and, specifically, a double Heschl's gyrus. This condition is more frequent on the left in these patients (Leonard et al., 2001).

In the surgical setting, HG can be used as a guide to the ventricular system; specifically to the ventricular atrium (Nagata and Sasaki, 2005).

If the sylvian fissure is opened and the HG is recognized, its direction can serve as a guide to the ventricular atrium, which is located 10 to 15 mm from the insular cortex. The total length of HG is 35 to 40 mm, so the distance between the lips of the sylvian fissure and the ventricular atrium is 45 to 55 mm (Tanriover et al., 2004).

However, in this area, at the level of the temporal stem, the retrolenticular portion of the internal capsule is located, with the possibility of damaging the geniculocalcarine fasciculus. Nagata y Sasaki (2005) stated that if insular corticectomy is made above the inferior insular sulcus, damage to the optic radiation can be prevented.

Planum temporale

Functionally, the left planum temporale (PT) is involved in language, and some studies using software to calculate the area of the PT, have shown that the extension of the left PT is larger than the right one (Habib and Robichon, 1999; Moffatt et al., 1998).

In cerebral angiography, the posterior-most branch of the sylvian artery (M3 segment) can serve as a guide to recognize the planum temporale. In the lateral projection, it corresponds to the posterior sylvian point (Moran et al., 1997; Osborn, 1999).

Although most of this portion of the supratemporal planum is flat, it has small sulci and gyri that increase its surface area (Ratnanather, 2003). The spatial orientation of the PT is horizontal (Fig. 10).

Within the sylvian fissure, the planum polare, Heschl's gyrus and the planum temporale are related to the middle cerebral artery and its branches. Therefore, upon analyzing a brain arteriography and considering the morphology of the artery, it is possible to indirectly recognize different parts of the temporal lobe (Moran et al., 1997; Osborn, 1999).

For instance, the curved interval between the M1 and M2 segments of the artery runs parallel to the limen insulae. At the sylvian fissure, the course of the major trunks of the MCA marks the inferior insular sulcus while its anterior branches demarcate the anterior insular sulcus. The place at which the posterior-most branches of the MCA change their

course towards the cortex is called "the sylvian point".

The posterior-most portion of the planum temporale is identified by the course of the posterior-most branch of the MCA. In contrast, the horizontal course of the MCA branches (M3 segment) demarcates the frontoparietal and temporal slopes of the Sylvian operculum. These anatomical and angiographical landmarks allow the construction of the sylvian triangle which draws the insular limits in angiographical studies (Fig. 11).

We can conclude that Anatomy is the basis for an adequate recognition of the different parts of the planum supratemporale. In the present article, the authors correlate the normal anatomy of the planum supratemporale with imaging studies, such as MRI, CT, and cerebral angiography.

REFERENCES

- BINDER J (1997). Functional magnetic resonance imaging. Language mapping. *Neurosurg Clin NA*, 8: 383-392.
- CAMPERO A, TROCCOLI G, MARTINS C, FERNANDEZ-MIRANDA FC, YASUDA A, RHOTON AL Jr (2006). Microsurgical approaches to the medial temporal region: an anatomical study. *Neurosurgery*, 59 (ONS Suppl 4): 279-308.
- CARPENTIER A, CLEMENCEAU S, COSTABLE T, CORNU P, BAULAC M, VAN EFFENTERRE R (2002). Identification of Heschl's gyrus in functional IRM. Neurosurgical applications. *Neurochirurgie*, 48: 80-86.
- COMAIR Y, TAMRAZ JC (2001). Cortical anatomy: normal and abnormal sulcal and gyral patterns. In: Wyllie E (ed.). *The treatment of epilepsy. Principles and practice*. 3rd ed. Lippincott, Williams and Wilkins, Philadelphia, pp 79-92.
- FRIED I (1997). Anatomic temporal lobe resections for temporal lobe epilepsy. *Neurosurg Clin N A*, 4: 233-242.
- HABIB M, ROBICHON F (1999). Dominance hémisphérique. *Encycl Med Chir (Elsevier, Paris)*, Neurologie 17-022-C-10,8p.
- LEONARD CM, ECKERT MD, LOMBARDINO LJ, OAKLAND T, KRANZLER J, MOHR CM, KING WM, FREEMAN A (2001). Anatomical risk factors for phonological dyslexia. *Cerebral Cortex*, 11: 148-157.
- MOFFAT SD, HAMPSON E, LEE DH (1998). Morphology of planum temporale and corpus callosum in left handers with evidence of left and right hemisphere speech representation. *Brain*, 121: 2369-2379.
- MORAN CJ, KIDO DK, CROSS DT III (1997). Cerebral vascular angiography: indications, technique, and normal anatomy of the head. In: Baum S (ed.). *Abrams Angiography*. 4th ed. Little, Brown and company, Boston, pp 241-283.
- NAGATA S, SASAKI T (2005). Lateral transsulcal approach to asymptomatic trigonal meningiomas with correlative microsurgical anatomy: technical case report. *Neurosurgery*, 56 (ONS Suppl 2): E438.

- OSBORN AG (1999). *Diagnostic cerebral angiography*. 2nd ed. Lippincott, Williams and Wilkins. Philadelphia.
- RATNANATHER JT, BARTA PE, HONEYCUT NA, LEE N, MORRIS HM, DZIORNY AC, HURDAL MK, PEARLSON GD, MILLER MI (2003). Dynamic programming generation of boundaries of local coordinatized submanifolds in the neocortex: application to the planum temporale. *Neuroimage*, 20: 359-377.
- RHOTON AL Jr (2002a). The cerebrum. *Neurosurgery*, 51(Suppl): S1-S52.
- RHOTON AL Jr (2002b). The supratentorial arteries. *Neurosurgery*, 51(Suppl): S53-S120.
- ROPER SN, RHOTON AL Jr (1997). Surgical anatomy of the temporal lobe. *Neurosurg Clin N A*, 2: 223-231.
- RUSSELL SM, GOLFINOS JG (2003). Amusia following resection of a Heschl gyrus glioma. Case report. *J Neurosurg*, 98: 1109-1112.
- TANRIOVER N, RHOTON AL JR., KAWASHIMA M, ULM AJ, YASUDA A (2004). Microsurgical anatomy of the insula and the sylvian fissure. *J Neurosurg*, 100: 891-922.
- WEN HT, RHOTON AL JR, DE OLIVEIRA E, CARDOSO AC, TEDESCHI H, BACANELLI M, MARINO R Jr (1999). Microsurgical anatomy of the temporal lobe. Part 1: mesial temporal lobe anatomy and its vascular relationships as applied for amygdalohippocampectomy. *Neurosurgery*, 5: 549-592.
- ZEMAN A (2005). Tales from the temporal lobes. *N Eng J Med*, 352: 119-121.