

# Some aspects of the neurometrics of the Sahel goat in Nigeria

J.O. Olopade<sup>1</sup>, H.D. Kwari<sup>2</sup>, J.C. Shawulu<sup>2</sup>, M. Ofua<sup>1</sup> and S.K. Onwuka<sup>1</sup>

1- Department of Veterinary Anatomy, University of Ibadan, Nigeria

2- Department of Veterinary Anatomy, University of Maiduguri, Nigeria

## SUMMARY

A study of the neurometrics of the Sahel goat was done using sixteen goats. The mean brain weight obtained was 85.13g. The mean brain length, depth, cerebral length, depth and cerebellar length and depth were 9.38cm, 4.34cm, 5.78cm, 4.34cm, 2.79cm and 2.43cm respectively, while the relative brain weight was 0.004. Animals below one year of age and 20kg body weight had significantly higher relative brain weight than animals at and above this age and body weight groups. Female goats had a lower mean brain weight than males. There was a strong positive correlation between body weight and brain depth while a strong negative correlation existed between body weight and relative brain weight.

The result is added information to the comparative neuroanatomy of small ruminant breeds and should serve as baseline research data in applied fields.

**Key words:** Neurometrics – Brain – Sahel goat

## INTRODUCTION

The Sahel goat is kept mainly by the Maure, Fulani and Tuareg tribes in the Sahel Zone, south of the Sahara from Chad to Senegal and they are range goats kept mainly for milk and meat by nomad herders (Gall, 1996).

There are different types of this breed; the one in Nigeria is predominantly the Borno white ecotype (Kwari, 2001). Basic research into the breed includes fetal studies on the calvarium (Silvachelvan, 1995) and morphological and metric studies of the different ecotypes of the breed (Kwari, 2001) among others.

Little is known, particularly in recent times, about the neurobiology of this breed, and the Sahel appears to be the only major breed of goat in Nigeria for which neurometrical parameters have not been reported (Olopade and Onwuka, 2002; Onwuka et al., 2002).

The aim of this work is to conduct a neurometrical study on the brain of the Sahel breed of goats in Nigeria.

## MATERIAL AND METHODS

A total of sixteen Sahel goats (ten males and six females) were used for this study. The live weights of the animals were taken using a weighing scale prior to slaughter. The goats were then decapitated after restraint at the occipito-atlantal junction. The severed heads were kept at -20°C and the brains were later removed without chemical fixation according to the method used by Olopade et al. (2005).

Correspondence to:

Dr. James Olopade. Craniofacial Anatomy and Environmental Neuroscience Unit, Department of Veterinary Anatomy, University of Ibadan, Nigeria. E-mail: jkayodeolopade@yahoo.com / jo.olopade@mail.ui.edu.ng

Submitted: February 22, 2007

Accepted: July 3, 2007

Each brain was weighed using a Microwa Swiss® digital weighing machine while the linear measurements taken were according to the landmarks in Figs. 1 and 2.

The values obtained in this study were analysed using the Pearson correlation students t-test at 5% level of significance and presented as means ± S.D.

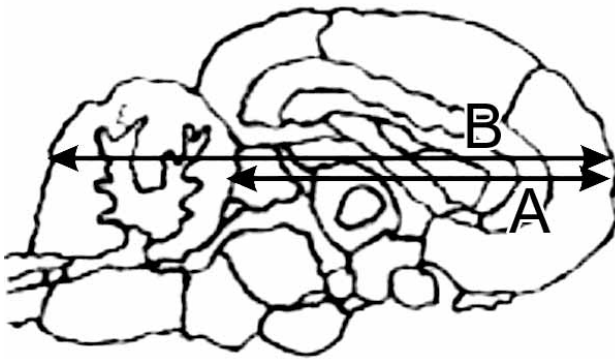


Fig. 1. Schematic diagram of brain of Sahel goat showing the landmarks used for morphometry. A=LOC, B=LOB.

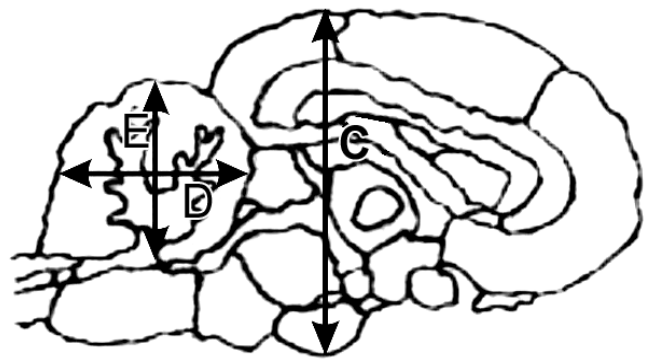


Fig. 2. Schematic diagram of the brain of Sahel goat showing the landmarks used for morphometry. C=DOB, D=LOCB, E=DOCB.

RESULTS

Table 1. Neurometrical data of the Sahel goat, n-16.

WOA (kg)	WOH (kg)	WOB (g)	LOB (cm)	DOB (cm)	LOCB (cm)	DOCB	LOC (cm)	R <sub>1</sub>	R <sub>2</sub>
19.63	1.31	85.13	8.38	4.34	2.79	2.43	5.78	4.41	67.03
± 2.90	± 0.25	±1.97	±0.64	±0.31	±0.37	±0.37	±0.27	±0.17	±3.42

Table 2. Weight-based neurometrical data of the Sahel goat.

	WOA (kg)	WOH (kg)	WOB (g)	LOB (cm)	DOB (cm)	LOCB (cm)	DOCB	LOC (cm)	R <sub>1</sub>	R <sub>2</sub>
≥20kg n=7	22.29 ±1.67	1.41 ±0.16	86.31 ±8.58	8.21 ±0.25	4.44 ±0.28	2.70 ±0.48	2.35 ±0.24	5.79 ±0.24	3.87 ±0.26	61.55 ±8.03
<20kg n=9	17.56 ±1.60	1.23 ±0.29	84.20 ±7.68	8.51 ±0.83	4.26 ±0.31	2.86 ±0.26	2.50 ±0.29	5.78 ±0.30	4.83* ±0.62	71.28 ±16.00

Table 3. Age-based neurometrical data of the Sahel goat.

	WOA (kg)	WOH (kg)	WOB (g)	LOB (cm)	DOB (cm)	LOCB (cm)	DOCB	LOC (cm)	R <sub>1</sub>	R <sub>2</sub>
≥1 yr n=7	20.86 ±2.61	1.35 ±0.21	83.39 ±5.60	8.20 ±0.22	4.47 ±0.22	2.65 ±0.40	2.48 ±0.18	5.72 ±0.27	4.03 ±0.37	62.51 7.90
<1yr n=9	18.66 ±2.87	1.28 ±0.29	86.48 ±9.39	8.52 ±0.83	4.23 ±0.33	2.90 ±0.33	2.39 ±0.33	5.82 ±0.27	4.71* ±0.75	70.54 ±16.50

Table 4. Sex-based neurometrical data of the Sahel goat.

	WOA (kg)	WOH (kg)	WOB (g)	LOB (cm)	DOB (cm)	LOCB (cm)	DOCB	LOC (cm)	R <sub>1</sub>	R <sub>2</sub>
Male n=10	18.80 ±2.62	1.31 ±0.28	85.44 ±6.75	8.22 ±0.46	4.25 ±0.30	2.64 ±0.31	2.50 ±0.28	5.90* ±0.21	4.63 ±0.76	67.94 ±15.98
Female n=6	21.00 ±3.03	1.32 ±0.22	84/60 ±10.19	8.65 ±0.85	4.48 ±0.27	3.00 ±0.37	2.33 ±0.26	5.58 ±0.25	4.06 ±0.37	65.50 ±9.86

\* Significantly higher at p < 0.05

WOA = Weight of animal  
 LOCB = Length of cerebellum  
 WOH = Weight of head  
 DOB = Depth of brain  
 WOB = Weight of brain

DOCB = Depth of cerebellum  
 LOB = Length of brain  
 R<sub>1</sub> = Relative brain weight(x10<sup>-2</sup>)  
 LOC = Length of cerebrum  
 R<sub>2</sub> = Ratio of weight of brain to weight of head(x10<sup>-2</sup>)

The mean weight of the Sahel goat brain in this study was 85.13 g, while the weight of head was 1.31 kg. The length of the brain, brain depth, cerebral length and depth were 8.38 cm, 4.34 cm, 5.78 cm, 2.78 cm and 2.43 cm, respectively. The relative brain weight was 0.004 while the brain accounted for about 7% of the weight of the head.

Female Sahel goats had a significantly lower ( $p < 0.005$ ) brain length than the males. Animals of one year of age and above had a significantly lower relative brain weight ( $p < 0.05$ ) than animals below one year; likewise for animals 20 kg and above as compared to those below this body weight.

Animals below one year of age had higher values for brain length, cerebellar length and cerebral length than animals of one year and above, although these values were not significant.

There was a strong positive correlation ( $p < 0.01$ ) between body weight and brain depth while a strong negative correlation was found between body weight and relative brain weight, and between the weight of the Sahel head and the ratio of the brain to the head weight. Although there was a negative correlation ( $p < 0.05$ ) between age and the relative brain weight, sex and the cerebral length, brain depth and relative brain weight, and between cerebral and cerebellar lengths, a positive correlation ( $p < 0.05$ ) was found between cerebral length and relative brain weight.

## DISCUSSION

The brain weight of 85.13 g obtained in the study was similar to that obtained for Red Sokoto goats, which was 85.85 (Olopade and Onwuka, 2002), and higher than the 56.89 g obtained for West African Dwarf goats (Onwuka et al., 2002). The Sahel, however, at 0.004 has the lowest relative brain weight when compared to the 0.006 of the other two breeds (Olopade and Onwuka, 2002; Onwuka et al., 2002). This is most likely the result of the bone weight of the long-legged Sahel goat. The relative brain weight of 0.004 or 1:250 is also lower than the 1:40, 1:100, 1:125 of humans, cats and dogs respectively but higher than the 1:550, 1:560 and 1:600 of the lion, elephant and horse respectively (Kuhlenbeck, 1973).

The linear measurements of 8.38 cm, 4.33 cm, 2.43 cm and 5.78 cm for LOB, DOB,

DOCB and LOC were lower than the 9.96 cm, 4.66 cm, 3.61 cm, and 6.55 cm obtained for the Red Sokoto while the 2.79 cm of the cerebellar length of the Sahel was longer in comparison with the Red Sokoto's 2.66 cm. Our data also reveal that the Sahel has a relatively longer cerebellum, since the LOCB was higher than the DOCB, contrary to what has been recorded in the other breeds in Nigeria (Olopade and Onwuka, 2002; Onwuka et al., 2002).

The animals of one year of age and above, and animals of 20 kg and above had slightly lower values for the LOB and LOCB than animals below those ages and body weights. This suggests that as the animal begins to grow in age and put on weight, a rostrocaudal compression occurs in the brain development of this breed. Since the LOCB is higher than the DOCB, the results obtained in this study thus suggests that the much greater difference between the LOCB and DOCB in favor of the former could have occurred in the early months of the life of the Sahel goat, as showed in Table 3. The relative similarity in brain weights between the age groups (1 year) and weight group (20 kg) and thus the significantly higher values of relative brain weight for animals below one year and below this weight group, together with the negative correlations obtained between these groups and relative brain weights suggest that the Sahel breed of goats attains most of its brain weight at a relatively early age; this is not the case of the West African Dwarf sheep (Olopade et al., 2005). This occurrence may translate to early independence and cognitive function for young Sahel goats.

The heavier brains of Sahel males obtained in this study is inconsistent with the results obtained for West African Dwarf goats and sheep, and for Red Sokoto goats (Onwuka et al., 2002, Olopade et al., 2005; Olopade and Onwuka, 2002) and this may partially be an outcome of the significantly lower cerebral length in the females studied here. This outcome is, however, in agreement with human studies where females had smaller brains (Skulleruel, 1985), and males were also found to have a larger cerebral volume (Giedd et al., 1987).

The cerebellum is involved in motor learning and cognitive function in humans, and animal experiments have found structural changes in the cerebellum in response to long-term motor skill activity (Hutchin-

son et al., 2003). The relatively longer cerebellum in this study may indicate a response to a specialized motor activity in the Sahel goat in comparison to other breeds. The specialized activity could well be an adaptive response of skillful movement in the Sahel due to having long legs. A significantly greater absolute cerebellar volume has been found in male musicians as compared to male non-musicians (Hutchinson et al., 2003).

The present results are a contribution to the neurometrical data of small ruminant breeds in Nigeria and should find application in comparative neuroanatomy, neurophysiology, anesthesiology, and in geriatric and gender studies of the brain.

#### ACKNOWLEDGEMENTS

The authors are grateful to Drs. Agbashe and Fatola, then undergraduate project students, for their help in the bench work.

#### REFERENCES

- GALL CF (1996). *Goat breeds of the World*. Magret Verlag, Weikersheim, Germany.
- GIEDD JN, GASTELLANOS FS, RYAPAKSE JC, VAITUZS AC and RAPOPORT JL (1997). Sexual dimorphism of the developing human brain. *Neuropsychopharmacol Biol-Psychiatry*, 21: 1185-1201.
- HUTCHINSON S, LEE LH, GAAB N and SCHLAUG G (2003). Cerebellar volume of musicians. *Cerebral Cortex*, 13: 943-949.
- KUHLENBECK H (1973). *Central Nervous System of Vertebrates*, Vol. 3, Part II. Arnold, Backlin-Stresse, New York.
- KWARI HD (2001). A morphological study of ecotypes of Sahel goats in Borno State with special reference to sexual dimorphism. Ph.D. Thesis. Department of Veterinary Anatomy, University of Maiduguri.
- OLOPADE JO and ONWUKA SK (2002). Preliminary morphometric investigation of the brain of Red Sokoto (Maradi) goat. *Trop Vet*, 21: 80-84.
- OLOPADE JO, ADEJUMO DO, LADOKUN AO, OKANDEJI ME, ADESHINA AA and ONWUKA SK (2005). Cortical concentrations of metals and protein in the brain of two breeds of goats in Nigeria. *African J Biomed Res*, 8: 191-196.
- OLOPADE JO, ONWUKA SK, BALOGUN BA and OKE BO (2005). Morphometric investigation of the brain of West African Dwarf Sheep in Nigeria. *Int J Morphol*, 23: 99-104.
- ONWUKA SK, OLOPADE JO, BABAJIDE BF and EIMIYIEN IO (2002). Preliminary morphometric investigation of the brain of the West African Dwarf Goat. Proceedings of the 39<sup>th</sup> Nigerian Veterinary Medical Association Conference, Sokoto.
- SILVACHELVAN MN, HARARA BU and CHIBUZO BA (1995). Fetal development of the calvarium in Sahel goats. Its post natal significance. *Trop Vet*, 13: 109-118.
- SKULLERUD K (1985). Variations in the size of the human brain. Influence of age, sex, body length, body mass index, alcoholism, Alzheimer changes, and cerebral atherosclerosis. *Acta Neurol Scand Suppl*, 102: 1-94.