

Unilateral facial arteriovenous communication and its clinical implications

S. Prakash, S. Das and R. Suri

Department of Anatomy, Maulana Azad Medical College, New Delhi-110002, India

SUMMARY

Any abnormal communication between an artery and a vein is commonly referred to as arteriovenous malformation (AVM) or arteriovenous fistula (AVF). Such abnormal communications may be congenital or acquired. Communication between facial arteries and veins is of great clinical significance with respect to facial surgery. Anatomical knowledge of abnormal communications between arteries and veins may be important for vascular surgeons and radiologists performing angiographic studies. The present study reports the communication between facial artery and vein detected on the right side in the cadaver of a 52 year old man. This communication was situated at a distance of 2.5 cm from the angle of the mandible. Existence of such arteriovenous communications between facial vessels has important clinical implications.

Key Words: Arteriovenous malformation – Arteriovenous fistula – Arteriovenous communication

INTRODUCTION

The earliest description of AVM was the reporting of snakes covering the head of the Greek God Gordon's head (Khodad, 1973). AVM have also been termed as arteriovenous aneurysms, arteriovenous fistulas, abnormal arteriovenous communications, plexiform angiomas (Schultz and Hermosillo, 1980). The first AVF was descri-

bed as early as in 1758 by William Hunter. These communications are congenital or acquired.

AVM are more common in the scalp as compared to any other part of the body (Watson and McCarthy, 1940). The incidence of such vascular malformations of the mandible and maxilla are rare (Hoey et al., 1970). The AVM present since early childhood may undergo hypertrophy in later adulthood and thus require immediate treatment. Small fistulas may be detected by color Doppler and dilated arteries are detected by angiography (Sabiston and Lyerly, 1997).

The angular vein formed by the union of frontal and the supraorbital vein descends on the side of the root of the nose to continue as the anterior facial vein (Standring, 2005). The anterior facial vein runs posterior to the facial artery, descending over the superficial surface of the masseter to join the posterior facial vein to form the common facial vein (Standring, 2005). The facial artery is the main artery of the face and is a branch of the external carotid artery. It appears at the lower border of the mandible, passes from superficial to the submandibular gland and, at the angle of the mouth, gives off inferior labial and superior labial arteries supplying the lower and upper lips respectively (Standring, 2005). It then ascends towards the medial angle of the eye as the angular artery (Standring, 2005). In the present study, the facial vein and the facial artery communicated with each other on the right side at a distance of 2.5 cm from the angle of the mandible. Awareness of such abnormal communication between the facial artery and the vein may be important for clinicians, vascular surgeons, maxillo facial surgeons and radiologists.

Correspondence to:

Dr. Srijit Das, Department of Anatomy, Maulana Azad Medical College, Bahadur Shah Zafar Marg, New Delhi-110002, India.

Phone: 91-11-26889248. E-mail: das_srijit23@rediffmail.com

Submitted: April 14, 2005
Accepted: August 18, 2005

MATERIAL AND METHODS

During routine cadaveric dissection we detected an abnormal communication between the facial artery and the vein on the right side of the cadaver of a 52 year old man who died of respiratory illness. The facial vessels were delineated and an appropriate photograph was taken (Fig. 1).

OBSERVATIONS

On the right side

The facial artery originated from the external carotid artery and it crossed the base of the mandible, at the antero-inferior angle of the masseter to reach the facial region. It gave off superior and inferior labial arteries at a point 3.7 cm inferolateral to the angle of the mouth. The artery further traversed towards the medial angle of the eye. The facial vein traversed much posterior to the facial artery and at a point antero-inferior to the angle of the mandible; facial vein was joined by anterior division of the retromandibular vein. A vertical communicating channel measuring 2.2 cm in length connected the facial artery and the vein. The terminal branches of facial nerve emer-

ged at the anterior border of the parotid gland and traversed superficial to the facial vessels and other collateral branches.

On the left side

No abnormal communication between the facial vein and the artery was observed.

DISCUSSION

AVM are reported to be rare in the region of the upper lip, philtrum and soft palate (Hassard and Byrne, 1985). AVMs are either congenital or acquired in origin. Congenital AVMs occur as a result of lack of differentiation of arteries, veins and the capillaries during vascular development (Hassard and Byrne, 1985). There is a persistent communication between them, resulting in short-circuiting of the blood (Ennis et al., 1972). The increase in blood flow through these shunts results in the production of bruit. Acquired AVMs occur as a result of penetrating, blunt or surgical injury (Holt et al., 1980). Physical examination reveals an increase in skin temperature, visible and palpable pulsations, palpable thrill and bruit (Low, 2003). An MRI/ MRA scan followed by an

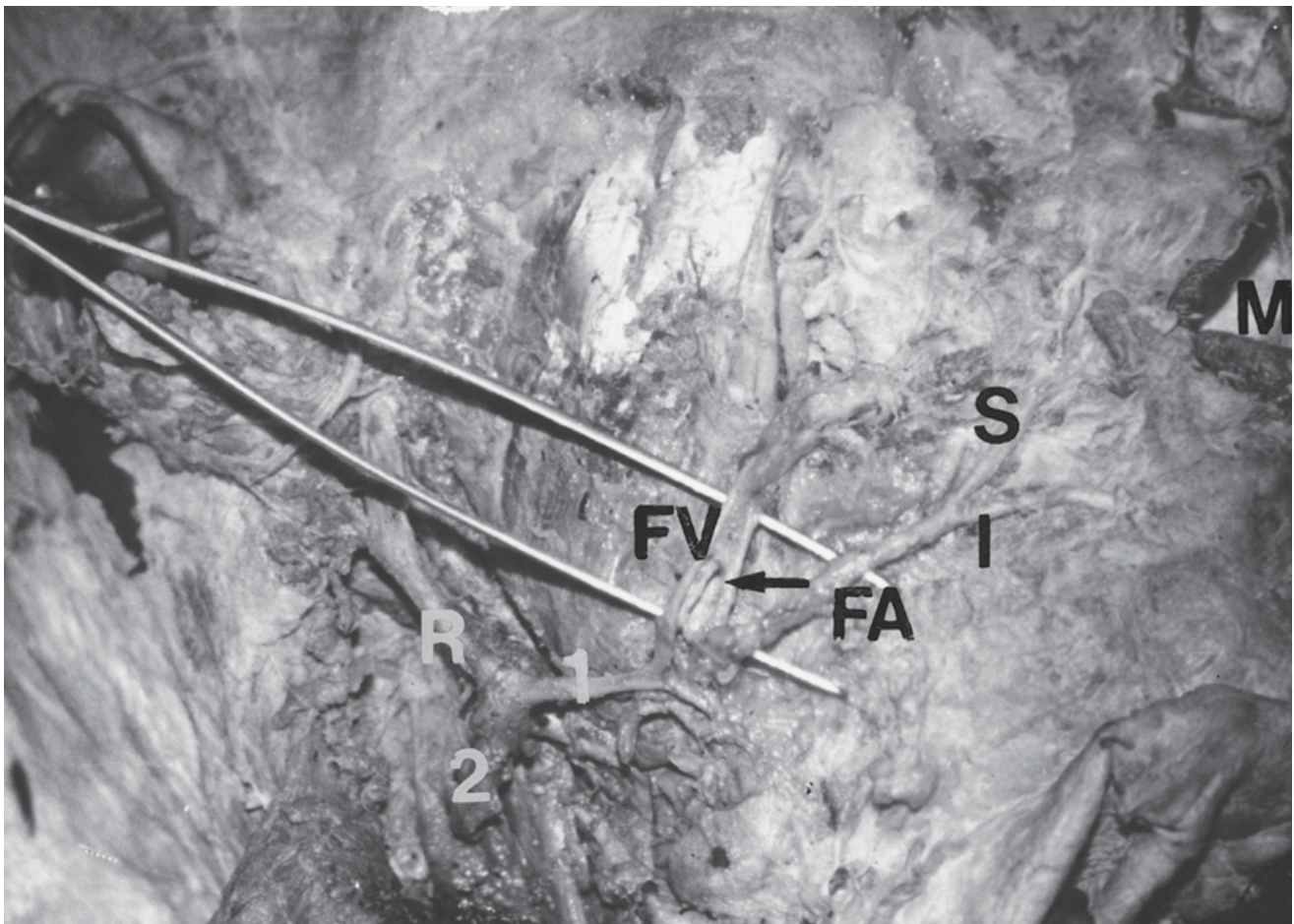


Fig. 1.- Photograph showing dissected region of the face (Right side).
 FV: Facial vein; FA: Facial artery; S: Superior labial Artery; I: Inferior labial Artery; M: Mouth; R: Retromandibular vein. Arrow (↔): Communication between facial artery and facial vein. 1 and 2: Anterior and posterior divisions of retromandibular vein, respectively.

arteriogram is the protocol of choice (Low, 2003). Treatment of these AVM is complete surgical excision following embolization therapy (Hassard and Byrne, 1985). The surgical approach involves the risk of uncontrolled bleeding and also injury to the branch of the facial nerve (Low, 2003).

In the present study we noticed the communication between the facial artery and the vein just before the facial artery divided into the inferior and superior labial arteries. Considering the movements of the cheek, it is likely that there would be stretching of these vessels. Such communication, observed unilaterally as in the present case, may result in the transmission of blood from the arterial to the venous side. Past research has defined the transmission of blood from the arterial to the venous side thus shunting the blood back towards the heart (Holt et al., 1980). There is also a reversal of blood flow in the venous segments (Holt et al., 1980). The absence of valves in the veins of the head and neck results in the dilatation process occurring more rapidly (Holt et al., 1980).

It is known that the venous side offers less peripheral resistance and any increase in arterial pulsation would be transmitted to the vein (Sabiston and Lyerly, 1997). The facial vein also has communication with the cavernous sinus and any involvement of the facial vein in such cases would produce more serious effects. The communication would also result in the mixing of venous and arterial blood.

Arterioles with a size > 50 microns provide major resistance to the blood flow, thereby increasing the metabolic demand. This means there would first be vasodilatation of small arterioles, followed by vasodilatation of the proximal larger arterioles (Hester and Hammer, 2002). The process of ascending vasodilatation is a conducted vasodilatation and flow-dependent response (Hester and Hammer, 2002).

Interestingly, an earlier study defined the role of the diffusion of vasoactive substances from the blood of venous origin to increase arteriolar

diameter, thereby causing vasodilatation of the adjacent arteriole (Hester and Hammer, 2002). These may be important in designing flaps during surgery of the submandibular gland and for reconstructive operations performed by maxillofacial surgeons.

As anatomists, we believe that any abnormal communication of the facial arteries and veins may be significant for vascular and maxillofacial surgeons in their clinical practice.

REFERENCES

- ENNIS JT, BATESON EM and MOULE NJ (1972). Uncommon arterio-venous fistulae. *Clin Radiol*, 23: 392-398.
- HASSARD AD and BYRNE BD (1985). Arteriovenous malformations and vascular anatomy of the upper lip and soft palate. *Laryngoscope*, 95: 829-832.
- HESTER RL and HAMMER LW (2002). Venular-arteriolar communication in the regulation of blood flow. *Am J Physiol Regul Integr Comp Physiol*, 282: 1280-1285.
- HOEY MF, COURAGE GR, NEWTON TH and HOYT WF (1970). Management of vascular malformations of the mandible and maxilla: review and report of two cases treated by embolization and surgical obliteration. *J Oral Surg*, 28: 696-706.
- HOLT JE, HOLT GR and THORNTON WR (1980). Traumatic arteriovenous malformation of the eyelid. *Ophthalmic Surgery*, 11: 771-777.
- KHODAD G (1973). Arteriovenous malformation of the scalp. *Ann Surg*, 177: 79-85.
- LOW DW (2003). Management of adult facial vascular anomalies. *Facial Plastic Surgery*, 19: 113-130.
- SABISTON Jr DC and LYERLY HK (1997). *Sabiston's Textbook of Surgery. The Biological Basis of Modern Surgical Practice*. WB Saunders Co, Philadelphia, pp 1731-1732.
- SCHULTZ RC and HERMOSILLO CX (1980). Congenital arteriovenous malformation of the face and scalp. *Plast Reconstr Surg*, 65: 496-501.
- STANDRING S (2005). *Gray's Anatomy. The Anatomical Basis of Clinical Practice*. Elsevier Churchill Livingstone, New York, pp 509, 552.
- WATSON WL and MCCARTHY WS (1940). Blood and lymph vessel tumors; a report of 1056 cases. *Surg Gynaecology and Obstetrics*, 71: 569.

