

# Variations in the number of human permanent teeth: hypodontia

E. Jiménez-Castellanos<sup>2</sup>, A. Carmona<sup>1</sup>, C.J. Catalina-Herrera<sup>1</sup>,  
E. Cordero<sup>2</sup> and J. Jiménez-Castellanos<sup>1</sup>

1- *Departamento de Anatomía y Embriología Humana*

2- *Departamento de Estomatología. Facultad de Medicina, Universidad de Sevilla, 41009 Sevilla, Spain*

## SUMMARY

The partial absence of teeth germs is a hereditary or acquired congenital defect called hypodontia. The present report analyses and discusses hypodontia in permanent dentition on the basis of eleven clinical cases. In these, the hypodontia corresponded to mandibular central incisors, maxillary lateral incisors, maxillary canines, or maxillary and mandibular premolars and molars. All these cases of hypodontia were recorded by photographs of the oral cavity and/or by orthopantomographic studies. Together with the most-frequent types of hypodontia already reported in the literature, other unusual anomalies—the lack of permanent canines, central incisors, or molars - from both the maxillary and mandibular alveolar arches- were also detected.

**Key words:** Hypodontia – Permanent dentition – Teeth – Oral cavity – Human

## INTRODUCTION

The partial absence of dental germs is a congenital defect of hereditary or acquired origins (Tucker et al., 1999; Thesleff, 2000). When all teeth germs are not present the defect is called anodontia –(a very rare anomaly); the absence of more than half of the teeth germs is referred to as oligodontia; and hypodontia is the lack of one or more teeth germs in a number lower than that corresponding to oligodontia (Maklin et al., 1979).

The most-precocious histological signs of dental development are the condensation of mesenchymal tissue and capillary vessels in the depth of the presumptive dental epithelium of the primitive oral cavity (Berkovitz et al., 1995).

The dental lamina (6<sup>th</sup> week), and later the enamel organs, represent the epithelial portion of the oral cavity with potential capacity to generate the ectodermal components of the teeth. In subsequent development, the adjacent mesenchymal tissue proliferates and condenses to form other components and portions of the future teeth (Mjör and Fejerskov, 1989). The permanent-teeth germs are developed later. They originate from the accessory dental lamina, in the case of molars (which have no precursors in temporal dentition), or from growth of the free edge of the dental lamina on its lingual side for the remaining permanent teeth. The emergence or eruption of permanent dentition takes place over an extended period ranging from 7 to 12 years, apart from the third molars, which erupt between 13 and 25 years, although sometimes they fail to appear at all (Moore and Persaud, 2004).

Most dental anomalies are more frequent in permanent than in deciduous dentition. With regard to permanent dentition, the lack of one or more teeth is evident in about 1-2 % of the population (Woelfel and Scheid, 1998). In the present article, one case of complete anodontia and different types of hypodontia related to several components of the permanent dentition are described and discussed in the light of data previously reported in the literature.

Correspondence to:

Prof. J. Jiménez-Castellanos. Departamento de Anatomía y Embriología Humana, Facultad de Medicina, 41009 Sevilla, Spain. Phone: +34 95-4552865; Fax: +34 95-4381662.

E-mail: jjcb@us.es

Submitted: September 28, 2004  
Accepted: February 8, 2005

## MATERIAL AND METHODS

To analyze the lack of permanent teeth, we used eleven clinical cases. The ages of our cases ranged from 12 to 39 years. Three corresponded to males, and the remaining 8 cases were females.

All patients were subjected to an oral examination, and an orthopantomographic study was performed in each case.

## RESULTS

Our results are summarized in Table 1.

Case 1 showed total anodontia associated with an ectodermal dysplastic syndrome. The remaining ten cases corresponded to different types of hypodontia.

In cases 2 and 3, the remaining teeth showed a mesial deviation and diastemas between the teeth to compensate for the dental arch defect.

Our cases 4, 5, and 6 were sisters of a five-child family. All three cases presented the lack of both maxillary lateral incisors, with a clear dominant hereditary component.

In case 7, the upper right lateral incisor, though present, showed an anomalous conoid form.

Case 8, together with the anomalies recorded in Table 1, showed the presence of retained mandibular second premolars.

## DISCUSSION

In recent years many studies have established the genetic basis of hypodontia, including identification of the genes involved in dental development and the association of the mutation of certain genes with different types of dental agenesis (Maas and Bei, 1997; Tucker et al., 1999; Thesleff, 2000; Nieminen et al., 2001; Thesleff and Mikkola, 2002).

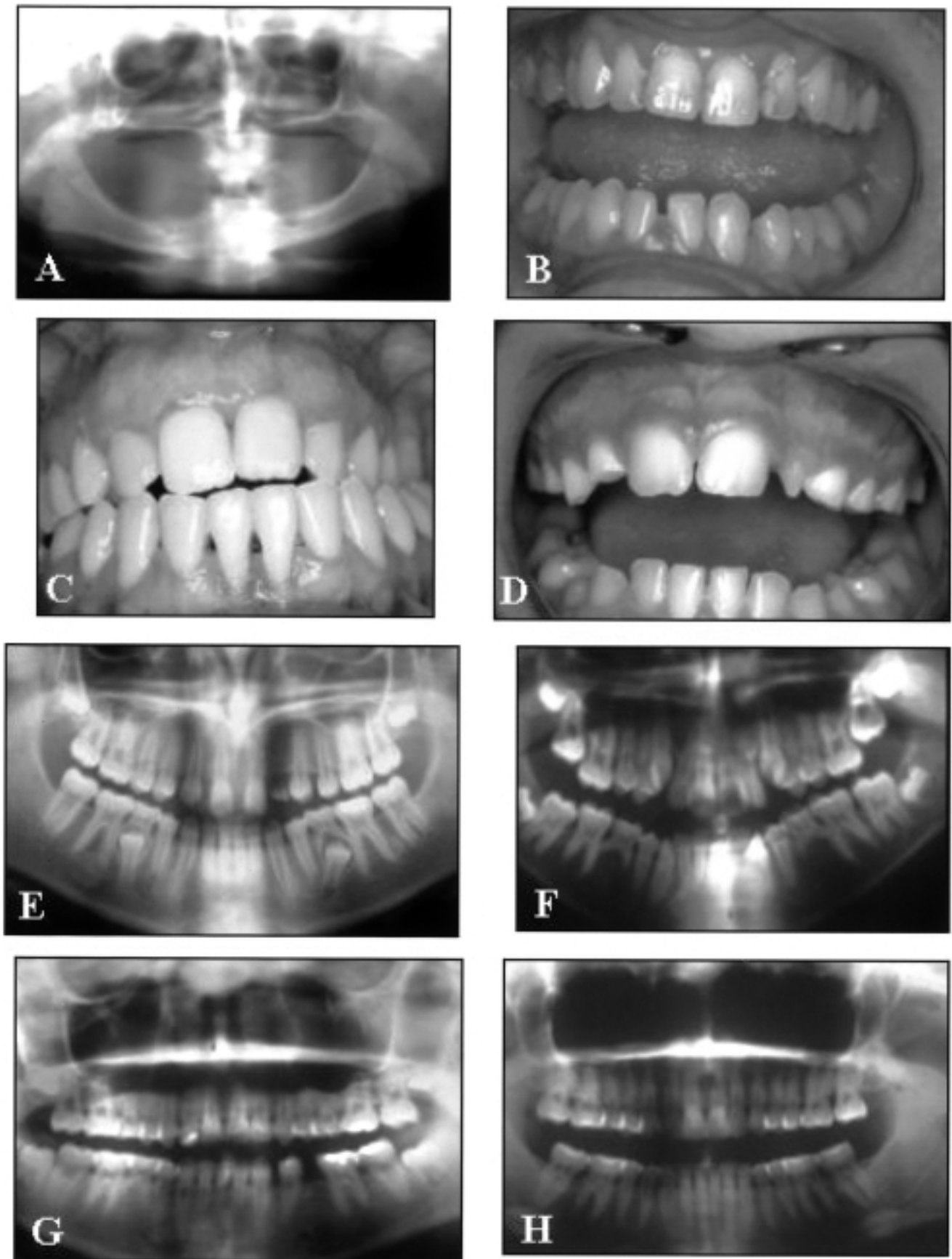
Hypodontia in deciduous dentition is less frequent than in permanent teeth, and is almost always confined to the central incisors and upper lateral incisors (Jarvinen and Lehtinen, 1981; Daugaard-Jensen et al., 1997).

Total or complete anodontia is a very rare anomaly, usually linked to a hereditary disease and additionally characterized by a failure of ectodermal development affecting other structures such as the hair, nails, and sebaceous and sudoriparous glands (Woelfel and Scheid, 1998). Here we report one such singular cases (case 1) of anodontia integrated within a hereditary ectodermal polydysplastic syndrome, and at the same time characterized by anhidrosis and hypotrichosis. This syndrome predominantly affects males, and is transmitted as a recessive genetic trait linked to sex.

Epidemiological studies carried out in different countries have revealed a prevalence of hypodontia in permanent dentition involving from 4

	Mandibular Central Incisor	Upper Lateral Incisor	Upper Canine	Mandibular Second Premolar	Upper Second Premolar	Third Molar	All Teeth
<b>CASE 1 (male, 14)</b>							All
<b>CASE 2 (fem, 35)</b>	Both						
<b>CASE 3 (male, 37)</b>	Both						
<b>CASE 4 (fem, 21)</b>		Both					
<b>CASE 5 (fem, 20)</b>		Both					
<b>CASE 6 (fem, 17)</b>		Both					
<b>CASE 7 (male, 12)</b>		Left					
<b>CASE 8 (fem, 15)</b>		Both	Right			Mandib (both)	
<b>CASE 9 (fem, 16)</b>				Both			
<b>CASE 10 (fem, 16)</b>				Both	Both		
<b>CASE 11 (fem, 39)</b>						All	

**Table 1.-** Summary of cases with the types of hypodontia found.



**Fig. 1.-** **A)** Orthopantomographic study in case one showing a total anodontia. **B)** Photograph of case three, showing the absence of both mandibular central incisors. **C)** Photograph of case six, presenting a dominant hereditary lack of both upper lateral incisors. **D)** Photograph of case seven, showing the absence of the left upper lateral incisor, and the conoid form of its homologous tooth on the right upper arch. **E)** Orthopantomographic study performed in case eight, showing the lack of the upper right canine, both mandibular molars, and both upper lateral incisors, together with retained mandibular second premolars. **F-G)** Orthopantomographic studies of cases nine and ten, showing the absence of both mandibular second premolars, and of all four mentioned teeth, respectively. **H)** Orthopantomographic study of case eleven, showing the lack of all third molars.

to 8.6% of the population (Magnusson, 1977; Maklin et al., 1979; Rolling, 1980; O'Dowling, 1989; Al-Emran, 1990; Symons et al., 1993; Aasheim and Ogaard, 1993; Backman and Whalim, 2001). However, in certain isolated communities, such as in Tasmania, hypodontia is exceptional, while –in contrast– in some groups of Mexican Indians almost 100% of the population is affected (Rozkovkova et al., 1999). Although that study considered only the agenesis of the third molar, it does suggest a possible association of hypodontia with ethnic or geographic factors.

According to the literature, the third molars are the permanent teeth most frequently absent (Woelfel and Scheid, 1998), as occurred in our case 11 (lack of all four teeth) and in case 8 (absence of mandibular third molars), but the reports present considerable variations, depending on the population studied (Levesque et al., 1981; Lynham, 1990). In any case, the lack of the third molar is a consequence of human evolution given the fact that the maxillary and mandibular bones suffer involutive changes rendering this tooth the least necessary for masticatory function.

Leaving aside these studies, the lack of one or both upper lateral incisors (1-2% of the population), mandibular second premolar (1%), and upper second premolar, in this order, and with a uni- or bilateral character, are the most-common deficiencies reported (Davis, 1987; Stritzel et al., 1990; Manrique et al., 1991; Woelfel and Scheid, 1998). Our findings are in good accord with these data because we have found a lack of the upper lateral incisors (cases 4, 5, 6, 7 and 8), the mandibular second premolars (cases 9 and 10), or the upper second premolars (case 10). However, some authors (Fuller and Denehy, 1984) have reported that the lack of maxillary and mandibular premolars is more frequent than that of the upper lateral incisors.

Canines, the teeth most stable in permanent dentition, are the dental elements least likely to be absent in permanent dentition (Fuller and Denehy, 1984). Here we report –in our case 8– the very unusual lack of the right upper canine. This tooth, although with some frequency may be retained, in contrast is very rarely not found. The lack of this tooth has important consequences for dental occlusion, since the canines have an essential protective role; their periodontal nerve receptors inform the CNS and masticatory centres in order to prevent mandibular closing beyond maximal intercuspitation.

Hypodontia produces functional and aesthetic defects which may be of more or less importance, depending on the number and type of teeth affected. These dysfunctional consequences are not usually considered in articles dealing with hypodontia. In our cases 2 to 7, there were evident aesthetic alterations, with lesser func-

tional engagement in case 7 because the preservation of the deciduous dentition acted to maintain space, preventing the displacement of the posterior dental region and the consequent malocclusion. This situation also occurred in our case 9, where, although posterior teeth were absent, the presence of the deciduous dentition diminished, at least transiently, the functional problem of malposition. This situation is opposite to that of case 10, where there was a lack of the temporal right second molar.

Apart from the lack of a canine in our case 8, previously commented on, case 1 showed very important defects in aesthetics and oral function, with additional sequelae in the psychological field.

## REFERENCES

- AASHEIM B AND OGAARD B (1993). Hypodontia in 9-year old Norwegians related to need of orthodontic treatment. *Scand J Dent Res*, 101: 257-260.
- AL-ENRAM S (1990). Prevalence of hypodontia and developmental malformation of permanent teeth in Saudi Arabian school children. *Br J Orthod*, 17: 115-118.
- BACKMAN B and WAHLIM YB (2001). Variations in number and morphology of permanent teeth in 7 year old Swedish children. *Int J Pediatr Dent*, 11: 11-17.
- BERKOVITZ BKB, HOLLAND GR AND MOXHAM BJ (1995). Atlas en color y texto de anatomía oral, histología y embriología, 2nd edition. Mosby/Doyma, Madrid, pp 248.
- DAUGAARD-JENSEN J, NODAL M and KJAER I (1997). Pattern of agenesis in the primary dentition: a radiographic study of 193 cases. *Int J Pediatr Dent*, 7: 3-7.
- DAVIS PJ (1987). Hypodontia and hyperdontia of permanent teeth in Hong Kong schoolchildren. *Community Dent Oral Epidemiol*, 15: 218-220.
- FULLER JL AND DENEHY GE (1984). Concise dental anatomy and morphology. Year Book Publishers, Chicago, pp 264-265.
- JARVINEN S and LEHTINEN L (1981). Supernumerary and congenitally missing primary teeth in Finnish children. An epidemiologic study. *Acta Odontol Scand*, 39: 83-86.
- LEVESQUE GY, DEMIRIJAM A and TANGUAY R (1981). Sexual dimorphism in the development, emergence and agenesis of the mandibular third molar. *J Dent Res*, 60: 1735-1741.
- LYNHAM A (1990). Panoramic radiographic survey of hypodontia in Australian Defence Force recruits. *Aust Dent J*, 35: 19-22.
- MAAS R AND BEI M (1997). The genetic control of early tooth development. *Crit Rev Oral Biol Med*, 8: 4-39.
- MAGNUSSON TE (1977). Prevalence of hypodontia and malformations of permanent teeth in Iceland. *Community Dent Oral Epidemiol*, 5: 173-178.
- MAKLIN M, DUMMET CO and WEINBERG R (1979). A study of oligodontia in a sample of New Orleans children. *ASDC J Dent Child*, 46: 478-482.
- MANRIQUE MC, OSTOS MJ AND GONZÁLEZ E (1991). Prevalence of dental agenesis in an Andalusian population. *Rev Eur Odontostomatol*, 3: 49-56.
- MIÖR IA and FEJERSKOV O (1989). Embriología e histología oral humana. Salvat, Barcelona.

- Moore KL and PERSAUD TVN (2004). *Embriología clínica*, 7th edition. Elsevier, Madrid.
- NIEMINEN P, ARTE S, TANNER D, PAULIN L, ALALUUSUA S, THESLEFF I and PIRINEN S (2001). Identification of a nonsense mutation in the PAX9 gene in molar oligodontia. *Eur J Hum Genet*, 9: 743-746.
- O'DOWLING IB (1989). Hypo-hyperdontia in an Irish population. *J Ir Dent Assoc*, 35: 114-117.
- ROLLING S (1980). Hypodontia of permanent teeth in Danish schoolchildren. *Scand J Dent Res*, 88: 365-369.
- ROZKOVCOVA E, MARKOVA M and DOLESI J (1999). Studies on agenesis of third molars among populations of different origin. *Sb Lek*, 100: 71-84.
- STRITZEL F, SYMONS AL and GAGE JP (1990). Agenesis of the second premolar in males and females: distribution, number and sites affected. *J Clin Pediatr Dent*, 15: 39-41.
- SYMONS AL, STRITZEL F AND STAMATION J (1993). Anomalies associated with hypodontia of the permanent lateral incisor and second premolar. *J Clin Pediatr Dent*, 17: 109-111.
- THESLEFF I (2000). Genetic basis of tooth development and dental defects. *Acta Odontol Scand*, 58: 191-194.
- THESLEFF I AND MIKKOLA M (2002). The role of growth factors in tooth development. *Int Rev Cytol*, 217: 93-135.
- TUCKER AS AND SHARPE PT (1999). Molecular genetics of tooth morphogenesis and patterning: the right shape in the right place. *J Dent Res*, 78: 826-834.
- WOELFEL JB and SCHEID RC (1998). *Anatomía dental. Aplicaciones clínicas*. Masson, Barcelona, pp 387-391.

