

A case of coexistence of three anatomical variations in the forearm: Gantzer's muscles, Martin-Gruber anastomosis, and nerve of Henle

K. Narayana¹, K. Narendiran², K. Prakash Shetty¹ and N. Prashanthi¹

1- Department of Anatomy, Center for Basic Sciences, Kasturba Medical College, Bejai, Mangalore, 575004, Karnataka, India

2- Faculty of Medicine, Asian Institute of Medicine, Science & Technology, Amanjaya, 08000 Sungai Petani, Kedah Darul Aman, Malaysia

SUMMARY

During routine dissection of a left forearm, a simultaneous occurrence of Gantzers' muscles, Martin-Gruber anastomosis and nerve of Henle was observed in a 72 year old male. Both accessory muscle heads (Gantzers' muscles) originated from the medial epicondyle and coursed distally. The lateral accessory head crossed the ulnar artery, the Martin-Gruber anastomosis, and the branches of the median nerve to the flexors, the interosseous neurovascular bundle and the median nerve itself. The medial accessory head (Flexor Digitorum Profundus Accessorius) crossed the above structures except the last two. The Martin-Gruber anastomosis was a connection between the nerve to the Flexor Digitorum Profundus (a branch of the median nerve) and the ulnar nerve, which traversed posterior to the ulnar artery and two accessory muscle heads. The nerve of Henle originated from the ulnar nerve just proximal to joining the Martin-Gruber anastomosis, coursed distally with the ulnar artery, and supplied the skin of the distal forearm. These muscular and nervous anomalies are clinically significant since they are mutually related to one another and could compress the nerves or may be compromised during surgical procedures.

Key words: Human – Martin-Gruber anastomosis – Nerve of Henle – Gantzer's muscles – Forearm

INTRODUCTION

The variations seen in the flexor compartment of the forearm are muscular, nervous and arterial, and they form the etiological factors of many neurological conditions. These syndromes are manifested when the median, the ulnar, and anterior interosseous nerves are compressed by the Pronator teres, Flexor Carpi Ulnaris or Gantzers' muscle (Al-Qattan, 1996; Tabib et al, 2001). The accessory muscle heads called Gantzers' muscles (Malhotra et al., 1982; Oh et al., 2000), occasionally produce clinical conditions such as anterior interosseous nerve syndrome. These muscle heads are accessory to the deep forearm flexor muscles flexor pollicis longus and flexor digitorum profundus (Jones et al, 1997). These conditions may aggravate when the additional nerves are present in this compartment. The Martin-Gruber anastomosis is a connection between the median and ulnar nerves, established by the branch/branches of the former directly or via its branches. Depending on the nature of the origin of the anastomotic branch, there are 3 to 5 types (Nakashima, 1993; Shu et al., 1999), but all serve functionally as a route of fiber transfer to the ulnar nerve. These connections are clinically important since even in complete lesion of the median nerve some muscles may not be paralyzed, leading to the erroneous conclusion of the median nerve being intact (Al-Qattan, 1996; Duteille et al., 2000).

Another variable structure is known as the nerve of Henle, which is a branch of the ulnar nerve that accompanies the ulnar artery and is

thought to deliver the sympathetic fibers to the latter and to innervate the skin of the distal ulnar forearm (McCabe and Kleinert, 1990). There are several reports on the incidence of all these variants, especially of Gantzers' muscles and their clinical significance. The incidence of Gantzers' muscle is 50-66%, and in all cases it is known to pass posterior to the median and anterior interosseous nerves (Al-Qattan, 1996; Oh et al., 2000). The Martin-Gruber anastomosis has been found in 23% (Rodriguez-Niedenfuhr et al., 2002) to 75% (Hasegawa et al., 2001) of cases and the nerve of Henle in around 45% of subjects (McCabe and Kleinert, 1990).

Thus, it is clear that all these variable structures have very high incidences on an individual basis. However, to our knowledge there are no reports addressing their mutual relationships.

MATERIALS AND METHODS

This variation was observed in a left forearm during routine dissection of a male cadaver aged about 72 years. When these variable structures were observed, fine dissection was carried out and their anatomy was studied. The findings were recorded by photography.

RESULTS

Gantzer's muscles

There were two accessory heads to the deep flexor muscles (Fig. 1). The lateral accessory head originated from the medial epicondyle and

coursed obliquely downwards and lateral to the medial slip. It crossed the ulnar artery, the Martin-Gruber anastomosis, the branches of the median nerve to the Flexor Digitorum Profundus, the anterior interosseous neurovascular bundle, and the median nerve. The ulnar artery passed through a gap formed by the 2 accessory heads. All but the median nerve were posterior to the muscle. The muscle formed a slim tendon that crossed the anterior interosseous nerve and joined the Flexor Pollicis Longus just 5 cm distal to the insertion of the pronator teres. A branch from the nerve to the Flexor Digitorum Profundus supplied it.

The medial accessory head originated from the medial epicondyle, but posterior to the lateral accessory head. It traversed downwards obliquely, just distal to the lateral accessory head, and crossed the ulnar artery and Martin-Gruber anastomosis and formed a slender tendon, then joining the Flexor Digitorum Profundus. Its tendon passed distally just lateral to the nerve of Henle. It was supplied by a branch from the nerve to the Flexor Digitorum Profundus from the median nerve.

Martin-Gruber anastomosis

This anastomotic branch originated from the median nerve to the Flexor Digitorum Profundus and traversed obliquely downwards and medially, crossing posterior to the Gantzers' muscles and the ulnar artery, and joined the ulnar nerve. The median nerve gave rise to 2 branches – medial and lateral, which were lateral to the radial artery. The medial branch cross-

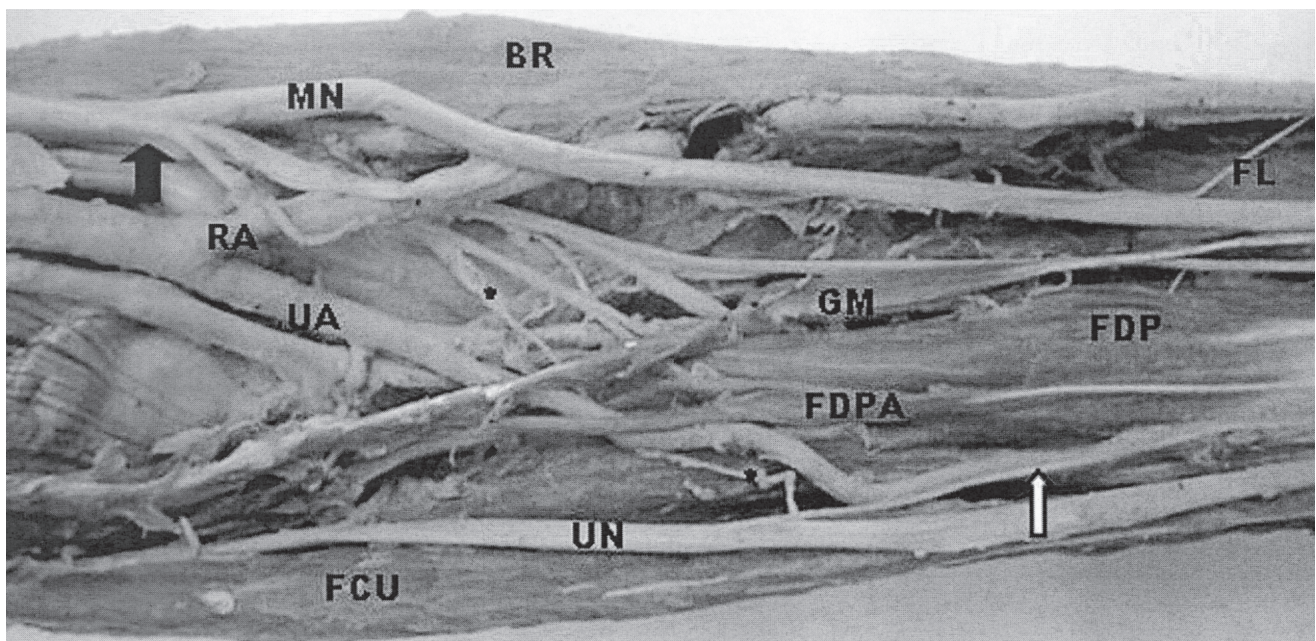


Fig. 1.- Photograph of the forearm showing Gantzer's muscles (GM and FDPA), Martin-Gruber anastomosis (*), and the nerve of Henle (open arrow). The Brachioradialis (BR), Flexor Carpi Ulnaris (FCU), Flexor Pollicis Longus (FL), Flexor Digitorum Profundus (FDP). Median nerve (MN), Ulnar nerve (UN), radial artery (RA), and ulnar artery (UA) are indicated. Note that the anterior interosseous nerve and other twigs from the median nerve to the superficial muscles lie lateral to the radial artery. An arrow indicates the site of origin of these nerves from the median nerve.

sed the radial artery superficially and then descended downwards to supply the superficial muscles. The lateral branch again divided into 3 branches. One branch passed superficial to the radial artery and supplied the superficial muscles, whereas another one supplied Gantzer's muscles, the Flexor Digitorum Profundus and also contributed to the Martin-Gruber anastomosis. The third branch supplied the Flexor Digitorum Profundus and continued as the anterior interosseous nerve in relation to the tendon of Gantzer's muscle.

Nerve of Henle

This originated from the ulnar nerve about 10 cm distal to the medial epicondyle, just proximal to the joining of Martin-Gruber anastomosis and accompanied the ulnar artery. It pierced the fascia and became cutaneous in the distal forearm.

DISCUSSION

Here we report the occurrence of three variable structures in the forearm. The muscle slips observed are accessory to the Flexors Pollicis longus and Digitorum Profundus, and are contained in Gantzer's muscles. There are numerous reports on their presence (Hammady et al., 1993; Al-Qattan, 1996) but the simultaneous occurrence of the other structures has not been reported in the literature consulted. These muscles arise from the medial epicondyle of the humerus (24%) or from the coronoid process of the ulna (68%), or from both (8%), and the incidence is wide, ranging from 39 to 90% (Mori, 1964). In the present case, one accessory muscle head inserted to the Flexor Pollicis Longus and the other one to the Flexor Digitorum Profundus. Both accessory heads crossed the ulnar artery and the Martin-Gruber anastomosis, but the lateral accessory head also crossed the nerve twigs from the median nerve to the Flexor Digitorum Profundus and the anterior interosseous nerve. The anterior interosseous nerve was first lateral to the lateral accessory head, but the tendon of the latter crossed the anterior interosseous nerve superficially, and this relationship between the accessory head and anterior interosseous nerve has been reported previously in the literature consulted (Oh et al., 2000). Hence, this relationship would lead to compression of the nerve, resulting in a clinical condition called anterior interosseous nerve syndrome (Tabib et al., 2001), although this is rare (Duteille et al., 2000). Another important relationship of Gantzer's muscles was that the tendon was posterior to the median nerve but anterior (ventral) to the anterior interosseous nerve. This is in contrast to the findings of Al-Qattan et al. (1996), who

reported that the muscle is always posterior to these two nerves.

The presence of 2 nerves further complicated the courses and relationships of other structures. The Martin-Gruber anastomosis observed in this case was similar to pattern I (anastomosis by a single nerve) and type b (anastomosis of a branch from the nerve to the Flexor Digitorum Profundus with the ulnar nerve) of the classification of Rodriguez-Niedenfuhr et al. (2002). The communicating branch followed a course in such a way that the ulnar artery lay between this nerve and the two accessory muscle heads. Since it crossed the anterior interosseous artery, the nerve could become compressed by these structures or vice versa. Since the Flexor Digitorum Profundus has a dual nerve supply, intramuscular nerve anastomosis also takes place. However, this was not observed by us.

The nerve of Henle contains both motor and sensory fibers (Valls-Sole, 1991; Erdem et al., 2002) and sympathetic fibers, and this nerve has been defined in 58% of cadavers (Balogh et al., 1999). This case resembled the type I classification, in which it originated more than 16 cm proximal to the ulnar styloid process (McCabe and Kleinert, 1990). The nerve followed the ulnar artery very closely and coursed just medial to the tendon of the medial accessory head. The tendons of these 2 accessory muscle heads were very thin, resembling the nerves nearby. Accordingly, they could be mistaken for the same. In conclusion, Gantzer's muscles, the Martin-Gruber anastomosis and the nerve of Henle, and their relations in the forearm are of paramount importance since they could be involved in many clinical conditions and surgical complications.

REFERENCES

- AL-QATTAN MM (1996). Gantzer's muscle. An anatomical study of the accessory head of the flexor pollicis longus muscle. *J Hand Surg*, 21: 269-270.
- BALOGH B, VALENCAK J, VESELY M, PARTSCH H and PIZA-KATZER H (1999). The nerve of Henle: an anatomic and immunohistochemical study. *J Hand Surg*, 24: 1103-1108.
- DUTEILLE F, AMARA B, DAUTEL G and MERLE M (2000). Isolated palsy of the flexor pollicis longus in anterior interosseous nerve syndrome. *Rev Chir OrthopReparatrice Appar Mot*, 86: 306-309.
- ERDEM HR, ERGUN S, ERTURK C and OZEL S (2002). Electrophysiological evaluation of the incidence of Martin-Gruber anastomosis in healthy subjects. *Yonsei Med J*, 43: 291-295.
- HASEGAWA O, MATSUMOTO S and IINO M (2001). Prevalence of Martin-Gruber anastomosis on motor nerve conduction studies. *No To Shinkei*, 53: 161-164.
- HAMMADY MV, SUBRAMANYA AV and MEHTA IM (1993). Occasional head of flexor pollicis longus muscle: a study of its morphology and clinical significance. *J Postgrad Med*, 39: 14-16.

- JONES M, ABRAHAMS P, SANUDO JR and CAMPILLO M (1997). Incidence and morphology of accessory head of flexor pollicis longus and flexor digitorum profundus (Gantzer's muscles). *J Anat*, 191: 451-455.
- MALHOTRA VK, SINGH NP and TEWARI SP (1982). The accessory head of the flexor pollicis muscle and its nerve supply. *Anat Anz*, 151: 503-505.
- MCCABE SJ and KLEINERT JM (1990). The nerve of Henle. *J Hand Surg*, 15: 784-788.
- MORI M (1964). Statistics on the musculature of the Japanese. *Okajimas Fol Anat Jap*, 40: 195-300.
- NAKASHIMA T (1993). An anatomic study on the Martin-Gruber anastomosis. *Surg Radiol Anat*, 15: 193-195.
- OH CS, CHUNG IH and KOH KS (2000). Anatomical study of the accessory head of the flexor pollicis longus and the anterior interosseous nerve in Asians. *Clin Anat*, 13: 434-438.
- RODRÍGUEZ-NIEDENFUHR M, VÁZQUEZ T, PARKIN I, LOGAN B and SANUDO JR (2002). Martin-Gruber anastomosis revisited. *Clin Anat*, 15: 129-134.
- SHU H, CHANTELOT C, OBERLIN C, ALNOT JY and SHAO H (1999). Anatomic study and review of the literature on the Martin-Gruber anastomosis. *Morphologie*, 83 (260): 71-74.
- TABIB W, ABOUFARAH F and ASSELINEAU A (2001). Compression of the anterior interosseous nerve by Gantzer's muscle. *Chir Main*, 20: 241-246.
- VALLS-SOLE J (1991). Martin-Gruber anastomosis and unusual sensory innervation of the fingers: report of a case. *Muscle Nerve*, 14: 1099-1102.