

# Gluteus minimus muscle: insertion to hip joint capsule in South Indian fetuses

**S. Rabi and S. Vettivel**

*Department of Anatomy, Christian Medical College, Vellore, India*

## SUMMARY

The insertion of the gluteus minimus muscle to the superior aspect of the fibrous capsule of the hip joint, in addition to the anterolateral aspect of the greater trochanter has been reported in surgery, cadavers, and full term fetuses. The present study aimed to determine whether or not such an insertion was present in the South Indian fetuses. Seven young-to-full term fetuses were used. A firm attachment of the gluteus minimus muscle to the hip joint capsule was present in all the specimens. Sharp dissection was required to separate it from the capsule. Histological assessment of the junction of the muscle to capsule revealed that bundles of collagen linked the skeletal muscle to the capsule in all cases. Striated muscle fibres became densely collagenous at the site of attachment to the connective tissue of the capsule and the dense collagen fibres were arranged in a linear fashion. Functional role and clinical anatomy of the capsular attachment are presented.

**Key words:** Gluteus minimus – Impingement syndrome – Hip joint

## INTRODUCTION

Detached slips may connect the gluteus minimus muscle with the tensor fascia latae, superior gemellus, vastus lateralis, gluteus medius, piriformis, or the capsule of the hip joint (Macalis-

ter, 1875; Le Double, 1897; Bergman et al., 1988; Salmons, 1995; Walters et al., 2001). During surgery on the adults, an insertion of the gluteus minimus into the superior aspect of the fibrous capsule of the hip joint was noted, in addition to the classic anterolateral aspect of the greater trochanter (Hardinge, 1982; Walters et al., 2001). In the Black, Caucasian and mixed racial origin cadavers, a firm attachment of gluteus minimus to the hip joint capsule was present; this attachment was also present in Black term fetuses; histological assessment of the junction of muscle to capsule revealed intramuscular tendons firmly anchoring the muscle to the capsule in all cases, confirming its insertion into the capsule. A tendinous insertion to the capsule was also demonstrated in the term fetuses. Capsular attachment is a normal insertion and not a variation (Walters et al., 2001). The purpose of the present study was to determine whether or not such an insertion was present in the South Indian fetuses.

## MATERIALS AND METHODS

Seven young-to-full term fetuses from the South Indian state of Tamil Nadu were used. Skin and fasciae were removed and the gluteus maximus muscle was divided midway and reflected. The gluteus medius muscle was separated from the gluteus minimus muscle, divided midway and reflected. The gluteus minimus muscle was exposed. Its muscle belly was elevated from its origin from the gluteal surface of the coxal bone

Correspondence to:

Dr. Suganthy Rabi. Department of Anatomy, Christian Medical College, Vellore 632 002, India.  
Phone: 0091 0416 2262603 ext. 4245 / 2260545; Fax 0091 416 2262788  
E-mail: suganthyrabi@cmcvellore.ac.in

Submitted: April 25, 2003  
Accepted: October 10, 2003

by blunt dissection up to the level of the hip joint capsule, where the insertion of its deep muscle fibres into the superior aspect of the joint capsule was examined. Its tendinous insertion to the anterolateral ridge of the greater trochanter was then elevated, and the tendon was mobilized proximally up to the level of the joint capsule and its attachment to the capsule was examined. Tissues taken from the junction of the muscle and tendon with the capsule were examined histologically using Verhoeff's and Van Gieson's stains.

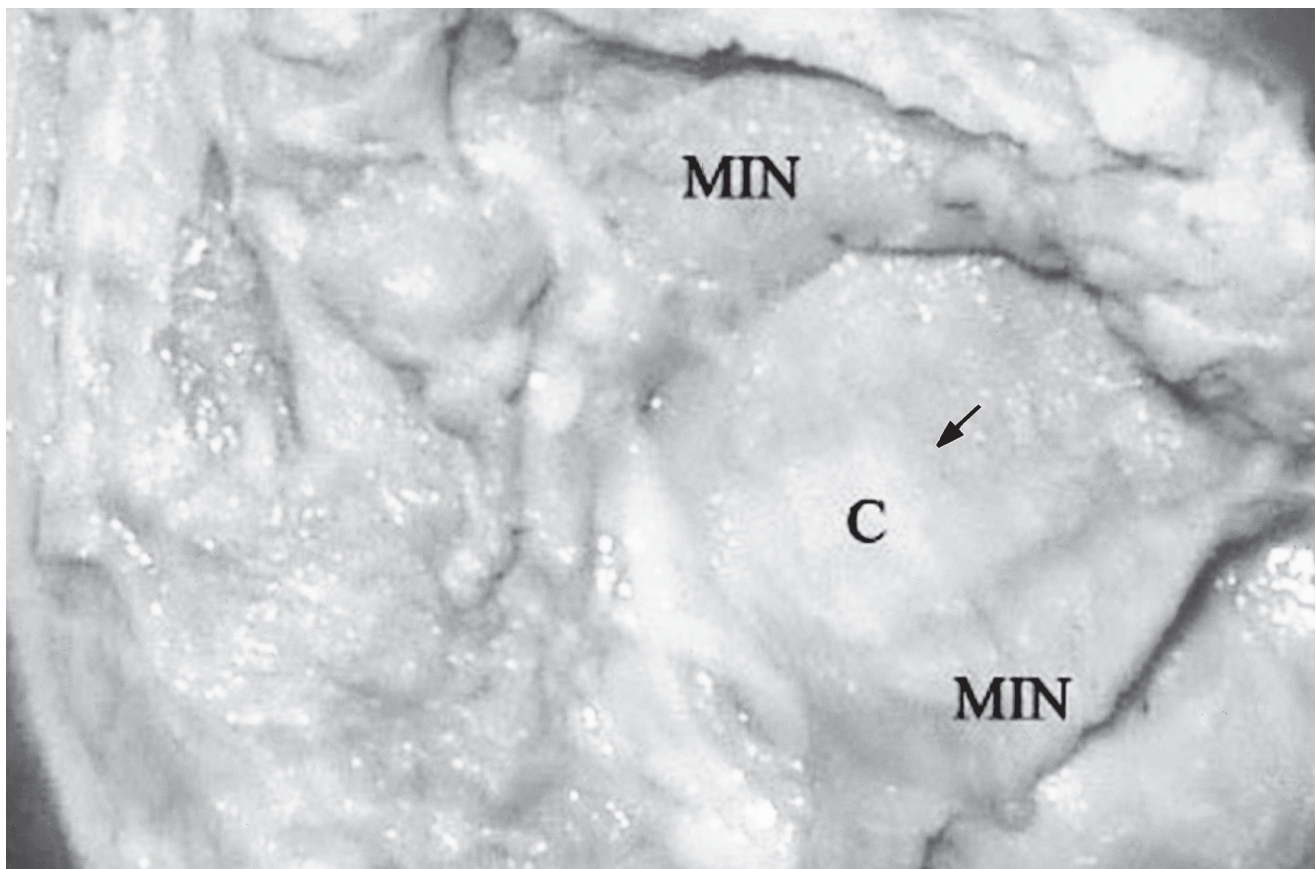
## RESULTS

The deep muscle fibres of the muscle belly of the gluteus minimus were firmly inserted into the superior aspect of the hip joint capsule (Fig. 1). The lower edge of the aponeurosis and the deep surface of the muscle at the tendon of insertion were firmly attached to the capsule. This attachment in the fetuses was not by any separate slip of the muscle. A firm attachment of the gluteus minimus muscle to the hip joint capsule was present in all the specimens dissected. Sharp dissection was required to separate it from the capsule. When the fetus was lifted by the gluteus minimus, the attachment was firm enough to suspend and


bear the fetus. Histological assessment of the junction of the muscle to the capsule revealed that bundles of collagen of the intramuscular tendons linked the skeletal muscle to the capsule in all cases (Fig. 2). Striated muscle fibres became densely collagenous at the site of attachment to the connective tissue of the capsule and the dense collagen fibres were arranged in a linear fashion.

## DISCUSSION

Attachment to the hip capsule was thought to be via detached slips connecting the gluteus minimus muscle with the capsule of the hip joint and an aberration (Bergman et al., 1988) and an expansion to the coxal capsule (Salmons, 1995). The attachment to the capsule may appear as an accessory muscle under cover of the main mass (Bergman et al., 1988). Our results clearly shown that the firm attachment of the main mass of the gluteus minimus, additionally to the hip joint capsule, is a normal insertion and not a racial variation, not a developmental change, not an age-related change, or not a postnatal hip joint function-related acquired change but a normal insertion. On the contrary, the absence of this insertion would be a variation (Walters et al., 2001).



**Fig. 1.-** Junction of gluteus minimus with hip joint capsule in a mid-term fetus. (Gluteus maximus and medius removed). MIN: gluteus minimus; C: hip joint capsule; Arrow: insertion of deep muscle fibres of gluteus minimus into the capsule.



**Fig. 2.-** Histology of junction of gluteus minimus with hip joint capsule in a mid-term fetus. M: skeletal muscle of gluteus minimus; T: linear collagen fibres of intermuscular tendons; C: connective tissue of capsule. Verhoeff and Van Gieson staining. x 88.

The linear arrangement of the dense collagenous bundles at the junction of gluteus minimus muscle to the capsule suggests a mechanical function. The tendinous insertion to the capsule, demonstrated histologically in all the younger and older fetuses, suggests that the insertion and collagen bundles are not a phenomenon acquired in later life (Walters et al., 2001).

The capsular attachment is responsible and necessary for retracting the capsule during hip joint activity to prevent entrapment of the capsule (Walters et al., 2001), as in the shoulder, elbow, and knee joints, during muscle dysfunction or dyssynchronous muscle activity such as muscle fatigue (Walters et al., 2001). Probably, the capsular attachment also helps in the supportive action of the gluteus minimus on the pelvis so that the components of the hip joint are in their usual relation when the contralateral foot is raised.

## REFERENCES

- BERGMAN RA, THOMPSON SA, AFIFI AK, SAADEH FA (1988). *Compendium of Human Anatomic Variation*. Urban & Schwarzenberg, Baltimore, pp 23.
- HARDINGE K (1982). The direct lateral approach to the hip. *J Bone Joint Surg*, 64B: 17-19.
- LE DOUBLE AF (1897). *Traite des variations du systeme musculaire de l'homme et de leur signification au point de l' anthropologie zoologique*. Vol. 2. Librairie C. Reinwald, Schleicher Freres, Paris, pp 226-227.
- MACALISTER A (1875). Additional observations on muscular anomalies in human anatomy (3<sup>rd</sup> series) with a catalogue of the principal muscular variations hitherto published. *Transactions of the Royal Irish Academy*, 25: 1-134.
- SALMONS S (1995). Muscles. In: Williams PL (ed). *Gray's Anatomy*. Churchill Livingstone, Edinburgh, pp 876-877.
- WALTERS J, SOLOMONS M and DAVIES J (2001). Gluteus minimus: observations on its insertion. *J Anat*, 198: 239-242.

