

Experimental autotransplantation of the trachea: Structural changes studied in the rabbit with a reference to human tracheal stenosis

C. Zagalo^{1,2}, N.R. Grande³, J. Martins dos Santos^{1,2},
E. Monteiro³ and A.P. Águas³

1- Health Sciences Institute, 2829-511 Monte de Caparica, Portugal

2- Department of Surgery, Portuguese Institute of Oncology, Lisbon, Portugal

3- Abel Salazar Institute for Biomedical Sciences, UMIB and IBMC, Porto University, Porto, Portugal

SUMMARY

Transplantation of the trachea is envisaged as the treatment of the future for severe cases of tracheal stenosis. In order to investigate the structural consequences of tracheal transplantation, we studied the adaptive changes of tracheal autografting in the rabbit. We found that autotransplantation of long portions of the trachea (involving 10 cartilage rings) was not viable in the rabbit, in contrast with the complete success observed after grafting of 4-ring segments of trachea. We report here on the morphological modifications of the trachea in these successful 4-ring autograftings of the organ. Marked epithelial alterations were seen in the early stage (one week) of the tracheal autografting, consisting of the loss of cilia and increase in the number of mucous cells. Two weeks after surgery, there was evidence of partial recovery by the epithelium. At three months after autografting, the epithelium was almost completely covered with cilia, the submucosa was poor in elastic fibers and cartilage foci were found outside the rings. Six months after surgery, the entire luminal surface of the rabbit trachea was covered with cilia; these samples showed discontinuities in the basement membrane and a paucity in elastic fibers. Major alterations were detected in the cartilage components of the autografted trachea, consisting in the fusion of adjacent rings and, at the suture lines, partial superimposition of rings. We conclude that the epithelium and the cartilage components of the trachea show distinct responses to autografting: changes in the epithelium are severe in the acute phase but are transitory and disappear in the long run, whereas

alterations of the cartilage are initially less conspicuous but slowly develop into the neoformation of cartilage tissue with fusion and superimposition of some tracheal rings, causing moderate tracheal stenosis.

Key Words: Tracheal stenosis – Autotransplant – Ciliated cell – Cartilage – Light microscopy

INTRODUCTION

Obstruction of the upper respiratory airways is a major cause of death and morbidity in head and neck injuries. Most patients require assisted ventilation with long-term tracheal intubation that may lead to tracheal stenosis, even when the intubation is performed correctly, i.e., with low pressure cuffs and de-inflation of the cuff at short and regular intervals. Tracheal stenosis is due to the formation of scar tissue resulting from repeated traumatic aggression of the trachea due to intubation. Furthermore, a significant number of patients undergoing tracheal intubation cannot be transferred immediately to medical centers sufficiently experienced in the maintenance of patients with assisted ventilation (Chabolle, 1983; Vlantis et al., 1998; Wax et al., 1998).

Surgical ablation of the stenosed portion of the trachea and end-to-end anastomosis remains the method of choice to treat serious tracheal stenosis (Grillo, 1969; Grillo et al., 1992; Bonnette et al., 1998; Cotter et al., 1999). This treatment, however, has important limitations; namely, in patients presenting long narrowed portions

of the trachea. In these cases, lowering of the larynx by sectioning the supra-hyoid muscles may not be enough to anastomose the tracheal ends without tension, a critical factor in the success of this type of surgery (Lacorreye et al., 1993; Panda and Mann, 1997; Cunningham et al., 1998; Cotter et al., 1999).

Recently, pioneering studies have indicated that tracheal autografting may have a role in future treatment of severe tracheal stenosis. It was shown that this technique could be successfully used to treat congenital tracheal stenosis (Backer et al., 1998). Elliott et al. (1996) reported the first clinical cases of tracheal reconstruction in children using cadaveric homograft trachea (Elliott et al., 1997). In 1998 Strome reported the first successful transplantation of the larynx in humans. These investigations have opened new avenues for organ transplantation in contaminated areas of the body, namely in the respiratory tract, since the presence of bacteria is commonly considered a bad prognostic factor in organ transplantation. Thus, transplantation of the trachea has been proposed as a potential option for the management of long-segment tracheal stenosis (Salmeron et al., 1998). Delaere et al. (1998) proposed a reliable reconstructive technique for extended hemilaryngectomy defects using tracheal autotransplantation. Clearly, even if just a short portion of trachea is suitable for transplantation, it would be possible to treat the vast majority of the patients with severe tracheal stenosis that cannot be resolved with currently available surgical techniques (Haider et al., 1998; Salmeron et al., 1998; Delaere et al., 1999).

Several experimental studies have been performed in animal models with the goal of studying the reconstruction of circumferential tracheal defects, namely by autografting the organ. Few of these publications deal with the morphological changes that accompany tracheal autografts, particularly the long term alterations that may be associated with the autotransplant (Inayama et al., 1995; Cheng et al., 1998). Furthermore, the two structural studies on tracheal autotransplantation only addressed alterations of the epithelium (Inayama et al., 1995; Cheng et al., 1998).

The present investigation derives from our own clinical experience with tracheal stenosis, and particularly from our finding that a significant number of our patients do not obtain good clinical results with currently available therapeutic options. We illustrate two of these clinical cases in our report.

Our goal in this study is to offer a comprehensive characterization of the morphological changes that occur in all the tissue layers of the trachea after autografting, ranging from early alterations to those seen up to six months after surgery has been performed.

MATERIALS AND METHODS

Case Reports: We illustrate two typical cases of human tracheal stenosis.

A.F. was a 24-year old man who suffered a motorcycle accident and was in a coma for 22 days. Twelve days after discontinuing assisted ventilation, the patient started complaining of dyspnea, which rapidly worsened and required tracheotomy. Endoscopic examination (Fig. 1, A) and CAT scan imaging (Fig. 1, B) revealed tracheal stenosis located where the cuff had been placed. The patient underwent tracheal surgery with excision of the stenotic segment and end-to-end anastomosis. The final result was considered to be clinically acceptable, although a moderate degree of stenosis remained visible in the post-operative endoscopic examination (Fig. 1, C).

C.A. was an eighteen-year old man who suffered a direct trauma to the neck with immediate dyspnea. A tracheotomy was performed and a stent was placed inside the tracheal lumen. After excision of the stent, the patient started to complain again of dyspnea. Tracheotomy was performed again. The CAT scan (Fig. 2, A) and the endoscopic evaluation revealed a 7-cm long stenotic segment of the trachea. The outcome of the surgical treatment of this case was poor: the patient could not be decanulated and remained with a permanent tracheotomy even after three surgical attempts to correct the tracheal stenosis. Microscopical examination of the surgical specimen revealed a marked fibrosis of the submucosal layer (Fig. 2, B).

Animals

We used 28 adult rabbits of mixed breed and of both sexes, weighing between 3 and 4 Kg, and with ages between 29 weeks and 2 years. The animals were kept in single cages, and cared for according to Portuguese law (DL 129/92 6th July and norm no. 1005/92), and the EC directive no. 86/609/CEE, which establishes the regulations for the protection of animals used in experimentation.

Experimental Surgery

The rabbits were anesthetized with sodium pentobarbital, 30 to 40 mg/Kg by intraperitoneal injection, and received 100,000 IU/Kg and 50,000 IU/Kg of penicillin G procaine and penicillin G potassium. A 5-cm longitudinal incision was performed along the median cervical line in the anesthetized animals. Exposure of the anterior surface of the trachea was obtained upon dissection of the ventral cervical muscles. The animals were divided into 3 groups, which were subjected to different surgical procedures.

Group 1.- Autografting of a short segment of trachea (4 cartilage rings) was performed in 15 animals. The trachea of the rabbits was sectioned

between the 4th and 5th tracheal rings and between the 8th and 9th. After surgical separation of this tracheal segment from the esophageic wall, it was immersed in warm saline containing G penicillin (200 IU/ml) (Daniel et al., 1950) and then anastomosed back in its original position with 5/0 silk suture, using transfixive stitches and avoiding superimposing of the tissue ends. Air leaks were carefully excluded and the surgical wound closed by layers.

Group 2.- In 3 animals we performed autografting of a long segment of trachea (10 cartilage rings). The same surgical technique described for the rabbits of group 1 was used to autograft a portion of the trachea made up of 10 tracheal rings. Because all of these animals died of tracheal occlusion within two weeks of autotransplantation, this type of experimental surgery was not pursued further.

Group 3.- Ten rabbits were sham-operated without removal of tracheal segments. The tracheal rings were surgically exposed and the wound was then closed.

Each of the above surgical procedures took, approximately 30 minutes "skin to skin".

Collection of Tracheal Autografts and Histology

The animals of Groups 1 (autografts of short tracheal segment) and 3 (sham-operated) were sacrificed by intraperitoneal injection of lethal doses of sodium pentobarbital on days 8, 15, 30, 90 and 180 after surgery (3 animals at each time in group 1 and 2 animals at each time in group 3).

All tracheas were removed, washed in phosphate buffer saline (PBS), and sectioned through the sagittal plane, obtaining two halves: left and right. Randomly, one of the halves was kept in buffered 10% formaldehyde and treated for observation by light microscopy after staining with Hematoxylin Eosine (HE), Periodic Acid Schiff (PAS) and Veroeff methods.

The animals of Group 2 (autografts of long tracheal segment) presented stridor 3 to 10 days after surgery, and all 3 rabbits died between the 4th and 12th day after surgery. The tracheas were removed at necropsy, washed in PBS, and fixed in 10% formaldehyde. Tracheal samples were embedded in paraffin and 5 μ m sections were obtained and stained for light microscopic examination.

RESULTS

Macroscopic Examination

Group 1 (autograft of 4-ring segment of trachea): One week after the tracheal autotransplantation, there were signs of congestion and edema of the grafted segment of trachea. No dehiscence of the surgical sutures was seen. Two weeks after surgery, the signs of congestion and edema

became less severe. Evidence of acute inflammation disappeared one month after autografting. Adventitial fibrosis involving the external surface of the trachea was observed. A few arteries were identified on the external surface of the transplanted segment of the trachea. A narrowing of the tracheal cross-section was seen in the central area of the graft where protrusion of the scar tissue occurred; this narrowing did not exceed 50% of the lumen of the trachea measured above and below the graft area (Fig 3, A). Animals sacrificed 6 months after the autotransplantation continued to display a similar narrowing of the tracheal cross-section that was visible on the external surface of the organ (Fig 3, B).

Group 2 (autografts of 10 rings of trachea): All the rabbits of this group presented stridor and died within the first two weeks of surgery. The grafts showed complete occlusion of the tracheal lumen (Fig 4).

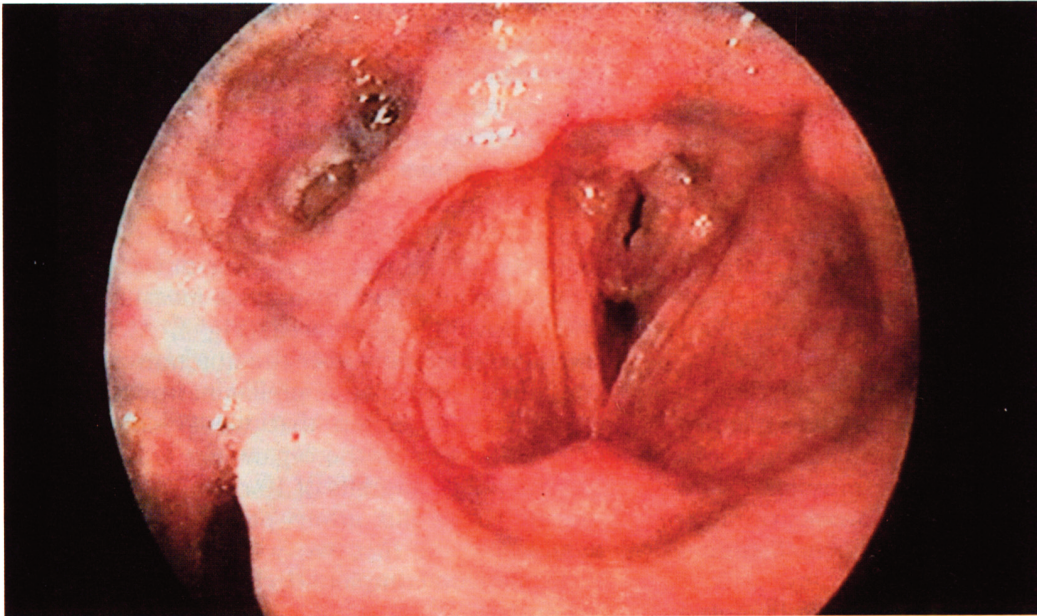
Group 3 (sham operation): There was no evidence of macroscopic abnormalities in any of the tracheas from the sham-operated animals.

Light Microscopy

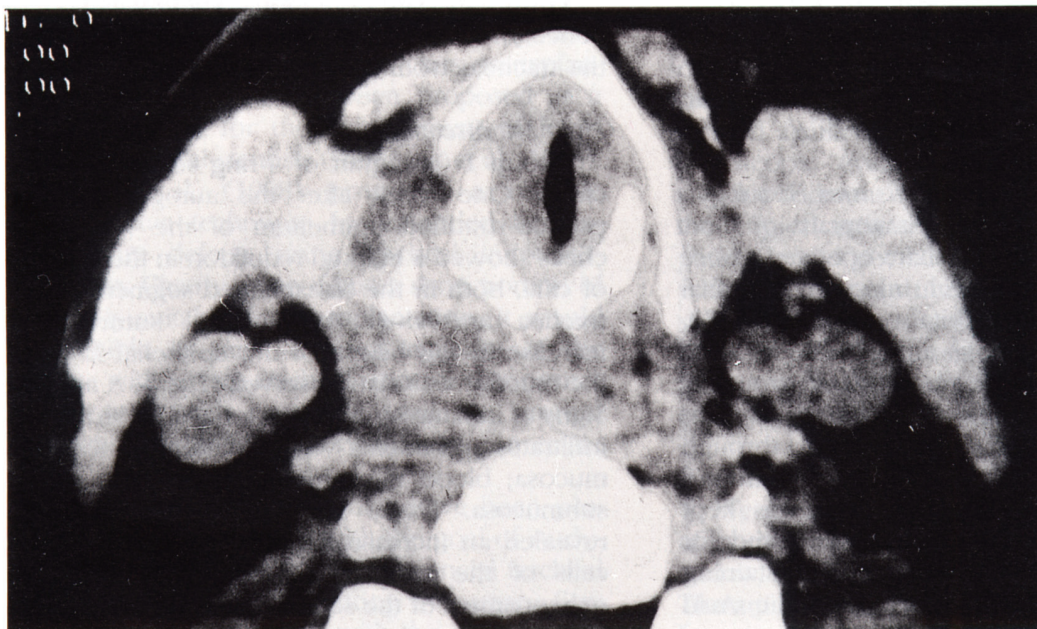
Group 1 (autograft of 4-ring segment of trachea): One week after the autografting, the pseudo-stratified epithelium of the rabbit tracheas showed a marked reduction in the number of cilia, both in the transplanted segment of the trachea and over the surgical sutures. An increase in the height of the epithelial layer of the mucosa was also observed (Fig. 5, A and B). Signs of inflammation characterized by leukocyte infiltrates and edema were identified in the submucosa; blood thrombi were also seen in the submucosa. Tissue sections stained with PAS revealed an increase in the number of mucous cells of the epithelium as well as a striking enhancement of the secretions on the epithelium surface when compared with samples from rabbits from control groups (Fig. 6, A and B). Veroeff staining of tracheal sections disclosed interruption of the elastic fibers of the submucosa at the areas of surgical incisions. The cartilage rings of the tracheal autografts showed enhanced cellularity (Fig. 7, A and B).

Two weeks after autotransplantation, the tracheal epithelium continued to show a reduction in cilia and an increase in mucous cell numbers. There was evidence of small neoformed vessels in the submucosa and signs of inflammation in the submucosa; the cartilage displayed necrotic areas near to the submucosa (Fig. 8). In central regions of the graft, there were foci of neoformed cartilage; signs of cartilage proliferation were also seen adjacent to both borders of the suture areas.

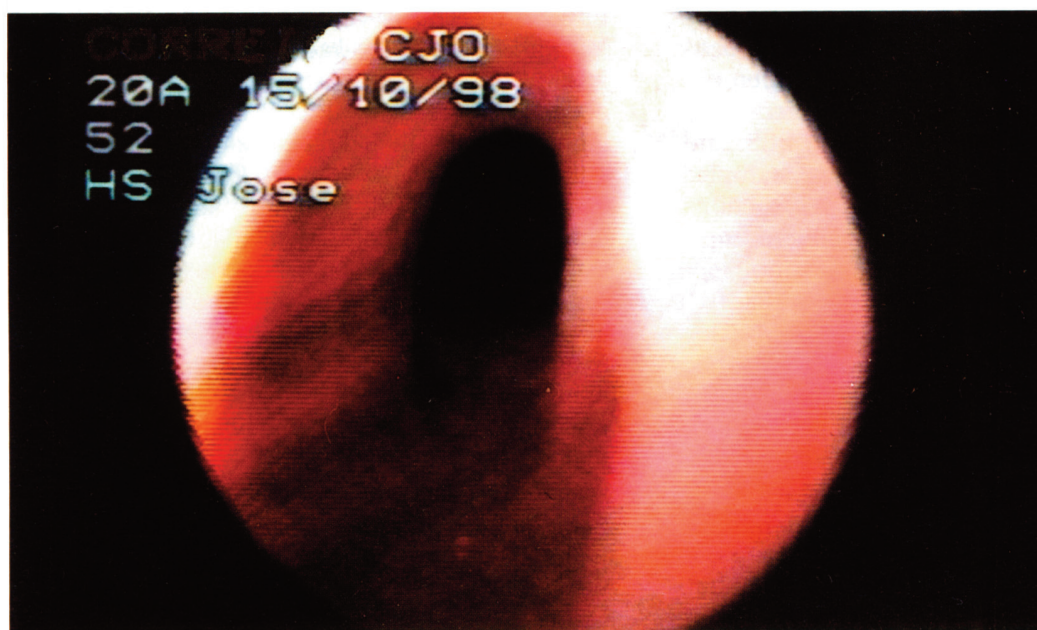
One month after tracheal autografting there were clear signs of recovery of the epithelium as expressed by the presence of cilia in many areas



1.- A



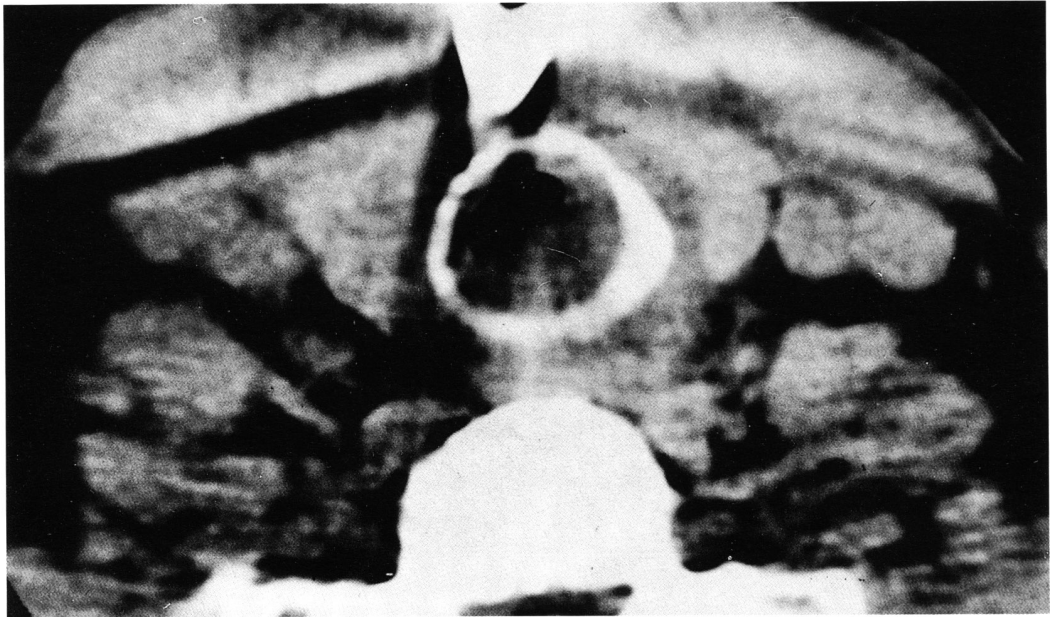
1.- B



1.- C

Fig. 1.- A: Endoscopic view of a Human tracheal stenosis. B: CAT of the same case of Human tracheal stenosis. C: Endoscopic post operative view of the same patient.

2.- A



2.- B



Fig. 2.- **A:** CAT image of a severe case of Human tracheal stenosis. **B:** Optical microscopy aspect of the surgical specimen of the above patient (H-E staining, x 400). The exuberant fibrosis of the submucosal layers is clearly visible.

of the epithelial surface (Fig. 9). There was evidence of chronic inflammation of the submucosa with lymphocytic infiltrates and neoformation of vessels. These inflammatory features were still present three months after the surgical procedure, although in moderate degrees.

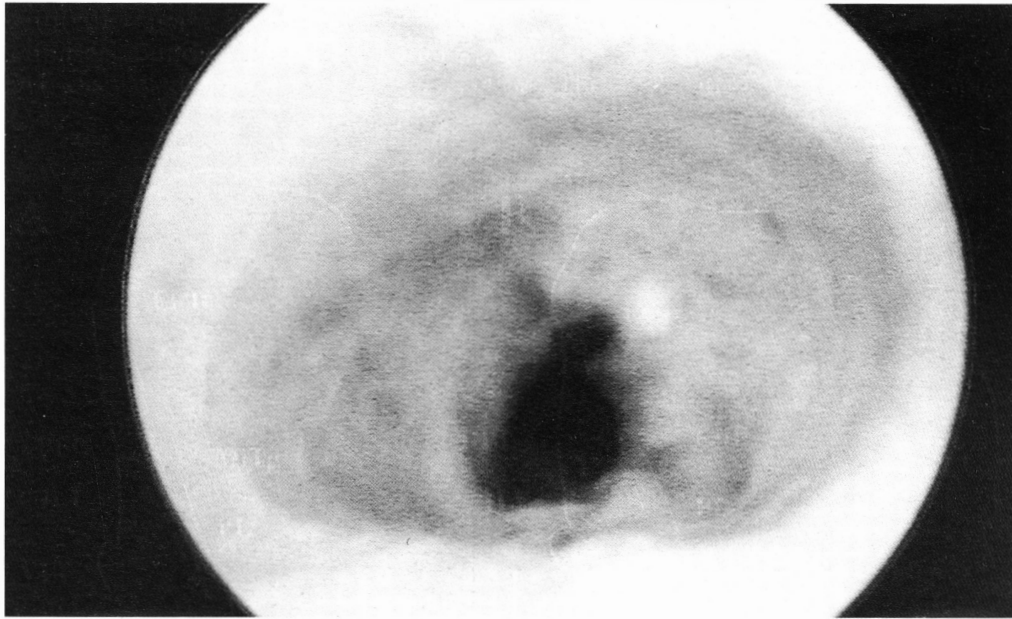
Three months after autografting, the mucosa was almost completely covered with ciliated pseudo-stratified epithelium. Elastic fibers were scarce in the submucosa (Fig. 10). There was remodeling of the cartilage rings with foci located independently from the individual rings and evidence of fusion between adjacent cartilage rings was also seen (Figs. 10 and 11).

Six months after tracheal autografting, the mucosa of the grafted segment had cilia over its

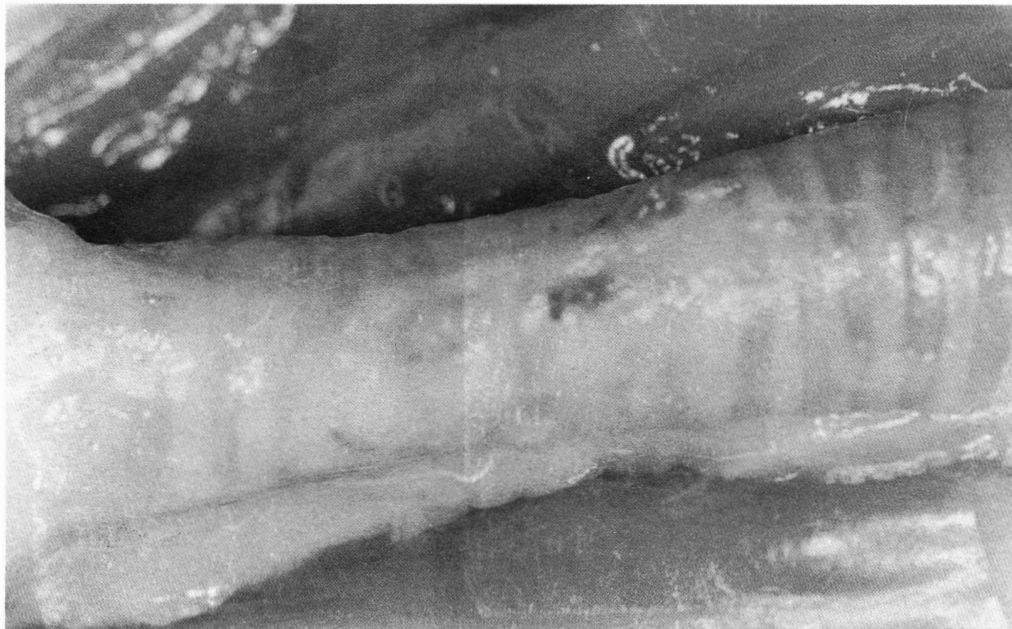entire surface and the mucosa over the suture lines was also covered with cilia. The basement membrane displayed discontinuous areas, with mucosal cells invading the submucosal layers (Fig. 12). The elastic fibers of the submucosa were scarce in the grafted area (Fig. 13). Partial superimposition of the tracheal rings was observed both within the transplanted segment and in the suture lines of the graft.

Group 2 (autografts of 10 rings of trachea): All the paraffin sections of trachea from rabbits subjected to transplantation of long segments of trachea showed necrosis of the graft.

Group 3 (sham operation): There was no evidence of microscopic abnormalities in any of the tracheas from the sham-operated animals.



3.- A



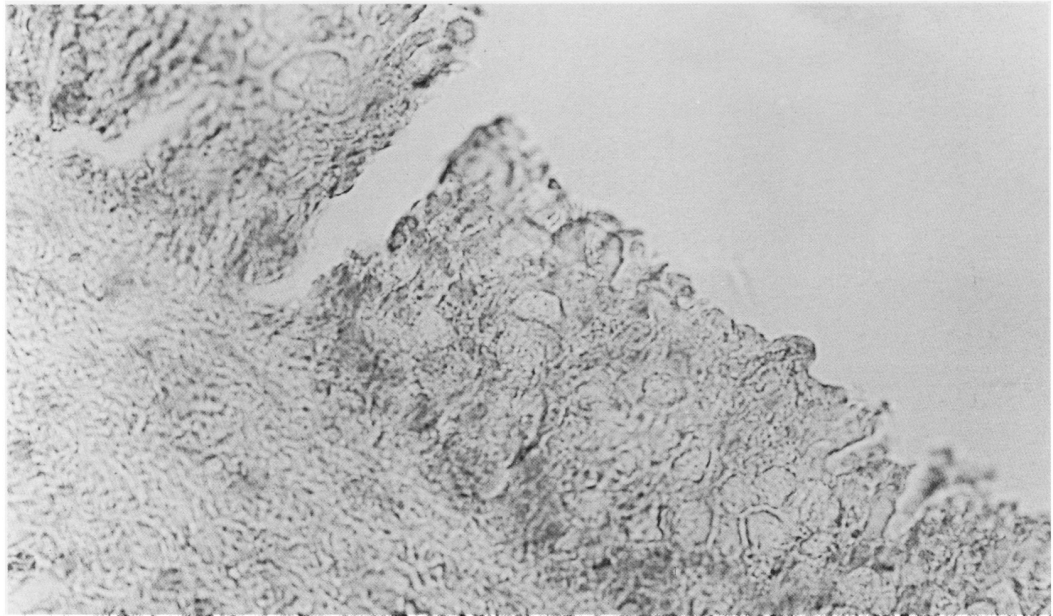
3.- B

Fig. 3.- **A:** Endoscopic aspect of the autotransplanted segment 15 days after surgery. Narrowing of the tracheal cross-section is seen. **B:** Macroscopic view of the autotransplanted segment, 180 days after surgery. A reduction on the external diameter of the trachea in the transplanted segment is noticed.

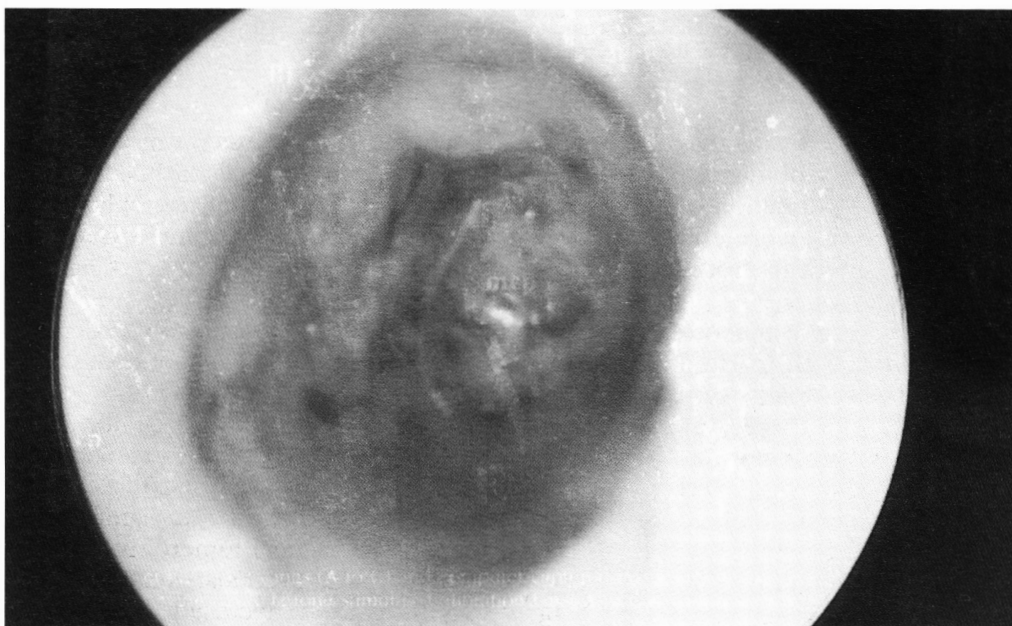

Fig. 4.- Endoscopic view of a ten-ring tracheal autotransplant. Complete occlusion of the tracheal lumen, caused by necrosis is shown.

5.- A



5.- B

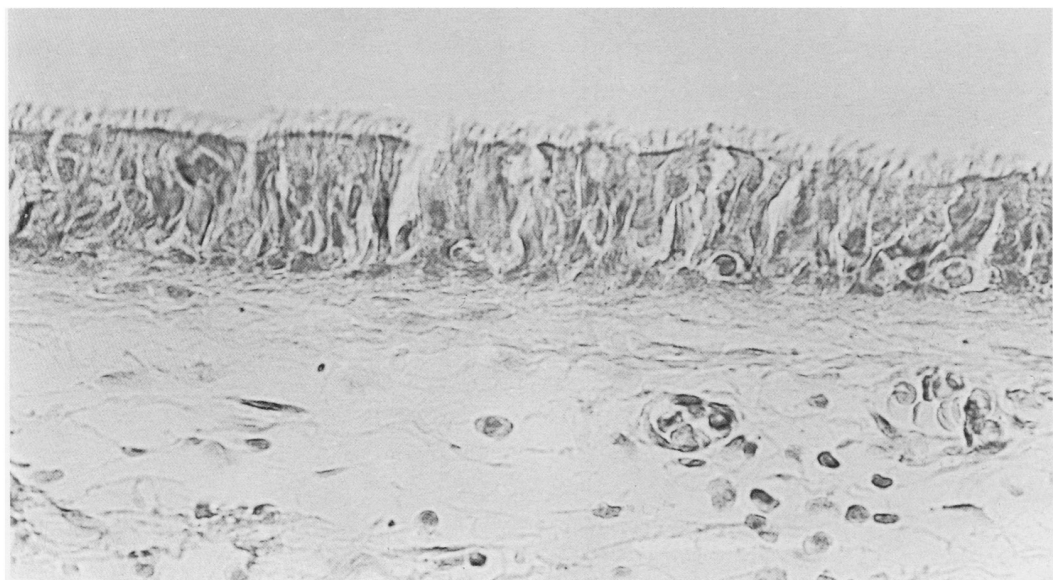


Fig. 5.- **A:** Optical microscopy aspect of a 4-ring tracheal segment autotransplant, 8 days after surgery. A marked reduction in the number of cilia as well as an increase in the height of the epithelial layer is noticed (H-E staining, x 400). **B:** View of the epithelial layer of a sham-operated animal, sacrificed 8 days after surgery (H-E staining, x 400).

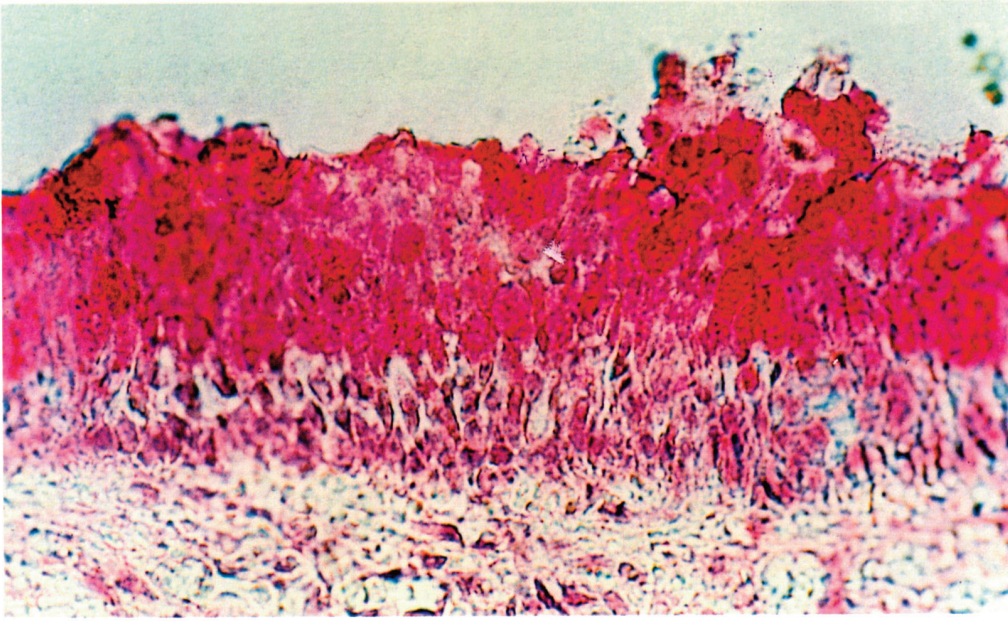
DISCUSSION

Surgery of the trachea and bronchi —tracheo-bronchoplasty— is a procedure widely used to treat tracheal stenosis (Chabolle, 1983; Grillo, 1969; Grillo et al, 1992; Jian et al., 1997). In patients with long areas of tracheal stenosis, however, tracheobroncoplasty cannot be applied (Donahue et al., 1997; Partridge and Flood-Page, 1997; Gavilan et al., 1998; Lano et al., 1998). In these cases, transplantation of tracheal segments has been envisaged as the treatment of the future (Salmeron et al., 1998).

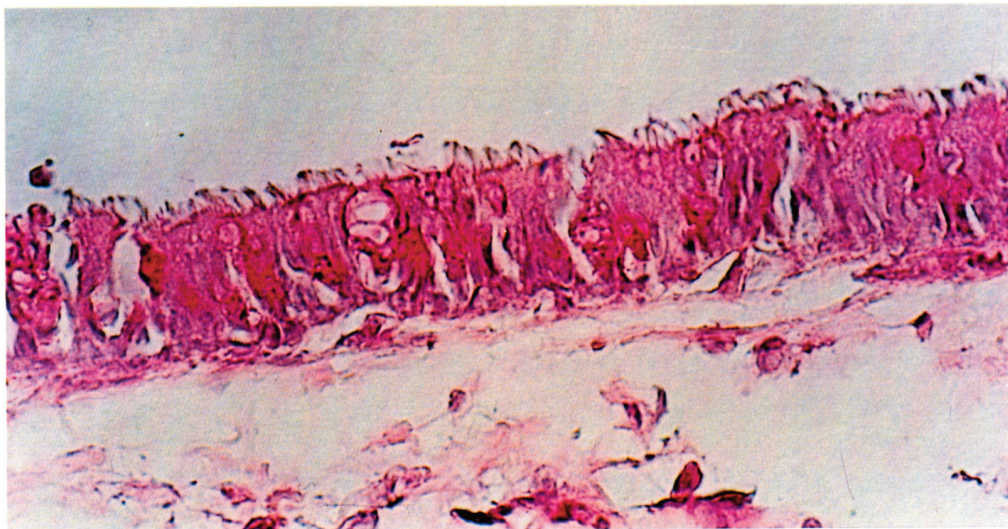Because the morphological features of the tissues affected in experimental tracheal transplantation have not been well defined, we decided to

investigate the structural modifications of the trachea due to autografting performed in the rabbit. Our data point to the viability of transplantation of short segments of trachea and reveal that the epithelium and cartilage of the trachea react differently to autografting.

Previous experimental studies have addressed tracheal autografting. In 1950, Daniel et al., published the results of experiments carried out on dogs, involving 3-ring tracheal autografting and reported tracheal necrosis one month after reimplantation. Also in the dog, Neville and colleagues found in 1976 that 3-ring autografts were able to preserve the tracheal lumen but the cartilage was reabsorbed; they also reported that 5-ring autografts caused necrosis and tracheal



6.- A



6.- B

Fig. 6.- **A:** Four ring tracheal autotransplant 8 days after surgery. An increase in the amount of mucous secretion is noticed (PAS staining, x 400). **B:** Sham-operated animal sacrificed 8 days after surgery (PAS staining, x 400).

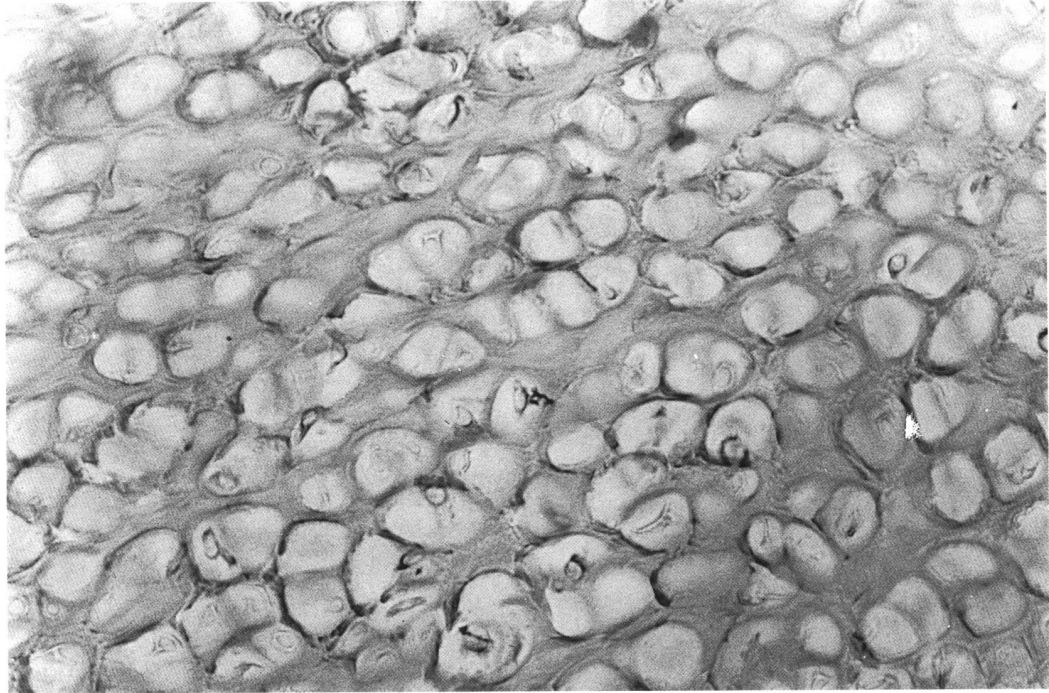
stenosis. In contrast, Inayama et al. (1995) did not report graft necrosis in a study on 4-to-6 ring tracheal autografts performed in the rabbit. In the present study we failed to successfully reimplant 10-ring tracheal segments in the rabbit but short segments (4 rings) were reimplanted with complete success as regards the long-term survival of the animals.

The main contribution of the present study is to establish the sequence of morphological alterations, from eight days up to six months, observed in rabbits subjected to autotransplantation of 4 tracheal rings. These alterations can be summarized as follows. The inflammatory response that occurs after autografting was accompanied by marked alterations in the epithelium, with loss of cilia and increase in both mucous cells and the mucous secretions detected on the epithelial surface. Signs of

remodeling of the cartilage were also observed early on after the grafting and these involved both mitotic figures and foci of cartilaginous necrosis. Taken together, these phenomena were interpreted as a response to the acute ischemia induced by surgery (Daniel et al., 1950; Saman and Ramon, 1997). Recovery of ciliated cells in the epithelium was already evident 15 days after transplantation. Neof ormation of vessels was also seen in the submucosa and was characterized by a thickening of the intima and a protrusion of the nuclei of the endothelial layer to the lumen. These morphological features can be interpreted as a sign of revascularization.

One month after surgery, the tracheal autografts showed a normal number of cilia on the epithelial surface. Signs of chronic inflammation—namely lymphocytic infiltration—were still present in the tracheal submucosa. The cartilage

7.- A



7.- B

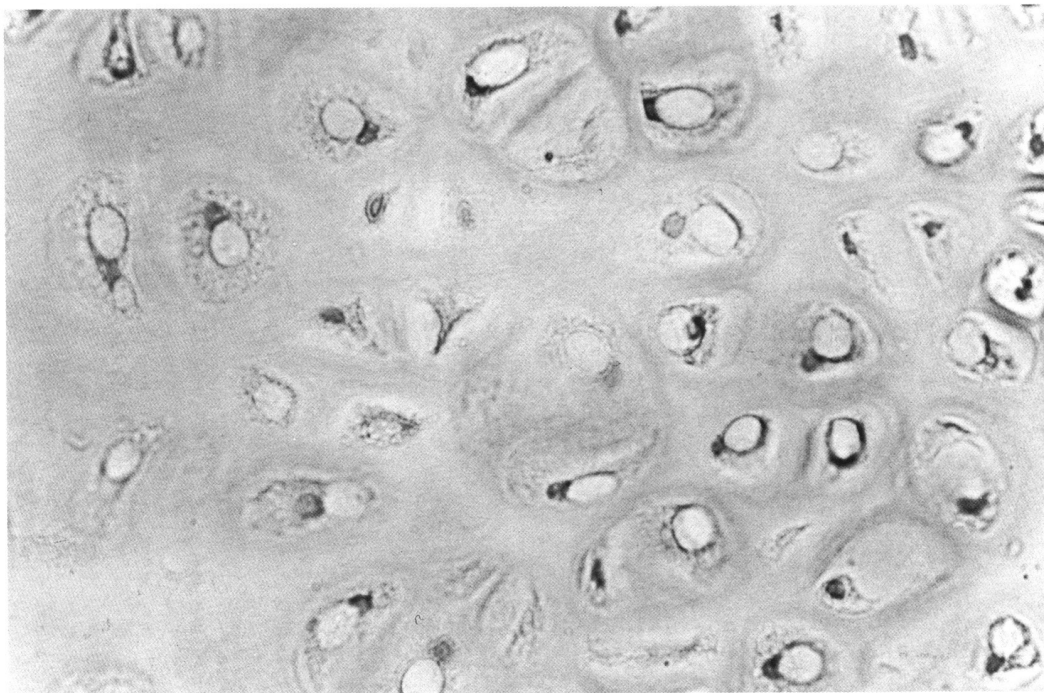


Fig. 7.- **A:** Cartilage aspect, 8 days after 4-ring tracheal autotransplant (H-E staining, x400). An increase in the number of condral cells is noticed. **B:** Cartilage aspect of a sham-operated rabbit, sacrificed 8 days after surgery (H-E staining, x 400).

rings showed alterations in their profile but remained viable and sufficiently rigid to keep the aerial tract open. Six months after surgery, the grafts displayed only a moderate degree of tracheal stenosis and degeneration of elastic fibers in the grafted areas. These changes did not seem to interfere with tracheal function or the survival of the rabbits.

The long-term mucosal alterations reported here are similar to those described by Inayama et al. (1995). In contrast to the observations by

these authors, we observed a certain delay in the recovery of ciliated cells of the epithelium. No progressive alterations of the elastic layer of the submucosa have been reported in any of the previous studies on experimental autografting; this could be due to unrecoverable damage to the continuity of the fibers as a result of surgery and ischemia.

The findings of our study suggests that autotransplant of a long segment (10 ring) is not feasible, most probably because of the prolonged

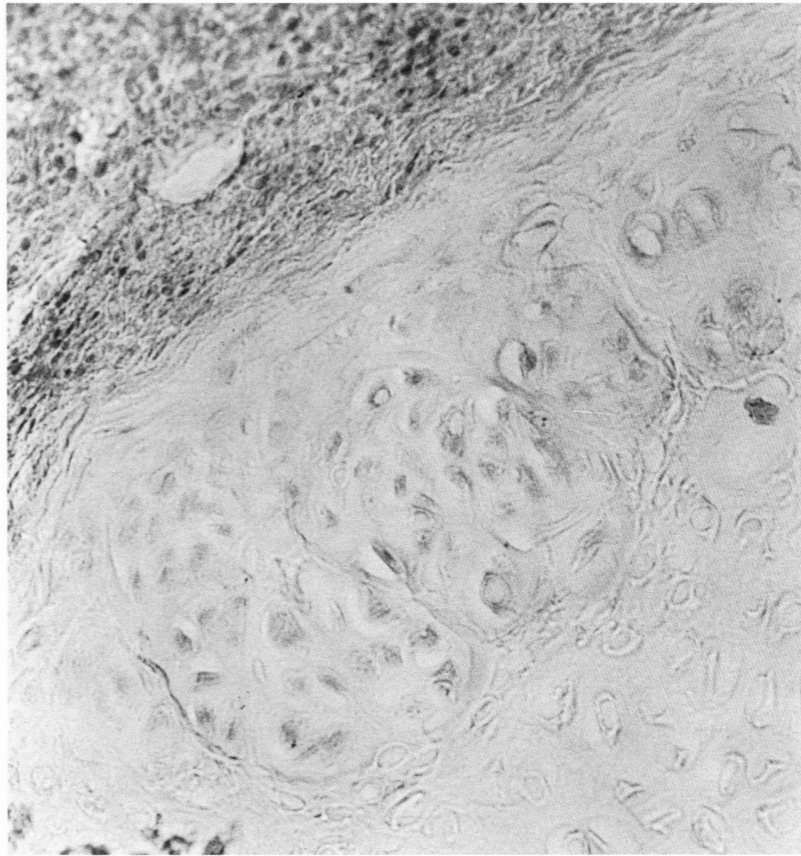

Fig. 8.- A necrotic area of cartilage, 15 days after 4-ring autotransplant (H-E staining, x 400).

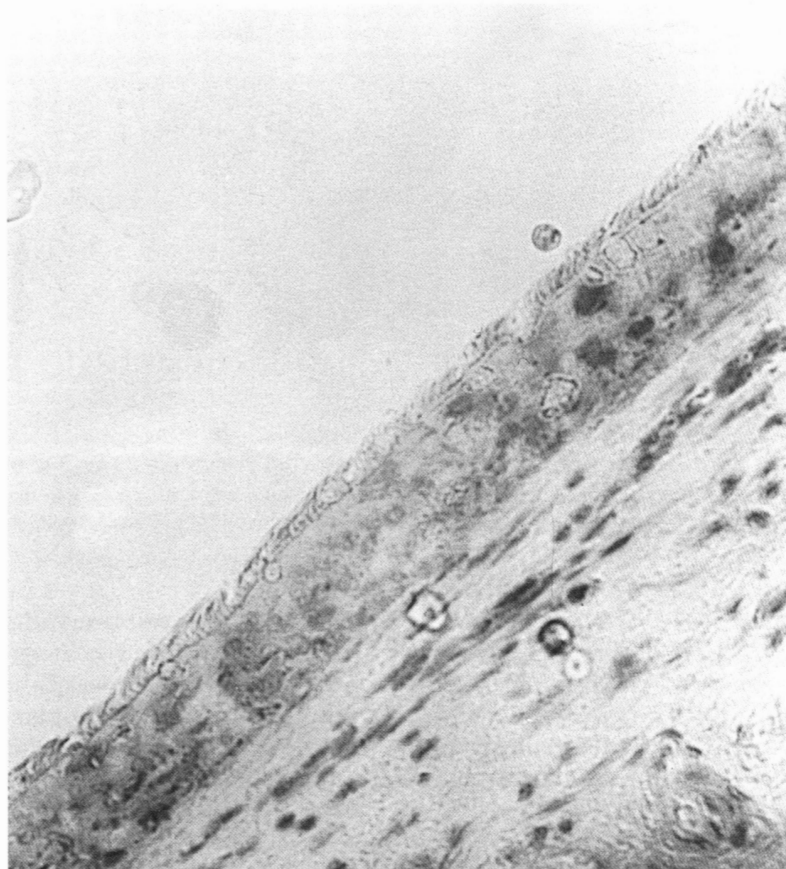


Fig. 9.- Epithelial layer covered with cilia, 30 days after 4-ring autotransplant (H-E staining, x 200).

ischemia undergone by the central part of the graft that ultimately causes necrosis of the transplant. In contrast, autotransplant of a short (4 ring) segment of the trachea is a viable surgical procedure, at least in the rabbit. We also conclude that the natural history of the adaptive response of the epithelium and cartilage is different in tracheal autografting; changes in the

mucosa are acute but transient whereas the lesions of the cartilage evolve slowly and are in the long run responsible for the observed moderate degree of stenosis of the trachea.

These different responses of the epithelium and cartilage should be taken into account whenever trachea transplantation is considered in humans.

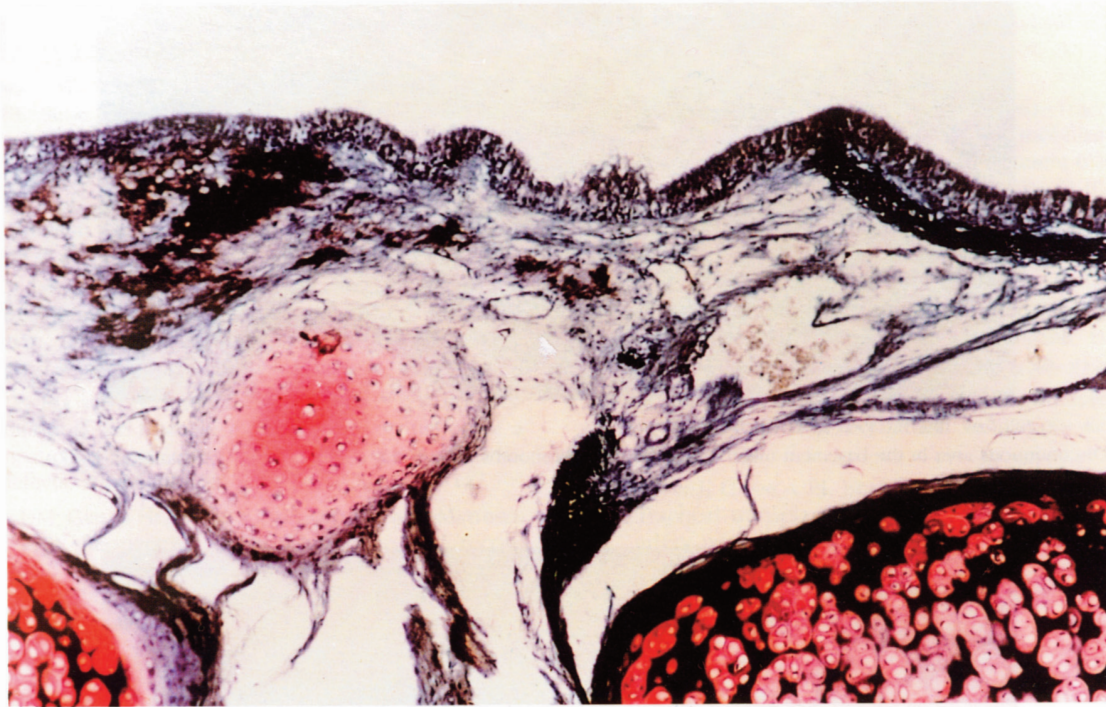


fig. 10.- View of the caudal scar area, three months after 4-ring autotransplant (Veroeff method staining, x 100). A cartilage focus independent from the cartilage rings is seen. Elastic fibers are scarce in the transplanted segment. The interruption in the elastic fiber layer is clearly seen on the right upper part of the figure.

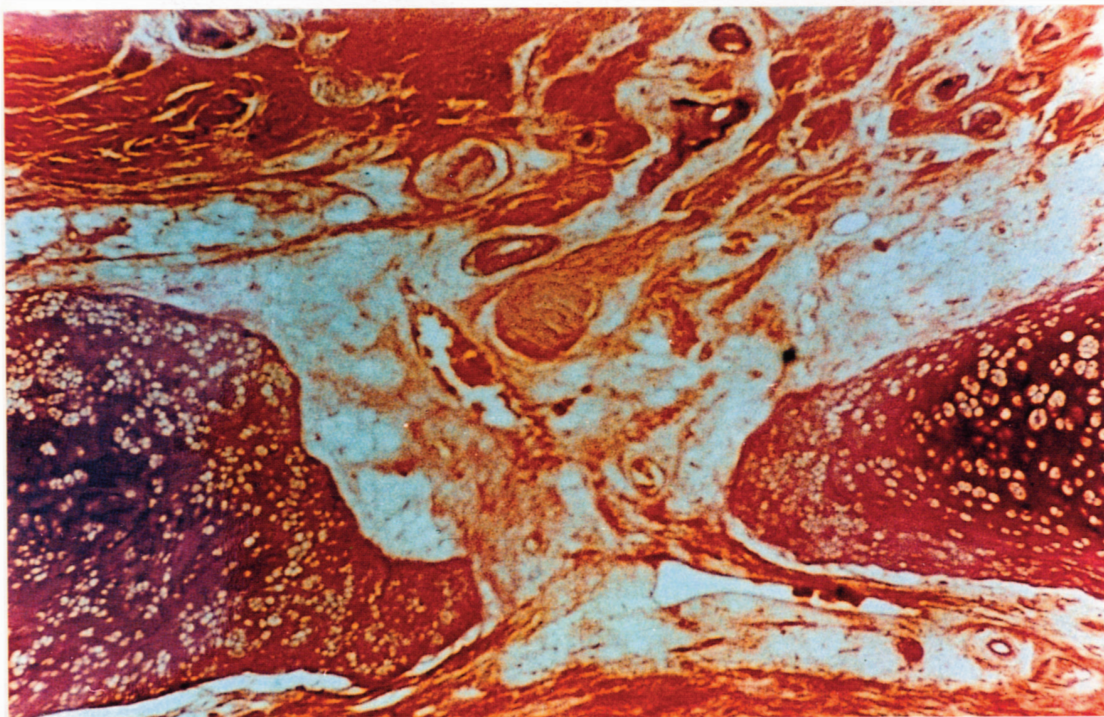


Fig. 11.- Remodeling of cartilage rings three months after 4-ring autotransplant. (H-E staining, x 100).

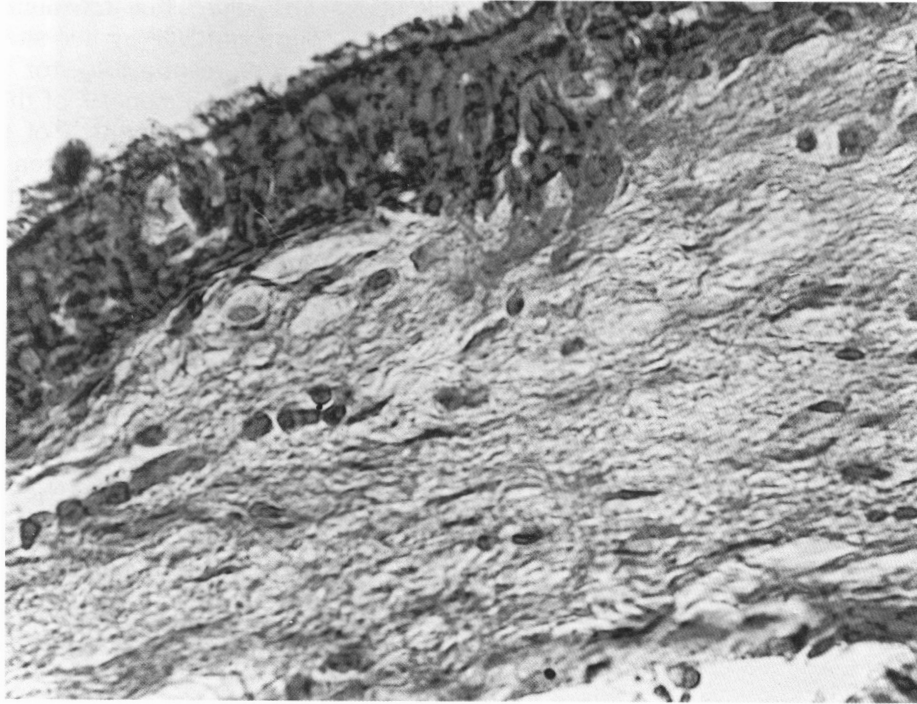


Fig. 12.- Discontinuous area in the basement membrane, observed six months after 4-ring autotransplant (PAS staining, x 400).

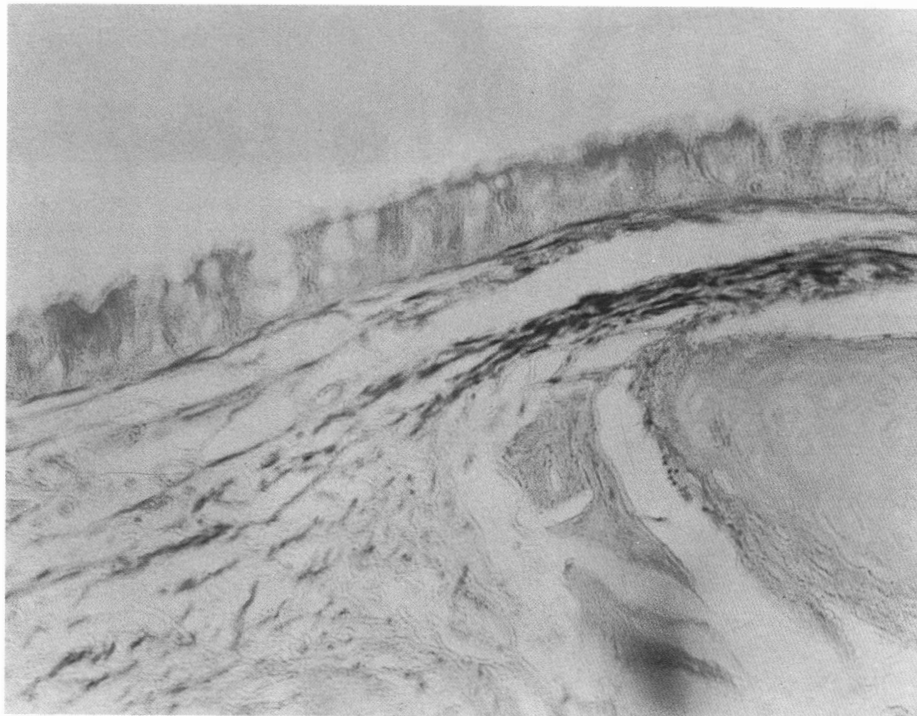


Fig. 13.- Aspect of the cranial scar, six months after 4-ring autotransplant. The interruption of the elastic fiber layer, as well as a marked reduction in the elastic fibers of the grafted area are seen (Veroeff method staining, x 200).

ACKNOWLEDGEMENTS

This work was supported by a contract from the Portuguese Ministry of Science and Technology to UMIB at ICBAS/UP.

REFERENCES

- BACKER C, MAVROUDIS C, DUNHAM ME and HOLINGER LD (1998). Repair of congenital tracheal stenosis with a free tracheal autograft. *J Thorac Cardiovasc Surg*, 115: 869-874.

- BONNETTE P, COLCHEN A, LEROY M and BISSON A (1998). Resection-anastomose trachéale pour sténose iatrogène. Une expérience de 340 cas. *Rev Mal Respir*, 15: 627-632.
- CHABOLLE F (1983). Les sténoses laryngées et tracheales non tumorales de l'adulte (a propos de 145 cas). Thèse Paris (Pitié-Salpêtrière).
- CHENG A, BACKER C, HOLINGER L, DUNHAM M, MAVROUDIS C and CRUSSI F (1997). Histopathologic changes after pericardial patch tracheoplasty. *Arch Otolaryngol Head Neck Surg*, 123: 1069-1072.
- COTTER CS, JONES DT, NUSS RC and JONAS R (1999). Management of distal tracheal stenosis. *Arch Otolaryngol Head Neck Surg*, 125: 325-333.
- CUNNINGHAM MJ, EAVEY RD, VIAHAKES GJ and GRILLO HC (1998). Slide tracheoplasty for long-segment tracheal stenosis. *Arch Otolaryngol Head Neck Surg*, 124 : 98-103.
- DANIEL RA Jr, TALIAFERRO RM and SCHAFFARZICK WR (1950). Experimental studies on the repair of wounds and defects of the trachea and bronchi. *Chest*, 17: 426-36.
- DELAERE P, POORTEN V, GOELENEN A, FERON M and HERMANS R (1998). Tracheal autotransplantation: A reliable reconstructive technique for extended hemilaryngectomy defects. *Laryngoscope*, 108: 929-934.
- DELAERE P, POORTEN V and HERMANS R (1999). Autotransplantation of the trachea: Experimental evaluation of a reconstructive technique for extended hemilaryngectomy defects. *Ann Otol Rhinol Laryngol*, 108: 143-147.
- DONAHUE DM, GRILLO HC, WAIN JC, WRIGHT CD and MATHISEN DJ (1997). Reoperative tracheal resection and reconstruction for unsuccessful repair of postintubation stenosis. *J Thorac Cardiovasc Surg*, 114: 934-942.
- ELLIOTT M, HAW M, JACOBS J, BAILEY C, EVANS J and HERBERHOLD C (1996). Tracheal reconstruction in children using cadaveric homograft trachea. *Eur J Cardiothorac Surg*, 10: 707-712.
- GAVILAN J, CERDEIRA MA and TOLEDANO A (1998). Surgical treatment of laryngotracheal stenosis: a review of 60 cases. *Ann Otol Rhinol Laryngol*, 107: 588-92.
- GRILLO HC (1969). The management of tracheal stenosis following assisted respiration. *J Thorac Cardiovasc Surg*, 157: 52-71.
- GRILLO HC, DOUGLAS JM and WAIN JC (1992). Laryngotracheal resection and reconstruction for subglottic stenosis. *Ann Thorac Surg*, 53: 54-63.
- HAIDER H, ZAGALO C and SANTIAGO N (1998). Laryngotracheal Stenosis: Experience of the Portuguese Institute of Oncology. *Rev Port ORL*, 36: 265-276.
- INAYAMA Y, TOMIYAMA I, AKAIDE M, KASE M, NAKAYAMA H, MOROHOSHI T, MATSUMOTO A and KANISAWA M (1995). Morphologic alterations and cytokinetic studies of tracheal autograft epithelium in rabbits. *Ann Thorac Surg*, 60: 952-957.
- JIAN LI, XU P and CHEN H (1997). Successful tracheal autotransplantation with two-stage approach using the greater omentum. *Ann Thorac Surg*, 64: 199-202.
- LACCORREYE H, MENARD M and LACCOURREYE O (1993). Chirurgie des sténoses laryngotrachéales de l'adulte. Editions Techniques, Paris (France). *Encycl Méd Chir Techniques Chirurgicales-Tête et Cou*, 46: 390-402.
- LANO Jr CF, DUNCAVAGE JA, REINISCH L, OSSOF RH, COUREY MS and NETTERVILLE JL (1998). Laryngotracheal reconstruction in the adult: a ten year experience. *Ann Otol Rhinol Laryngol*, 107: 92-99.
- MELLO F, MAMEDE R and VELLUDO M (1996). Tracheal neovascularization: A method involving mobilization of a complete tracheal neovascularized segment using a sternohyoid muscle flap. *Laryngoscope*, 106: 81-85.
- NEVILLE WE, BOLANOSKI PJP and SCOLTAZADEH H (1976). Homograft replacement of the trachea using immunosuppression. *J Thorac Cardiovasc Surg*, 72: 596-601.
- PANDA NK and MANN SB (1997). Modified laryngotracheoplasty for surgical management of chronic laryngotracheal stenosis in adults. *J Otolaryngol*, 26: 241-245.
- PARTRIDGE MR and FLOOD-PAGE P (1997). Multiple tracheal strictures following mechanical ventilation. *Respir Med*, 91: 503-504.
- SALMERON J, GANNON PJ, BLACKWELL KE and URKEN M (1998). Tracheal transplantation: Superior and inferior thyroid artery perfusion territory. *Laryngoscope*, 108: 849-853.
- SAMAN N and RAMON M (1997). Effect of intraoperative ischemia on chondrogenesis by vascularized auricular perichondrium grafted in the airway. *Ann Otol Rhinol Laryngol*, 106: 237-239.
- SILVA MT (1984). The use of transmission electron microscopy of ultrathin sections for the characterization of normal and damaged bacterial membranes. In: Guerra FC and Burton RM (eds.). *Biomembranes: Dynamics and Biology*. Plenum Press, New York, pp 1-15.
- STROME M (1998). 7th International congress on surgical and prosthetic voice restoration after total laryngectomy: Arcachon, France.
- VLANTIS AC, MARRS HA and VAN den HOOGEN FJ (1998). A surgical technique to prevent tracheostomal stenosis after laryngectomy. *Laryngoscope*, 108: 134-137.
- WAX MK, TOUMA BJ and RAMADAN HH (1998). Tracheostomal stenosis revision with simultaneous tracheoesophageal puncture. *Laryngoscope*, 108: 1509-1513.
- WHEATER PR, BURKITT HG and DANIELS VG (1990). Functional Histology. Churchill Livingstone, London, pp 183.