

Morphometric analysis of the extensor tendons of the hallux and potential implications for tendon grafting

Diogo Casal^{1,2}, Diogo Pais¹, Maria Angélica-Almeida², Tiago Bilhim¹, António Santos¹, João Goyri-O'Neill¹

1- Anatomy Department; Medical Sciences Faculty, New University of Lisbon, Portugal

2- Plastic and Reconstructive Surgery Department, São José Hospital, Lisbon, Portugal

SUMMARY

Although several tendon sources are available for reconstructive surgical procedures, all have one or more shortcomings. The aim of this work was to evaluate if the extensor tendons of the hallux showed anatomical characteristics that could make them an additional source for tendon grafting procedures.

The authors performed a detailed morphometric analysis of the extensor tendons of the hallux in 26 lower limbs in order to evaluate the putative association of anatomical variants with hallux valgus, and to attempt to assess the feasibility of using part of the extensor apparatus of the hallux as a source of tendon for grafting procedures.

An accessory extensor hallucis longus tendon was found in 92.3% of cases. The extensor hallucis brevis tendon length was 10.5 ± 0.6 cm; its width was 0.5 ± 0.1 cm, and its thickness varied between 1-2 mm, making it a potentially good candidate as a source of tendon grafts. Several anatomical variations were observed, namely the fusion of the tendons of the extensor hallucis brevis and the accessory extensor hallucis longus muscles in the distal part of the foot.

This new therapeutic option, if implemented, would possibly increase the supply of auto-

genous donor tissue for reconstructive procedures, thereby enhancing the reconstructive surgeon's armamentarium.

Key words: Extensor hallucis longus – Extensor hallucis brevis – Variation – Tendon injuries – Tissue graft

INTRODUCTION

Tendon grafts are often needed in reconstructive surgery and in the realms of Orthopedics, Plastic Surgery, Maxillofacial Surgery, Burn Surgery, and even in Heart Surgery (Wehbe, 1994; Schenk et al., 2009; Terzis and Kyere, 2008). These tendon grafts can be used to reconstruct tendon or ligament defects, stabilize joints and maintain soft tissues in position (Breek et al., 1989). Recently, the use of the plantaris tendon has been proposed for atrioventricular valve repair (Shuhaiber and Shuhaiber, 2003).

Redundancy in the function of certain tendons has been known for decades (Brand, 1961), allowing several alternatives for tendon harvesting to become perfectly established. However, when a patient sustains extensive injuries, it is not uncommon for autologous tendons to be insufficient to reconstruct all

the missing structures (Williamson and Richards, 2006). In addition, all tendon options currently in use for grafting procedures have one or more several limitations, namely: inconstancy; their removal results in a variable deficit in the donor region; and the surgical incisions required to perform their extirpation are located in body areas where healing is known to be suboptimal and thus results in conspicuous scars (Williamson and Richards, 2006; Tang, 2009). Therefore, any new alternative that might increase the supply of autologous tendons for reconstructive procedures would be invaluable.

Supernumerary tendons in the hallucal extensor apparatus have been well documented for more than 125 years (Macalister, 1875; Gray, 1918; Gruber, 1875; Sarrafian and Topouzian, 1969). In 1976, Tate and Pachnik described an accessory tendon of the extensor hallucis longus in the majority of individuals (Tate and Pachnik, 1976). In the 1980s Kaneff, Andreev and Stephanoff studied in detail the extensor tendons in the first ray of the foot, reporting several accessory tendons and over 20 different variations (Kaneff, 1986a, b; Kaneff and Andreev, 1983; Kaneff and Stephanoff, 1982). More recently, these findings have been reproduced by several authors (Denk et al., 2002; Bibbo et al., 2004; Hill and Gerges, 2008; Al-Saggaf, 2003; Bergman et al., 1988; Boyd et al., 2006; Aktekin et al., 2008).

Notwithstanding the reported high frequency of these accessory tendons, their clinical importance has been considered relatively minor, and their description is even omitted from many modern, comprehensive clinical anatomy textbooks (Hill and Gerges, 2008; Moore and Dalley, 2006). Moreover, the extensor tendons of the foot have not been used, as far as the authors know, as sources of tendon grafts (Chang, 2006; Tang, 2009).

Furthermore, certain authors have associated certain variations in the extensor apparatus of the hallux to hallux valgus (Al-Saggaf, 2003), which is a common condition in which there is lateral deviation of the big toe, at the metatarso-phalangeal joint (Prosche et al., 2004). However, these findings have not been replicated by others and are still a matter of debate (Bibbo et al., 2004).

Thus in this work we studied the extensor tendons of the hallux from human cadavers in order to evaluate the potential of any of these tendons as a source of tendon grafts, and to

assess whether there might be any association between the morphometric features of these tendons and the presence of hallux valgus.

MATERIALS AND METHODS

The study was performed on 26 lower extremities of freshly frozen adult human cadavers used for routine gross anatomical dissections at the Medical Sciences Faculty in Lisbon, Portugal. Age at death was mostly between 60 and 85 (average 72.3) years. There were 7 men (53.8%) and 6 women (46.2%). They had had no prior surgical procedures in the leg or foot regions.

The dorsum of the foot and lower leg were carefully dissected, exposing the extensor tendons of the hallux from their origin to their insertion. Their origin, length, width, thickness and type of insertion were recorded, as well as the occurrence of hallux valgus. The mean width of each tendon was calculated based on the average of the widths measured at three points: tendon origin, middle portion of the tendon, and immediately before insertion, in the most distal place where it would be surgically possible to section the tendon for harvesting.

This research required no specific permission from the ethics committee of our institution, and conformed to the provisions of the Declaration of Helsinki (1995, revised 2000).

Statistical analyses were performed using the PASWO 18.0 (IBM®) Statistical Analysis Software. The Chi-Square test was used to compare proportions, while Student's *t* test and ANOVA were used for comparing means. A *p* value below 0.05 was considered statistically significant. Mean values are represented by their numerical value \pm standard deviation.

RESULTS

In all cases, the extensor apparatus of the hallux was composed of the extensor hallucis longus tendon (EHLp) and the extensor hallucis brevis tendon (EHB). An accessory extensor hallucis longus tendon (EHLa) was found in 92.3% of cases. Figure 1 portrays the usual composition of the extensor tendons of the hallux. The EHLa originated from the same muscular belly as the EHLp in all cases (Fig. 1). When present, the EHLa was placed medially to the EHLp (91.7%) since its origin to its termination. Only in two feet, in

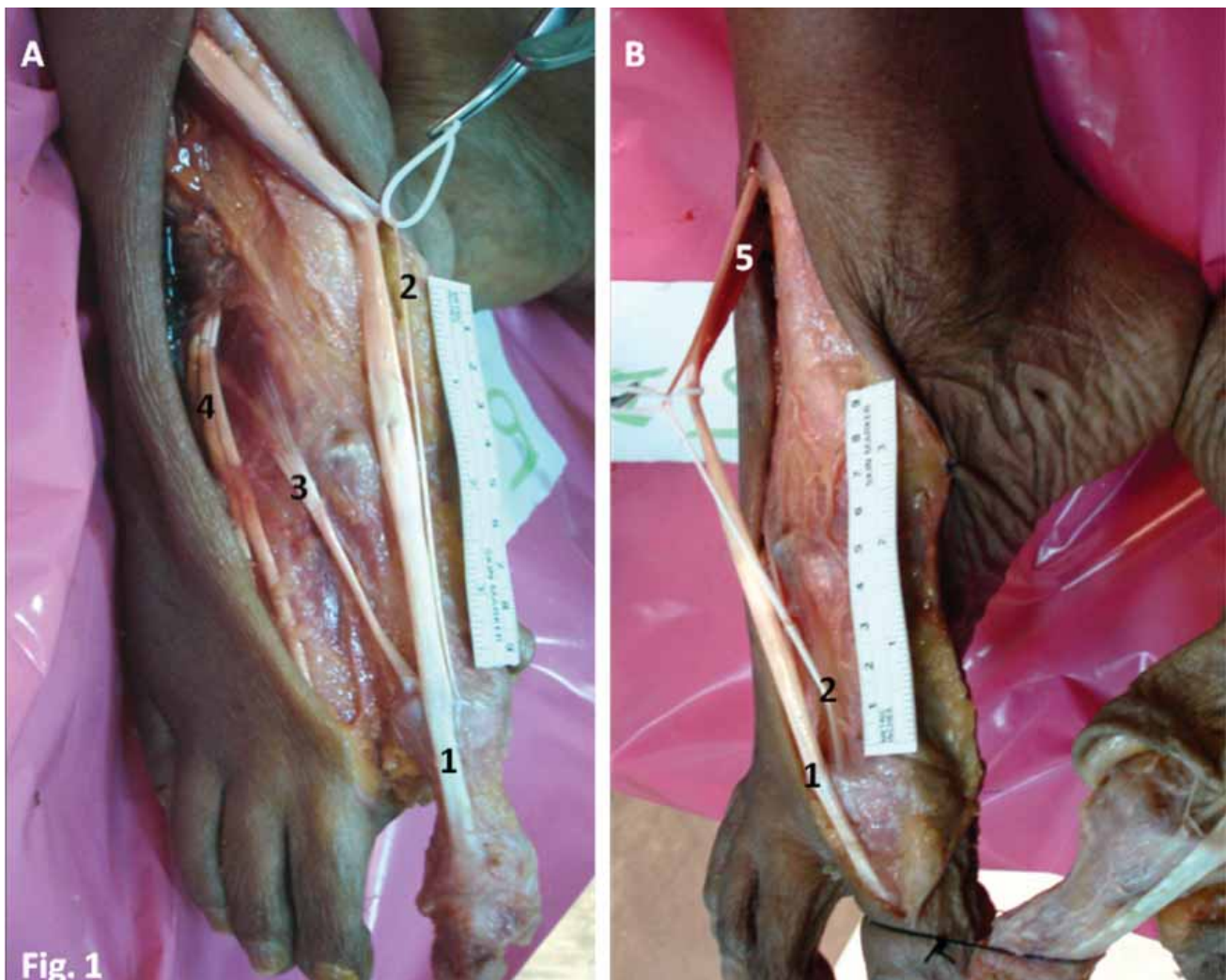


Figure 1. Dorsal (A) and medial (B) views of the right foot showing the extensor tendons of the hallux. 1- Extensor hallucis longus tendon; 2- Accessory extensor hallucis longus tendon; 3- Extensor hallucis brevis tendon; 4- Extensor digitorum longus tendons; 5- Common muscle belly of the extensor hallucis longus muscle giving off the extensor hallucis longus tendon and its accessory tendon.

the same cadaver, was the EHL_a absent (Fig. 2A). In both feet of one cadaver (8.3%) the EHL_a was placed laterally to the EHL_p and terminated in the medial portion of the EHB (Fig. 2B). In one foot, there were two separate EHL_a, one of them with a normal diameter but the other much thinner, that inserted separately at the base of the distal phalanx. These two separate EHL_a were placed laterally to the EHL_p.

Table 1 summarizes the results obtained globally, as well as those obtained after stratifying for sex and height. The EHL_a mean width (0.3 ± 0.1 cm) was significantly lower than that of the EHL_p (1.0 ± 0.2 cm), corresponding to approximately one third. However, in one cadaver this EHL_a had a mean width of 0.5 mm bilaterally; i.e., half of the mean width of the EHL_p itself in that case. There were no statistically significant differences

between tendon length and width on the right and left sides.

The mean EHB length was 10.5 ± 0.6 cm, and its mean width was 0.5 ± 0.1 cm; i.e., half of the EHL_p. The average thickness of the EHL_p, EHL_a, and of the EHB were remarkably constant, being approximately 3-4 mm, 0.5-1 mm, and 1-2 mm, respectively.

The EHB terminated in the dorsal and medial aspect of the base of the proximal phalanx of the hallux in all cases. The pattern of insertion of the EHL_p and the EHL_a, by contrast, was variable. In most cases (92.3%), the tendons terminated separately: the EHL_p at the base of the distal phalanx of the hallux and the EHL_a in the medial aspect of the dorsum of the base of the proximal phalanx of the big toe. In the only cadaver in which there was no EHL_a, the EHL_p terminated in the usual fashion at the

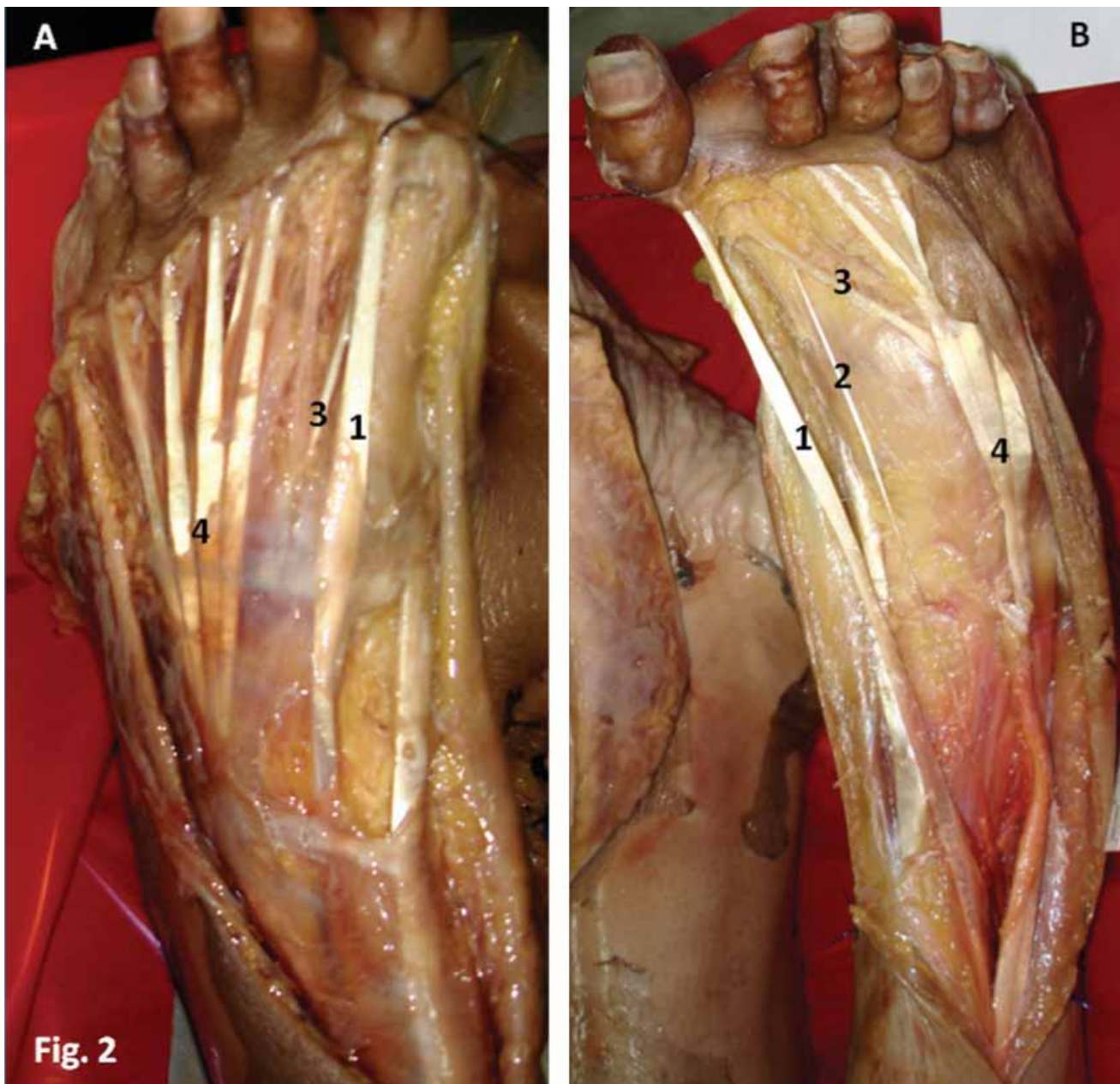


Figure 2. Dorsal view of the left (A) and right (B) feet of two different cadavers, showing anatomical variations in the extensor tendons of the hallux. In Figure 2A there is no accessory extensor hallucis longus tendon. In Figure 2B the accessory extensor hallucis longus tendon is placed laterally to the main extensor hallucis longus tendon and fuses with the extensor hallucis brevis tendon. 1- Extensor hallucis longus tendon; 2- Accessory extensor hallucis longus tendon; 3- Extensor hallucis brevis tendon; 4- Extensor digitorum longus tendons.

base of the distal phalanx. In one case in which there were two EHLs, these two tendons and the EHLp terminated isolatedly at the base of the proximal and distal phalanx, respectively. Thus, according to the Al-Sagaff classification of the insertion of the extensors of the hallux, the type I pattern was found in 92.4% of cases, whereas patterns I and III were found in 3.8% each (Al-Sagaff, 2003).

Hallux valgus was more frequent in females (72.7%) than in males (27.3%), this difference being statistically significant ($p = 0.02$). No

other associations between the presence of hallux valgus and other parameters, namely type of insertion, were found.

DISCUSSION

The composition of the extensor tendons of the hallux in our series did not differ significantly from what has been described in the literature, except for the prevalence of EHLs, which was 92.3% in our series; that is to say, much higher than that described originally by

		<1,75 m in Height (n=13)		>1,75 m in Height (n=13)		Overall n=26
		Male n=3	Female n=10	Male n=11	Female n=2	
EHLp	Length (cm)	24,5 ± 1,3 [23,5-26,0]	23,6 ± 0,6 [23,0-24,5]	26,5 ± 1,1 [25,0-28,0]	23,5 ± 0,1 [23,4-23,6]	24,9 ± 1,7 [23,0-28,0]
	Mean Width (cm)	0,9 ± 0,1 [0,8-1,1]	0,9 ± 0,1 [0,8-1,1]	1,1 ± 0,2 [0,7-1,3]	1,0 ± 0,1 [0,9-1,1]	1,0 ± 0,2 [0,7-1,3]
EHLa	Frequency	100%	90%	90,9%	100%	92,3% (24/26)
	Length (cm)	22,3 ± 1,9 [21,0-24,5]	21,4 ± 0,6 [21,0-22,5]	23,9 ± 0,7 [23,0-25,0]	22,0 ± 0,0 [22,0-22,1]	22,6 ± 1,4 [21,0-25,0]
	Mean Width (cm)	0,2 ± 0,0 [0,2-0,3]	0,3 ± 0,1 [0,2-0,4]	0,3 ± 0,1 [0,2-0,5]	0,3 ± 0,0 (0,3)	0,3 ± 0,1 [0,2-0,5]
	Position relatively to EHLp when present	Medial	100%	100%	80%	100%
Lateral		0%	0%	20%	0%	8,3%
EHB	Length (cm)	10,3 ± 0,8 [9,5-11,0]	10,1 ± 0,7 [9,0-11,0]	10,9 ± 0,2 [10,5-11,0]	10,0 ± 0,1 [9,9-10,1]	10,5 ± 0,6 [9,0-11,0]
	Mean Width (cm)	0,5 ± 0,1 [0,4-0,5]	0,4 ± 0,1 [0,4-0,6]	0,5 ± 0,1 [0,4-0,6]	0,4 ± 0,1 [0,4-0,6]	0,5 ± 0,1 [0,4-0,6]
Pattern of Insertion	I	0%	0%	9,1%	0%	3,8% (1/26)
	II	100%	90%	90,9%	100%	92,3% (24/26)
	III	0%	10%	0%	0%	3,8% (1/26)
Frequency of Hallux Valgus		100%	60%	27,3%	100%	42,3%

Table 1. Morphometric features of the extensor tendons of the hallux in 26 feet. EHLp- extensor hallux longus proprius tendon; EHLa - extensor hallux longus accessorius tendon; EHB - extensor hallux brevis tendon. Pattern of insertion of the extensor apparatus is divided into three classes according Al-sagaff (2003). Values between [] represent the limits of variation of each variable.

Author(s)	Number of specimens studied
(Sarrafian and Topouzian, 1969)	30
(Kaneff, 1986a)	151
(Denk et al., 2002)	63
(Al-saggaf, 2003)	60
(Bibbo et al., 2004)	32
(Boyd et al., 2006)	81
(Aktekin et al., 2008)	90

Table 2. Sample sizes of the largest studies on the extensor halluc tendons published in the last 40 years.

Kaneff and Al-Saggaf, who reported values of 48.88% and 35%, respectively (Kaneff, 1986b; Al-Saggaf, 2003). However, our value is not significantly higher than that described recently by other authors, who described an EHLA in 70-87% of cases (Tate and Pachnik, 1976; Denk et al., 2002; Bibbo et al., 2003; Hill and Gerges, 2008). It is plausible that the differences found among the different authors may be due to population differences. However, given that our series of 26 specimens is relatively small (Table 2), we believe that further studies are warranted to test this hypothesis.

Al-Saggaf postulated that the presence of a supernumerary tendon of the extensor hallucis longus could be a predisposing factor for the development of hallux valgus (Al-Saggaf, 2003). However, this association was not replicated in subsequent investigations (Bibbo et al., 2004). Similarly, we also failed to identify any statistically significant association between the presence of EHLA or any other morphometric feature and the presence of hallux valgus.

We found several anatomical variations regarding the EHLA. In 7.7% of cases this supernumerary tendon was absent. In addition, although it was almost always located medially to the EHLp (91.7%) it was also placed lateral to it (8.3%). Interestingly, in one case the EHLA was placed laterally to the EHLp and terminated in the medial portion of the EHB, which in turn terminated in the usual fashion: in the dorsal and medial aspect of the base of the proximal phalanx of the hallux. This variation has been described for the

first time by Denk et al. (2002) and corresponds, as far as the authors know, to the second case reported in the literature.

By performing a morphometric analysis of the extensor tendons of the hallux, we observed that the EHLA and the EHB had, on average, a width that was one third and one half of that of the EHLp, respectively. This observation was not mentioned in the literature review we conducted, and may be of great interest for a better understanding of the functional aspects of the foot and their correlation with clinical findings. This knowledge could, for example, help explain why conservative treatment may suffice in a substantial number of cases of EHLp section or rupture, since the EHB and the EHLA will probably maintain the cut ends of the EHLp tendon close together, allowing tendon repair to occur spontaneously and thereby avoiding the need for surgery (Scaduto and Cracchiolo, 2000).

In addition, this study unequivocally suggests that the relatively large width and thickness of the EHB, as well as its significant length and constancy, would make EHB an excellent candidate as a source of tendon grafts. Moreover, this tendon fulfills all the other criteria currently accepted for donor tendons for tendon or ligament repair. In this sense, it is not situated too deeply, and hence would facilitate harvesting; no significant donor site loss would result from its harvesting, and its cross sectional diameter is not too large to hamper revascularization, while still being sufficient to provide enough autologous

material for reconstruction (Williamson and Richards, 2006). Another potential advantage of using this tendon as a graft would be that the surgical incision necessary to harvest it would be placed in the dorsum of the forefoot, which corresponds to a place of the body where wounds usually heal inconspicuously and where scars are not easily visible (Parkhouse et al., 2006). This is a major advantage relative to other donor sites, such as the forearm and leg, where scars are frequently more noticeable (Parkhouse et al., 2006).

Functionally, there is strong evidence to suggest that harvesting this tendon would not result in any significant clinical deficit, since the tendon is routinely incorporated in the dorsalis pedis flap with no resulting impairment of the extension of the hallux (Furlow, 2009). Indeed, it is unanimously accepted that the main function of the EHB is only to aid the EHLp in extending the big toe at the metatarso-phalangeal joint (Moore and Dalley, 2006).

Additionally, the EHB compares favorably with the tendons commonly used in clinical practice in terms of certain anatomical characteristics. The palmaris longus tendon, for example, which is the most commonly used donor tendon in Hand Surgery (Williamson and Richards, 2006), is only slightly longer (10 to 12 cm), and has a similar width and thickness: 3-5 mm and 1-2 mm, respectively (Chui and Edgerton, 1990). Moreover, whereas the EHB is generally considered to be constant, the palmaris longus muscle is known to be absent in up to 12 to 25% of limbs (Williamson and Richards, 2006; Neumeister and Wilhelmi, 2006; Moore and Dalley, 2006). The plantaris tendon, which is also commonly used in reconstructive procedures, is also absent in 18% of limbs (Williamson and Richards, 2006).

In spite of all these potential advantages, the use of the EHB has been overlooked as a potential tendon donor site in Reconstructive Surgery (Chang, 2006; Williamson and Richards, 2006; Tang, 2009; Neumeister and Wilhelmi, 2006). We believe this is rather unfortunate, since the EHB would be particularly well suited for the repair of torn ligaments of the hand, such as the collateral ligaments of the metacarpal-phalangeal joint of the thumb (Breek et al., 1989); the reconstruction of the A2 and A4 pulleys associated with the flexor tendons of the hand (Pederson et al., 2006) and, eventually, in some facial

reconstructive procedures, to contribute to soft tissue suspension (Terzis and Kyere, 2008). This proposal, if implemented, would increase the supply of autologous donor tissue for reconstructive procedures, thereby enhancing the surgeon's arsenal.

ACKNOWLEDGMENTS

The authors appreciate the proficiency of all Technical Staff members of the Department of Anatomy, in particular of Mr. Carlos Lopes and of Mr. Marco Costa.

REFERENCES

- AKTEKIN M, UZMANSEL D, KURTOGLU Z, SANLI EC, KARA AB (2008). Examination of the accessory tendons of extensor hallucis longus muscle in fetuses. *Clin Anat*, 21: 713-717.
- AL-SAGGAF S (2003). Variations in the insertion of the extensor hallucis longus muscle. *Folia Morphol*, 62: 147-155.
- BERGMAN RA, AFIRI AK, MIYAUCHI R (1988). Illustrated encyclopedia of human anatomic variations.
- BIBBO C, ANDERSON RB, DAVIS WH (2003). Injury characteristics and the clinical outcome of subtalar dislocations: a clinical and radiographic analysis of 25 cases. *Foot Ankle Int*, 24: 158-163.
- BIBBO C, ARANGIO G, PATEL DV (2004). The accessory extensor tendon of the first metatarsophalangeal joint. *Foot Ankle Int*, 25: 387-390.
- BOYD N, BROCK H, MEIER A, MILLER R, MLADY G, FIROOZBAKHS K (2006). Extensor hallucis capsularis: frequency and identification on MRI. *Foot Ankle Int*, 27: 181-184.
- BRAND PW (1961). Tendon grafting. *J Bone Joint Surg*, 43B: 444-453.
- BREEK JC, TAN AM, VAN THIEL TP, DAANTJE CR (1989). Free tendon grafting to repair the metacarpophalangeal joint of the thumb. Surgical techniques and a review of 70 patients. *J Bone Joint Surg Br*, 71: 383-387.
- CHANG P (2006). Repair and grafting of tendon. In: MATHES SJ (ed.) *Plastic Surgery*. 2nd ed. Saunders, Philadelphia.
- CHUI DTW, EDGERTON BW (1990). Repair and grafting of tendon. In: MCCARTHY JG (ed.) *Plastic Surgery*. 1st ed. Saunders, Philadelphia.
- DENK CC, OZNUR A, SURUCU HS (2002). Double tendons at the distal attachment of the extensor hallucis longus muscle. *Surg Radiol Anat*, 24: 50-52.
- FURLOW LT (2009). Dorsalis Pedis Flap. In: STRAUCH B, VASCONEZ LO, HALL-FINDLAY EJ, LEE BT (eds.). *Encyclopedia of Flaps*. 3rd ed. Lippincott Williams and Wilkins, Philadelphia.
- GRAY H (1918). *Anatomy of the Human Body*. Lea & Febiger, Philadelphia.
- GRUBER W (1875). Über die Varietäten des Musculus extensor hallucis longus. *Arch Anat Physiol Wissen Med*, 565-589.
- HILL RV, GERGES L (2008). Unusual accessory tendon connecting the hallucal extensors. *Anat Sci Int*, 83: 298-300.
- KANEFF A (1986a). Die Aufrichtung des Menschen und die morphologische Evolution der Musculi extensores digitorum pedis unter dem Gesichtspunkt der evolutionen Myologie. Teil I. *Gegenbaurs Morphol Jahrb*, 132: 375-419.

- KANEFF A (1986b). Die Aufrichtung des Menschen und die morphologische Evolution der Musculi extensores digitorum pedis unter dem Gesichtspunkt der evolutiven Myologie. Teil III. *Gegenbaurs Morphol Jahrb*, 132: 681-722.
- KANEFF A, ANDREEV D (1983). Über die organogenetische Entwicklung des M. extensor hallucis longus beim Menschen. *Anat Anz*, 154: 237-244.
- KANEFF A, STEPHANOFF A (1982). Vergleichend-anatomische Untersuchung des M. extensor hallucis longus beim Menschen. *Gegenbaurs Morphol Jahrb*, 128: 690-701.
- MACALISTER A (1875). Additional observations on muscular anomalies in human anatomy. *Trans R Ir Acad Sci*, 25: 1-130.
- MOORE KL, DALLEY AF (2006). Lower Limb. *Clinically Oriented Anatomy*. 5th ed. Lippincott Williams and Wilkins, Philadelphia.
- NEUMEISTER MW, WILHELMI BJ (2006). Flexor Tendon Repair. In: MCCARTHY JG, GALIANO RD, BOUTROS SG (eds). *Current Therapy in Plastic Surgery*. 1st ed. Saunders, Philadelphia.
- PARKHOUSE N, CUBISON TCS, HUMZAH MD (2006). Scar Revision. In: MATHES SJ, HENTZ VR (eds). *Plastic Surgery*. 2nd ed. Saunders, Philadelphia.
- PEDERSON WC, STEVANOVIC M, ZALAVRAS CL, SHERMAN R (2006). Reconstructive Surgery: Extensive Surgery to the Upper Limb. In: MATHES SJ (ed). *Plastic Surgery*. 2nd ed. Saunders, Philadelphia.
- PROSCHE H, FUHRMANN R, LINB W, FRÖBER R (2004). The post-operative stability of the first metatarsal. *Eur J Anat*, 8: 55-59.
- SARRAFIAN SK, TOPOUZIAN LK (1969). Anatomy and physiology of the extensor apparatus of the toes. *J Bone Joint Surg Am*, 51: 669-679.
- SCADUTO AA, CRACCHIOLO A (2000). Lacerations and ruptures of the flexor or extensor hallucis longus tendons. *Foot Ankle Clin*, 5: 725-736.
- SCHENK S, MEIZER R, KRAMER R, AIGNER N, LANDSIEDL F, STEINBOECK G (2009). Resection arthroplasty with and without capsular interposition for treatment of severe hallux rigidus. *Int Orthop*, 33: 145-150.
- SHUHAIBER JH, SHUHAIBER HH (2003). Plantaris tendon graft for atrioventricular valve repair: a novel hypothetical technique. *Tex Heart Inst J*, 30: 42-44.
- TANG JB (2009). Flexor tendons. In: CHUNG KC, DISA JJ, GOSAIN AK, KINNEY BM, RUBIN JP (eds). *Plastic Surgery: Indications and Practice*. 1st ed. Saunders, China.
- TATE R, PACHNIK RL (1976). The accessory tendon of extensor hallucis longus: its occurrence and function. *J Am Podiatry Assoc*, 66: 899-907.
- TERZIS JK, KYERE SA (2008). Minitendon graft transfer for suspension of the paralyzed lower eyelid: our experience. *Plast Reconstr Surg*, 121: 1206-1216.
- WEHBE MA (1994). Tendon graft anatomy and harvesting. *Orthop Rev*, 23: 253-256.
- WILLIAMSON DG, RICHARDS RS (2006). Flexor tendon injuries and reconstruction. In: MATHES SJ (ed). *Plastic Surgery*. Saunders, Philadelphia.