

Rare co-existence of variant left circumflex artery origin and tortuous right bronchial artery: a case report

Naheed Kausar

Anatomy Division, Biomedical Sciences Department, College of Medicine, King Faisal University, Al Ahsa, Saudi Arabia

SUMMARY

Anatomical variations in coronary and bronchial arteries can significantly impact clinical management and interventional procedures. A rare case of the separate origin of the left circumflex artery (LCX) from the left coronary sinus was reported, coexisting with a tortuous and hypertrophied right bronchial artery, identified on contrast-enhanced computed tomography (CT) angiography. The absence of the left main coronary artery, observed in this patient, occurs in approximately 0.4% of the population and is relevant for percutaneous coronary interventions, stent placement, and surgical grafting. Coronary artery tortuosity may further complicate catheterization and contribute to myocardial ischemia. The tortuous, hypertrophied bronchial artery increases the risk of haemoptysis and may complicate embolization. Although each anomaly is uncommon, their concurrent presence is exceptionally rare. This case highlights the importance of thorough pre-procedural imaging and careful anatomical evaluation to guide interventions, minimize procedural risks, and enhance patient management, while contributing to the understanding of rare vascular variations.

Key words: Coronary arteries – Left circumflex artery – Bronchial arteries – Arterial variation –

Computed Tomography – Angiography – Angina – Anatomical variation

INTRODUCTION

The complex vascular network of the human body, especially within the cardiovascular and pulmonary systems, is essential for normal physiological function. The left circumflex artery and the right bronchial artery are two distinct vessels crucial to their respective organ systems. The left circumflex artery typically originates as a principal branch of the left main coronary artery, which arises from the left aortic sinus, situated immediately superior to the aortic valve. This vessel is crucial for myocardial perfusion, supplying the lateral wall of the left ventricle and, in approximately 10% of individuals with left-dominant circulation, giving rise to the posterior descending artery (Veltri et al., 2010). The right bronchial artery, a component of the bronchial arterial system, generally originates from the superior portion of the descending thoracic aorta, often through an intercostobronchial trunk (Choi et al., 2021; Morita et al., 2010). This arterial system functions under high pressure, delivering oxygenated blood to the bronchial tree, pulmonary lymph nodes, major pulmonary vessels, oesophagus, and pleura (Ostrowski et al., 2024). While these origins and

Corresponding author:

Naheed Kausar. College of Medicine, King Faisal University, Anatomy Division, Biomedical Sciences Department, FHDF 3426, Prince Fawaz Street, Al Khalidiyah Dist., 31982 Al Hafuf, Al Ahsa, Saudi Arabia. E-mail: nmurtaza2015@gmail.com

Submitted: September 26, 2025. **Accepted:** November 3, 2025

<https://doi.org/10.52083/YBOX1035>

distributions represent the normal anatomical configurations, both the coronary and bronchial arterial systems are known for their considerable anatomical variations (Choi et al., 2021; Ostrowski et al., 2024; Ullah et al., 2017) including differences in the origin of the coronary arteries and morphological changes such as tortuosity in the bronchial arteries.

Significant variations in these critical arteries can substantially alter clinical presentation and treatment strategies. For example, the anomalous origin of the left circumflex coronary artery from the right sinus of Valsalva is a recognized congenital coronary anomaly (Çitaku et al., 2015; Dursunoğlu et al., 2007; Mohsen et al., 2013).

Although often regarded as a minor variation, this specific anomaly can complicate diagnostic procedures and interventional cardiology, particularly during percutaneous coronary interventions (Dursunoğlu et al., 2007; Mohsen et al., 2013). In severe presentations, anomalies of the coronary arteries can precipitate serious sequelae, including myocardial ischemia, ventricular arrhythmias, syncope, and potentially sudden cardiac death. This is particularly true when a coronary artery originates anomalously from the pulmonary artery, creating a “coronary steal” phenomenon that compromises myocardial perfusion (Elouali et al., 2021; Liu et al., 2022). In parallel, the tortuosity of the bronchial arteries, specifically the right bronchial artery, represents a notable morphological deviation. Bronchial artery tortuosity is frequently associated with substantial vascular proliferation and heightened blood flow within the bronchial circulatory system, often serving as an adaptive response in various pulmonary pathologies (Kang et al., 2024). This notable tortuosity can precipitate or worsen clinical manifestations like haemoptysis, especially when associated with underlying pulmonary inflammatory or infectious processes (Kathuria et al., 2020). This tortuosity can also present considerable technical challenges during interventional procedures such as bronchial artery embolization, necessitating meticulous pre-procedural planning supported by advanced imaging techniques (Copping et al., 2024; Fukamatsu et al., 2023).

The embryological origins of these vascular structures offer insight into their propensity for variation. Coronary arteries primarily develop from an epicardial vascular plexus that subsequently remodels to form the definitive arterial network connected to the aorta (Siekman, 2018; Thiene et al., 2021). Conversely, the bronchial arteries originate from the systemic circulation, with theoretical considerations suggesting their derivation from persistent segmental or pharyngeal arch arteries, implying a developmental linkage to the formation of the bronchial tree (Gao et al., 2021; Suchodolski et al., 2024). Anomalies of the coronary arteries exhibit worldwide prevalence, with reported incidences varying between 0.3% and 5.6% (Ullah et al., 2017), and fewer than 1% of the general population, with the anomalous origin of the circumflex coronary artery from the right sinus of Valsalva being noted in 0.18% to 0.67% of angiographic investigations (Bolívar-Mejía et al., 2020; Mohsen et al., 2013; Nesheiwat et al., 2020). Variations within the bronchial artery system, encompassing both tortuosity and aberrant origins, are prevalent worldwide and frequently associated with augmented blood flow, often as a compensatory mechanism in the context of chronic pulmonary pathologies (Ostrowski et al., 2024; Takizawa et al., 2021).

While specific prevalence data regarding the simultaneous occurrence of an anomalous left circumflex coronary artery origin and tortuosity of the right bronchial artery is not extensively documented in existing literature, case reports and related studies suggest a correlation between severe coronary artery anomalies and modifications in bronchial circulation. Examples include dilated bronchial arteries functioning as collateral pathways in intricate congenital heart conditions (Vizzuso et al., 2018). Moreover, generalized bronchial artery hypertrophy, which frequently precedes or accompanies tortuosity, has been observed in association with coronary artery disease (Tresoldi et al., 2013). Moreover, instances where anomalies of the coronary and bronchial arteries occur concurrently have been noted, exemplified by the connection of enlarged bronchial arteries with an aberrant origin of the left coronary artery from the pulmonary artery (ESCR Abstract,

2022', 2022; Vizzuso et al., 2018), and the rare occurrence of coronary-bronchial artery fistulas (Sun et al., 2024; Takahashi et al., 2023). The intricate relationship between typical anatomical structures and their variations, particularly when multiple anomalies manifest concurrently within a single patient, underscores the critical role of sophisticated imaging techniques in achieving precise diagnoses and implementing effective patient care strategies.

CASE REPORT

This case concerns a 51-year-old female patient, normoglycemic and normotensive, with no other personal history of interest. In the year 2022, the patient presented with a history of chronic cough and haemoptysis. Examination was performed, and she was diagnosed with bilateral multilobar with features of bronchiolitis on computed tomography (CT) scan chest. In the year 2024, the patient presented in the emergency room (ER) with severe chest pain radiating to the left arm, neck and the back.

High-sensitivity troponin (hs-cTn) test was performed immediately, and levels were found within normal range. A CT angiogram with contrast was performed and left coronary dominance observed. The CT coronary angiography revealed an anomalous coronary anatomy by chance, consisting of the existence of an aberrant origin of the left circumflex artery (LCX), directly from the aortic arch instead of originating from the left coronary artery, with an origin in the left anterior descending (LAD) artery and the absence of a left main coronary trunk. The right coronary artery (RCA) originated normally from the right coronary sinus. No instances of coronary artery disease with arterial blockages were detected. These findings are visually represented in Fig. 1.

In fact, the left coronary artery typically originates from a single orifice in the left aortic sinus, located immediately above the aortic valve. This initial segment is known as the left main trunk. The left main trunk usually bifurcates into two primary branches, LCX and LAD (Thiene et al., 2021). The left circumflex artery in this case was directly originating from the left aortic sinus with

a separate ostium (Fig. 1). This coronary artery anomaly, classified as a congenital variant of coronary origin, has been described as "extremely rare" (Hussain et al., 2014).

Further assessment of the systemic thoracic vasculature revealed a tortuous and hypertrophied right bronchial artery arising from the descending thoracic aorta. The artery displayed a convoluted path with significant bends as it approached the right pulmonary hilum, indicative of adaptive thickening. No aneurysmal alterations or pathological dilatations were discernible, apart from the observed hypertrophy. The contralateral bronchial branches appeared unremarkable (Fig. 2).

The coexistence of a separate LCX origin, tortuous RCA, and a tortuous hypertrophied right bronchial artery represented an uncommon and infrequent anatomical variant that is not typically detailed within the existing literature.

As of the current date, the patient achieved a complete response to therapy for bronchiectasis.

DISCUSSION

Anatomical variations in the coronary and bronchial arterial systems hold significant clinical implications for patient management, and can complicate surgical and interventional procedures.

Coronary Artery Variations

Coronary artery anomalies are reported in 0.3% to 5.6% of angiographic studies (Al-Sadawi et al., 2019). In this case, the left anterior descending (LAD) and left circumflex (LCX) arteries arise separately from the left coronary sinus, representing an absent left main coronary artery (Francois et al., 2020; Hussain et al., 2014), occurring in approximately 0.4% of the population (Hussain et al., 2014; Sidhu et al., 2019). This variant is clinically significant due to its impact on catheterization, stent placement, and surgical grafting strategies. Although an anomalous LCX origin from the right coronary cusp is considered a relatively common benign variant (0.18-0.67%) (Bhattad and Ramsaran, 2022; Mohsen et al., 2013), it may still complicate interventional procedures. With respect to classification methodologies, established systems

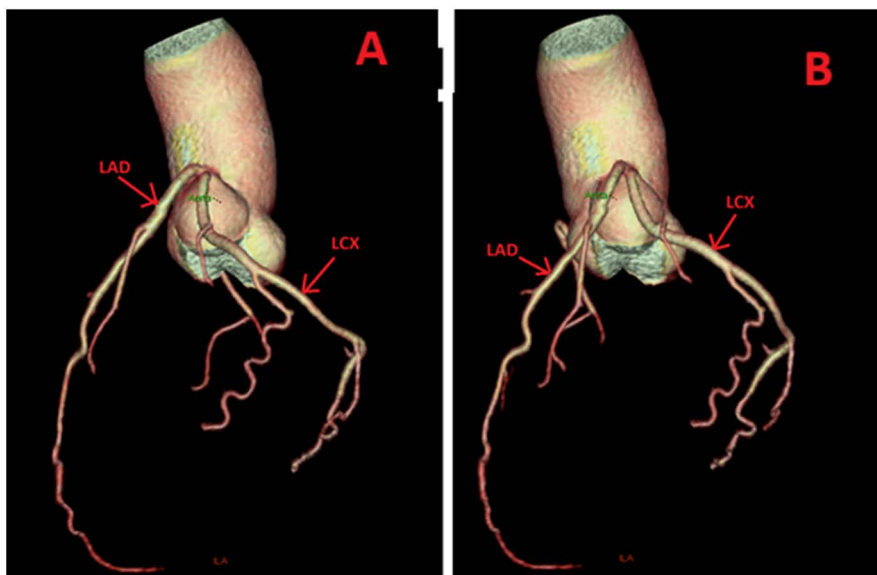


Fig. 1.- Three-dimensional CT coronary angiography (A and B different views) demonstrating variant of separate origin of the left anterior descending artery (LAD) and the left circumflex artery (LCX) directly from the left coronary sinus, with absence of a left main coronary trunk. The right coronary artery (RCA) arises normally from the right coronary sinus.

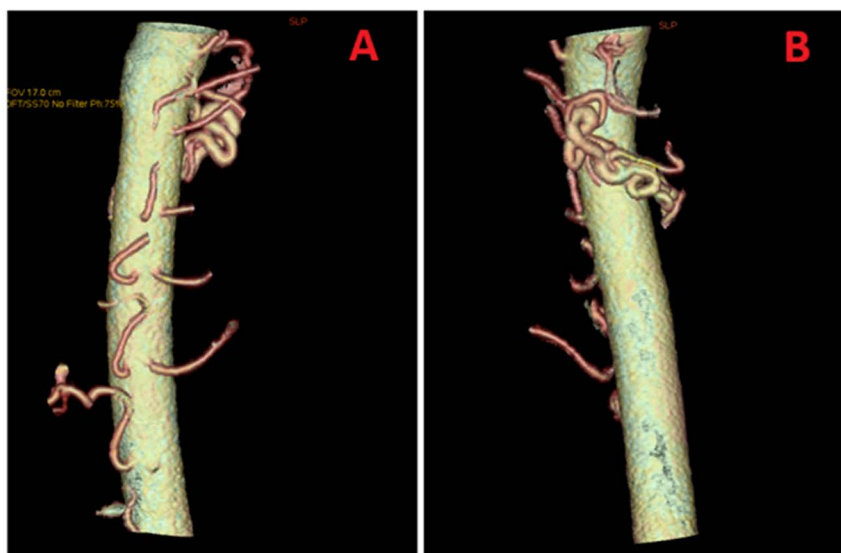


Fig. 2.- Three-dimensional CT angiography of the thoracic aorta, A. showing left and right bronchial arteries and B. demonstrating a tortuous and hypertrophied right bronchial artery, arising from the descending thoracic aorta, the artery shows multiple loops and exaggerated angulations along its path.

are available for categorizing individual coronary anomalies. For instance, the Lipton et al. classification framework delineates single coronary arteries based on their point of origin and anatomical trajectory (Kök et al., 2023). The distinct origin of the left anterior descending and left circumflex arteries from the left coronary sinus, as observed in this patient, constitutes a congenital absence of the left main coronary artery. While this specific arrangement might not perfectly align with every subtype within broad single coronary artery clas-

sifications, it is clearly recognized as a distinct and rare coronary anomaly within the literature (Francois et al., 2020; Hussain et al., 2014).

Bronchial Artery Variations

Tortuous and hypertrophied bronchial arteries often arise as an adaptive response to chronic pulmonary conditions, such as bronchiectasis or pulmonary vascular obstruction, and are reported in approximately 46 % of patients with bron-

chiectasis undergoing CT assessment (Almeida et al., 2020; Kang et al., 2024; Trisolini et al., 2011). Clinically, these vessels increase the risk of haemoptysis and complicate procedures such as bronchial artery embolization (Fukamatsu et al., 2023; Le et al., 2020). While there is no formal classification for bronchial artery tortuosity, abnormal vessels are typically defined by a diameter ≥ 2 mm or a tortuous course extending to the hilum, often accompanied by hypertrophy (Le et al., 2020; Yan et al., 2021).

Clinical Implications of Combined Anomalies

The coexistence of a separate LCX origin and a tortuous hypertrophied right bronchial artery is exceedingly rare. Previous studies have reported correlations between bronchial artery hypertrophy and coronary artery disease (Tresoldi et al., 2013), as well as coronary-bronchial artery fistulas (Nam and Choo, 2013; Sun et al., 2024; Takahashi et al., 2023). These combined anomalies pose important clinical challenges. The anomalous LCX may complicate vessel engagement during percutaneous coronary intervention (Bhattad and Ramsaran, 2022).

The tortuous hypertrophied bronchial artery increases the risk of haemoptysis and technical difficulty during embolization (Fukamatsu et al., 2023; Le et al., 2020). Unrecognized coronary-bronchial artery fistulas may lead to severe complications, such as acute myocardial infarction, if embolization inadvertently reaches the coronary circulation (Nam and Choo, 2013; Sun et al., 2024; Takahashi et al., 2023).

This case emphasizes the critical importance of thorough pre-procedural imaging and careful anatomical assessment to guide procedural planning, mitigate risks, and optimize patient management. Such meticulous assessment is crucial for averting iatrogenic complications and enhancing clinical results, especially during procedures affecting either the coronary or bronchial vasculature (Sun et al., 2024).

The concurrent presence of a separate LCX origin with a tortuous hypertrophied right bronchial artery is exceptionally rare, highlighting the value of reporting such unique anatomical variations.

CONCLUSION

In conclusion, this case report highlights the rare concurrent occurrence of an aberrant origin for the left circumflex artery and a tortuous right bronchial artery, emphasizing the imperative for thorough pre-procedural imaging in intricate cardiovascular and pulmonary scenarios. The careful anatomical evaluation is essential for planning interventions, minimizing procedural risks, and ensuring safe patient management. Reporting such unique vascular variations contributes to the broader understanding of anatomical diversity and its clinical implications.

ETHICAL CONSIDERATIONS

This case report has been prepared in accordance with the ethical principles of the Declaration of Helsinki, with authorization for its publication provided by the author as the subject of the report. As the author is the subject, Institutional Review Board approval was not required.

REFERENCES

- ALMEIDA JM, LEAL C, FIGUEIREDO L (2020) Evaluation of the bronchial arteries: normal findings, hypertrophy and embolization in patients with hemoptysis. *Insights Imaging*, 11(1): 70.
- AL-SADAWI M, IHSAN M, GARCIA AN, DOGAR M, CELENZA-SALVATORE J, MCFARLANE SI (2019) Congenital absence of left main coronary artery with anomalous origin of left anterior descending and left circumflex arteries presenting with acute non-ST elevation myocardial infarction. *Am J Med Case Rep*, 7(10): 264.
- BHATTAD PB, RAMSARAN E (2022) Anomalous origin of the left circumflex coronary artery: approach in acute coronary syndrome. *Cureus*, 14(9).
- BOLÍVAR-MEJÍA A, ABAD P, MARTÍNEZ C, RENDÓN JC, SANCHEZ JZ, SALDARRIAGA C (2020) Origen anómalo de la coronaria izquierda corregido con maniobra modificada de Lecompte. *Arch Cardiol Mex*, 91(3): 385-387.
- CHOI WS, KIM MU, KIM H, YOON CJ, LEE JH (2021) Variations of bronchial artery origin in 600 patients. *Medicine*, 100(22): e26001.
- ÇITAKU H, KAMBERI L, GORANI D, KOÇINAJ D, KRASNIQI X (2015) Anomalous origin of left circumflex artery. *Med Arch*, 69(6): 423.
- COPPING R, NG N, OSMAN S (2024) Selective embolisation of an idiopathic bronchial artery pseudoaneurysm presenting with recurrent laryngeal nerve palsy: a case report. *CVIR Endovasc*, 7(1): 62.
- DURSUNOĞLU D, ÖZALP G, TAŞKÖYLÜ Ö, SEMİZ E (2007) Anomalous origin of the left circumflex coronary artery: a case report. *Anadolu Kardiyol Derg*, 12(4): 207.
- ELLOUALI F, LENOIR M, GRAN C, ALLARY C, FOUILLOUX V, OVAERT C (2021) Early presentation of patients with abnormal origin of left coronary artery from the pulmonary artery is a predictor of poor mid-term outcomes. *Pediatr Cardiol*, 43(4): 719-727.
- EUROPEAN SOCIETY OF CARDIOVASCULAR RADIOLOGY OFFICE@escr.org ESCR ABSTRACTS (2022) Change in functional and anatomical imaging parameters. *Int J Cardiovasc Imaging*, 38(12): 2513-2579.
- FRANCOIS J, KARIYANNA PT, JAYARANGAAH A, MATTHEW T,

- MCFARLANE IM (2020) Absence of the left main artery with separate ostia of the left anterior descending artery and circumflex from the left sinus Valsalva: a case report. *Am J Med Case Rep*, 8(5): 134.
- FUKAMATSU F, YAMADA A, YAMADA K, NONAKA T, AONUMA T, TSUKAHARA Y, KAWAKAMI S, SASAKI H, FUJINAGA Y (2023) Serial assessment of computed tomography angiography for pulmonary and systemic arteries using a reduced contrast agent dose for the diagnosis of systemic artery-to-pulmonary artery shunts. *Jpn J Radiol*, 42(5): 460-467.
- GAO C, XU W, LI Z, CHEN L (2021) Analysis of bronchial and vascular patterns in left upper lobes to explore the genesis of mediastinal lingular artery and its influence on pulmonary anatomical variation. *J Cardiothorac Surg*, 16(1): 306.
- HUSSAIN N, REHMAN AU, CHEEMA FH (2014) Twin ostial openings in the left posterior aortic sinus: a pictorial overview of coronary revascularisation and aortic valve replacement in a patient with absent left main artery. *BMJ Case Rep*, 2014: bcr2014204043.
- KANG J, ZHANG W, WANG M, HUA P, WANG B (2024) Hemoptysis in a complex case: unravelling underlying factors. *Research Square*, 2024. DOI: 10.21203/rs.3.rs-5276718/v1.
- KATHURIA H, HOLLINGSWORTH HM, VILVENDHAN R, REARDON CC (2020) Management of life-threatening hemoptysis. *J Intensive Care*, 8(1): 23.
- KÖK Z, SÖKMEN E, BINGÖL B, KALAYN (2023) An extremely rare coronary anomaly: right single coronary artery or agenesis of left main coronary artery? A classification dilemma. *Research Square*, 2023. DOI: 10.21203/rs.3.rs-3727316/v1.
- LE H, LE VN, PHAM NH, PHUNG AT, NGUYEN T, ĐỒ Q (2020) Value of multidetector computed tomography angiography before bronchial artery embolization in hemoptysis management and early recurrence prediction: a prospective study. *BMC Pulm Med*, 20(1): 231.
- LIPTON MJ, BARRY WH, OBREZ I, SILVERMAN JF, WEXLER L (1979) Isolated single coronary artery: diagnosis, angiographic classification, and clinical significance. *Radiology*, 130(1): 39-47.
- LIU B, LALLA S, HOTH SS, MCALINDON E (2022) Multimodal imaging of an incidental anomalous coronary artery. *CJC Open*, 5(2): 161-163.
- MOHSEN G, MOHSIN KG, FORSBERG M, MILLER EJ, TANIUCHI M, KLEIN AJ (2013) Anomalous left circumflex artery from the right coronary cusp: a benign variant? *Cardiol Rev*, 25(6): 284-287.
- MORITA Y, TAKASE K, ICHIKAWA H, YAMADA T, SATO A, HIGANO S, TAKAHASHI S (2010) Bronchial artery anatomy: preoperative 3D simulation with multidetector CT. *Radiology*, 255(3): 934-943.
- NAM KJ, CHOO KS (2013) Left circumflex coronary artery fistula connected to the right bronchial artery associated with bronchiectasis: multidetector CT and coronary angiography findings. *J Korean Soc Radiol*, 68(4): 285-288.
- NESHEIWAT Z, EID J, SONI R, HARNISH P, SABBAGH E, ELTAHAWY E (2020) A single, shared origin for all three coronary arteries from the right coronary cusp: a case report. *J Med Case Rep*, 14(1): 94.
- OSTROWSKI P, BONCZAR M, GLĄDYS K, KLIMECZEK-CHRAPUSTA M, MUSIAŁ A, MATUSZYK A, BALAWENDER K, WALOCHA J, KOZIEJ M, CLARKE E, POLGUJ M, SMĘDRAA, ŻYTKOWSKIA, WYSIADECKI G (2024) The complex anatomy of the bronchial arteries: a meta-analysis with potential implications for thoracic surgery and hemoptysis treatment. *Sci Rep*, 14(1): 30942.
- SIDHU NS, WANDER GS, MONGA A, KAUR A (2019) Incidence, characteristics and atherosclerotic involvement of coronary artery anomalies in adult population undergoing catheter coronary angiography. *Cardiol Res*, 10(6): 358-368.
- SIEKMANN AF (2018) Coronary artery development, one cell at a time. *Nature*, 559(7714): 335-336.
- SUCHODOLSKI A, WIELGUS K, STROJEK M, SZULIK M, GŁOWACKI J (2024) Major aortopulmonary collateral arteries: clinical, echocardiographic, and radiologic characteristics. *Pol J Radiol*, 89: e302.
- SUN S, ZOU Q, CHANG P (2024) Bronchial artery embolization leading to acute myocardial infarction: a case report on bronchial artery-coronary artery fistula. *Research Square*, 24(1): 677.
- TAKAHASHI T, HOSOGI S, YAMANAKA T, TSUCHIKANE E (2023) Chronic total occlusion of the left circumflex coronary artery with collateral channels from the bronchial artery: a case report. *Eur Heart J Case Rep*, 7(10): yta484.
- TAKIZAWA H, MIYAMOTO N, SAKAMOTO S, TAKASHIMA M, MATSUMOTO D, KAWAKITA N, TOBA H, KAWAKAMI Y, YOSHIDA M, KONDO K, TANGOKU A (2021) Hypervascularized bronchial arteries as a risk factor for intraoperative bleeding and prolonged surgery. *J Thorac Dis*, 13(8): 4731.
- THIENE G, FRESCURA C, PADALINO MA, BASSO C, RIZZO S (2021) Coronary arteries: normal anatomy with historical notes and embryology of main stems. *Front Cardiovasc Med*, 8: 649855.
- TRESOLDI S, LEO GD, VILLA F, SQUARZA S, BENECCI IM, FLOR N, SARDANELLI F, CORNALBA G (2013) Bronchial artery hypertrophy is correlated with coronary artery disease. *Acta Radiol*, 55(3): 287-294.
- TRISOLINI R, BURZI M, PATELLI M (2011) Hypertrophied bronchial artery as a cause of bleeding after transbronchial needle aspiration. *Respiration*, 83(1): 81.
- ULLAH S, KHAN M, KHAN N, ZEB H, PATEL RM (2017) Absence of left circumflex artery: a rare congenital disorder of coronary arteries. *Case Rep Cardiol*, 2017(1): 8710135.
- VELTRI A, BUSO M, GARETTO I, SACCHETTO P, AVOGLIERO F, ARNÒ M (2010) Transperitoneal radiofrequency ablation of renal masses: a risky approach? In: CIRSE 2010 Main Programme and Abstract Book, pp 400-400.
- VIZZUSO A, RIGHI R, ZERBINI M, GAMANJI S, CUCCHI P, GALLO F, GIGANTI M, BENEÀ G, CARNEVALE A (2018) An unusual presentation of anomalous left coronary artery from the pulmonary artery (ALCAPA) syndrome in a 70-year-old man: a case report. *J Med Case Rep*, 12(1): 308.
- YAN H, LU G, HUANG X, ZHANG DZ, GE KY, ZHANG JX, LIU J, LIU S, SHI H, ZU Q (2021) Development of a model to predict recurrence after bronchial artery embolization for non-cancer related hemoptysis. *BMC Pulm Med*, 21(1): 419.