

# Occipitalization total of the atlas: Morphological characteristics and review of clinical implications in an adult male cranium

Marcos Pérez-Riffo<sup>1</sup>, Francisco J. Pérez-Rojas<sup>1</sup>, Marión Verdugo-González<sup>2</sup>

<sup>1</sup>Departamento de Ciencias Preclínicas, Facultad de Medicina, Universidad Católica del Maule, Talca, Chile

<sup>2</sup>Kinesióloga, Unidad de Paciente Crítico, Hospital Regional de Talca, Talca, Chile

## SUMMARY

Atlas occipitalization is a rare cranio-vertebral anomaly where the atlas fuses with the occipital bone. This study analyzes a detailed case of this condition in the cranium of an adult male from the cranial collection of the Anatomy Department at Universidad Católica del Maule in Talca, Chile. The complete fusion observed, also known as occipitocervical synostosis or atlantooccipital assimilation, involved the upper articular facets of C1 fusing with the occipital condyles. A severe arthritic deformation was noted in the lower right articular facet, measuring 32.5 mm, in contrast to the 17.45 mm left facet. The transverse processes were intact but deteriorated due to taphonomic effects. Asymmetry in the lower articular facets and a leftward deviation of the external occipital crest suggested significant disruption in atlantoaxial joint dynamics. Additionally, the reduced circumference of the occipital foramen indicated potential neural compression.

This study contributes to the fields of morphological sciences and clinical anatomy by providing a thorough description of this rare anomaly.

The unique case, with its detailed anatomical and morphometric data, offers valuable insights for future research and surgical planning. Furthermore, the embryological and biomechanical analysis enhances understanding of the clinical implications, emphasizing the importance of early diagnosis and management of this condition in both academic and clinical settings.

**Key words:** Occipital bone – Atlas – Craniovertebral junction – Atlantooccipital joint – Congenital abnormalities

## INTRODUCTION

The human craniocervical junction is an anatomically variable region, defined as extending from the occiput (basioccipital) to the C2-C3 discal space, where due to complex phylogenetic and ontogenetic processes, there can be a wide range of morphological variations. It develops as a highly specialized spinal column segment, which offers great dynamism to the cephalic segment in order to allow for visual, olfactory, and auditory

---

### Corresponding author:

Francisco Javier Pérez Rojas. Campus San Miguel, Av. San Miguel 3605, Talca. Phone: +56968784359. E-mail: fjperez@ucm.cl

---

Submitted: October 11, 2024. Accepted: October 23, 2024

<https://doi.org/10.52083/YCBF7960>

follow-up, oral prehension, and holding up the weight of the head (Raybaud, 2011). Congenital bone anomalies in this region can lead to a greater risk of segmentary instability and spinal cord invasion, which in turn can have neurological implications (Lalit et al., 2017). The most commonly reported anomalies in this region include the

Arnold-Chiari malformation, platybasia (flattened cranial base), basilar invagination, atlas occipitalization, dysmorphic atlas or dens, *os odontoideum*, vertebral intersegmental fusion, spinal canal stenosis, and segmentary instability for the atlantooccipital and atlantoaxial joints (Kayhan et al., 2015).

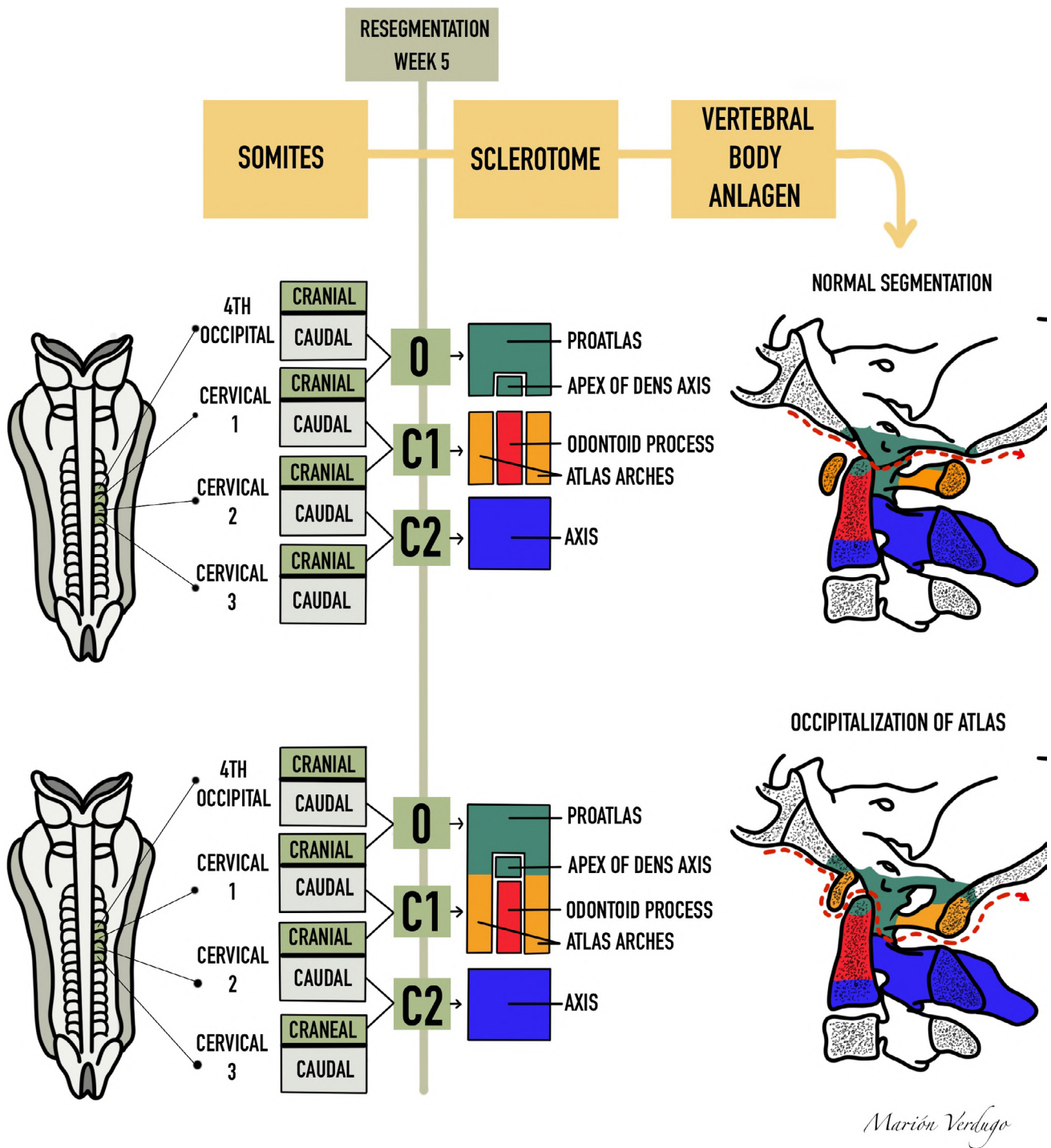


Fig. 1.- Formation of the craniocervical junction and its primordial sclerotomal state made up of the proatlas, C1 and C2. Those derived from the proatlas (green) are the basioccipital, exoccipital, and the apical segment of the odontoid process from the axis. The resegmented sclerotome C1 gives rise to the odontoid process (red) and the lateral zones corresponding to the posterior arch of the atlas (yellow). Sclerotome C2 (blue) will give rise to the vertebral body of the axis.

Atlas occipitalization is an anomaly where the atlas (C1) fuses with the occipital bone, altering the biomechanics and anatomy of the cranio-vertebral joint. This condition, with a prevalence in both sexes of between 0.08% and 2.8%, can manifest either symptomatically or asymptotically (Kahouadji et al., 2013). Beginning with Realdo Colombo, who made the first description of atlas occipitalization in 1579 (Bašić et al., 2014), various authors including Ackerman (1790), Meckel (1815), and especially Rokitansky in 1844 have published cases of partial or total atlas occipitalization (Erbengi and Öge, 1994). The first radiological demonstration was done by Schuller in 1911 (Al-Motabagani and Surendra, 2006). This anomaly varies from complete bone fusion to the presence of an osseous crest or a fibrous band joining limited areas of the atlas and occiput (Al-Motabagani and Surendra, 2006). Four types of occipito-cervical synostosis have been classified according to the atlas zones fused with the occiput: Zone 1, with fusion of the atlas anterior arch; Zone 2, with fusion mainly involving the lateral masses of the atlas; Zone 3, with fusion involving the atlas posterior arch; and Zone 4, with combinations of all zones (Mudaliar et al., 2013). In most cases, fusion is observed between the atlas anterior arch (Zone 1) and the anterior margin of the occipital foramen (Kayhan et al., 2015). Prior studies have documented that this condition can be both congenital and acquired, although it is more commonly congenital and associated with conditions including Klippel-Feil syndrome (Gholve et al., 2007). Acquired cranio-cervical fusion can occur with ankylosing spondylitis and rheumatoid arthritis (Burwood and Watt, 1974). Symptomatic atlas occipitalization may have significant clinical implications, being associated with neck pain, limited movement, abnormal head posture (bone torticollis) and in severe cases, neurological issues due to compression of adjacent neural structures, leading to muscle weakness, ataxia, and muscular atrophy (Sharma et al., 2017).

The development of the cranio-vertebral region, in particular the formation of the craniocervical junction, is a complex process influenced by differentiation, segmentation, and fusion of occipitocervical somites (Chandraraj and Briggs, 1992).

During the fourth and fifth weeks of intra-uterine life, the paraxial mesodermal tissue around the notochord is differentiated into somites, which are divided into occipital, cervical, thoracic, lumbar, sacral, and coccygeal somites. These then give rise to sclerotomes, which form the vertebral bodies (Muthukumar, 2016).

The cervico-occipital joint develops between the fourth occipital somite and the first cervical somite, producing the transition sclerotome called the pro-atlas, which in humans is assimilated into the occipital. This process also gives rise to various occipital structures and the first cervical vertebrae (Pang and Thompson, 2011) (Fig. 1).

Atlas occipitalization could be explained by a failure in the segmentation of the fused sclerotomes in the fourth occipital somite and the first cervical somite, causing a lack of separation in these areas during the embryonic period (Müller and O'Rahilly, 2003).

The objective of this study is to present a detailed case of atlas occipitalization in an adult male cranium, describing its embryological development, the specific morphological characteristics observed, and comparing these findings with similar cases in the scientific literature to deepen comprehension of the clinical and biomechanical implications associated with this bone anomaly in the cranio-vertebral junction.

## MATERIALS AND METHODS

This descriptive case study centered on analyzing an adult male human cranium which presented atlas occipitalization, from the skull collection in the Anatomy Department at Universidad Católica del Maule, Talca, Chile. The specimen was chosen for its previously observed atlantooccipital fusion characteristics, with visual inspections done alongside physical measurements using a digital calibrator to detail the bone structures' dimensions. Teleradiography was carried out along with photographs from various angles to obtain detailed images of the cranio-vertebral junction, allowing for an exhaustive evaluation of the structural integrity and the extent of the fusion. The basal Welcher angle was recorded, formed by the intersection of the sphenoid and clivus planes, to

determine the presence of platybasia. All the gathered data were analyzed and compared with extant literature to discuss the variations associated with this condition. All procedures fulfilled the ethical rules for research with human specimens, ensuring respect for the institutional ethical directives from Universidad Católica del Maule.

## RESULTS

An adult male cranium with atlas occipitalization was found in the collection of the anatomy department at Universidad Católica del Maule, in Talca, Chile. Out of a total of 127 adult skulls, only one presented total atlas occipitalization, comprising 0.79% of the total set. Upon observing the anatomical characteristics of the atlas, we can note that it presents an asymmetrical fusion with the occiput, and its median axis is shifted leftwards by 7 mm, according to the median occiput axis determined by the basion-opisthion line.

The anterior arch of C1 is entirely joined to the anterior margin of the occipital foramen, with a discrete dehiscence of 4.2 mm x 7.2 mm located

at the level of the anterior tuber and the upper part of the left arch (Fig. 2). The anterior tuber is clearly visible, thanks to which we can determine that the atlas presents a rotation of  $11.05^\circ$  towards the left (figure 4B). The facet joint for the odontoid axis process has an oval outline, and is 7.31 mm wide and 7.63 mm high.

The lateral masses for C1 are totally fused to the occipital condyles (Fig. 3). The left lateral mass presents erosion due to taphonomic effects, with a lower articular surface that is flat, smooth, and ovoid, with an antero-medial orientation and a length of 17 mm. Its latero-medial diameter could not be measured due to erosion. The right lateral mass has a lower facet joint which is irregularly circular and severely deformed by an advanced osteoarthritic process, notably increased in all its dimensions, with an antero-posterior diameter of 32 mm and a width of 29.5 mm, presenting notable lateral lipping. There are also various pores, both coalescent and punctual, of an erosive nature in the subchondral bone, accompanied by some areas with eburnation. Bone prominences appear

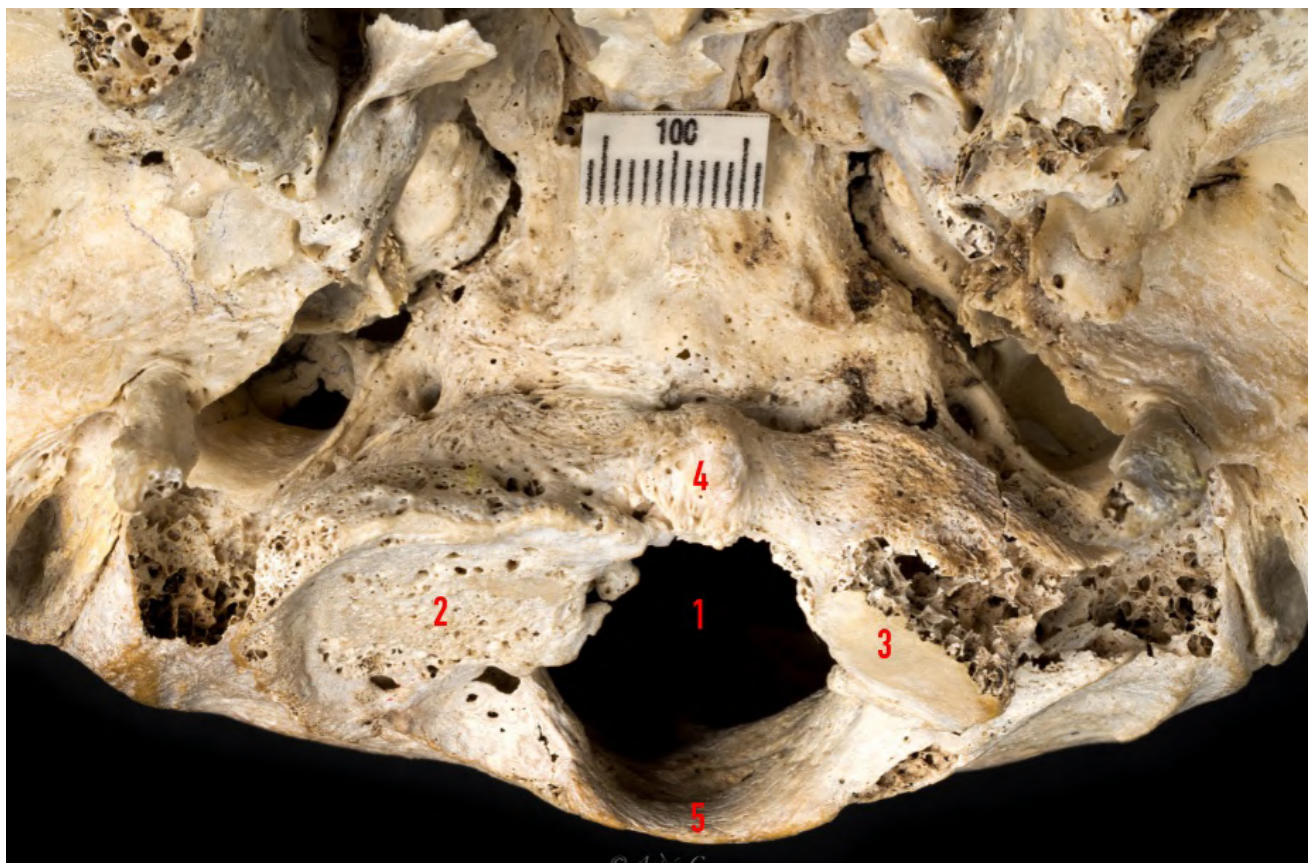

Fig. 2.- Image shows a cranium with total atlas occipitalization, seen from an anteroinferior exocranial perspective. (1: Foramen magnum, 2: Lower right articular surface of the atlas, 3: Lower left articular surface of the atlas, 4: Anterior tuber, 5: Posterior arch of the atlas).

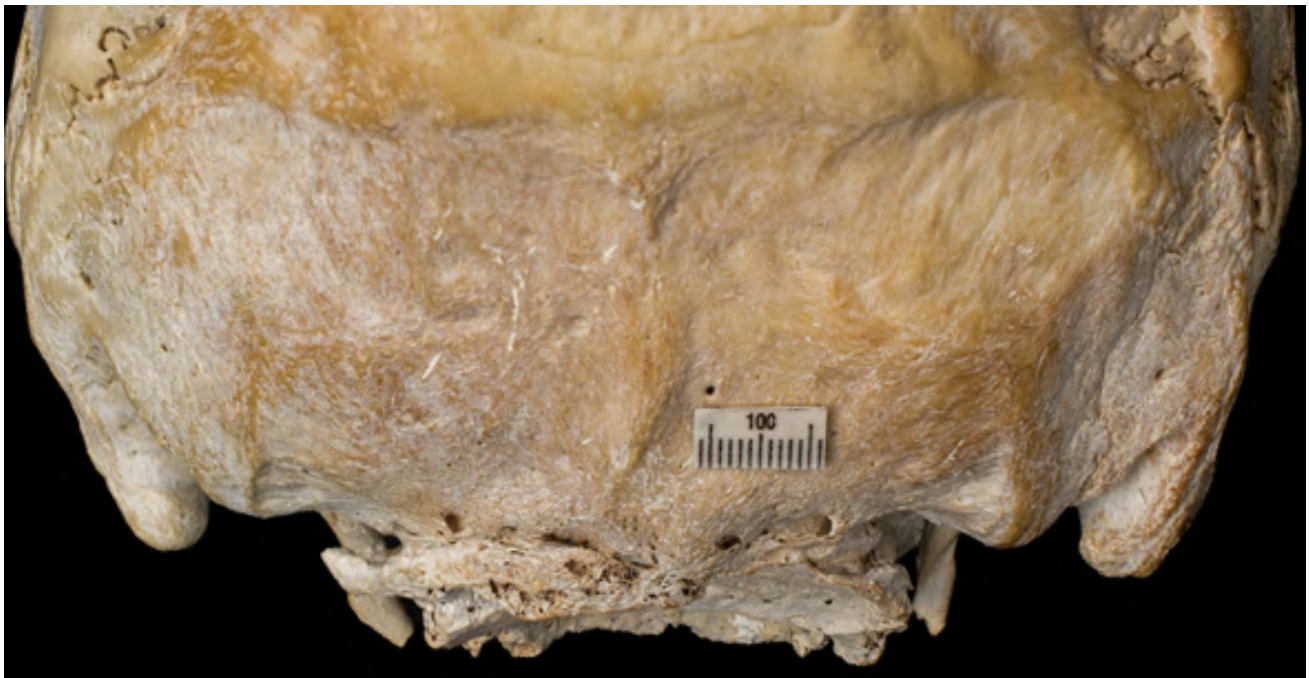

Fig. 3.- Posterior vision of total atlantooccipital fusion. Note the foramens for posterior cervical nerves to pass through.

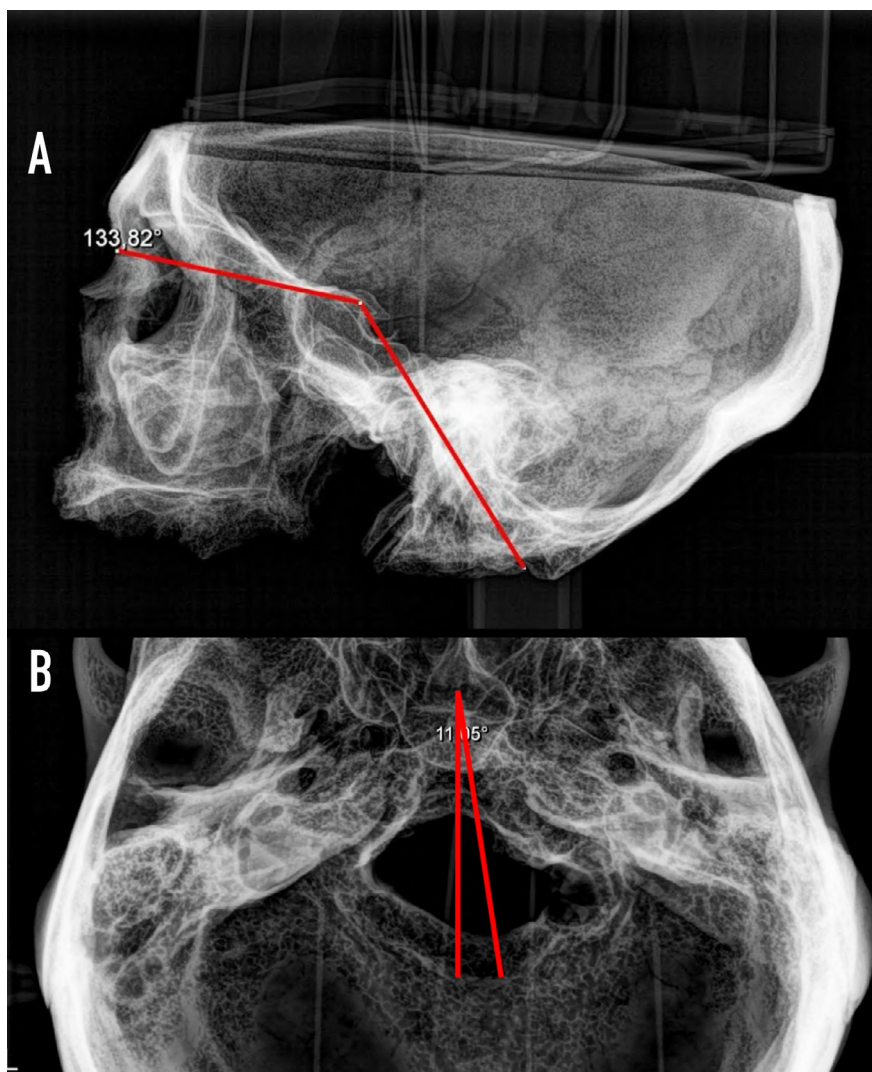


Fig. 4.- A. Lateral tele-radiography presenting the Washed B angle. B. Upper view tele-radiography presenting an atlas rotation of 11.05° towards the left.

in the lateral masses' medial faces along its more posterior extremes, with the most notable being the right side for the insertion of the transverse ligament. Both project into the occipital foramen, decreasing its cross-sectional diameter.

The posterior arch is totally fused into the posterior margin of the occipital foramen, with some small foramina appearing where dorsal branches pass for C1. No posterior tuber is observed (Fig. 3). The external face of the left posterior arch is strongly eroded. In the immediate dorsal area from both lower facet joints, we can find the depressions corresponding to the path for the C2 cervical branch, with the right being more accentuated. Within the left transverse process, there are fractures on both the anterior and posterior roots delimiting the cross-sectional foramen, along with strong erosion. The right side presents a certain amount of root to the anterior of the cross-sectional foramen, with all the remainder being destroyed. It should be noted that a bone foramen is visualized in both sides, created by the occipital-C1 fusion, through which the vertebral artery enters the endocranium, which, according to the Wang's classification, corresponds to a type III part of the vertebral artery (Li et al., 2019).

The occipital foramen presents as irregularly circular, with a morphology very similar to the C1 vertebral foramen and deviated towards the left. Its anterior conoid portion has a cross-sectional diameter of 15.56 mm; its posterior ovoid portion has a diameter of 27.82 mm; and its largest anteroposterior diameter is 34.84 mm.

Greater development was observed in the right mastoid process, with a very marked mastoid incision, as well as upper and lower nuchal lines on the same side, indicating greater sternocleidomastoid muscle activity, together with the right cervical musculature, implying right bone torticollis.

The endocranium presents destroyed posterior clinoid processes, probably due to taphonomic effects. The clivus has a Washed angle of  $133.82^\circ$  (Boogard basal angle) ruling out the presence of platybasia (Fig. 4A). The right internal petro-occipital fissure in its most proximal section, lateral to the clivus, has begun the synostosis process. A

large right jugular tuber is visible, beneath which there is a vascular channel where the vertebral artery runs towards the center of the clivus, of 30.5 mm. In the left side, the left jugular tuber is of moderate size and the underlying vascular canal has a length of 26.7 mm. We can observe the presence of a vermian fossa, whose height, measured from the opisthion to the bifurcation point of the internal occipital crest, is 35.7 mm., with a base of 43.5 mm. As with the occipital foramen, this fossa shows a strong asymmetry towards the left. It is also interesting to indicate that the right cerebellar fossa has a concave morphology, which is clearly more marked than its homologue on the left side.

## DISCUSSION

During embryonic development, atlas occipitalization arises from an alteration in the segmentation and fusion of occipitocervical somites. Occipital and cervical somites normally form structures which become occipital bones and cervical vertebrae. However, in the case of occipitalization, there is a failure during separation of the sclerotomes for the fourth occipital somite and the first cervical somite, leading to fusion between the atlas (C1) and the occipital bone (Müller and O'Rahilly, 2003; Chandraraj and Briggs, 1992). This defective process happens during the fourth and fifth weeks of intra-uterine life, altering normal morphogenesis for the cranio-cervical junction (Pang and Thompson, 2011). This malformation can also lead to major biomechanical problems, affecting head and neck mobility, and in some cases compressing neural structures, which can lead to neurological symptoms (Sharma et al., 2017; Gholve et al., 2007). Variability in the manifestation of this anomaly suggests that the severity of the fusion depends on how much the sclerotomes' early segmentation is affected, given rise to cases ranging from partial to total fusions, as described in this study (Bašić et al., 2014; Al-Motabagani and Surendra, 2006).

This study is particularly relevant because it describes a case of complete atlantooccipital fusion, which is infrequent in the literature, and provides a basis for future morphometric and clinical research in this area. The finding of severe arthritic

deformations on the lower right joint face suggests a biomechanical overloading derived from occipitalization, presenting the hypothesis that these deformations could be a late manifestation of long-term structural adaptation. The reduced circumference of the occipital foramen observed in this case could have significant clinical implications regarding neural compression, which not only reinforces the importance of early diagnosis, but also offers a window of opportunity for more effective clinical intervention in similar cases.

This case also contributes to understanding the morphological variations of atlantooccipital fusion, which is crucial for planning surgical interventions in the craniovertebral region. The observations from this cranium offer morphometric details which are not only useful for the academic environment, but can also be applied in the diagnosis and clinical management of patients with neurological symptoms related with compression of vascular or neural structures.

Atlas occipitalization can have severe clinical implications, ranging from asymptomatic to severe neurological symptoms due to neural structure compression. This particular case showed complete fusion, representative of the variations observed in prior studies and allowing for a deeper discussion about the biomechanical and clinical implications of this condition.

### **Biomechanical Implications**

Atlas occipitalization alters normal biomechanics in the cervical spine. Gholve et al. (2007) highlighted how these alterations can lead to increased mechanical load on adjacent segments, possibly accelerating joint wear and increasing predispositions to arthritis and other cervical pathologies. This phenomenon could explain the arthritic deformations observed in our case, where the lower right joint facet presented significant wear compared with the left.

The C1 vertebra occupies the most essential position for interacting with the cranium above and the C2 vertebra caudally, constituting the atlantooccipital and atlantoaxial joints. It thus aids in the complex biomechanical movements of the skull and neck along with transmitting the weight

of the skull towards the spine. It also clears the way for the spinomedullary junction through the vertebral foramen, the vertebral artery, and the first cervical nerve on the upper surface of the posterior arch, making it more vulnerable.

It should be noted that many authors stress that synostosis between the atlas and condyles displaces the force from the mobile occipital-C1 joint towards the C1-C2 joints (Li et al., 2019). This increases segment tension and leads to continual stretching of the C1-C2 vertebrae, leading to progressive weakening of ligament resistance, progressive atlantoaxial subluxation, and finally atlantoaxial luxation (DAA).

Cranio-vertebral joints are designed to offer a wide range of movement for the head and transmit the weight of the head towards the rest of the spinal column. These movements include flexing, extension, bilateral flexion and rotation, distraction, and axial loads. However, proper biomechanics for these joints can be altered by pathological ossification, which can occur between occipital condyles and the upper articular facets of the atlas. Atlas occipitalization suppresses movement between the occiput and the atlas. During maximum flexing, maximal tension is exerted on the occipito-odontoid ligaments. Any attempt at lateral or rotational flexing exerts abnormal tension upon these ligaments, leading to overstretching that can cause hypermobility for the atlas along the axis with the possibility of atlantoaxial subluxation or hypermobility of the atlantooccipital joint.

The lower joint facets for the atlas are normally circular, flat, or slightly convex, aimed downwards and medially, articulating with the axis.

The occipitocervical union, which includes the occiput, atlas, and axis, represents a unique and complex interface between the cranium and cervical spine. Over 50% of the rotation and flexion-extension of the head and neck take place in this region. Atypical ossification within the joint complex between the cranium and spinal column can notably decrease or even suppress movements in this region.

The typical configuration of joint facets in the atlantoaxial joint provides bio-elastic and hydro-

dynamic lubrication for the joint, as with other joints. In occipitalization, the remodeling of the atlas and orientation of upper joint facets of the axis can alter head movements. The fusion between the atlas and the occipital bone influences the distribution pattern of the force exerted by the head on the spinal column. In this case, the force is directly transferred via the lateral atlas masses towards the upper facets of the axis. This is reflected in the disposition and distribution of the bone trabecula within the vertebrae. The functional adaptation of the first and second cervical vertebrae caused changes in the inclination of the lateral joint facet and altered these facets' geometric form.

The end of movement between the occipital bone and the atlas in the case of occipitalization thus probably influences the thickness and density of the bone found below the joint cartilage, and the lack of synovial articulation between the occipital bone and atlas could not efficiently absorb the energy generated by head movement. The potential weight of the head is directly transmitted to the atlantoaxial joint, and is not suppressed by the cartilage which normally exists within the atlantooccipital joint. Consequently, the abnormal articulation between the skull and spine caused by occipitalization could generate excessive movement in the atlantoaxial joint and increase the tension placed on ligaments, leading to subluxation or dislocation of the entire atlantooccipital complex. An abnormal biomechanical condition caused by a solid union between the atlas and occipital could also lead to gradual weakening of the atlantoaxial joint with progressive atlantoaxial subluxation. According to Wortzman and Dewar (2018), the space for facet joints in both sides can appear asymmetrical in the case of atloaxoid subluxation. The most notable clinical symptom of atloaxoid subluxation is torticollis with the head being tilted to one side, rotation towards the contralateral side, and light flexion, which could be what happened in this case.

### **Clinical Correlations**

Atlas occipitalization can manifest with a broad spectrum of neurological symptoms due to spinal cord compression and the adjacent vascular

structures. Kahouadji et al. (2013) discussed how radiological detection of this anomaly can reveal the need to evaluate atlantoaxial stability to prevent complications during surgeries. This aspect is crucial for pre-operational patient management, ensuring that no adverse events happen due to inadvertently manipulating a compromised cervical spine. Anomalies related with the atlas and the occipital region are clinically significant, due to the presence of the first cervical nerve and the vertebral artery in the upper face of the atlas vertebra. Vertebral artery compression can compromise blood flow to the brain, and nerve compression can produce neurological symptoms (Mudaliar et al., 2013). Many authors have reported neurovascular complications arising due to atlantooccipital fusion. Anatomically, the fusion can compress the vertebral artery, the first cervical nerve, and the posterior atlantooccipital membrane, all of which are related with the posterior arch of the atlas. Atlantooccipital fusion can affect postural muscles, leading to head extension and abnormal posture. Fusion can compress the spinal cord and lead to neurological complications because of occipitocervical synostosis. In the neurological exam, the patient can reveal clinical findings including: neck pain, numbing, pain in their extremities, weakness, abnormal head posture, and dull headache localized in the posterior area.

### **Prevalence and Manifestations**

Studies including Khamanarong et al. (2013) and Skrzat et al. (2010) provide a context for the prevalence and anatomical manifestations of atlas occipitalization, indicating that, although it is a rare condition, its recognition is vital due to its possible neurological complications. Understanding the variations in how this anomaly manifests helps anticipate and better manage any possible clinical consequences.

### **Considerations for Clinical Practice**

Wang et al. (2019) emphasized the importance of understanding the morphometric dimensions of the occipitalized C1 for safe surgeries, particularly when placing screws. The lack of familiarity with altered anatomy can increase the risk of

complications during operations, which means that detailed measurements and deep knowledge of anatomical morphology are fundamental for surgical planning in patients with this anomaly. Standard routine X-rays may be insufficient for clear diagnosis, with a tomography commonly being needed to confirm the presence and extent of occipitocervical fusion (Al-Motabagani and Surendra, 2006).

### Evolution of Knowledge and Future Directions

Finally, the studies by Xu et al. (2017) and Yan et al. (2023) illustrate how continual research is essential to deepen understanding of atlas occipitalization. These consider not only direct complications, but also the specific radiological characteristics which can help with diagnosis and management. The development of new classification systems based on CAT scan images can significantly improve the ability to forecast and treat atlantoaxial dislocations in the context of atlas occipitalization.

### CONCLUSION

This case reinforces the need for careful diagnosis and individualized management of atlas occipitalization, highlighting the importance of a multidisciplinary focus when treating this condition. Collaboration between radiologists, neurosurgeons, and orthopedists is crucial for optimizing clinical results and improving quality of life for patients affected by this complex congenital anomaly.

### REFERENCES

- AL-MOTABAGANI MA, SURENDRA M (2006) Total occipitalization of the atlas. *Anat Sci Int*, 81: 173-180.
- BAŠIĆ Z, ANTERIĆ I, ŠKORIĆ E, VILOVIĆ K, ANĐELINOVIĆ Š (2014) Occipitalization of the atlas in archaeological material from the 16<sup>th</sup>-19<sup>th</sup> Century. *Int J Osteoarchaeol*, 24(4): 540-542.
- BURWOOD RJ, WATT I (1974) Assimilation of the atlas and basilar impression: a review of 1,500 skull and cervical spine radiographs. *Clin Radiol*, 25(3): 327-333.
- CHANDRARAJ S, BRIGGS CA (1992) Failure of somite differentiation at the cranio-vertebral region as a cause of occipitalization of the atlas. *Spine*, 17(10): 1249-1251.
- ERBENGLI A, ÖGE HK (1994) Congenital malformations of the craniovertebral junction: classification and surgical treatment. *Acta Neurochirurgica*, 127: 180-185.
- GHOLVE PA, HOSALKAR HS, RICCHETTI ET, POLLOCK AN, DORMANS JP, DRUMMOND DS (2007) Occipitalization of the atlas in children: morphologic classification, associations, and clinical relevance. *J Bone Joint Surg Am*, 89(3): 571-578.
- KAHOUADJI E, LUCAS O, KHONSARI RH, LONGIS J, HAMEL O, CORRE P (2013) Occipitalisation de l'atlas. Diagnostic radiologique et implication clinique. *Rev Stomatol Chir Maxillofac Chir Orale*, 114(3): 187-191.
- KAYHAN B, ÇORUK P, ERTURK M, SENGUL G (2015) Occipitocervical synostosis: case report. *Anatomy*, 9(2): 104-107.
- KHAMANARONG K, WORAPUTTAPORN W, RATANASUWAN S, NAMKING M, CHAIJAROONKHANARAK W, SAE-JUNG S (2013) Occipitalization of the atlas: its incidence and clinical implications. *Acta Medica Acad*, 42(1): 41-45.
- LALIT M, PIPLANI S, MAHAJAN A, KULLAR JS (2017) Occipitalization of atlas: a case report with its ontogenic basis and review of literature. *Curr Trends Diagn Treat*, 1(1): 34-37.
- LI T, YIN YH, QIAO GY, WANG HW, YU XG (2019) Three-dimensional evaluation and classification of the anatomy variations of vertebral artery at the craniovertebral junction in 120 patients of basilar invagination and atlas occipitalization. *Operative Neurosurg*, 17(6): 594-602.
- MUDALIAR RP, SHETTY S, NANJUNDAIAH K, JYOTHI KC (2013) An osteological study of occipitocervical synostosis: its embryological and clinical significance. *J Clin Diagn Res*, 7(9): 1835.
- MÜLLER F, O'RAHILLY R (2003) Segmentation in staged human embryos: the occipitocervical region revisited. *J Anat*, 203(3): 297-315.
- MUTHUKUMAR N (2016) Proatlas segmentation anomalies: surgical management of five cases and review of the literature. *J Pediatr Neurosci*, 11(1): 14-19.
- PANG D, THOMPSON DN (2011) Embryology and bony malformations of the craniovertebral junction. *Child's Nervous System*, 27: 523-564.
- RAYBAUD C (2011) Anatomy and development of the craniovertebral junction. *Neurological Sci*, 32 Suppl 3: S267-S270.
- SHARMA DK, SHARMA D, SHARMA V (2017) Atlantooccipital fusion: prevalence and its developmental and clinical correlation. *J Clin Diagn Res*, 11(6): AC01.
- SKRZAT J, MRÓZ I, JAWOREK JK, WALOCHA J (2010) A case of occipitalization in the human skull. *Folia Morphologica*, 69(3): 134-137.
- WANG HW, LI XP, YIN YH, LI T, YU XG (2019) Change of anatomical location of the internal carotid artery relative to the atlas with congenital occipitalization and the relevant clinical implications. *World Neurosurg*, 130: e505-e512.
- WORTZMAN G, DEWAR FP (1968) Rotary fixation of the atlantoaxial joint: rotational atlantoaxial subluxation. *Radiology*, 90(3): 479-487.
- XU JX, WANG CG, ZHOU CW, TANG Q, LI JW, XU HZ, MAO FM, TIAN NF (2017) Cervical myelopathy caused by invaginated laminae of the axis associated with occipitalization of the atlas: Case report and literature review. *Medicine*, 96(51): e9156.
- YAN J, QIU C, FU L, LIU X, ZHENG Y (2023) radiologic features of atlas occipitalization and its clinical implications. *Spine*, 48(13): 962-968.