

# Unilateral optic nerve aplasia associated with microphthalmia: a rare cadaveric report

Arthur T. Manjatika<sup>1,2</sup>, Joshua G. Davimes<sup>1</sup>, Erin F. Hutchinson<sup>1</sup>, Amadi O. Ihunwo<sup>1</sup>

<sup>1</sup>*School of Anatomical Sciences, University of the Witwatersrand, Parktown, Johannesburg, South Africa*

<sup>2</sup>*School of Life Sciences and Allied Health Professions, Anatomy Division, Kamuzu University of Health Sciences, Blantyre, Malawi*

## SUMMARY

This case report describes the anatomical presentation of the anomalous optic nerve (cranial nerve II). Cranial nerve II developmental anomalies encompass both optic nerve hypoplasia and aplasia. While most studies on optic nerve anomalies rely on radiological imaging, anatomical presentation and nerve course are rarely described. The current case reveals a complete absence of the right optic nerve and its connection to the optic chiasma, resembling radiological presentation of optic nerve aplasia. In addition, the right-sided bony orbit and eyeball were smaller than the left, accompanied by a poorly developed cornea and iris with a calcified mass, resembling clinical presentation of microphthalmia. Having a thorough understanding of the gross anatomical presentation and course of optic nerve anomalies can facilitate precise diagnosis and management of visual impairments associated with these anomalies. Furthermore, such knowledge can provide valuable insights into the actual prevalence of optic nerve aplasia and further substantiate the literature.

**Key words:** Optic nerve aplasia – Microphthalmia – Cadaver – Anomaly

## INTRODUCTION

Anomalies of the optic nerve are a significant cause of visual impairments (Taylor, 2007), and include optic nerve hypoplasia and aplasia (Margo et al., 1992). Optic nerve hypoplasia is common and presents with a smaller number of optic nerve fibres (Martín-Begué and Saint-Gerons, 2016). In contrast, optic nerve aplasia is a rare complete absence of optic nerve fibres, either unilaterally or bilaterally (Margo et al., 1992; Martín-Begué and Saint-Gerons, 2016; Taylor, 2007). Developmentally, the eye forms from the neural ectoderm, mesoderm and neural crest cells. The derivative of the neural ectoderm includes the optic nerve, retina and iris smooth muscles. The neural crest cells contribute to the formation of the stroma of the iris, ciliary muscles, choroid and vitreous part, and the endothelium and stroma of the cornea, while the mesoderm is interposed between the ectodermal tissues forming the cornea, choroid and vitreous substances, and sclera (Ohuchi et al., 2016; Taylor, 2007).

---

### Corresponding author:

Joshua Gabriel Davimes. School of Anatomical Sciences, Faculty of Health Sciences, University of the Witwatersrand, 7 York Road, Parktown, 2193, Johannesburg, South Africa. Phone: +27 11 717 1337. E-mail: joshua.davimes@wits.ac.za - Orcid: 0000-0001-9808-5249

---

**Submitted:** December 13, 2023. **Accepted:** January 12, 2024

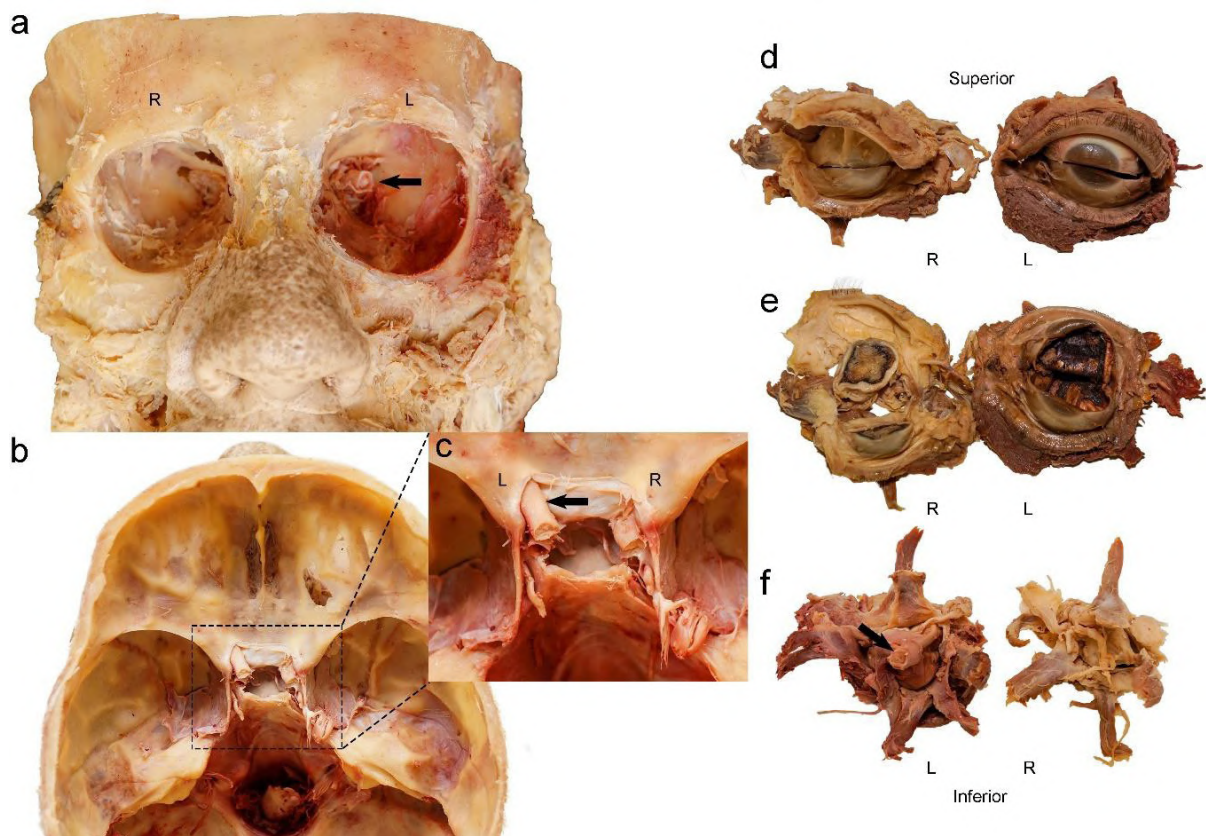
<https://doi.org/10.52083/TRRU3034>

An adult human optic nerve (cranial nerve II or CNII) is approximately 40 to 50 mm in length (Zeiss et al., 2017). CNII is a continuation of the optic tract which originates from the optic chiasma and courses about 10mm intracranially before taking an extracranial course (about 30 mm) by passing through the optic canal of the sphenoid bone to reach the posterior aspect of the eyeball to receive visual impulses from the neural retina. Developmentally, CNII is a derivative of the fore-brain and, due to the complexity of the coordinated events during the development of the eye, optic nerve aplasia may be associated with other central nervous system or ocular anomalies (Martín-Begué and Saint-Gerons, 2016). The majority of these anomalies have been reported through radiological imaging studies that do not provide the comprehensive anatomical presentation and course of the anomalous optic nerve (Handley et al., 2021; Martín-Begué and Saint-Gerons, 2016;

Taylor, 2007; Zhou et al., 2020). Herein, a case of unilateral optic nerve aplasia associated with microphthalmia is reported on following an incidental cadaveric dissection finding. Cadaveric dissections are exploratory in nature, and offer a comprehensive way to describe the anomalous course of any variation, an advantage that cannot be adequately achieved in living individuals when using radiological imaging studies.

### CASE REPORT

This cadaveric study was conducted under the ethical clearance waiver number W-CBP- 220504-01 and was covered by the Human Tissue Act (No. 65 of 1983) and the National Health Act (No. 61 of 2003) on the use of human specimens for research and teaching purposes. During the routine dissection of the head and neck region in a female cadaver, South African of European descent, aged 52, the right eye appeared smaller and underde-

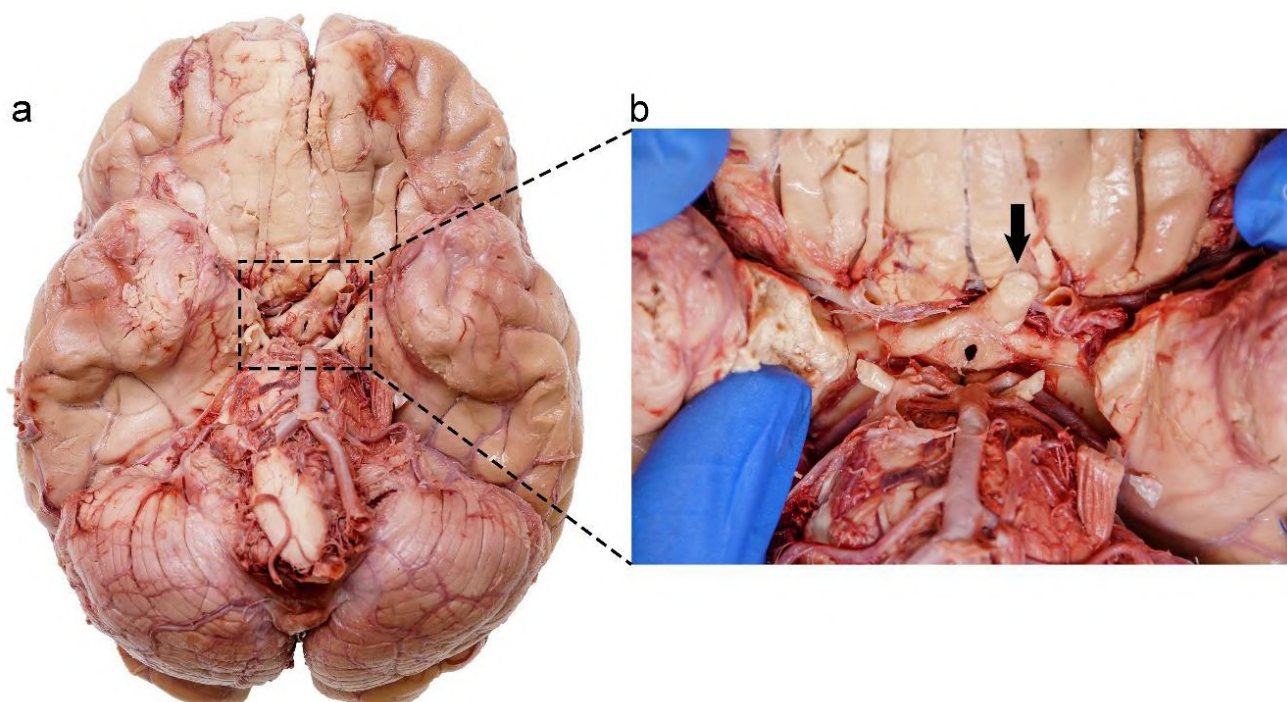


**Fig. 1.-** External and internal features of the skull and eyeballs. (a), anterior view of the skull showing a smaller right orbit and a larger left orbit, black arrow indicating the present left optic nerve. (b), Superior view of the intra-cranial fossa showing the central part of the mid-cranial fossa (Sella turcica) and its related structures. (c), Inset from b, with a magnified view showing the left optic nerve (black arrow) passing through the optic canal and the right ophthalmic artery passing through the right optic canal. (d), anterior view of the eyeballs, note the poorly developed cornea and iris of the right eye. (e), a transverse section of the eyeballs showing a calcified mass in the right eyeball and normal vitreous body and retina in the left eyeball. (f), posterior view of the eyeballs showing extraocular muscles, black arrow indicating left optic nerve as it enters the left eyeball, and fat and fibrous tissue on the right eyeball. R=Right side, L=Left side.

veloped when compared to the left eye. The eyes were then excised as part of the dissection protocol from the orbital sockets and inspected for abnormalities, where only the left optic nerve was present (Figs. 1 and 2). After the excision of the eyes, the brain was removed from the skull, where additional inspections of the neural tissues were conducted. These included gross inspections of the whole brain, followed by sagittal, horizontal and coronal sectioning.

In addition to a complete absence of the right optic nerve (Figs. 1 and 2), the bony orbit of the right side was smaller (orbital breadth 36.13 mm, orbital height 32.20 mm) when compared to the left (orbital breadth 40.60 mm, orbital height 36.24 mm). The right eyeball was also smaller with a poorly developed cornea and iris (Fig. 1D). A transverse section of the right eyeball showed the presence of a calcified mass covering the interior spaces, while the left eyeball presented with a normal vitreous body and retinal appearance (Fig. 1E). The right eyeball showed the presence of all, albeit grossly atrophied, extra-ocular muscles with fibrous tissue and fat occupying the central posterior part of the eyeball. The left eyeball showed the normal presence of all extra-ocular

muscles with the optic nerve entering the posterior aspect centrally (Fig. 1F). The right optic canal was only patent enough for the passage of the right ophthalmic artery, while the left optic canal was intact with the left optic nerve and left ophthalmic artery passing through it (Fig. 1A-C). Both the left and right oculomotor (CN III), trochlear (CN IV) and abducens (CN VI) nerves took their normal course to supply their respective extra-ocular muscles. Visual inspection of the inferior view of the intact whole brain showed the complete absence of the right optic nerve and its connection to the optic chiasma. The right and left optic tracts originated off-centre to the left but then continued along their normal paths as the left and right optic tracts on either side of the tuber cinereum and infundibulum (Fig. 2A and B). A relatively smaller right splenium of the corpus callosum (13.68 mm, measured at widest point) compared with the left (15.17 mm) was the only noticeable difference in the midsagittal view of the brain. Horizontal and coronal brain sections showed no gross differences between the right and left side optic radiations (geniculocalcarine tracts), lateral geniculate bodies and superior colliculi.



**Fig. 2.-** Inferior view of the brain. **(a)** presence of a cut left side optic nerve and absent right. **(b)** magnified inset showing convergence of left- and right-side optic tracts continuing as a single left optic nerve.

## DISCUSSION

Optic nerve aplasia has been variably defined in the literature (Martín-Begué and Saint-Gerons, 2016; Ohuchi et al., 2016; Zhou et al., 2020). Diagnosis of optic nerve aplasia within the clinical setting is confirmed radiologically when a blind eye presents with a total absence of optic nerve fibres, optic disc, retinal ganglion cells and central retinal vessels (Martín-Begué and Saint-Gerons, 2016; Meire et al., 2011; Ohuchi et al., 2016; Taylor, 2007). The total absence of optic nerve fibres leading to the absence of the optic disc and central retina vessels in the case study presented concurs with radiological descriptions of optic nerve aplasia.

Ohuchi et al. (2016) reported a bilateral case of optic nerve aplasia observed during an autopsy. The optic nerve presented as a myelinated cotton-thread-like cord originating from the poorly developed optic chiasma and extending to the posterior pole of the eyeball (Ohuchi et al., 2016), which is consistent with an extreme case of hypoplasia presented in the literature (Margo et al., 1992). In contrast to Ohuchi et al. (2016), a complete unilateral absence of both the intracranial and extracranial course of the optic nerve is presented in the current case study.

The commonly used diagnostic imaging modalities for optic nerve aplasia include magnetic resonance imaging, computerized tomography, and brightness (B-Scan) ultrasonography. However, controversy still exists regarding the best imaging modalities to accurately diagnose true optic nerve aplasia (Martín-Begué and Saint-Gerons, 2016; Ohuchi et al., 2016; Zhou et al., 2020). As a result of differential diagnostic criteria being presented in imaging studies, optic nerve hypoplasia has been grossly misidentified as optic nerve aplasia in the literature and the incidence of true optic nerve aplasia remains unclear (Martín-Begué and Saint-Gerons, 2016).

While some patients with optic nerve hypoplasia may present with partial blindness, it should be noted that in true optic nerve aplasia patients usually present with complete blindness (Meire et al., 2011). Ocular anomalies associated with optic nerve aplasia include microphthalmia, iris

anomalies, retinal dysplasia, cataracts, corneal oedema and sclerocornea (Handley et al., 2021; Martín-Begué and Saint-Gerons, 2016; Ohuchi et al., 2016).

Microphthalmia is the presence of an abnormally small eye with reduced axial length and corneal diameter measurements (Verma and FitzPatrick, 2007). The normal adult human eye presents with a mean axial length of 23.8 mm and a corneal diameter which ranges between 9.0-10.5 mm (Handley et al., 2021; Verma and FitzPatrick, 2007). In the clinical setting, any adult human eye with a mean axial length of less than 21 mm is considered microphthalmic (Verma and FitzPatrick, 2007). In the current case, eyeball measurements were not taken, as cadaveric soft tissues usually shrink after preservation with formalin. Instead, the measurements of the orbital socket taken to substantiate the gross appearance of the left and right eyeballs presented with an approximately 4mm smaller orbital height and breadth in the right eye. Thus, the size difference presented in the right eye when compared to the left in the current case may be considered within the spectrum of microphthalmia (Handley et al., 2021; Verma and FitzPatrick, 2007).

Optic nerve aplasia may also be associated with cardiovascular, endocrinological, gastrointestinal, vertebral and neurological anomalies (Ghassemi et al., 2015). While little is known about the lived state of health of the cadaver, presented in the current case study, a smaller right splenium of the corpus callosum was observed. The presence of a reduced splenium of the corpus callosum may be considered consistent with corpus callosum hypoplasia (Martín-Begué and Saint-Gerons, 2016). In contrast with the current case study, the radiological imaging of the brain in the case of optic nerve aplasia reported by Ohuchi et al. (2016) did not reveal any associated brain anomalies. Despite this finding, the existing evidence suggests that unilateral optic nerve aplasia associated with microphthalmia usually occurs without brain abnormalities, especially when the aplasia is due to single eye developmental interruptions (Martín-Begué and Saint-Gerons, 2016; Ohuchi et al., 2016; Taylor, 2007). In keeping with the varied embryological contributions of tissues to the

development of the eye previously reported, the absent right optic nerve in the current case may be due to developmental anomalies of the retinal ganglion cells (Ohuchi et al., 2016).

The calcified vitreous tissue may imply that the mesenchyme failed to develop properly (Margo et al., 1992; Ohuchi et al., 2016). In addition, there could be reduction in blood flow around the right eyeball, which could lead to proteins within the vitreous humor becoming sticky and hardening.

Potential contributing genetic factors are difficult to ascertain, as the family and genetic history was not available. There is also limited literature on the incidence and genetics of human optic nerve aplasia associated with microphthalmia (Ghassemi et al., 2015; Handley et al., 2021; Meire et al., 2011).

## CONCLUSION

The current report includes the anatomical presentation of a true optic nerve aplasia associated with microphthalmia. Cadaveric reports may advance the understanding of optic nerve aplasia to the current sparse literature and substantiate clinical and radiological presentations, in turn, improving diagnosis and treatment.

## ACKNOWLEDGEMENTS

The authors sincerely thank those who donated their bodies to science to perform anatomical research (Wits School of Anatomical Sciences Body Donation Programme). Such research can potentially increase humankind's overall knowledge to improve patient care. Therefore, these donors and their families deserve our highest gratitude.

## REFERENCES

- GHASSEMI F, BAZVAND F, HOSSEINI SS, KARKHANEH R, EBRAHIMIADIB N, SHEKARCHI B (2015) Optic nerve aplasia: Case report and literature review. *J Ophthalmic Vis Res*, 10: 187-192.
- HANDLEY SE, MARMOY OR, GORE SK, MANKAD K, THOMPSON DA (2021) Case report: Unilateral optic nerve aplasia and developmental hemichiasmal dysplasia with vep misrouting. *Doc Ophthalmol*, 142: 247-255.
- MARGO CE, HAMED LM, FANG E, DAWSON WW (1992) Optic nerve aplasia. *Arch Ophthalmol*, 110: 1610-1613.
- MARTÍN-BEGUÉ N, SAINT-GERONS M (2016) Congenital optic nerve anomalies. *Arch Soc Esp Oftalmol (English Edition)*, 91: 577-588.
- MEIRE F, DELPIERRE I, BRACHET C, ROULEZ F, VAN NECHEL C, DEPASSE F, CHRISTOPHE C, MENTEN B, DE BAERE E (2011) Nonsyndromic bilateral and unilateral optic nerve aplasia: First familial occurrence and potential

implication of *cyp26a1* and *cyp26c1* genes. *Mol Vis*, 17: 2072.

OHUCHI H, TANIGUCHI K, MIYAISHI S, KONO H, FUJITA H, BANDO T, FUCHIZAWA C, OHTANI Y, OHTANI O (2016) Autopsy case of bilateral optic nerve aplasia with microphthalmia: Neural retina formation is required for the coordinated development of ocular tissues. *Acta Med Okayama*, 70: 131-137.

TAYLOR D (2007) Developmental abnormalities of the optic nerve and chiasm. *Eye*, 21: 1271-1284.

VERMA AS, FITZPATRICK DR (2007) Anophthalmia and microphthalmia. *Orphanet J Rare Dis*, 2: 1-8.

ZEISS CJ, TU DC, PHAN I, WONG R, TREUTING PM (2017) Special Senses: Eye. In: *Comparative Anatomy and Histology: A mouse, rat, and human atlas*, Second edition. Elsevier, pp 445-470.

ZHOU Y, RYAN ME, METS MB, YOON HH, RAHMANI B, KURUP SP (2020) Aplasia of the optic nerve: A report of seven cases. *Neuroophthalmology*, 44: 332-338.