

# Radiographic assessment of maxillary sinus lateral wall and anatomy of posterior superior alveolar artery: A Cone-Beam Computed Tomographic

Renuka Devi KR, Mahima V. Guledgud, Karthikeya Patil, Sanjay CJ, Nagabhushana D, Harshitha N

*Department of Oral Medicine and Radiology, JSS Dental College and Hospital, JSS Academy of Higher Education and Research, Mysore - 570 015, India*

## SUMMARY

The aims of the study were to determine the thickness of maxillary sinus (MS) lateral wall and to assess the prevalence, distance from maxillary sinus floor, diameter and course of posterior superior alveolar artery (PSAA) based on age, gender and dental status using cone-beam computed tomography (CBCT) that might be relevant to accomplish complication free surgeries in posterior maxilla. CBCT images of maxillary sinus (right and left) were obtained for 40 patients, which included 20 males and 20 females. Maxillary sinus lateral wall and PSAA parameters were measured and evaluated. The data obtained were then subjected to descriptive statistical analysis; independent t-test and one-way Anova test were performed and compared based on age, gender and dental status. The results showed that the average thickness of the lateral wall of the maxillary sinus was determined to be approximately around 2.50 mm. PSAA was observed in 25% of subjects with a maximum distance of 8.83 mm from the maxillary sinus floor and a minimum distance of 6.90 mm. PSAA

had a diameter of 1-2 mm with the intraosseous course in most individuals. Comparison between CBCT images of the selected individuals among age groups, gender and dental status were not statistically significant on measuring the above mentioned parameters. This study concluded that CBCT provides valuable diagnostic information pertaining to sinus and related landmarks that assist during surgical procedures.

**Key words:** Maxillary sinus lateral wall – PSAA – CBCT – Dental implants

## INTRODUCTION

Dental implants are frequently used to reconstruct edentulous areas of the posterior maxilla. Restoring of the posterior edentulous maxilla with dental implants is challenging due to insufficient height and width of the alveolar bone ridge (Talo Yildirim et al., 2019). To overcome these difficulties, two surgical methods utilised for maxillary sinus augmentation are the lateral

---

### Corresponding author:

Dr. Mahima V, Guledgud, Professor. Department of Oral Medicine and Radiology, JSS Dental College and Hospital, JSS Academy of Higher Education and Research, Mysore - 570 015, India. Phone: +91 94480 86800. E-mail: dr.mahimavg@jssuni.edu.in

---

Submitted: March 10, 2022. Accepted: March 17, 2022

<https://doi.org/10.52083/RLF18348>

window approach and the crestal method (Kiakojori et al., 2017). According to ancient medicine, sinuses as part of the skull's anatomy are intrinsically connected to vital organs. The maxillary sinuses undergo pneumatization as the age advances. The infraorbital artery (IOA) and the PSAA are branches of the maxillary artery that supply the superior membrane and lateral wall of the maxillary sinus (Van Cauwenberge et al., 2004). Maxillary sinus augmentation procedure is a safe and effective technique for the rehabilitation of the severely atrophic posterior maxilla with a significant predictability. Schneiderian membrane perforation and deterioration of the lateral wall's vascular supply are the most prevalent complications of this surgical approach. During intervention, it is necessary to predict probability of sinus membrane perforations; the thickness of the lateral sinus wall must be assessed. It is also critical to evaluate the anatomy of the maxillary sinus in order to avoid complications, since PSAA is closely related to the anatomy of the MS (Talo Yildirim et al., 2019; Van Cauwenberge et al., 2004). After the emergence of three-dimensional imaging mode, CBCT is deemed as the gold standard to evaluate the MS lateral wall thickness and its vascular anatomy owing to its accuracy, high resolution, and better tissue contrast by eliminating the overlap of surrounding structures (Van Cauwenberge et al., 2004).

In this backdrop, the present study was designed to measure the maxillary sinus lateral wall thickness, and also the prevalence, diameter and course of PSAA using CBCT. This study also correlates gender, age groups, and dental status with the MS and PSAA parameters which may provide significant information and assist the clinician in operative procedures.

## **MATERIALS AND METHODS**

The study was approved by the Institutional Ethics Committee. Forty CBCT scans of 20 females and 20 males were reviewed summing up to 80 sinuses. The study samples were obtained from the outpatients attending the Department of Oral Medicine and Radiology, with age range of 21-86 years (mean age of 76 years). Prior to commencing the CBCT exposure, demographic data, complaint

and past history of the patients were recorded. All of the subjects signed a formal consent form allowing their data to be used for research.

After precise placement of the study subject, ProMax 3D Mid CBCT machine was set to standard exposure parameters at 90 KvP, 8mA, 0.04 S, medium FOV on each side of the maxillary sinus for exposure. The resultant images, with slice thickness of 0.400 mm, were stored in DICOM format. Only high-quality images entirely encompassing the bilateral maxillary sinuses were included after an initial screening, while low-quality images and those with any artefacts were eliminated. Scans that detected unilateral and/or bilateral maxillary sinus developmental abnormalities, fractures, or any pathology such as a tumor or cyst were also excluded.

The axial, coronal and sagittal sections of selected CBCT images were reformatted and analyzed under optimum viewing conditions, and the following measurements were performed on coronal sections using Planmeca Romexis 5.3 (3D Software).

### **Measurement of Maxillary sinus lateral wall thickness**

For the purpose of the study, the maximum distance perpendicularly from the inner point to the outermost point on the lateral wall of both right and left maxillary sinuses on coronal sections was considered to be the lateral wall thickness of the maxillary sinus. One vertical line was drawn on the coronal section 5mm from the maxillary sinus floor using a digital caliper. Taking this as a reference plane, a horizontal line drawn on the lateral wall of the maxillary sinus at the level of 5 mm measured the thickness of maxillary sinus lateral wall (Fig. 1).

### **Prevalence of PSAA**

CBCT sections were checked for radiolucency interrupting the lateral wall of the maxillary sinus by scrolling it from anterior aspect to posterior aspect evaluated the prevalence of PSAA.

### Measurement of distance of PSAA from the maxillary sinus floor

The maximum distance from the floor of the maxillary sinus to the area of visibility in the lateral wall of the maxillary sinus on coronal sections was considered to be the distance of PSAA from the maxillary sinus floor. One linear line drawn on the coronal section from the floor of the maxillary sinus to the level of visibility of posterior superior alveolar canal located in the lateral wall of the maxillary sinus using a digital caliper measured the distance of PSAA from maxillary sinus floor (Fig. 2).

### Measurement of diameter and determining the course of PSAA

The longest anteroposterior distance from the point most anteriorly to the point most posteriorly on coronal sections was considered to be the diameter of PSAA. One horizontal line was drawn on the coronal section anteroposteriorly at the area of visibility of PSAA canal in the lateral

wall of the maxillary sinus using a digital caliper measured the diameter of PSAA (Fig. 3). Based on the visibility, the path of the posterior superior alveolar artery was determined (Fig. 4).

The measurements were made at four different locations: the first premolar (P1), the second premolar (P2), the first molar (M1), and the second molar (M2) (M2). On the other side of the sinus, the same procedures were used.

### Statistical Analysis

The data was generated on MS Office Excel Sheet (version 2019), and statistical analysis was performed using the Statistical Package for Social Sciences (SPSS). A comparison was made between gender, dental status, and age groups. The obtained data were then subjected to descriptive statistics, One-way Anova and Independent sample t-test to analyze the statistical significant difference between the means in groups.

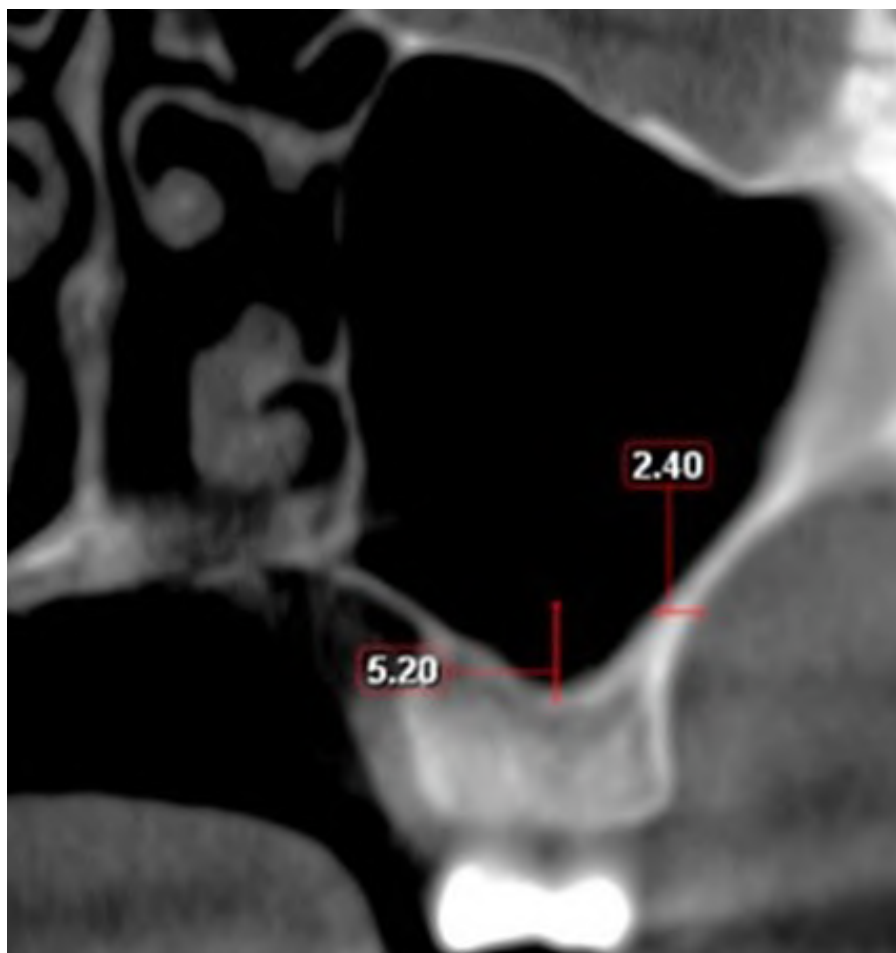

Fig. 1.- Measurement of maxillary sinus lateral wall thickness on coronal section.

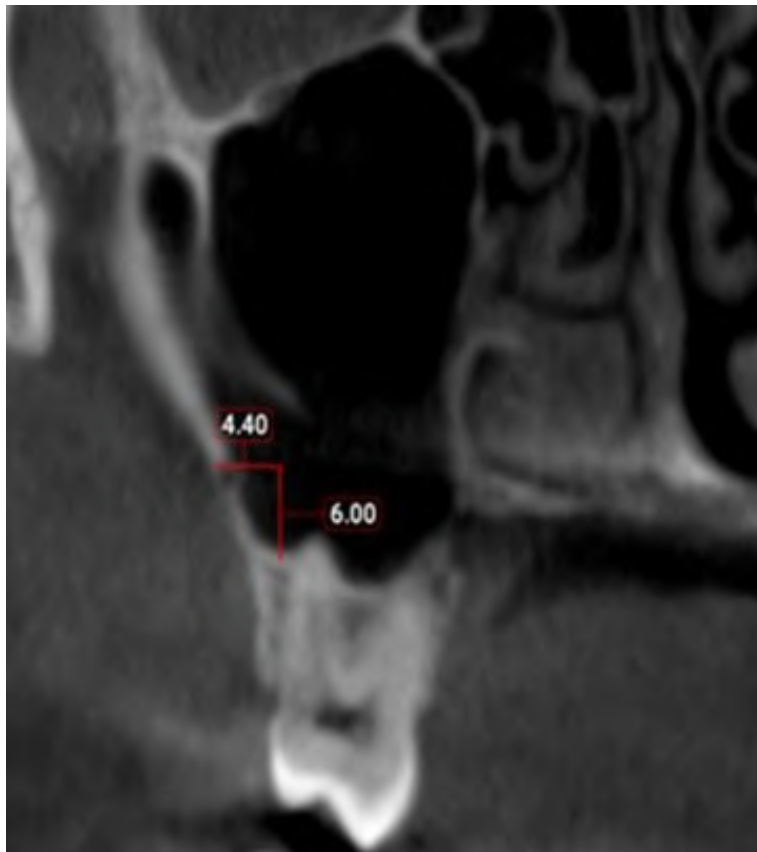


Fig. 2.- Distance of PSAA from maxillary sinus floor on coronal section.

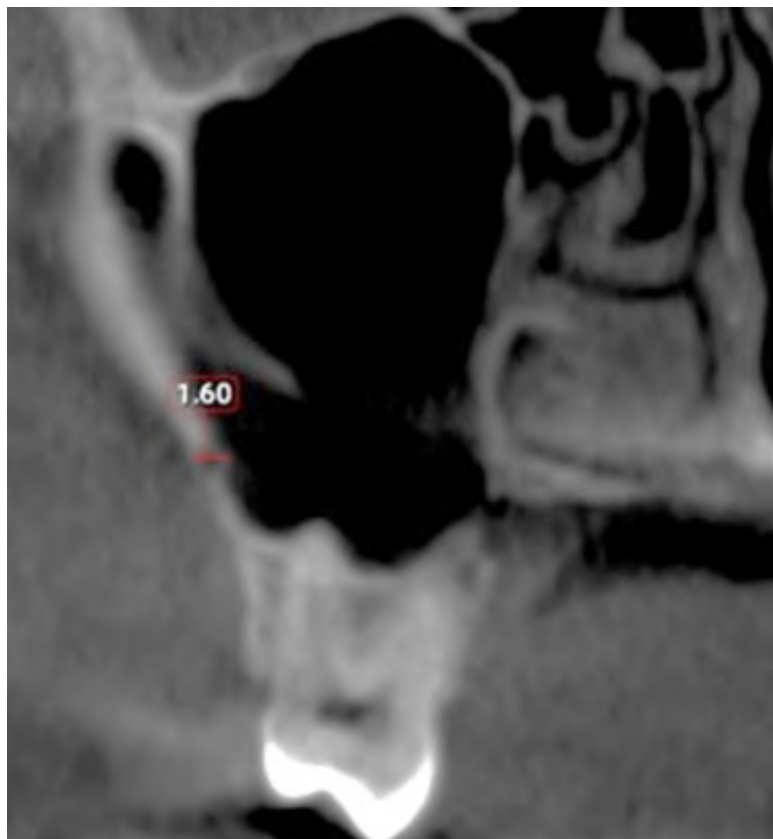

Fig. 3.- Diameter of PSAA on coronal section.

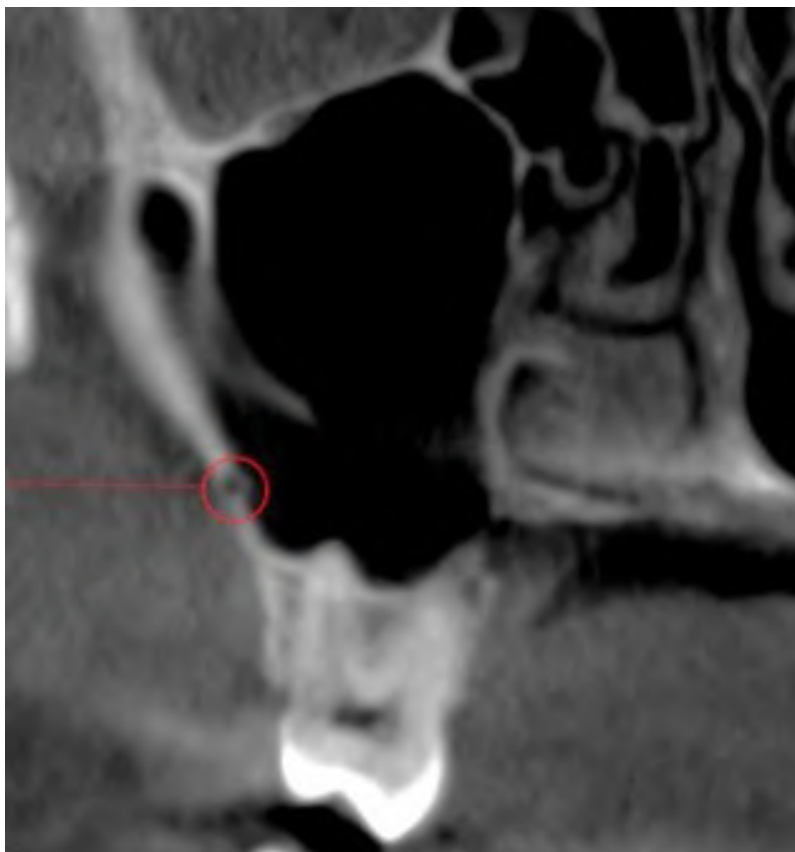


Fig. 4.- Course of PSAA on coronal section.

## RESULTS

Among the 40 study subjects, 20 (50%) were males and 20 (50%) females, with a mean age of 44.000 and 37.3500 in males and females respectively. Thirty study subjects were dentulous (46.7%) and 10 were edentulous (10.0%).

The mean thickness of maxillary sinus lateral wall at P1 was  $2.40 \pm 0.57$  mm, P2 was  $2.57 \pm 0.59$  mm, M1 was  $2.46 \pm 0.71$  mm and M2 was  $1.98 \pm 0.57$  mm (Table 1).

Table 1. Maxillary sinus lateral wall thickness.

Maxillary sinus lateral wall thickness (mm) (n=40)		
TOOTH SITE	MEAN	SD
P1	2.40	$\pm 0.57$
P2	2.57	$\pm 0.59$
M1	2.46	$\pm 0.71$
M2	1.98	$\pm 0.57$

The maxillary sinus lateral wall thickness was compared between males and females: males appeared to have a thinner wall thickness than women with the exception at P2 location. Despite

the fact that there was a mean value difference between genders, there were no statistically significant variations. The subjects' varying age groups and dental status (edentulous and non-edentulous) had no statistically significant influence on the lateral wall thickness (Table 2).

The presence of PSAA was detected on 25% of patients among the study subjects.

The mean distance of PSAA from the maxillary sinus floor was  $6.90 \pm 0.43$  mm at P1,  $7.44 \pm 0.53$  mm at P2,  $8.58 \pm 0.51$  mm at M1 and  $8.83 \pm 1.54$  mm at M2. The total mean distance of PSAA indicates that the distance from the maxillary sinus floor was found to be greater in molars than in premolars. PSAA distance from the maxillary sinus floor was substantially larger in dentulous people than in edentulous persons (Table 3).

PSAA vessel mean diameter was higher in molars than premolars. According to linear measurements, the mean diameter of the posterior superior alveolar artery at P1, P2, M1, M2 was reported to be less than 1 mm in 46.83% cases, 1-2 mm in 51.89% of cases and more than 2mm in only one patient among the study subjects (Table 4).

**Table 2.** Differences in maxillary sinus lateral wall thickness by age, gender and dental status.

TOOTH SITE	GENDER	Mean ± SD	Sig (2-tailed)	DENTAL STATUS	Mean ± SD	P	AGE GROUPS	Mean ± SD	Sum of squares	sig
P1	Male	2.39 ± .549	0.96	Dentate	2.39 ± 0.56	0.95	21-30	2.45 ± 0.64	26.2	.903
	Female	2.40 ± .608						31-40		
			41-50	2.33 ± 0.53						
			51-60	2.43 ± 0.65						
			71-80	2.60 ± 0.28						
P2	Male	2.64 ± .520	0.26	Dentate	2.56 ± 0.59	0.83	21-30	2.74 ± 0.59	28.3	.426
	Female	2.49 ± .667						31-40		
			41-50	2.51 ± 0.72						
			51-60	2.49 ± 0.58						
			71-80	2.40 ± 0.00						
M1	Male	2.39 ± .753	0.38	Dentate	2.47 ± 0.68	0.88	21-30	2.30 ± 0.52	40.0	.641
	Female	2.53 ± .670						31-40		
			41-50	2.48 ± 0.49						
			51-60	2.57 ± 0.91						
			71-80	2.80 ± 0.56						
M2	Male	1.98 ± .547	0.95	Dentate	2.02 ± 0.59	0.28	21-30	1.97 ± 0.59	26.3	.294
	Female	1.99 ± .613						31-40		
			41-50	2.04 ± 0.47						
			51-60	1.86 ± 0.46						
			71-80	2.80 ± 0.56						

**Table 3.** PSAA distance from maxillary sinus floor.

PSAA distance from maxillary sinus floor (mm) (n=40)		
TOOTH SITE	MEAN	SD
P1	6.90	± 0.43
P2	7.44	± 0.53
M1	8.58	± 0.51
M2	8.83	± 1.54

**Table 4.** Diameter of PSAA.

Diameter of PSAA (mm) (n=40)		
Category	mm	%
Category 1	<1	46.83%
Category 2	1-2	51.89%
Category 3	>2	1.26%

When age groups, gender, and dental status were compared, there was no variability in PSAA diameter and distance from the maxillary sinus floor (Tables 5 and 6).

On examining the course of PSAA at P1, 5% were intraosseous and 2.5 % were intrasinusal. At P2, 12.5% were intraosseous and 12.5% were intrasinusal. At M1, 1.3% were superficial, 11.3 % were intrasinusal and 15% were intraosseous. At M2, 1.3% were superficial, 15% were intrasinusal and 28.8 % were intraosseous (Table 4). As a result of the statistical comparison, the intraosseous form of PSAA was the most prevalent, followed by intrasinusal, and lastly superficial.

## DISCUSSION

Osseointegration of dental implants needs appropriate bone quantity as well as bone quality. The MS is one of the most important anatomic

features to consider when inserting implants in the posterior maxillary region. The length and location of implants are influenced by the reduced bone height produced by MS pneumatization. Thus, procedures such as maxillary sinus floor elevation (SFE), which facilitate the placement of longer implants in the posterior maxilla (Tarun Kumar and Anand, 2014). The most common intraoperative complication during sinus elevation is perforation of the Schneiderian membrane (Schwartz-Arad et al., 2015).

Infracture and wall-off are two methods for preparing the lateral window osteotomy. The lateral wall is tapped over the graft materials as a roof in the infracture method, while in the wall-off procedure, the lateral wall is removed to get access to the sinus. In addition to maxillary sinus floor elevation, surgical procedures must consider lateral wall thickness and PSAA (Wallace et al.,



2012; Raja, 2009). Data from earlier research that described the distance of the lower border of the window to the maxillary sinus floor were used to establish the measuring point of the lateral wall (Wallace et al., 2012; Woo and Le, 2004).

According to the literature, only a few studies have examined the impact of age, sex, and dental status on lateral wall thickness of maxillary sinus. Clinicians utilize the sinus floor as a reference point when designing the lateral window

osteotomy's margins from a clinical standpoint (Wallace et al., 2012).

According to Zijderveld et al. (2008), 78% of patients had a thin lateral maxillary sinus wall. The thickness of the lateral wall should be measured before surgery, since it may compromise the sinus membrane's integrity (Kiakojoiri et al., 2017). In addition to maxillary sinus floor elevation, surgical procedures must consider lateral wall thickness and PSAA. Few researchers have

**Table 5.** Differences in distances of PSAA from maxillary sinus floor by age, gender and dental status.

TOOTH SITE	GENDER	Mean ± SD	Sig (2-tailed)	DENTAL STATUS	Mean ± SD	P	AGE GROUPS	Mean ± SD	Sum of squares	sig
P1	Male	6.86 ± 0.51	0.78	Dentate	6.92 ± 0.47	0.85	21-30	6.98 ± 0.56	1.15	0.69
	Female	6.96 ± 0.40					31-40	6.97 ± 0.00		
			41-50	6.96 ± 0.40						
			51-60	6.56 ± 0.00						
			71-80	6.50 ± 0.00						
P2	Male	7.83 ± 0.53	0.74	Dentate	7.77 ± 0.59	0.29	21-30	7.83 ± 0.67	4.60	0.61
	Female	7.92 ± 0.56					31-40	7.81 ± 0.00		
			41-50	7.70 ± 0.62						
			51-60	7.95 ± 0.35						
			71-80	8.50 ± 0.00						
M1	Male	8.98 ± 0.30	0.92	Dentate	9.00 ± 0.58	0.66	21-30	8.83 ± 0.72	5.86	0.88
	Female	8.96 ± 0.69					31-40	9.20 ± 0.50		
			41-50	8.96 ± 0.46						
			51-60	8.98 ± 0.40						
			71-80	8.95 ± 0.07						
M2	Male	8.57 ± 2.25	0.38	Dentate	9.18 ± 0.60	0.39	21-30	9.29 ± 0.59	78.3	0.41
	Female	9.03 ± 0.53					31-40	9.29 ± 0.72		
			41-50	8.92 ± 0.71						
			51-60	7.91 ± 2.90						
			71-80	9.00 ± 0.70						

**Table 6.** Differences in diameter of PSAA by age, gender and dental status.

TOOTH SITE	GENDER	Mean ± SD	Sig (2-tailed)	DENTAL STATUS	Mean ± SD	P	AGE GROUPS	Mean ± SD	Sum of squares	sig
P1	Male	1.00 ± 0.23	0.85	Dentate	1.01 ± 0.18	0.92	21-30	0.96 ± 0.20	0.40	0.29
	Female	1.03 ± 0.15					31-40	0.85 ± 0.00		
			41-50	1.13 ± 0.54						
			51-60	0.11 ± 0.00						
			71-80	0.80 ± 0.00						
P2	Male	0.95 ± 0.18	0.68	Dentate	1.06 ± 0.31	0.10	21-30	0.97 ± 0.20	0.62	0.90
	Female	1.0 ± 0.36					31-40	0.86 ± 0.00		
			41-50	1.04 ± 0.45						
			51-60	0.96 ± 0.18						
			71-80	0.80 ± 0.00						
M1	Male	1.06 ± 0.25	0.72	Dentate	1.17 ± 0.40	0.12	21-30	1.11 ± 0.38	0.28	0.70
	Female	1.12 ± 0.47					31-40	1.26 ± 0.59		
			41-50	1.13 ± 0.32						
			51-60	0.95 ± 0.30						
			71-80	0.84 ± 0.06						
M2	Male	1.05 ± 0.37	0.37	Dentate	1.09 ± 0.37	0.60	21-30	0.99 ± 0.20	1.02	0.14
	Female	1.16 ± 0.34					31-40	1.50 ± 0.42		
			41-50	1.03 ± 0.40						
			51-60	1.30 ± 0.36						
			71-80	1.20 ± 0.00						

**Table 7.** Course of PSAA.

Course of PSAA			
TOOTH SITE	Intraosseous	Intrasinusal	Superficial
P1	5%	2.5 %	-
P2	12.5%	12.5%	-
M1	15%	11.3%	1.3%
M2	28.8 %	15%	1.3%

explored into MS lateral wall thickness, PSAA, and possible relationships with patient's age, gender, and dental status (Kiakojoori et al., 2017).

The present research demonstrated a thicker lateral wall in females in comparison to male subjects at the M1 location, and thicker lateral wall in male subjects at the P2 location. We noticed that the difference of lateral wall thickness between genders were not statistically significant.

Previous studies on lateral wall thickness found significant gender variations exclusively in the premolar area (Yang et al., 2012). Kang et al. (2013) discovered a substantial difference between males and females at a three-millimeter distance from the sinus floor. In terms of dental status, the findings of this study revealed that dentate people have thicker lateral walls than edentulous people, however the difference is statistically insignificant. In their investigation, Khajehahmadi et al. (2014) found no significant differences between dentulous and edentulous subjects. However, among dentate individuals, there was a trend toward a thicker lateral wall. Monje et al. (2014) analyzed the relationship between edentulous span and lateral wall thickness, and observed that the greater the edentulous span, the thinner the lateral wall. Also, that there was no statistically significant difference in age groups. Our findings are in agreement with statistics stated from earlier researches, which established that sinus lateral wall thickness does not increase with age (Kang et al., 2013; Monje et al., 2014). This is an interesting finding observed in our study. As the bone atrophy might progress further with time, it would have been noteworthy to study the association between duration of the edentulousness of the subjects with the lateral wall thickness. Further studies in this regard may shed more information on this aspect.

Various studies on PSAA prevalence rate observed the following: Ella et al. (2008), 10.5%; Rosano et al. (2009), 47%; Jung et al. (2011), 52.8%; Apostolakis and Bissoon et al. (2014), 82%; Kang et al. (2013), 64.3%; Watanabe et al. (2014), 58.6%; Güncü et al. (2011), 64.5%, and Yang et al. (2012), 32.5% (see Kiakojoori et al., 2017 for review). The prevalence of PSAA on CBCT in our current study data shows detection rate of around 26% (n=40) among the study subjects. Detection rate is higher in molar locations than premolars.

Discrepancy in many of the studies may be related to the lack of expertise of the clinicians, mode of imaging, and technical elements in assessing CBCT data (Kiakojoori et al., 2017). Our CBCT images were obtained from a premium CBCT machine available in the market.

The distance of PSAA from maxillary sinus floor is significant in establishing the exact position of the PSAA, as well as the optimum length of an implant to be positioned in the edentulous area (Manjushri Waingade et al., 2021). The PSAA mean distance from the maxillary sinus floor was approximately about 6.00 mm to 8.00 mm for the P1, P2, M1, M2 areas. The distance of the posterior superior alveolar artery from sinus floor decreased towards the premolar region and increases as it approaches at the molar region. Other studies by Yang et al. (2012), Watanabe et al. (2014), Apostolakis and Bissoon (2014), Jung et al. (2011) and Yu et al. (2019), observed that the mean distance at P1, P2, M1, M2 were 7.75 mm, 9.57mm, 6.47 mm, 8.17 mm and 9.70 mm, respectively. In different orientations, the distance between the PSAA and the maxillary sinus floor varied substantially across individuals around the mean values (Apostolakis and Bissoon, 2014; Kiakojoori et al., 2017).



Based on the hypothesis of Fayek et al. (2021), the mean diameter of PSAA was classified into three categories: Category 1: less than 1 mm; Category 2: between 1-2 mm; Category 3: more than 2 mm.

The mean diameter of PSAA obtained from our study was between 1-2 mm (Category 2) at P1, P2, M1, M2 locations. Very few individuals' PSAA diameter varied less than 1 mm (Category 1). Also, the diameters of PSAA in females are comparatively higher than males. Concerning the dental status, dentulous patients revealed larger PSAA vessels except in M2 region. A larger diameter might indicate serious bleeding, which could lead to intraoperative and postoperative problems such perforation of the Schneiderian membrane, graft material displacement, and hematoma of surrounding structures (Manjushri Waingade et al., 2021). There was no difference associated with age groups. Findings from our results exhibits no statistical difference between gender, dental status and age.

Studies by Kang et al. (2013), Güncü et al. (2011) and Apostolakis and Bissoon (2014), are in support of our study and show no statistical significance among gender and age groups. In contrast, comparison with younger age groups, Mardinger et al. (2007) found that elderly patients had larger diameter.

For the purpose of our study, the course of PSAA was divided into three types: Type I: Superficial; Type II: Intraosseous; and Type III: Intrasinusal.

When assessing the path of PSAA in relation to the lateral wall based on the visibility, we found Type II intraosseous course (30%) (n=40), followed by Type III intrasinusal (20%), (n=40) and then Type I superficial course (5%) (n=40) at all examined locations and remaining were not located.

Our findings show similar results to the previous studies revealing the most frequent course as intraosseous by Güncü et al. (2011) (68.2% of intraosseous course, 26% intrasinusal course). Ella et al. (2008) (71.4 % of intraosseous course, 14.3% intrasinusal course), Ilgüy et al. (2013) (71.1% of intraosseous course, 13% intrasinusal course), Kang et al. (2013) (64.3% of intraosseous course, 29.1% intrasinusal course).

The key anatomical points of the maxillary sinus and the position of PSAA were clearly demonstrated in this study. As a result, these parameters are recommended for offering complication-free implant planning operations.

The main observations made from the study are the following:

- Mean thickness of maxillary sinus lateral wall
- Prevalence and Course of PSAA
- Mean distance of PSAA from maxillary sinus floor
- PSAA mean diameter

The average thickness of the lateral wall of the maxillary sinus was determined to be approximately around 2.50 mm. PSAA was observed in 25% of subjects, with a maximum distance of 8.83mm from the maxillary sinus floor and a minimum distance of 6.90 mm. PSAA had a diameter of 1-2mm with the intraosseous course in most individuals.

The above parameters were found to be statistically insignificant between genders, dental status and age groups. It is concluded from the results of our study that the abovementioned observations are an important factor to address in order to reduce the probable consequences before and during surgery.

## REFERENCES

- APOSTOLAKIS D, BISSOON AK (2014) Radiographic evaluation of the superior alveolar canal: measurements of its diameter and of its position in relation to the maxillary sinus floor: a cone beam computerized tomography study. *Clin Oral Implants Res*, 25: 553-559.
- ELLA B, SÉDARAT C, DA COSTA NOBLE R, NORMAND E, LAUVERJAT Y, SIBERCHICOT F, CAIX P, ZWETYENGAN N (2008) Vascular connections of the lateral wall of the sinus: surgical effect in sinus augmentation. *Int J Oral Maxillofac Implants*, 23(6): 1047-1052.
- FAYEK MM, AMER ME, BAKRY AM (2021) Evaluation of the posterior superior alveolar artery canal by cone-beam computed tomography in a sample of the Egyptian population. *Imaging Science in Dentistry*, 51: 35-40.
- GÜNCÜ GN, YILDIRIM YD, WANG HL, TÖZÜM TF (2011) Location of posterior superior alveolar artery and evaluation of maxillary sinus anatomy with computerized tomography: a clinical study. *Clin Oral Implants Res*, 22(10): 1164-1167.
- ILGÜY D, ILGÜY M, DOLEKOGLU S, FISEKCIOGLU E (2013) Evaluation of the posterior superior alveolar artery and the maxillary sinus with CBCT. *Braz Oral Res*, 27(5): 431-437.
- JUNG J, YIM JH, KWON YD, AL-NAWAS B, KIM GT, CHOI BJ, LEE DW (2011) A radiographic study of the position and prevalence of the maxillary arterial endosseous anastomosis using cone beam computed tomography. *Int J Oral Maxillofac Implants*, 26(6): 1273-1278.

KANG SJ, SHIN SI, HERR Y, KWON YH, KIM GT, CHUNG JH (2013) Anatomical structures in the maxillary sinus related to lateral sinus elevation: a cone beam computed tomographic analysis. *Clin Oral Implants Res*, 24(Suppl A100): 75-81.

KHAJEHAHMADI S, RAHPEYMA A, HOSEINI ZARCH SH (2014) Association between the lateral wall thickness of the maxillary sinus and the dental status: cone beam computed tomography evaluation. *Iran J Radiol*, 11: e6675.

KIAKOJORI A, NASAB S, ABESI F, GHOLINIA H (2017) Radiographic assessment of maxillary sinus lateral wall thickness in edentulous posterior maxilla. *Electronic Physician*, 9: 5948-5953.

MANJUSHRI WAINGADE, SOMESHWARI SALUNKHE, RAGHAVENDRA S MEDIKARI (2021) Assessment of position of posterior superior alveolar artery in relation to maxillary sinus using cone-beam computed tomography. *J Orofacial Sci*, 13: 105-113.

MARDINGER O, ABBA M, HIRSHBERG A, SCHWARTZ-ARAD D (2007) Prevalence, diameter and course of the maxillary intraosseous vascular canal with relation to sinus augmentation procedure: a radiographic study. *Int J Oral Maxillofac Surg*, 36(8): 735-738.

MONJE A, CATENA A, MONJE F, GONZALEZ-GARCÍA R, GALINDO-MORENO P, SUAREZ F, WANG HL (2014) Maxillary sinus lateral wall thickness and morphologic patterns in the atrophic posterior maxilla. *J Periodontol*, 85:676- 682.

RAJA SV (2009) Management of the posterior maxilla with sinus lift: review of techniques. *J Oral Maxillofac Surg*, 67: 1730-1734.

ROSANO G, TASCHIERI S, GAUDY JF, DEL FABBRO M (2009) Maxillary sinus vascularization: a cadaveric study. *J Craniofac Surg*, 20(3): 940-943.

SCHWARTZ-ARAD D, HERZBERG R, DOLEV E (2015) The prevalence of surgical complications of the sinus graft procedure and their impact on implant survival. *J Periodontol*, 75: 511-516.

TALO YILDIRIM T, GÜNCÜ G, COLAK M, TÖZÜM T, F (2019) The relationship between maxillary sinus lateral wall thickness, alveolar bone loss, and demographic variables: a cross-sectional cone-beam computerized tomography study. *Med Princ Pract*, 28: 109-114.

TARUN KUMAR AB, ANAND U (2015) Maxillary sinus augmentation. *J Int Clin Dent Res Organ*, 7, Suppl S1: 81-93.

VAN CAUWENBERGE P, SYS L, DE BELDER T, WATELET JB (2004) Anatomy and physiology of the nose and the paranasal sinuses. *Immunol Allergy Clin North Am*, 24: 1-17.

WALLACE SS, TARNOW DP, FROUM SJ, CHO SC, ZADEH HH, STOUPEL J, DEL FABBRO M, TESTORI T (2012) Maxillary sinus elevation by lateral window approach: evolution of technology and technique. *J Evid Based Dent Pract*, 12(Suppl 3): 161-171.

WATANABE T, SHIOTA M, GAO S, IMAKITA C, TACHIKAWA N, KASUGAI S (2014) Verification of posterior superior alveolar artery distribution in lateral wall of maxillary sinus by location and defect pattern. *Quintessence Int*, 45: 673-678.

WOO I, LE BT (2004) Maxillary sinus floor elevation: review of anatomy and two techniques. *Implant Dent*, 13: 28-32.

YANG SM, PARK SI, KYE SB, SHIN SY (2012) Computed tomographic assessment of maxillary sinus wall thickness in edentulous patients. *J Oral Rehabil*, 39: 421-428.

YU SJ, LEE YH, LIN CP, WU AYJ (2019) Computed tomographic analysis of maxillary sinus anatomy relevant to sinus lift procedures in edentulous ridges in Taiwanese patients. *J Periodontal Implant Sci*, 49(4): 237-247.

ZIJDERVELD SA, VAN DEN BERGH JP, SCHULTEN EA, TEN BRUGGENKATE CM (2008) Anatomical and surgical findings and complications in 100 consecutive maxillary sinus floor elevation procedures. *J Oral Maxillofac Surg*, 66: 1426-1438.