

# Two anatomical variations associated with potential vascular entrapment in the upper limb

S. Koshy, S. Rabi, I. Indrasingh and S. Vettivel

*Department of Anatomy, Christian Medical College, Vellore, India*

## SUMMARY

During routine dissection of the right upper limb of a South Indian male, aged 56, at this department, a supracondylar process was found, from which a fibrous arch extended to the medial intermuscular septum. A triple-headed pronator teres muscle arose by a narrow head from a supracondylar process, a bulky head from a fibrous arch, the medial intermuscular septum, and the medial supracondylar ridge of the humerus, and the other head from the coronoid process of the ulna. The brachial artery and median nerve crossed behind the supracondylar process and fibrous arch, enclosed in a supratrochlear foramen, reached the front of the elbow, and passed through the pronator teres between its bulky and coronoid heads. The cubital fossa was absent. The brachial artery divided into the radial, common interosseous, and ulnar arteries. The median artery was enlarged, arose from the anterior interosseous artery, and passed through the carpal tunnel. The superficial palmar arch was incomplete. Digital arteries from the ulnar artery supplied the medial three and a half fingers and those from the median artery supplied the lateral one and a half fingers. A phylogenetic, clinical and embryological interest of the anatomical variations in the case is presented.

**Key words:** Supracondylar process – Median nerve – Median artery – Pronator teres

## INTRODUCTION

The pronator teres muscle normally arises by a humeral head just proximal to the medial epicondyle from the common tendon of the flexor muscles and by an ulnar head from the medial side of the coronoid process (Salmons, 1995). At the elbow, the brachial artery sinks deeply and ends by dividing into the radial and ulnar arteries. In 83% of cases, the median nerve enters the forearm between the two heads of the pronator teres (Gabella, 1995).

The superficial palmar arch is mainly fed by the ulnar artery, passing superficially to the flexor retinaculum, then curving laterally to form an arch (Gabella, 1995). About one third of the superficial palmar arches is formed by the ulnar alone; another third is completed by the superficial palmar branch of the radial artery and the other third is completed either by the arteria radialis indicis, a branch of the arteria princeps pollicis, or by the median artery (Coleman and Anson, 1961). The median artery is a slender branch from the start of the anterior interosseous artery, and accompanies and supplies the median nerve; it is sometimes enlarged, reaching the palm with the median nerve, where it may join the superficial palmar arch or may end as one or two palmar digital arteries (Gabella, 1995). The aim of the paper is to present the variations in the case and discuss their clinical, phylogenetic, and embryological interest.

Correspondence to:  
Dr. Shajan Koshy, Department of Anatomy, Christian Medical College, Vellore 632 002, India.  
Telephone: 0416-2262603 ext. 4245/2344; Fax: 0091-416-2262788.  
E-mail: shajank@hotmail.com

Submitted: March 28, 2003  
Accepted: August 29, 2003

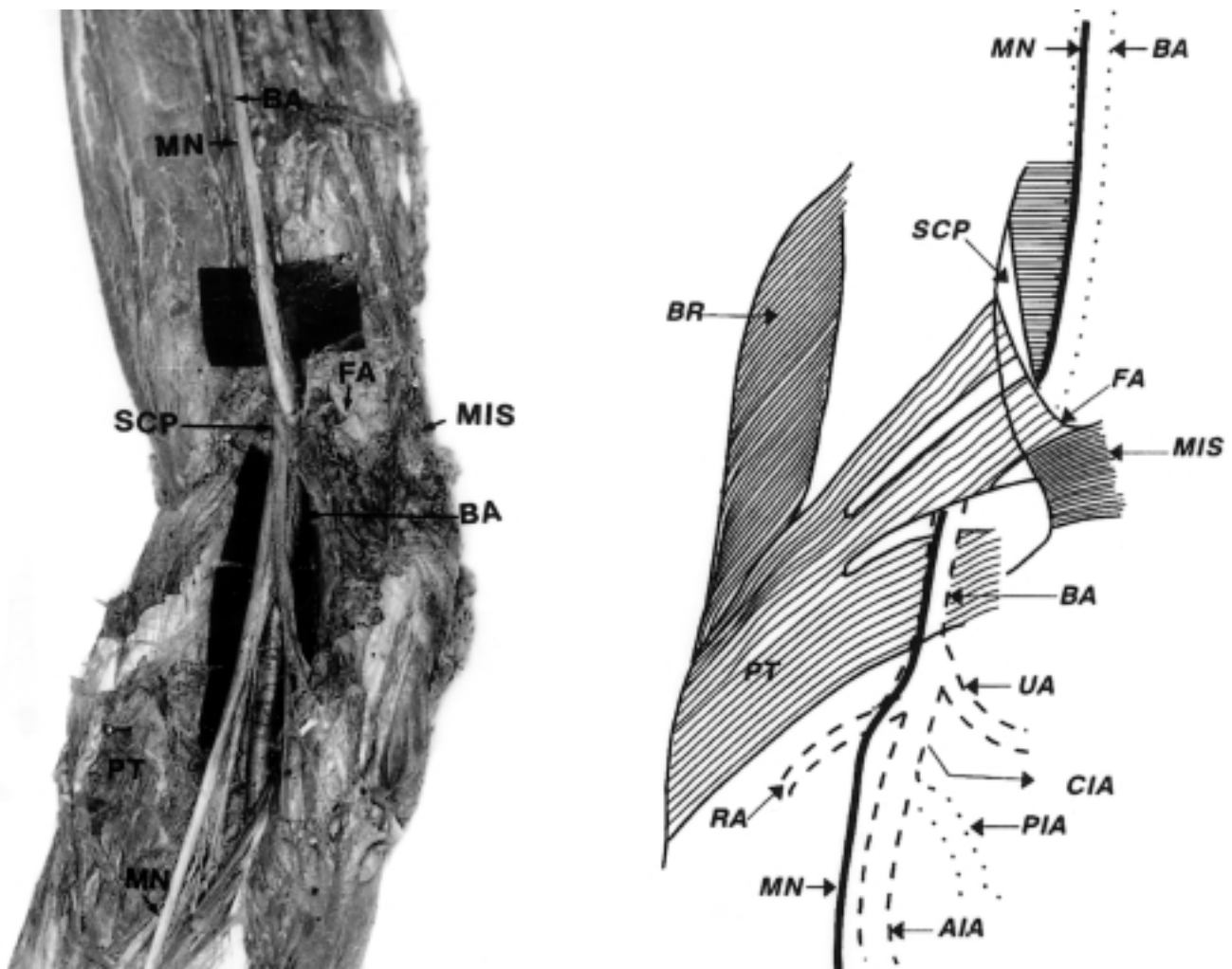
## OBSERVATIONS

During routine dissection of the right upper limb of a South Indian male, aged 56, by the medical students at this department, a supracondylar process was found, from which a fibrous arch extended to the medial intermuscular septum. The pronator teres muscle was fleshy and bulky and presented three heads: a narrow head arose from the supracondylar process; a bulky head from the fibrous arch, medial intermuscular septum and medial supracondylar ridge of the humerus, and the other head arose from the coronoid process of the ulna (Fig. 1).

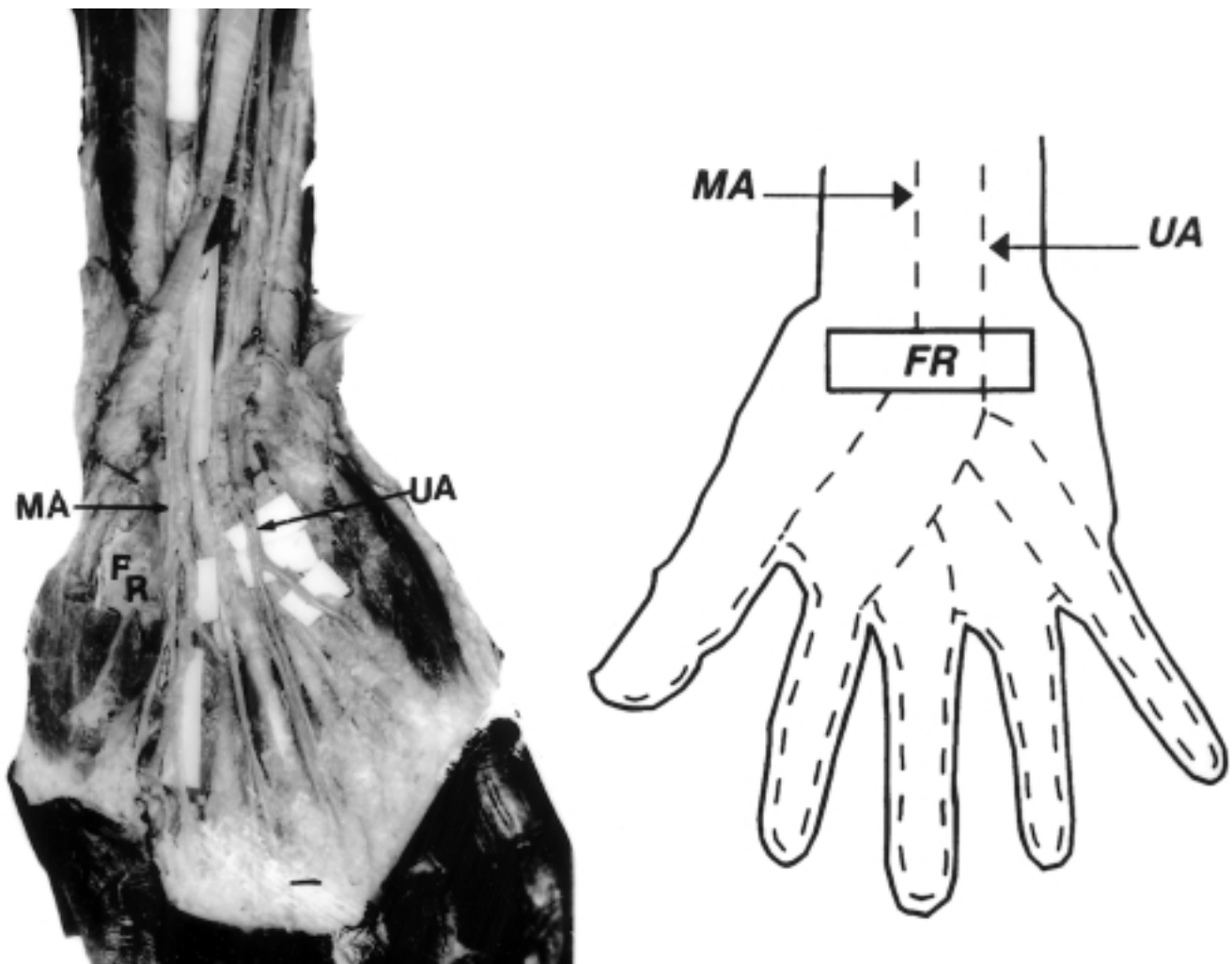
The brachial arterial tree was traced down to the superficial palmar arch but small branches were sacrificed. The brachial artery was medially displaced. The median nerve coursed distally in front of the axillary and brachial arteries. The brachial artery and median nerve crossed behind the supracondylar process and fibrous arch, passed through the hole between them and the

humerus, reached the front of the elbow (Fig. 1), passed through the pronator teres between its bulky and coronoid process heads, and were located medially in the substance of the muscle (Fig. 1). From a higher origin, the pronator teres took a straight course to its insertion. Therefore, it was close to the brachioradialis muscle and the cubital fossa was absent. Beyond the pronator teres, the brachial artery subdivided into the radial, common interosseous, and ulnar arteries (Fig. 1).

The ulnar artery formed an incomplete superficial palmar arch, which gave three common digital arteries for the adjacent sides of the medial four fingers and a proper digital artery for the medial side of the little finger (Fig. 2), similar to the 'type A superficial palmar arch' of Weathersby (1955). The median artery, from the anterior interosseous artery, was bilaterally large and continued deep to the flexor retinaculum in the carpal tunnel, forming a common digital artery, which divided into two digital arteries supplying



**Figure 1.** Triple-headed pronator teres muscle and the unusual course of the brachial artery and median nerve. MN - median nerve; BA - brachial artery; SCP - supracondylar process; FA - fibrous arch; MIS - medial intermuscular septum; BR - brachioradialis; PT - pronator teres; UA - ulnar artery; RA - radial artery; CIA - common interosseous artery; PIA - posterior interosseous artery; AIA - anterior interosseous artery.



**Figure 2.-** Course of the median artery and arterial distribution in the palm.  
 MA – median artery; FR – flexor retinaculum (partly removed); UA – ulnar artery.

the thumb and the radial side of the index finger (Fig. 2), as in other reports (MacCormack et al., 1953; Misra, 1955; Hennesberg and George, 1992).

#### COMMENTS

The supracondylar process, fibrous band (ligament of Struthers) and humerus form a foramen (Bergman et al., 1988). It is the homologue of the entepicondylar foramen or supratrochlear foramen of many animals (Soames, 1995). The coronoid attachment of the pronator teres may be absent; accessory slips may arise from a supracondylar process, the biceps brachii muscle, the brachialis muscle, or the medial intermuscular septum (Macalister, 1875; Testut, 1884; Thane, 1892; Le Double, 1897; Salmons, 1995). The pronator teres is attached to the supracondylar process and fibrous arch, when the course of brachial artery is usually changed (Salmons, 1995). The supratrochlear foramen encloses the brachial artery and median nerve. It

may be a site for entrapment of the brachial artery and median nerve (Nebot-Cegarra et al. 1992). The artery and nerve then run through the pronator teres to the forearm (Tountas and Bergman, 1993). This may be another site for their entrapment. This resembles the normal arrangement in Felidae, some carnivores, and many other animals (Thane, 1892; Gabella, 1995). A third head of the pronator teres, arising from the medial intermuscular septum and fused to the brachialis, overlapped the brachial artery and median nerve, which were not displaced (Barrett, 1936).

Since the cubital fossa is absent, the median nerve and brachial artery are more medial in the substance of the muscle; thus, probably no brachial pulse will be found in the cubital fossa, which would be of clinical significance. The brachial artery divides into the radial, ulnar and interosseous arteries, as in Thane (1892).

The median artery passes with the median nerve, deep to the flexor retinaculum and through the carpal tunnel. It is a site for its entrapment (Chalmers, 1978).

The axis artery and superficial brachial artery are involved in the morphogenesis of the arteries of the upper limb (Singer, 1933; Schwyzer and De Garis, 1935). The axis artery persists in the adult to form the axillary, brachial and interosseous arteries. Transiently, a median artery arises as a branch of the interosseous artery (Singer, 1933) and begins to regress, remaining as a residual artery and accompanying the median nerve. The superficial brachial artery gives two branches, a medial superficial antebrachial, and a lateral that continues as the radial artery (Vancov, 1961). The superficial antebrachial artery divides into the median and ulnar arteries (Vancov, 1961). These anastomose with the corresponding branches of the axis artery, which are the trunks of origin of the median and ulnar arteries. The trunks of deep origin predominate and the superficial arteries regress (Rodriguez-Niedenführ et al., 1999, 2001). The median artery takes part in the formation of the superficial palmar capillary plexus. When the median artery undergoes regression, this plexus is supported by a branch of the ulnar artery and radial artery and forms the superficial palmar arch. In the present case, the digital branches were from the median and ulnar arteries, with no communication between them. This means that the median-interosseous-ulnar trunk persists and hence an incomplete superficial palmar arch is present.

Variation in the branching pattern of the brachial artery is of clinical significance in cardiac catheterisation for angioplasty, pedicle flaps in plastic surgery, and arterial grafting of the brachial pulse. The presence of the supratrochlear foramen and triple-headed pronator teres and the associated entrapment of the brachial artery and median nerve, as well as the passage of the median artery and median nerve deep to the flexor retinaculum and through the carpal tunnel and their entrapment there, have a common interest: i.e., potential sites for clinical syndromes of compression in the supratrochlear foramen, the pronator teres muscle, and carpal tunnel. The presence of the median artery under the flexor retinaculum may cause symptoms of the carpal tunnel syndrome (Barfred et al., 1985).

## REFERENCES

- BARFRED T, HOJLUND AP and BERTHEUSSEN K (1985). Median artery in carpal tunnel syndrome. *J Hand Surg*, 10A: 864-867.
- BARRETT JH (1936). An additional (third and separate) head of the pronator teres muscle. *J Anat*, 70: 577-578.
- BERGMAN RA, THOMPSON SA, AFIFI AK and SAADEH FA (1988). Compendium of human anatomic variations. Urban & Schwarzenberg, Baltimore, pp 206.
- CHALMERS J (1978). Unusual cases of peripheral nerve compression. *The Hand*, 10: 168-175.
- COLEMAN SS and ANSON BJ (1961). Arterial patterns in the hand based upon a study of 650 specimens. *Surg Gynecol Obstet*, 113: 409-424.
- GABELLA G (1995). Cardiovascular system. In: WILLIAMS PL (ed). *Gray's Anatomy*. 38<sup>th</sup> ed. Churchill Livingstone, Edinburgh, pp 1538-1544.
- HENNESBERG M and GEORGE BJ (1992). A further study of the high incidence of the median artery of the forearm in Southern Africa. *J Anat*, 181: 151-154.
- LE DOUBLE AF (1897). Traite des variations musculaire de l'homme et de leur signification an point de l'anthropologie zoologique, vol. 1. Librairie C. Reinwald, Schleicher Freres, Paris, pp 79-82.
- MACALISTER A (1875). Additional observations on muscular anomalies in human anatomy (3<sup>rd</sup> series) with a catalogue of the principal muscular variations hitherto published. *Transactions of the Royal Irish Academy*, 25: 1-134.
- MACCORMACK LF, CAULDWELL EW and ANSON BW (1953). Brachial and antebrachial arterial patterns. A study of 750 extremities. *Surg Gynecol Obstet*, 96: 43.
- MISRA BD (1955). The arteria mediana. *J Anat Soc India*, 4: 48.
- NEBOT-CEGARRA J, PEREZ-BERRUEZO J and REINA DE LA TORRE F (1992). Variations of the pronator teres muscle: predispositional role to median nerve entrapment. *Arch Anat Hist Emb Nor et Exp*, 74: 35-45.
- RODRIGUEZ-NIEDENFÜHR M, SAÑUDO JR, VAZQUEZ T, NEARN L, LOGAN B and PARKIN I (1999). Median artery revisited. *J Anat*, 195: 57-63.
- RODRIGUEZ-NIEDENFÜHR M, BURTON GJ, DEU J and SAÑUDO JR (2001). Development of the arterial pattern in the upper limb of staged human embryos: normal development and anatomic variations. *J Anat*, 199: 407-417.
- ROIG M (1995). An anatomical study and ontogenetic explanation of 23 cases with variations in the main pattern of the human brachio-antebrachial arteries. *J Anat*, 187: 473-479.
- SALMONS S (1995). Muscle. In: Williams PL (ed). *Gray's Anatomy*. 38<sup>th</sup> ed. Churchill Livingstone, Edinburgh, pp 846.
- SCHWYZER AG and DE GARIS CF (1935). Three diverse patterns of the arteria brachialis superficialis in man. *Anat Rec*, 63: 405-416.
- SINGER E (1933). Embryological pattern persisting in the arteries of the arm. *Anat Rec*, 55: 403-409.
- SOAMES RW (1995). Skeletal system. In: Williams PL (ed). *Gray's Anatomy*. 38<sup>th</sup> ed. Churchill Livingstone, Edinburgh, pp 626.
- THANE GD (1892). Arthrology - Myology - Angiology. In: SCHAFER EA, THANE GD (eds). *Quain's Elements of Anatomy*. 10<sup>th</sup> ed. Longmans, Green and Co., London, pp 223-224, 439-441.
- TOUNTAS CP and BERGMAN RA (1993). Anatomic variations of the upper extremity. Churchill Livingstone, New York, pp 137-138.
- VANCOV V (1961). Une variete extremement complexe des arteres du membre superieur chez un foetus humain. *Anat Anz*, 109: 400-404.
- WEATHERSBY HT (1954). The volar arterial arches. *Anat Rec*, 118: 365.