

# Embryological basis of coarctation in cervical aortic arch: Ductus caroticus anomaly

Sudesh Prabhu<sup>1</sup>, Siddhant Mehra<sup>1</sup>, Shreesha Maiya<sup>2</sup>, Colin John<sup>1</sup>

<sup>1</sup>Dept of Paediatric Cardiac Surgery, Narayana Institute of Cardiac Sciences, Bengaluru, India

<sup>2</sup>Dept of Paediatric Cardiology, Narayana Institute of Cardiac Sciences, Bengaluru, India

## SUMMARY

Coarctation of the cervical aortic arch (CAA), though rare, is a clinical entity of embryological significance. Based on Rathke's aortic arch diagrams and Edward's concept of functioning double aortic arch, we are postulating that the coarctation in a CAA occurs due to partial involution of the dorsal aorta developed from the "ductus caroticus". Hence coarctation in CAA should be classified as a "clinically significant aortic arch anomaly of ductus caroticus origin". Conversely, location of coarctation in CAA substantiates the theory that embryogenesis of CAA is due to aortic arch development from the third or second branchial arch vessel, rather than the usual fourth arch vessel.

**Key words:** Cervical aortic arch – Coarctation – Ductus caroticus anomaly – Rathke's aortic arch diagram

## INTRODUCTION

Cervical aortic arch (CAA) is defined as the anomaly where the ascending aorta arises normally from the left ventricle and extends in such a fashion that the aortic arch is situated high in the neck on either side (Shuford et al., 1972). CAA

was classified into five distinct forms based on configuration of the aorta, sequence of brachiocephalic branching and embryogenesis, known as Haughton classification (Haughton et al., 1975). There are many theories which explain the causation of CAA, but one of the common explanations is that, when the aortic arch develops from second or third branchial arch vessel instead of the usual fourth arch vessel, it leads to CAA. Most common clinical scenarios arising because of CAA are due to the pressure symptoms on the surrounding structures, aneurysm (Baravelli et al., 2007), internal carotid artery insufficiency (Elualai et al., 2016) and coarctation of the arch (Tiraboschi et al., 1980).

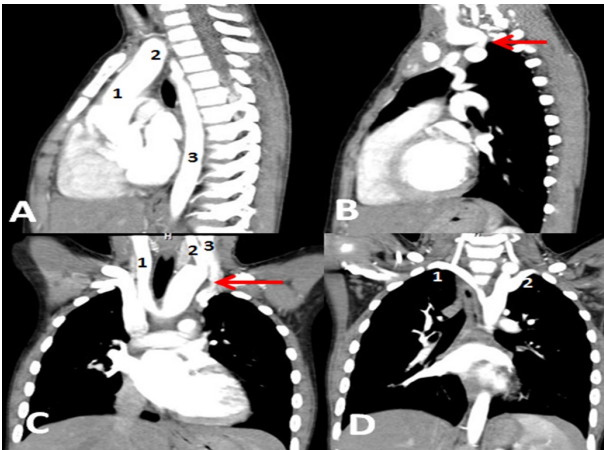
A portion of the aortic arch in CAA is formed by the ductus caroticus (embryonic dorsal aorta between points of junction with the third and fourth branchial arch). Based on Rathke's aortic arch diagrams and Edward's concept of functioning double aortic arch (Edwards, 1948), we are postulating that the coarctation in a CAA occurs due to partial involution of dorsal aorta developed from ductus caroticus.

## CASE REPORT

A 6-year-old boy weighing 20 kg presented with bilateral calf muscle claudication. Examination revealed pulsating mass and murmur in the neck. Bilateral lower limb pulses were weak. Echocardiography demonstrated a long ascending aorta

**Corresponding author:** Sudesh Prabhu. Paediatric Cardiac Surgeon, Narayana Institute of Cardiac Sciences, 258/A Hosur Road, Bommasandra Industrial Area, Anekal Taluk, Bengaluru 560099, Karnataka, India. Mobile: +919886899450.  
E-mail: sudesh006@gmail.com

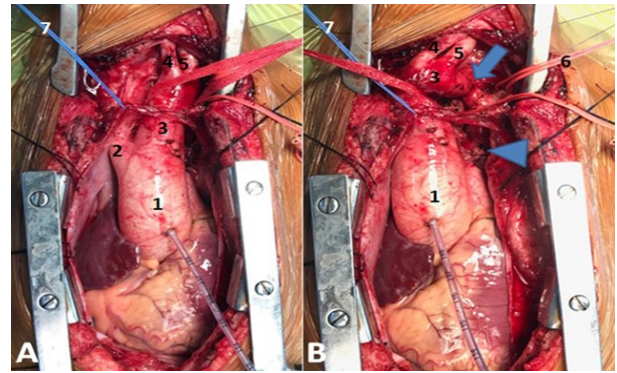
Submitted: 15 May, 2020. Accepted: 31 August, 2020.



**Fig 1.** Cardiac CT scan. **A** – Sagittal plane demonstrating ascending aorta (1), cervical aortic arch (2) and descending aorta (3). **B** – Coarctation segment is pointed with an arrow. **C** – Coronal plane demonstrating right common carotid artery (1) as the first branch, followed by left external (2) and internal (3) carotid arteries, coarctation segment is pointed with an arrow. **D** - Left subclavian artery (2) can be seen arising distal to coarctation segment and aberrant right subclavian artery (1) is the last branch.

(diameter = 17mm) with steep curving transverse arch (diameter = 6mm) with a coarctation segment (diameter = 2 mm) just distal to left carotid artery with a gradient of 77/24 mm Hg with complete diastolic spillage. There was no obstruction in origins of aortic arch branches. Computerized tomography (CT scan) demonstrated a cervical aortic arch with short segment (10 mm) coarctation (diameter = 2 mm). The arch vessels in order were the right common carotid artery, the left external carotid artery, the left internal carotid artery, the left subclavian artery, and an aberrant right subclavian artery. The coarctation segment was just distal to the left internal carotid artery. Multiple arterial collaterals were seen in the neck and upper chest wall (Fig. 1).

Under general anaesthesia with monitoring lines in situ (femoral arterial and central line), median sternotomy was performed, with incision extending to left neck at the anterior border of sternocleidomastoid. The pericardium was opened and marsupialized. Aortic root pressure monitoring line was placed. A gradient of 80 mm Hg was found between the ascending aorta and the femoral arterial line. The ascending aorta and the arch vessels were dissected and looped (Fig. 2). The ligamentum was divided. The arch was clamped distal to the right common carotid artery. The left external carotid artery, the left internal carotid artery, and the left subclavian artery were snared individually. The coarctation segment was resected and end-to-end anastomosis was performed abolishing the gradient. The incision was closed routinely and the patient was transferred to the intensive care unit. The child was extubated uneventfully after overnight ventilation. Post-operative echocardiography



**Fig. 2.-** Intra-operative photographs of CAA with coarctation. 1 - ascending aorta, 2 - right common carotid artery, 3 - arch of aorta, 4 - left external carotid artery, 5 - left internal carotid artery, 6 - loop around the left subclavian artery, 7 - loop around the innominate vein, right subclavian artery is aberrant. Arrow – coarctation segment, arrow-head – divided ligamentum.

demonstrated no narrowing or turbulence in the arch. Histology was consistent with coarctation (Fig. 3). There was no residual lesion on echocardiography at one-year follow-up.

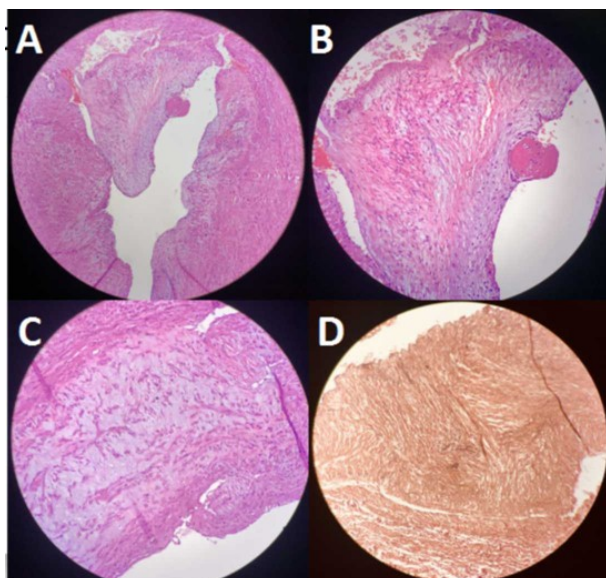
Parental consent was obtained for publication and the ethics committee of Narayana Institute of Cardiac Sciences approved the same (NHH/AEC-CL-2020-472).

## COMMENTS

The ductus caroticus is the embryonic dorsal aorta at the junction of the third and fourth branchial arch. It normally disappears in early embryonic life (at embryo size of 12 to 14 mm). Persistent ductus caroticus can form ligamentum caroticum (when it persists as a thin strand of tissue without a lumen), or arteria muscularis cervicis (short communicating vessel with a lumen), or can form a portion of cervical aortic arch (Moncada et al., 1975).

Juxta ductal coarctation (CoA) occurs due to the narrowing of the aortic arch at its junction with the descending aorta, and there are multiple theories explaining the pathogenesis (Backer et al., 2013). Widely accepted among these is the “ductal sling theory”, which has clinical and histological evidence. This proposes that the CoA is due to the ductal tissue extending into the adjacent aorta in the form of a circumferential sling. Contraction and fibrosis of this ductal sling at the time of ductal closure leads to constriction of the aorta and a primary coarctation.

In the cases of CAA in which a ligament or ductus was documented, it arose from the upper descending aorta and extended to the ipsilateral pulmonary artery. The descending aorta is beyond the origin of the subclavian artery, and if ductal tissue is to cause coarctation, it should be in the juxta ductal area. Hence pathogenesis of juxta ductal coarctation cannot be extrapolated to coarctation in CAA, as the narrowing in CAA occurs be-



**Fig. 3.-** Histology demonstrating intimal thickening along with increased fibro elastic tissue with formation of ridges protruding into the lumen (A). The intimal thickening is in the form of laminations of collagen and elastic fibers lying parallel with the media and the luminal surface lined by unremarkable endothelium (B). There is scarring of the media (confirmed on Masson's trichrome stain) (C and D). There is no inflammation and no atherosclerosis.

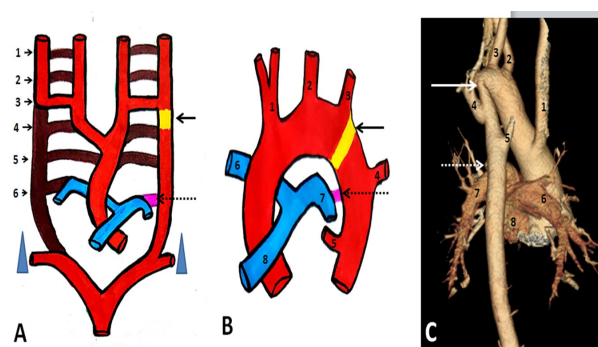
tween the carotid artery and subclavian artery. This leads us to consider an embryological basis rather than accept the acquired ductal sling theory for coarctation in CAA.

Edwards' concept with the help of Rathke's diagram of aortic arch can be used to explain the embryologic basis of coarctation in CAA (Edwards, 1948). Here the involution of the portion of dorsal aorta which has developed from ductus caroticus causes narrowing and coarctation of aorta (Fig. 4). Hence CoA in CAA should be classified as "clinically significant aortic arch anomaly of ductus caroticus origin".

Both the cases in Tiraboschi et al. (1980) had narrowing in the portion of the arch that has originated from ductus caroticus. One patient had right cervical aortic arch with narrowing between right common carotid artery and right subclavian artery in a right aortic arch. The second patient with left cervical aortic arch, narrowing was between left common carotid artery and left subclavian artery, the portion that has developed from ductus caroticus.

### Conclusion

Coarctation in cervical aortic arch occurs due to partial involution of a portion of the dorsal aorta which has developed from the ductus caroticus. Hence coarctation in CAA should be classified under "clinically significant aortic arch anomaly of ductus caroticus origin".



**Fig. 4.-** Embryological origin of cervical aortic arch (CAA) in our patient explained with the help of Rathke's diagram with computed tomography (CT scan) correlating with our findings. **A** – Rathke's aortic arch diagram showing 1 to 6 primitive arches, Arrow pointing to the ductus caroticus on the left (yellow) and broken arrow pointing to the distal left sixth arch leading to formation of the ductus (pink). The brown colored portion will disappear and the red colored portion will form the future aorta and its branches. **B** – After the formation of CAA, arrow pointing at the portion of the CAA that has developed from ductus caroticus (yellow) and the broken arrow pointing at the ductus (pink). **C** – CT scan with 3D reconstruction (posterior oblique view) arrow pointing at the coarctation segment and the broken arrow pointing at the ductus. (1 – right common carotid artery, 2 – left external carotid artery, 3 – left internal carotid artery, 4 – left subclavian artery, 5 – right aberrant subclavian artery). The distance between the ductus and arch narrowing is quite obvious.

### REFERENCES

- BACKER CL, KAUSHAL S, MAVROUDIS C (2013) Coarctation of the aorta. In: Mavroudis C, Backer CL (eds). *Pediatric Cardiac Surgery*, 4th edition, Blackwell Publishing Ltd, pp 256-282.
- BARAVELLI M, BORGHI A, ROGIANI S, PREDAL, QUATTROCIOCCHI M, FANTONI C, CRUPI G, TIRABOSCHI R (2007) Clinical, anatomopathological and genetic pattern of 10 patients with cervical aortic arch. *Int J Cardiol*, 114(2): 236-240.
- EDWARDS JE (1948) Anomalies of the derivatives of the aortic arch system. *Med Clin North Am*, 32: 925-949.
- ELUALAI G, CHODISETTY S, USEN BO, PATEL RD (2016) "Patent ductus caroticus" embryological basis and its clinical significance. *Elixir Physio & Anat*, 98: 42439-42442.
- HAUGHTON VM, FELLOWS KE, ROSENBAUM AE (1975) The cervical aortic arches. *Radiology*, 114(3): 675-681.
- MONCADA R, SHANNON M, MILLER R, WHITE H, FRIEDMAN J, SHUFORD WH (1975) The cervical aortic arch. *Am J Roentgenol Radium Ther Nucl Med*, 125(3): 591-601.
- SHUFORD WH, SYBERS RG, MILLEDGE RD, BRINSFIELD D (1972) The cervical aortic arch. *Am J Roentgenol Radium Ther Nucl Med*, 116(3): 519-527.
- TIRABOSCHI R, CRUPI G, LOCATELLI G, HO SY, PARENZAN L (1980) Cervical aortic arch with aortic obstruction: report of two cases. *Thorax*, 35(1): 26-30.