

# Meniscal ossicle. Cadaveric and imaging cases report

Germán Gutiérrez<sup>1,2</sup>, Camila Rodríguez<sup>1</sup>, María Ignatov<sup>1</sup>

<sup>1</sup>Departamento de Anatomía, Facultad de Medicina, Universidad de la República, Montevideo, Uruguay

<sup>2</sup>Departamento Clínico de Imagenología, Hospital de Clínicas, Universidad de la República, Montevideo, Uruguay

## SUMMARY

Meniscal ossicles are small fragments of cancellous bone containing bone marrow surrounded by meniscal cartilage. Two cases of meniscal ossicle are reported, one found during routine dissection of the knee joint and the other as an incidental finding on magnetic resonance imaging (MRI). It is a rare entity and is usually located in the posterior horn of the medial meniscus. Cases have been reported since the 1930s in imaging methods. Its association with meniscal tear is common, as it occurred in the reported case. Its origin is discussed, proposing that they may represent vestigial remnants of development or that they have a post-traumatic origin. They are usually asymptomatic, being an exceptional cause of knee pain. MRI is the method of choice for its evaluation, allowing to distinguish a meniscal ossicle from other intra-articular entities, such as a free body or an intrameniscal calcification. A review of the literature is also presented.

**Key words:** Knee joint – Tibial meniscus injuries – Magnetic resonance imaging

## INTRODUCTION

Meniscal ossicles of the knee are rare findings in humans, being common in other species such as rodents, domestic cats and Bengal tigers (Tuite et al., 1995). They consist of fragments of cancellous bone containing bone marrow, covered by lamellar

bone, totally surrounded by the meniscal cartilage (Rohilla et al., 2009).

Meniscal ossicles were first described by Burrows in 1934, who reported two cases encountered on plain radiography. A retrospective review carried out in 2003 (Prabhudesai and Richards) identified 52 publications up to that time. In the orthopedic literature, the largest case series reported ten cases (Weaber, 1942), whereas the largest series in the radiologic literature described six cases (Schnarkowski et al., 1995). This last article is based on 1287 Magnetic Resonance Imaging (MRI) studies, reporting a prevalence of 0,15%, being more frequent in young men.

Meniscal ossicles are generally asymptomatic, being found incidentally in imaging methods, since they represent an exceptional cause of knee pain. They are usually located in the posterior horn of the medial meniscus, its location in the other meniscus being rare. They can cause or be associated with a posterior-traumatic meniscal tear (Seema et al., 2009).

MRI is the non-invasive imaging method of choice for its evaluation, as it confirms its situation within the substance of the meniscus and the presence of cortical and cancellous bone tissue. In addition, it is the method that differentiates a meniscal ossicle from other diagnoses, such as loose bodies, meniscal calcifications, osteochondritis dissecans, chondrocalcinosis, semimembranous or popliteal tendon avulsion (Bernard et al., 2019). The first description in which the diagnosis was made with MRI was in 1993 (Yao and Yao).

## CASE REPORT

Firstly, a cadaveric case is presented, in which a meniscal ossicle was found during the usual dis-

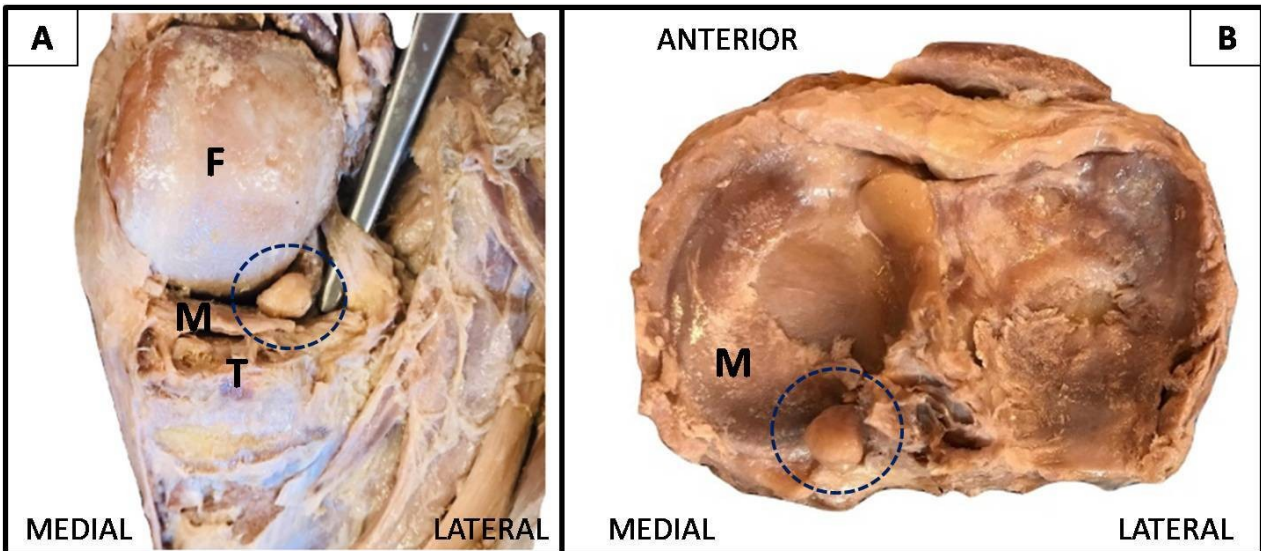
---

**Corresponding author:** Germán Gutiérrez. Universidad de la República, Departamento de Anatomía, Facultad de Medicina, Luis Cavia 3071/902, Montevideo 11300, Uruguay. Phone: 59891027882.

E-mail: ggutierrez@fmed.edu.uy

---

Submitted: 28 February 2020. Accepted: 30 April, 2020.



**Fig 1.** Cadaveric case. Right knee. **A.** Posterior view. **B.** Superior view. F: medial femoral condyle. T: medial tibial condyle. M: medial meniscus. Circle: meniscal ossicle.

section of the knee joint. It is a small ossicle, measuring 9 mm (length), 7 mm (height) and 6 mm (width), that is located within the posterior horn of the medial meniscus, which is thinned (Fig. 1).

Secondly, the case of an 83-year-old male patient with bilateral knee osteoarthritis diagnosed by simple plain radiography is presented. During the evolution, an MRI of both knees was requested to evaluate possible meniscus pathology, which was confirmed by finding degenerative tears in the posterior horn of the medial meniscus of both knees (finding not shown). In the right knee, a small bone formation measuring 6 mm (length), 6 mm (height) and 4 mm (width) is located within the posterior horn of the medial meniscus, with a continuous cortical layer of low signal in all the sequences, similar to the cortical of the adjacent bone; and a high internal signal on T1 weighted images, with homogeneous sign suppression on proton-density weighted images with fat suppression. This finding is consistent with a meniscal ossicle (Fig. 2).

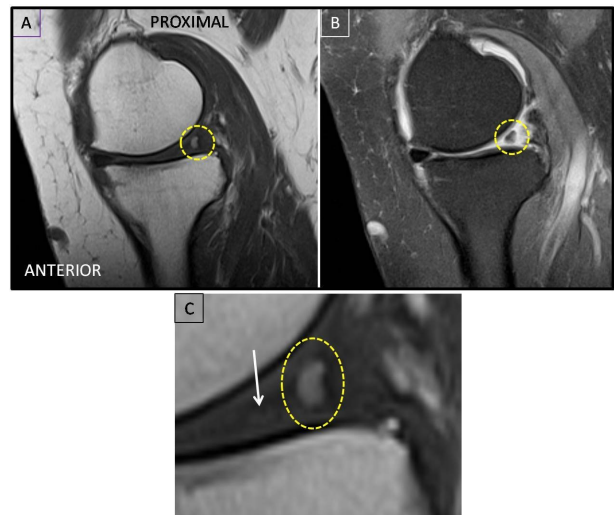
**COMMENTS**

The etiology of meniscal ossicles is discussed and has not been clearly defined. One hypothesis suggests that they are vestigial structures, which is supported by their presence in other species such as rodents (Pederson, 1949). Other authors hold the hypothesis of a post-traumatic origin, after either simple or repeated trauma. This would generate mucoid degeneration or meniscal tear, resulting in heterotopic ossification (Mohankumar, 2014). This hypothesis is based on observations that showed the association between these ossicles and meniscal tears, particularly of the posterior horn, similar to the case reported. This is thought to be secondary to the abundant vascularity of the area, predisposing damaged meniscal

tissue to dystrophic ossification.

Clinically, they are usually asymptomatic. Symptoms appear when the meniscus shape is secondarily altered, increasing the risk of rupture or degeneration. The most common symptom is intermittent pain, but it can also manifest with swelling and joint effusion (Yao and Yao, 1993). Mechanical locking is usually not a typical feature of a meniscal ossicle, unlike an intraarticular loose body (Van Breuseghem et al., 2003).

A meniscal ossicle is treated surgically if only symptomatic, and a limited excision of the lesion by arthroscopy is the treatment of choice (Kato et al., 2007).



**Fig 2.** MRI of right knee. Circle: meniscal ossicle. **A.** Sagittal T1 weighted image. **B.** Sagittal protonic-density weighted image with fat suppression. **C.** Enlarged sagittal T1 image, where ossicle high internal signal is better appreciated, delimited by a layer of cortical tissue of low signal, located within the medial meniscus posterior horn (arrow).

Radiologically, the plain radiography demonstrates the trabecular structure typical of the ossicle, which allows its differentiation with meniscal calcification. Intra-articular free bodies and osteochondritis dissecans are entities that can mimic a meniscal ossicle, but the latter are usually accompanied by a bone or cartilaginous defect, its differentiation being difficult when this associated finding does not occur (Prabhudesai and Richards, 2003).

MRI is the non-invasive imaging method of choice for its assessment, taking in consideration that arthroscopy remains the reference standard for the diagnosis of knee internal injuries (Crawford et al., 2007). In MRI, meniscal ossicles show fat marrow signal and trabecular structure, typical characteristics of spongy bone, thus distinguishing them from meniscal calcification, in addition to demonstrating its location within the meniscus substance.

Therefore, a fatty bone marrow signal is typically seen on T1 weighted images, and homogeneous suppression of signal on fat-suppressed images, matching with the adjacent bone signal in all sequences (Tuite et al., 1995).

As a summary, and in agreement with the majority of the reports, the location of the ossicle of each reported case was typical, having the distinctive characteristics in MRI. In regard to the report of the cadaveric case, no similar reports were found in the literature.

### Conclusion

Meniscal ossicles are a rare finding in imaging methods, usually located in the posterior horn of the medial meniscus, and are generally asymptomatic. MRI is the non-invasive imaging technique of choice for its evaluation. Their characteristics and typical location confirm the diagnosis, and allow us to distinguish them from other intra-articular entities such as osteochondral free bodies, dissecting osteochondritis, meniscal calcifications or avulsion fractures.

### ACKNOWLEDGEMENTS

We gratefully acknowledge the help and support rendered by Dr. Eduardo Corchs, Prof. Adj. of Radiology. We are also grateful to the donors who have graciously gifted their bodies to our institution for research and medical education.

### REFERENCES

- BERNARD CD, McGAUVVRAN AM, DESAI VS, FRICK MA, TIEGS-HEIDEN C, CAMP CL, KRYCH A, COLLINS MS (2019) Understanding the implications of the meniscal ossicle: patient presentation, treatment, and outcomes. *J Knee Surg*, Aug 7 doi: 10.1055/s-0039-1693724.
- BURROWS HJ (1934) Two cases of ossification in the internal semilunar cartilage. *Br J Surg*, 21(83): 404-410.
- CRAWFORD R, WALLEY G, BRIDGMAN S, MAFFULLI N (2007) Magnetic resonance imaging versus arthroscopy in the diagnosis of knee pathology, concentrating on meniscal lesions and ACL tears: a systematic review. *Br Med Bull*, 84: 5-23.
- KATO Y, OSHIDA M, SAITO A, RYU J (2007) Meniscal ossicles. *J Orthop Sci*, 12: 375-380.
- MOHANKUMAR R, PALISCH A, KHAN W, WHITE LM, MORRISON WB (2014) Meniscal ossicle: posttraumatic origin and association with posterior meniscal root tears. *AJR Am J Roentgenol*, 203(5): 1040-1046.
- PEDERSON HE (1949) The ossicles of the semilunar cartilages of rodents. *Anat Rec*, 105: 1-9.
- PRABHUDESAI V, RICHARDS P (2003) Radiological appearance as a meniscal ossicle develops: a case report and review of literature. *Injury*, 34: 378-382.
- ROHILLA S, YADAV RK, SINGH R, DEVGAN A, DHAULAKHANDI DB (2009) Meniscal ossicle. *J Orthop Traumatol*, 10(03): 143-145.
- SEEMA R, YADAV RK, SINGH R, DEVGAN A, DHAULAKHANDI DB (2009) Meniscal ossicle. *J Orthopaed Traumatol*, 10: 143-145.
- SCHNARKOWSKI P, TIRMAN PF, FUCHIGAMI KD, CRUES JV, BUTLER MG, GENANT HK (1995). Meniscal ossicle: radiographic and MR imaging findings. *Radiology*, 196: 47-50.
- TUITE MJ, DE SMET AA, SWAN JS, KEENE J (1995) MR imaging of a meniscal ossicle. *Skeletal Radiol*, 24: 543-545.
- VAN BREUSEGHEM I, GEUSENS E, PANS S, BRYNS P (2003) The meniscal ossicle revisited. *JBR-BTR*, 86: 276-277.
- WEAVER JB (1942) Calcification and ossification of the menisci. *J Bone Joint Surg Am*, 24: 873-882.
- YAO J, YAO L (1993) Magnetic resonance imaging of a symptomatic meniscal ossicle. *Clin Orthop*, 293: 225-228.