

Duplication of the radial artery - a case report

Rajasekar S. Salem and Shivali Srivastava*

Department of Anatomy, Sri Manakula Vinayagar medical College and Hospital, Kalitheerthalkuppam, Puducherry, India

SUMMARY

During routine dissection of a 65-year-old male cadaver, for undergraduate students of Sri Manakula Vinayagar Medical College and Hospital, we came across a rare anatomical variation of vasculature of the left forearm. Four centimeters below the bifurcation of the brachial artery, the radial artery split into a medial and a lateral branch. Both the branches ran individually for a distance of eight centimeters before reuniting to form a single artery once again.

Key words: Radial artery – Variation

INTRODUCTION

According to Bergman et al. (1988), a high origin of the radial artery is seen in 15% cases and that of ulnar artery in 2% cases, usually form the middle third portion of the brachial artery. A superficial, tortuous radial artery arising from the medial side of the brachial artery has been reported (Shetty et al., 2012). Rodriguez- Niedenfuhr et al. (2003) named the radial artery arising in the arm as the brachioradial artery. The radial artery has been reported to arise from the axillary artery also. A case of high bifurcation of the brachial artery with reunion at the elbow has also been reported (Harrington, 1905). Another frequent variation is a superficial radial artery seen in 14.26% of cadaveric cases and 9.75% of angiographic studies (Karlsson and Niechajev, 1982). A case where the radial artery divided into medial and lateral branch-

es, 1.5 cm below the bifurcation of the brachial artery, was reported (Bhatt et al., 2009).

CASE REPORT

During routine dissection of a 65-year-old formalin-embalmed male cadaver for undergraduate students of Sri Manakula Vinayagar Medical College and Hospital, a rare anatomical variation of the radial artery was noted in the left forearm.

In the left upper extremity, the brachial artery bifurcated into the radial and ulnar artery at the level of the neck of the radius. However four centimeters distal to this bifurcation, the radial artery split into a medial and lateral branch (Fig. 1). Both the branches ran individually for a distance of eight centimeters. The superficial branch of radial nerve was seen traversing between the two branches of the radial artery. The two branches then reunited and travelled as a single artery for a distance of six centimeters before reaching the lower end of the radius. Both the branches – the medial and lateral – gave many muscular branches throughout their course.

COMMENTS

Radial artery anatomical variations are commoner than brachial or ulnar artery variations (Ciervo, 2001). Amongst several kinds of variations, a real duplication has only been reported once (Kadanoff & Balkansky, 1966). Other patterns considered as duplication are unusual cases in which two radial arteries are present, each one supplying a different territory (Sankott, 1919, 1920). A case with double radial artery in a radial forearm flap was noted (Bumbasirević et al., 2005). Another case of superficial radial artery which bifurcated from the deep radial artery 4 cm below the antecubital fossa was recorded (Sasaki et al., 2000). Yet another pattern

Corresponding author: Shivali Srivastava. Department of Anatomy, Sri Manakula Vinayagar medical College and Hospital, Kalitheerthalkuppam, Puducherry- 605107, India.

Tel: +919626493881. E-mail: srivastavashimi@gmail.com / ssrajasekar7@gmail.com

Submitted: 20 November, 2013. Accepted: 20 January, 2014.

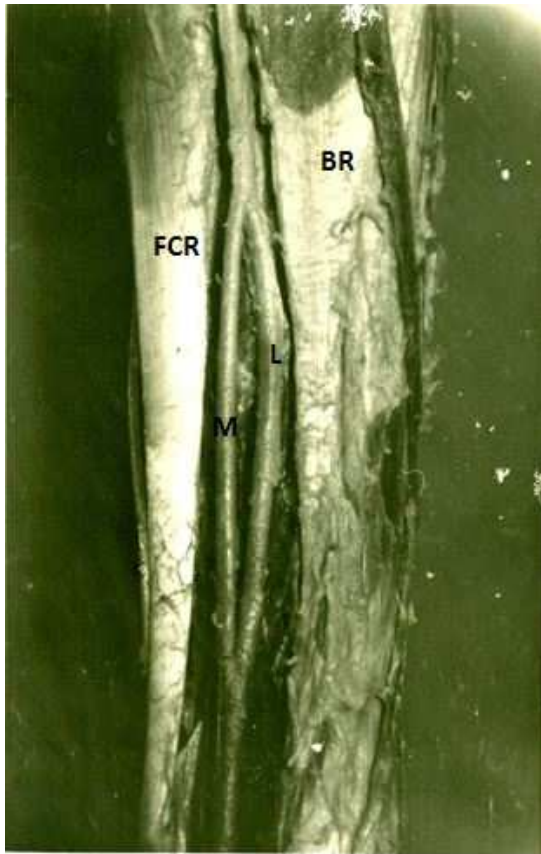


Fig. 1. View of the left forearm showing the splitting of the radial artery (FCR- flexor carpi radialis, BR- Brachioradialis, L- lateral branch of split radial artery, M- medial branch of split radial artery).

noted was a case where a proximal radial artery was seen originating from the brachial, supplying the upper third of the forearm, while a distal radial artery originated from the anterior interosseous supplying the normal branches of the radial in the distal third of the forearm and hand was reported (Sankott, 1919). In a report by Thomson (1884), it was suggested that the proximal artery may be considered as the radial recurrent, and the distal, a substitute for the absent radial artery. A very rare case of absence of the radial artery, with the brachial artery dividing into ulnar and common interosseous artery, was also recorded (Suganthi et al., 2002). Similar cases with absence of the radial artery have also been reported (Charles, 1894; Poteat, 1986).

In a study by Rodríguez-Niedenführ et al. (2001) it has been suggested that the arterial pattern of the upper limb develops from an initial capillary plexus by a proximal to a distal differentiation (in the forearm with a posterior-anterior polarity) due to the maintenance, enlargement and differentiation of certain capillary vessels, and the regression of others; it is also suggested in this study that the arterial variations may be explained on the basis of this theory by modifications of the normal pattern of capillary maintenance and regression.

Appreciation of the variations in the upper extremity and even lower extremity vasculature is important to prevent injury. This is especially significant to patients undergoing dialysis or even simple procedures such as IV drug administration or IV cannulation (Ciervo 2001).

Accidental cannulation of the radial artery has also been reported. In a report by Francis and Martin, details of an unintentional cannulation of an aberrant radial artery have been discussed (Whalen and Martin, 2011). Such incidences can lead to dire consequences unless diagnosed and treated immediately. A very simple recommendation would be to palpate for a pulse over what appears to be a vein before cannulation or injection.

In maxillofacial surgery, the radial forearm free flap reconstruction is a standard procedure. It is one of the most commonly harvested free tissues for reconstruction following surgical ablation of oropharyngeal cancer (Bhatt et al., 2009). There are some variations of the radial artery that may jeopardize the vascularity of the radial forearm free flap or the hand. Surgeons performing such procedures must always be vigilant to the possibility of aberrations such as these.

REFERENCES

- BERGMAN RA, THOMSON SA, AFIFI AK, SAADEH FA (1988) Compendium of human anatomic variation. Catalog, Atlas and World Literature. Urban & Schwarzenberg, Baltimore, pp 81-83.
- BHATT V, GREEN J, GREW N (2009) Dealing with aberrant vessels in radial free forearm flaps - Report of a case and review of literature. *J Cranio maxillo-facial Surg*, 37: 87-90.
- BUMBASIREVIĆ M, LESIĆ A, FILIPOVIĆ B (2005) Duplication of the radial artery in the radial forearm flap. *Clin Anat*, 18: 305-307.
- CHARLES JJ (1894) A case of absence of radial artery. *J Anat Physiol*, 28: 449-450.
- CIERVO A (2001) Absence of the brachial artery: report of a rare human variation and review of upper extremity arterial anomalies. *J Vasc Surg*, 33: 191-194.
- HARRINGTON (1905) A high bifurcation of the brachial artery with a reunion at the elbow. *John's Hospkins Hospital Bull*, 16: 65-66.
- KADANOFF D, BALKANSKY G (1966) Two cases with rare variations of arteries of the upper extremities. *Anat Anz*, 118: 289-296.
- KARLSSON S, NIECHAJEV IA (1982) The arterial anatomy of the upper extremity. *Acta Radiol Diagn (Stockh)*, 23: 115-123.
- PELIN C, ZAGYAPAN R, MAS N, KARABAY G (2006) An unusual course of the radial artery. *Folia Morphol*, 65: 410-413.
- POTEAT WL (1986) Report of a rare human variation: absence of the radial artery. *Anat Rec*, 214: 89-95.
- RODRÍGUEZ-NIEDENFÜHR M, BURTON GJ, DEU J,

- SAÑUDO JR (2001) Development of the arterial pattern in the upper limb of staged human embryos: normal development and anatomic variations. *J Anat*, 199: 407-417.
- RODRIGUEZ-NIEDENFUHR M, VAZQUEZ T, PARKIN IG, SANUDO JR (2003) The arterial patterns of the human upper limb: an update on the anatomical variations and the embryological development. *Eur J Anat*, 7: 21-28.
- SANKOTT AM (1919) Über eine neue Varietät der art. radialis. *Anat Anz*, 52: 502-511.
- SANKOTT AM (1920) Zweiter Beitrag zur kasuistik der varietäten der art. radialis. *Anat Anz*, 53: 397-398.
- SASAKI K, NOZAKI M, AIBA H, ISONO N (2000) A rare variant of the radial artery: clinical considerations in raising a radial forearm flap. *Br J Plast Surg*, 53: 445-447.
- SHETTY SD, NAYAK SB, MADHAV VN, SIRASANA-GANDLA SR, ABHINITHA P (2012) The abnormal origin, course and distribution of the arteries of the upper limb: a case report. *J Clin Diagn Res*, 6: 1414-1416.
- SUGANTHY J, KOSHY S, INDRASINGH I, VETTIVEL S (2002) A very rare absence of radial artery: a case report. *J Anat Soc India*, 51: 1-6.
- THOMPSON A (1884) Note on two instances of abnormality in the course and distribution of the radial artery. *J Anat Physiol*, 18: 265-269.
- WHALEN FX, MARTIN DP (2011) Unintentional cannulation of aberrant radial artery: review and treatment recommendations. *Signa Vitae*, 6: 89-90.