

Biometrical and histometrical observations on the testis and epididymis of the African sideneck turtle (*Pelusios castaneus*)

Samuel G. Olukole^{*1}, Matthew O. Oyeyemi² and Bankole O. Oke¹

¹Department of Veterinary Anatomy, Faculty of Veterinary Medicine and ²Department of Veterinary Surgery and Reproduction, Faculty of Veterinary Medicine, University of Ibadan, Ibadan, Nigeria

SUMMARY

Biometrical and histometrical observations were carried out on the testis and epididymis of twenty five adult African sideneck turtles (*Pelusios castaneus*) with a view to providing basic data that could be relevant in the comparative regional anatomy of the male reproductive organs of sea and freshwater turtles. The mean body weight of the turtles used in this work was 547 ± 41.4 g. The mean relative testicular and epididymal weights of the turtles were of 0.163% and 0.122%, respectively. The testis is sheathed by a capsule organised into two layers, the outer tunica vaginalis and the inner tunica albuginea. The highly convoluted seminiferous tubules of the testicular tissue had basement membranes lined with germ cells arranged in successive layers representing different stages of cell division. The epididymis had spermatozoa within its lumen, with about 5 to 8 ductuli efferentes found within its lamina propria. The epithelia of the epididymis and ductuli efferentes were lined by pseudostratified ciliated columnar cells. The diameter of the seminiferous tubules relative to those of the lumen and germinal epithelium of the testis, as well as the epididymal ductal diameter, luminal diameter and epithelial height of the *P. castaneus*, were all similar to those previously reported in turtles and other reptiles. This work provides baseline data on the gross and microanatomy of the testis and epididymis of *P. castaneus*, and is expected to

be useful in the comparative regional anatomy of sea and freshwater turtles.

Key words: Testis – Epididymis – African sideneck turtle – Biometry

INTRODUCTION

Turtles of the genus *Pelusios* belong to the family *Pelomedusidae* and are unable to fully withdraw their heads into their shells, instead of drawing it to the side and folding it beneath the upper edge of the shell, and hence are called African sideneck turtles (Broadley and Boycott, 2009). The African sideneck turtle (*Pelusios castaneus*) is a freshwater turtle of the family *Pelomedusidae*, widely distributed in West Africa, occurring from Guinea and Senegal to northwestern Angola (Kirkpatrick, 1995). The *P. castaneus* is a small to medium in size, with relatively extensive plastron that may have a hinge present between the pectoral and abdominal scutes (Olukole et al., 2010).

Biometric and histometrical observations of the male reproductive organs of turtles had been reported by several authors. These include the Stinkpot turtle, *Sternotherus odoratus*, (Mcpherson and Marion, 1981); the Australian freshwater turtle *Emydura krefftii*, (Goerges, 1983); the freshwater turtle *Trionyx gangeticus*, (Rao and Shaad, 1985); the Loggerhead turtle, *Caretta caretta*, (Wibbles et al., 1990); the Kemp's Ridley sea turtle, *Lepidochelys kempi*, (Rostal, 1991); the Australian fresh-

* Corresponding author: Samuel G. Olukole. Department of Veterinary Anatomy, Faculty of Veterinary Medicine, University of Ibadan, Ibadan, Nigeria. Tel: +2348033574752.

E-mail: sg.olukole@mail.ui.edu.ng

Submitted: 18 July, 2013. Accepted: 15 December, 2013.

water turtles, *Chelodina rugosa* and *Elseya dentata*, (Kennett, 1999) and Florida Softshell Turtle, *Apalone ferox* (Meylan et al., 2002). With the exception of the report of Olukole et al. (2011) on the gross anatomy of the male reproductive organs of the African sideneck turtle, there is hardly any research report on the morphology and morphometry of the male reproductive organs of the turtles of the genus *Pelusios*. The existing research reports on the genus had mainly focused on its conservation, nutrition and history of migration (Broadley and Boycott, 2009), morphometry of the external body anatomy (Olukole et al., 2010) and haematology (Omonona et al., 2011).

This study was therefore designed to investigate the biometry and histometry of the testis and epididymis of the *P. castaneus* with a view to providing basic data that could be relevant in the comparative regional anatomy of the male reproductive organs of sea and freshwater turtles.

MATERIALS AND METHODS

Twenty five adult male *P. castaneus*, picked up between the months of July and September (peak of raining season) from various river banks in Ibadan, Nigeria, were used for the study. The animals were kept in artificial ponds and were stabilized for 72 hours prior to the investigations carried out. They were fed with commercial fish pellets *ad libitum*. Biometry of the carapace and plastron were determined using a Draper® 115 mm vernier caliper and metric tape. The body weight of the animals was taken with the aid of a Microvar® weighing balance. The turtles were anaesthetized using ketamine HCl at 25mg/kg body weight intramuscularly using the thigh muscle. Anatomical nomenclature used in the study followed the reports of Laparent De Broin (2001) and Wyenken (2001) while the research protocol for the work followed guidelines from the Research and Ethics Committee of the Faculty of Veterinary Medicine, University of Ibadan, Nigeria.

The animals were sacrificed by cervical decapitation. The carapace was then separated from the plastron as described by Wyneken (2001). The superficial and deep structures of the coelomic cavities of the turtles were exposed. The right and left testes and epididymides were then dissected out quickly and placed in Petri dishes containing normal saline prior to morphometric investigations. The weight of the testes and epididymides were determined using the Digital Microvar® weighing balance, while metric investigations of these organs were made using metric tape and venier caliper. Biometric data of the testis and epididymis was carried out as reported by Olukole et al. (2009). Samples from the testes and epididymis were fixed in Bouin's fluid and embedded in paraffin blocks. Sections of 3 mm thick were stained with Haematoxylin and Eosin (Akinloye et al., 2002). The slides of testis and epididymis were studied under the light microscope and the following measurements were taken: the relative volume of the germinal epithelium, the luminal diameter of seminiferous tubule, the seminiferous tubular diameter, epididymal tubular diameter, epididymal luminal diameter and epididymal epithelial height. For each parameter, ten measurements were made per section using a calibrated eye-piece micrometer (Graticules Ltd. Toubridge Kent).

Statistical analysis

All data obtained were expressed as means with the standard deviation and subjected to Student's t-test and correlation analysis using the GraphPad Prism version 4.00 for Windows, GraphPad Software. Statistical significance was reported at $P < 0.05$.

RESULTS

The mean body weight of the turtles used in this work as well as the dimensions of the carapace and plastron are given in table 1. The epididymis was attached to the caudal border of the testis

Table 1. Mean and SD values of the testicular biometrical parameters of *P. castaneus*.

WOA(g)	WRT(g)	WLT(g)	GSI (%)	LRT(cm)	LLT(cm)	CRT(cm)	CLT(cm)
547	0.452	0.437	0.163	1.36	1.24	2.48	2.56
±41.4	±0.08 ^a	±0.07 ^a		±0.17 ^b	±0.09 ^b	±0.22 ^c	±0.19 ^c

*Means with different superscripts differ significantly ($P < 0.05$). WOA – Weight of the animal. WRT – Weight of the right testis. WLT – Weight of the left testis. GSI- Gonosomatic Index. LRT – Length of the right testis. LLT – Length of the left testis. CRT – Circumference of the right testis. CLT - Circumference of the left testis

Table 2. Mean and SD values of the epididymal biometrical parameters of *P. castaneus*.

WOA(g)	WRE(g)	WLE(g)	EMI (%)	LRE(cm)	LLE(cm)
547 ± 41.4	0.339 ± 0.0531 ^a	0.329 ± 0.0549 ^a	0.122	2.88 ± 0.202 ^b	2.96 ± 0.264 ^b

* Means with different superscript differ significantly ($P < 0.05$). WOA – Weight of the animal. WRE – Weight of the right epididymis. WLE – Weight of the left epididymis. EMI – Epididymal mass index. LRE – Length of the right epididymis. LLE – Length of the left epididymis.

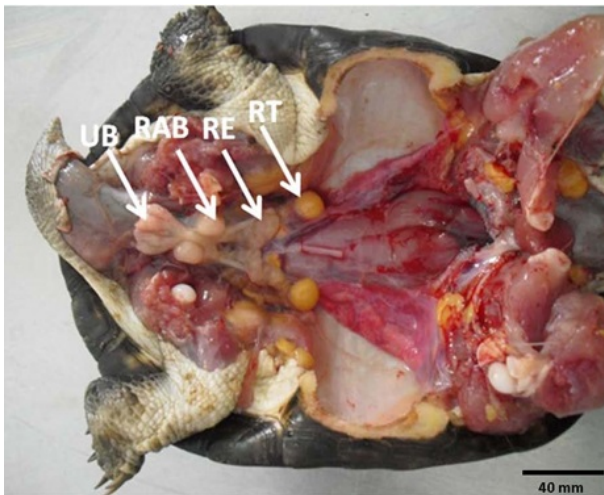


Fig. 1. Male reproductive organs of the African sideneck turtle (*P. castaneus*). RT: Right testis; RE: Right epididymis; RAB: Right accessory urinary bladder; UB: Urinary bladder.

(Fig. 1). The testis as well as epididymis was located ventral to the kidneys and cranial to the accessory urinary bladder (Fig. 2). The epididymis was cream in colour, convoluted and continued caudally as the ductus deferens. There was no significant difference ($P>0.05$) between the left and right testicular parameters on one hand as well as between the left and right epididymal parameters on the other hand (Tables 1 and 2). There was a weak positive correlation between the weight of the animals and the weight of the testis (Table 3). The mean relative testicular and epididymal weights of the turtles used for this study were of 0.163% and 0.122%, respectively. There were strong positive correlations between the weight of the turtles and the circumference of right and left testes (Table 3).

The testis of the *P. castaneus* is ensheathed by a capsule organised into two layers, the outer tunica vaginalis and the inner tunica albuginea. The tunica albuginea of the *P. castaneus* is thicker than the tunica vaginalis and is composed of dense connective tissue rich in blood vessels, fibrocytes and collagen fibres. The thin tunica vaginalis is composed of a single layer of simple epithelium having elongated nuclei and resting on a basement membrane separating it from the inner tunica albuginea (Fig. 3A). The histology of the testis of the *P. castaneus* shows the extension of the tunica albuginea into the testicular tissue proper in the form of septa (septula testis) divides it into lobules (lobuli testis), each lobule containing one or more seminiferous tubules (Fig. 3B). Wedged among adjacent seminiferous tubules was the interstitium containing interstitial (Leydig) cells and blood vessels. These cells were polygonal in shape and were found in most sections examined.

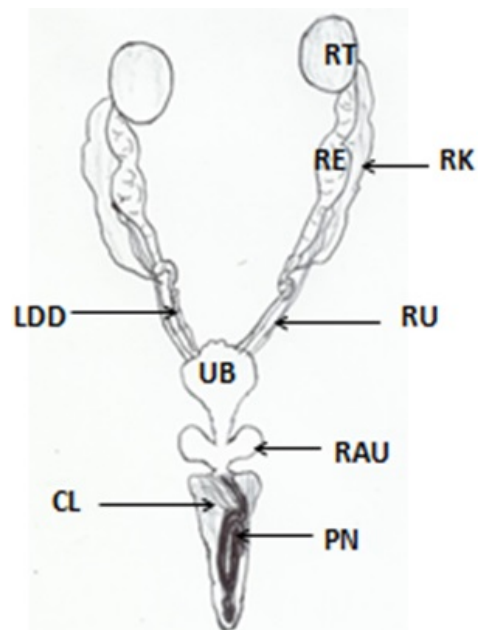


Fig. 2. Diagrammatic presentation of the male reproductive organs of the *P. castaneus*. RK: Right Kidney; RU: Right Ureter; LDD: Left Ductus Deferens; RE: Right Epididymis; RT: Right Testis; UB: Urinary Bladder; RAU: Right accessory Urinary Bladder; CL: Cloaca; PN: Penis.

Seminiferous tubules of various sizes and shapes ranging from being irregular to S-shaped were found in sections (Fig. 3B). In most sections, the spherically shaped seminiferous tubules were more abundant. Highly convoluted seminiferous tubules formed about 70% of the testicular tissue of the *P. castaneus* with each having a basement membrane lined with germ cells arranged in successive layers representing different stages of cell division (spermatogenesis and meiosis) and differentiation (spermiogenesis). Cells identified in succession from the basement membrane to the lumen of the

Table 3. Estimates of correlation between body weight of the animal and the testicular and epididymal parameters of *P. castaneus*

Parameters	Coefficient of correlation (r)
WOA(g)	1.000
WRT(g)	0.218
WLT(g)	0.128
LRT(cm)	0.0551
LLT(cm)	0.115
CRT(cm)	0.613
CLT(cm)	0.627
WRE(g)	0.276
WLE(g)	0.0399
LRE(cm)	0.522
LLE(cm)	0.661

WOA – Weight of the animal. WRT – Weight of the right testis. WLT – Weight of the left testis. LRT – Length of the right testis. LLT – Length of the left testis. CRT – Circumference of the right testis. CLT - Circumference of the left testis. WRE – Weight of the right epididymis. WLE – Weight of the left epididymis. LRE – Length of the right epididymis. LLE – Length of the left epididymis

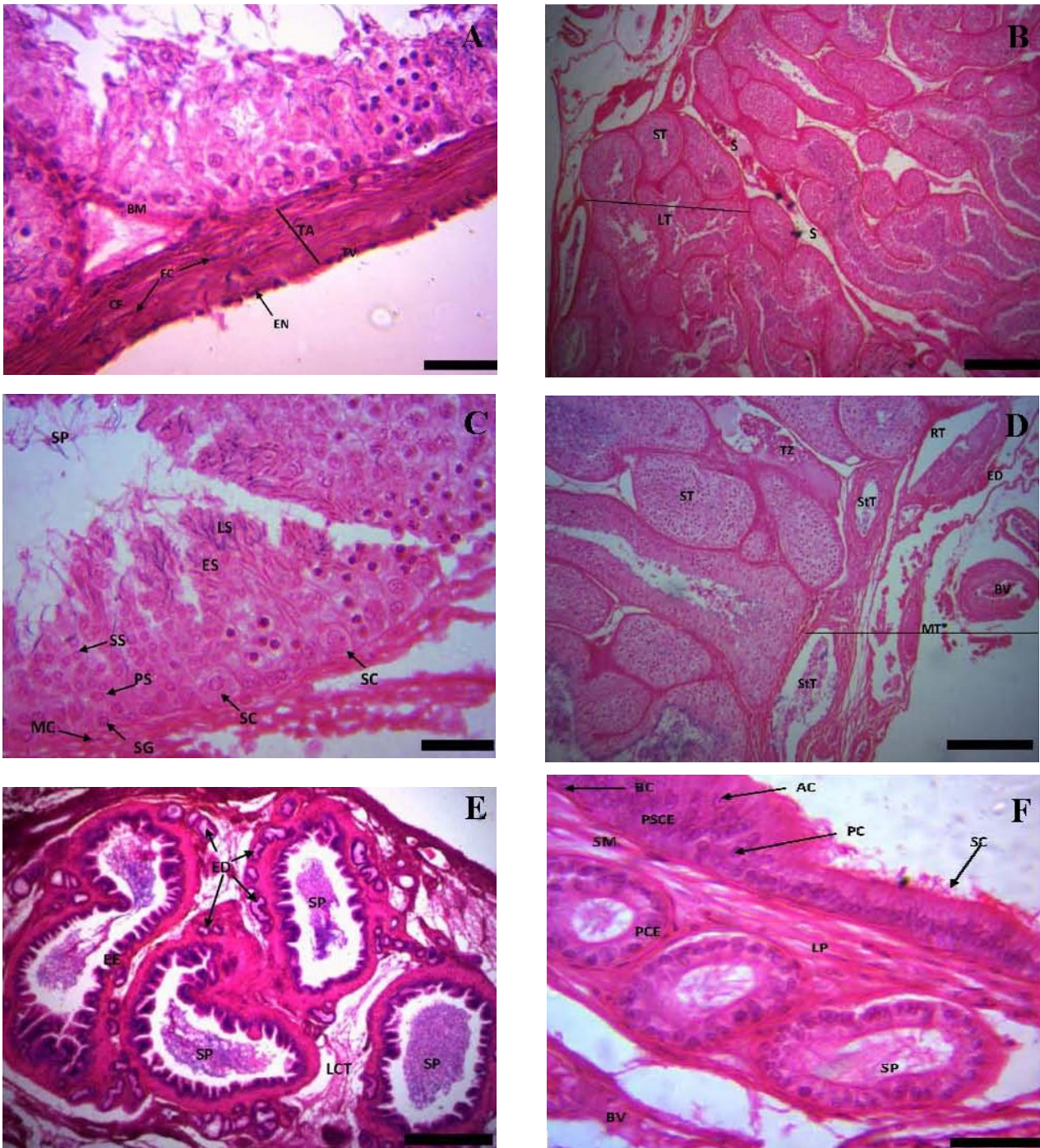


Fig. 3. Photomicrographs of the testis and epididymis of the testis of the *P. castaneus*. **(A)** The testicular capsule showing, BM: basal membrane of seminiferous tubule; CF: collagen fibres; EN: elongated nucleus of the epithelium of tunica vaginalis; FC: fibrocytes; TA: tunica albuginea; TV: tunica vaginalis. (Bar: 5 μ m). **(B)** Testis showing the extension of tunica albuginea into the testicular tissue proper in the form of septa (S) which divides it into lobules, lobuli testis, (LT) each consisting of 4- 6 seminiferous tubules (ST). (Bar: 100 μ m). **(C)** Testis showing: SC: Sertoli cell; SG: Spermatogonium; PS: Primary spermatocyte; SS: Secondary spermatocyte; ES: Early (round) spermatid; LS: Late spermatid; SP: Spermatozoa; MC: Myoid cell (flattened contractile cell found outside the basement membrane of the seminiferous tubule); IC: Interstitial cell. (Bar: 5 μ m). **(D)** Mediastinum testis of *P. castaneus*. MT: Mediastinum testis; ST: Seminiferous tubule; StT: Straight tubule; TZ: Transitional zone; RT: Rete testis; ED: Efferent ductile; BV: Blood vessel. Notice that the transitional zone joins the seminiferous tubule to a straight tubule. (Bar: 25 μ m). **(E)** Epididymis of the *P. castaneus* showing the epididymal ducts surrounded by efferent ducts (ED); EE: Epithelium of epididymis; LCT: Loose connective tissue; SP: Spermatozoa. (Bar: 5 μ m). **(F)** Epididymis of the *P. castaneus* showing the pseudostratified columnar epithelium (PSCE) of the epididymis; the principal cell (PC) and apical cell (AP). SM: Smooth muscle; LP: Lamina propria; SP: Spermatozoa; PCE: Pseudostratified columnar epithelium of the efferent duct; BV: Blood vessel. (Scale bar: 5 μ m).

seminiferous tubule were spermatogonia, primary spermatocyte, secondary spermatocyte (few in number), round and elongated spermatids; and spermatozoa. The Sertoli cell was also identified by its high nuclear to cytoplasmic ratio although its outline and details were barely identified. Contractile cells known as myloid cells were found beneath the basement membrane of the seminiferous tubule (Fig. 3C). The mediastinum testis of the *P. castaneus* is composed the rete testis which leads from the seminiferous tubules into efferent ductules. Also, within the mediastinum testis are the straight tubules and the transitional zone that links the seminiferous tubules with the straight tubules (Fig. 3D).

The epididymis had spermatozoa within its lumen all the sections observed (Figs. 3E and F). In these sections, about 5 to 8 ductuli efferentes were found within the lamina propria of the epididymis (Fig. 3E). The epithelia of the epididymis and ductuli efferentes were lined by pseudostratified ciliated columnar cells (Fig. 3F). The epithelium of the epididymis had basal cells located at the basement membrane; principal cells were abundant with few apical cells found very close to the luminal surface while smooth muscles were found beneath the basement membrane of the epididymal epithelium within the lamina propria (Fig. 3F). Also, within the lamina propria of the ductuli efferentes were found blood vessels and connective tissues.

The mean and standard deviation of the histomorphometric parameters of the testis and epididymis (3 different segments based on morphology: proximal, mid and distal portions) are given in table 4. The diameter of the seminiferous tubules of the turtle was significantly lower ($P < 0.05$) than the diameter of the duct of the epididymis for the proximal portion of the epididymis (Table 4). The diameter of the duct of the epididymis showed no significant differences ($P > 0.05$) across the three regions of the epididymis. However, the luminal diameter of the distal portion of the epididymis was significantly higher ($P < 0.05$) than that of the proximal portion of the epididymis while the epithelial height of the proximal portion was significantly higher ($P < 0.05$) than that of the distal portion (table 4). With respect to the luminal diameter, epithelial height and ductal diameters, there were no significant differences ($P > 0.05$) between the mid and distal portions of the epididymis (Table 4). However, the values obtained for luminal and ductal diameter were higher in the distal portion than those of the mid portion. Also, the mean value of epithelial height was higher in the mid portion than that of the distal portion of the epididymis. There was a low positive correlation (0.0530) between the diameter of the duct of epididymis and its epithelial height and also a high negative correlation (-0.7422) between epithelial height and lumen diameter.

DISCUSSION

The colour, shape and constituency of the testis and epididymis observed in this study were in conformity with earlier reports on the male reproductive organs of freshwater turtles (Keller and Schwanke, 2001). This is similar to the testis of the Australian freshwater turtle, *Emydura kreftii* (Georges, 1983). However, this is contrary to the report of Wyneken (2001) on sea turtles which stated that the testis is generally tan in colour and fusiform in shape. The gonadosomatic index of the turtles used in this work is similar to that reported in the freshwater turtle, *Trionyx gangeticus* being 0.101% (Roa and Shaad, 1985) but is smaller than the 0.5% gonadosomatic index reported in the Florida Softshell Turtle, *Apalone ferox* (Meylan et al., 2002).

The Epididymal mass index obtained in the study is similar to that reported in the Florida Softshell Turtle, *Apalone ferox* being 0.3% (Meylan et al., 2002). The positive correlation between the weight of the animal and the weights of the testis and epididymis implies that the as the body weight of the animal increased, those of the testis and epididymis increased concurrently. The average length of the right testis was greater than that of the left but the length of the left epididymis was greater than the right. This is consistent with a previous report on testicular parameters of freshwater turtles (Roa and Shaad, 1985). Anatomical relations of the epididymis as well as the testis of the *P. castaneus* are similar to those reported in sea and freshwater turtles (Roa and Shaad, 1985; Wyneken, 2001; Keller and Schwanke, 2001; Meylan et al., 2002).

Microscopic analysis of the epididymis of the turtle in this study showed that it is lined by pseudostratified columnar epithelium with stereocilia. This is in conformity with earlier reports on the histology of the epididymis of reptiles (Keller and Schwanke, 2001; Meylan et al., 2002). This epithelium type is also in conformity with that reported in mammals (Oke, 1982, 1988; Massanyi et al., 2003; Olukole and Obayemi, 2010). Also the efferent duct of the *P. castaneus* is covered by pseudostratified columnar epithelium as earlier reported in reptiles as well as mammals (Lofts, 1977; Bacha and Bacha, 2000; Meylan et al., 2002; Young et al., 2006). The basal cells located at the basement membrane of the epithelium of the epididymis, as well as the abundance of principal cells, with few apical cells found very close to the luminal surface with smooth muscles beneath the basement membrane of the epididymal epithelium, had all been reported in reptiles and mammals (Lofts, 1977; Bacha and Bacha, 2000; Meylan et al., 2002; Young et al., 2006).

The histological components of the testicular capsule of the *P. castaneus* bear close similarity with the report of Al-Dokhi et al. (2004) on the tes-

ticular capsule of the snake *Eryx jayakari*. The histological features of the thick tunica albuginea and thin tunica vaginalis of the *P. castaneus* are also consistent with those reported in reptile and mammals (Meylan et al., 2002; Al-Dokhi et al., 2004; Young et al., 2006). The tunica albuginea of reptiles and mammals had been reported to compose of dense connective tissue rich in blood vessels, fibrocytes and collagen fibres (Bacha and Bacha, 2000; Al-Dokhi et al., 2004; Young et al., 2006). Seminiferous tubules of various sizes and shapes, ranging from being irregular to S-shaped found in the turtles, are in conformity with earlier reports on the testis of turtles and reptiles generally (Meylan et al., 2002; Al-Dokhi et al., 2004; Gribbins et al., 2003; Gribbins, 2011; Gribbins and Rheubert, 2011). Similar observations had been reported in mammals (Bacha and Bacha, 2000; Young et al., 2006). The organization of the cells of the spermatogenic series as well as the positions of the Sertoli cells in the seminiferous tubules of the *P. castaneus* is similar to those reported in reptiles and mammals (Bacha and Bacha, 2000; Gribbins et al., 2003; Dyce et al., 2002; Young et al., 2006; Gribbins, 2011; Gribbins and Rheubert, 2011). Also, the relationship among the transitional zone, the seminiferous tubules and the rete testis within the mediastinum testis as observed in the *P. castaneus* is similar to those reported in the stinkpot turtle *Sternotherus odoratus* (Mcpherson and Marion, 1981), the Mediterranean Gecko, *Hemidactylus turcicus* (Rheubert et al., 2011) as well as in mammals (Bacha and Bacha, 2000).

The histomorphometry of the testis and epididymis of the *P. castaneus* is similar to those of the Australian freshwater turtle *Emydura krefftii*, the freshwater turtle *Trionyx gangeticus*, and the male Slider Turtle, *Trachemys scripta* (Goerges, 1983; Rao and Shaad, 1985, Gribbins et al., 2003). It is also in close similarity with those of rodents (Oke, 1982, 1988; Massanyi et al., 2003; Olukole et al., 2009; Olukole and Obayemi, 2010). While the diameter of the seminiferous tubules of the *P. castaneus* is similar to those reported in the freshwater turtle *Trionyx gangeticus* (Rao and Shaad, 1985) and in the Florida Softshell Turtle, *Apalone ferox* (Meylan et al., 2002), it is however significantly lower than those reported in mammals (Oke, 1982, 1988; Kolodzieyski and Danko, 1995; Massanyi et al., 2003; Olukole et al., 2009; Olukole and Obayemi, 2010). Although the epididymis of the *P. castaneus* cannot be grossly divided into head, body and tail as in mammals, yet the values of its luminal diameter, epithelial height and epithelial ductal diameter across the proximal, mid and posterior portions of the epididymis, all follow the similar patterns of dimensions reported in the head, body and tail epididymis of mammals (Massanyi et al., 2003; Olukole et al., 2009; Olukole and Obayemi, 2010). The posterior portion of the epi-

dymis, like the tail epididymis of mammals, contained more spermatozoa than its proximal and mid portions. This is in conformity with previous reports on the epididymis of turtles (Mcpherson and Marion, 1981; Georges, 1983; Kennett, 1999). The low positive correlation observed between the diameter of the duct of epididymis and its epithelial height means that with an increase in epithelial height, the increase in ductal diameter is low. The high negative correlation obtained between epithelial height and lumen diameter suggests that with a decrease in the height of the epithelium, the lumen increased significantly. This relationship can be attributed to function rather than structure, as the posterior portion of epididymis has the widest lumen since it is assumed to store spermatozoa. This may explain why more spermatozoa mass were found in the posterior portion of the epididymis of the *P. castaneus* than in its mid and proximal portions.

This study shows that biometrical observations, histology and histomorphometry of the testis and epididymis of the *P. castaneus* are similar to those previously reported in turtles and other reptiles. Nevertheless, seasonal studies on these observations are recommended for further details on the reproductive biology of the male *P. castaneus*. The outcome of this work therefore provides baseline data on the dimensions of the testis and epididymis in the *P. castaneus*, thereby making available useful research data in comparative regional anatomy of sea and freshwater turtles as well as the reproductive biology of the turtle.

ACKNOWLEDGEMENTS

This work was supported by University of Ibadan Senate Research Grants (SRG/FVM/2010/4A and SRG/FVM/2010/1B).

REFERENCES

- AKINLOYE AK, IGBORHA OO, OLANIYI MO, ALAKA OO, OKE BO (2002) Preliminary investigation on the effects of bitter kola (*Garcinia kola*) extract on rabbit testes and epididymides. *Trop Vet*, 18: 49-54.
- AL-DOKHI OA, AL-ONAZEE YZ, MUBARAK M (2004) Light and electron microscopy of the testicular tissue of the Snake *Eryx jayakari* (Squamata, Reptilia) with a reference to the dividing germ cells. *J Biol Sci*, 4: 345-351.
- BACHA WJ, BACHA LM (2000). Color Atlas of Veterinary Histology. Lippincott Williams and Wilkins, USA, pp 219.
- BROADLEY DG, BOYCOTT RC (2009) *Pelusios sinuatus* (Smith 1838) –Serrated Hinged Terrapin. Conservation Biology of Freshwater Turtles and Tortoises. *Chelonian Research Monographs*, 5: 036.1-036.5.
- DYCE KM, SACK WO, WENSING CJC (2002) Textbook of Veterinary Anatomy. 2nd ed. W.B. Saunders, Philadelphia.

- GEORGES A (1983) Reproduction of the Australian freshwater turtle *Emydura krefftii* (Chelonia: Chelidae). *J Zoo London*, 201: 331-350.
- GRIBBINS KM (2011) Reptilian spermatogenesis: A histological and ultrastructural perspective. *Spermatogenesis*, 1: 250-269.
- GRIBBINS KM, RHEUBERT JL (2011) The ophidian testis, spermatogenesis and mature spermatozoa. In: Aldridge RD, Sever DM (editors). *Reproductive Biology and Phylogeny of Snakes*. Vol. 9. Enfield, NH: Science Publishers, pp 183-264.
- GRIBBINS KM, GIST DH, CONGDON JH (2003) Cytological evaluation of spermatogenesis and organization of the germinal epithelium in the male Slider Turtle, *Trachemys scripta*. *J Morphol*, 255: 337-346.
- KELLER A, SCHWANKE C (2001) Repteis fosseis do Brasil: breve introducao a herptologia. In: Brito IM (Ed.). *Geologia historica*. Uberlandia: EDUFU 303-363.
- KENNETT RM (1999) Reproduction of two species of freshwater turtle, *Chelodina rugosa* and *Elseya dentata*, from the wet-dry tropics of northern Australia. *J Zoo London*, 247: 457-473.
- KIRKPATRICK DT (1995) *An Essay on Taxonomy and the Genus Pelusios*. Available at: <http://www.unc.edu/~dtkirkpa/stuff/pel.html>. Accessed 22 February 2013.
- KOLODZIEYSKI L, DANKO J (1995) A histological, histochemical and immunohistochemical picture of the ovary of a hermaphrodite goat. *Folia Veterinaria*, 39: 107-110.
- LAPPARENT DE BROIN F DE (2001) The European turtle fauna from the Triassic to the present. *Dumerilia*, 4: 155-217.
- LOFTS B (1977) Patterns of spermiogenesis and steroidogenesis in male reptiles. In: Tyndale-Discoe TH (ed.). *Reproduction and evolution*. Proceedings of the 4th symposium on comparative biology of reproduction. Canberra, Australia Capital Territory, Australia, pp 127-136.
- MASSANYI P, JANCOVA A, UHRIN V (2003) Morphometric study of male reproductive organs in the rodent species *Apodemus Sylvaticus* and *Apodemus flavicollis*. *Bull Vet Inst Pulway*, 47: 133-138.
- MCPHERSON RJ, MARION KR (1981) Seasonal testicular cycle of the stinkpot turtle (*Sternotherus odoratus*) in central Alabama. *Herpetologica*, 37: 33-40.
- MEYLAN PA, SCULER R, MOLER P (2002) Spermatogenic cycle of the Florida Softshell Turtle, *Apalone ferox*. *Copeia*, 3: 779-786.
- OKE BO (1982) Some studies on the reproductive organs of the African giant rat (*Cricetomys gambianus*, Waterhouse) during the climatic seasons at Ibadan. *M.Sc. thesis, Department of Veterinary Anatomy, University of Ibadan, Nigeria*.
- OKE BO (1988) Some aspects of the reproductive biology of the African giant rat (*Cricetomys gambianus*, Waterhouse). Ph D thesis, Department of Veterinary Anatomy, University of Ibadan, Nigeria.
- OLUKOLE SG, OBAYEMI TE (2010) Histomorphometry of the testis and epididymis in the domesticated adult African great cane rat (*Thryonomys swinderianus*). *Int J Morphol*, 28: 1251-1254.
- OLUKOLE SG, OYEYEMI MO, OKE BO (2009) Biometrical observations on the testes and epididymis of the domesticated adult African great cane rat (*Thryonomys swinderianus*). *Eur J Anat*, 13: 71-75.
- OLUKOLE SG, AINA OO, OKUSANYA BO (2010) Morphometric analysis of the external body anatomy of the African sideneck turtle *Pelusios sinuatus*. *Conference proceedings of the 30th Annual Symposium on Sea Turtle biology and conservation held in Goa, India*, 313.
- OLUKOLE SG, OYEYEMI MO, OKE BO (2011) Gross anatomy of the male reproductive organs of the African Sideneck Turtle (*Pelusios sinuatus*). *Book of Abstracts, 48th Annual Conference of the Nigerian Veterinary Medical Association*, held in Ilorin, Kwara State, Nigeria, 58.
- OMONONA AO, OLUKOLE SG, KUSHE FA (2011) Haematology and serum biochemical parameters in free ranging African sideneck turtle (*Pelusios sinuatus*) in Ibadan, Nigeria. *Acta Herpetologica*, 6: 267-274.
- RAO RJ, SHAAD FU (1985) Sexual cycle of the male freshwater turtle, *Trionyx gangeticus* (Cuvier). *Herpetologica*, 41: 433-437.
- RHEUBERT JL, SIEGEL DS, VENABLE KJ, SEVER DM, GRIBBINS KM (2011) Ultrastructural description of spermiogenesis within the Mediterranean Gecko, *Hemidactylus turcicus* (Squamata: Gekkonidae). *Micron*, 42: 680-690.
- ROSTAL DC (1991) The reproductive behaviour and physiology of the Kemp's Ridley sea turtle, *Lepidochelys kempi* (Garman, 1880). *Ph.D. dissertation Texas AandM University College Station*.
- WIBBLES T, OWENS DW, LIMPUS CJ, REED PC, AMOSS MS (1990) Seasonal changes in serum gonadal steroids associated with migration, mating, and nesting in the loggerhead sea turtle (*Caretta caretta*). *Endocrinology*, 79: 154-164.
- WYNEKEN J (2001) *The anatomy of sea turtles*. US Department of Commerce NOAA Technical Memorandum. NMFS-SEFSC 470, 1-172.
- YOUNG B, LOWE JS, STEVENS A, HEATH JW (2006) *Wheater's Functional Histology: A text and colour atlas*. Fifth edition, Churchill Livingstone, Elsevier Limited, pp 346-358.